

IMPLANT TRIBUNE

The World's Implant Newspaper · U.S. Edition

Miniscrew series

Part II offers tips for optimal miniscrew insertion.

▶ Section B1

ENDO TRIBUNE

The World's Endodontic Newspaper · U.S. Edition

Apical microsurgery

Consider these nine basic steps when surgery is required.

▶ Section C1

COSMETIC TRIBUNE

The World's Cosmetic Dentistry Newspaper · U.S. Edition

Mutilated dentition

Full-mouth fixed rehabilitation of a mutilated dentition.

▶ Section D1

Implants displaced into the maxillary sinus

By Dov M. Almog, DMD, Kenneth Cheng, DDS & Mohammad Rabah, DMD

As some have predicted,¹ the growth in dental implant-based procedures increased considerably in recent years. As a result, there has been a rapid increase in the number of practitioners involved in implant placement, including specialists and generalists, with different levels of expertise.

At the same time, although at a low frequency, we are witnessing a diversity of unusual complications associated with these procedures, some of which are displaced implants into the maxillary sinus.

A literature search revealed several

published reports of displaced foreign bodies into the maxillary sinus.²⁻⁶ Generally speaking, foreign bodies in the maxillary sinus include multiple displaced objects. These include teeth, roots, impression materials, dental instruments, broken burs and, more recently, dental implants.

Although foreign bodies in the maxillary sinus are not common, it behooves us to familiarize ourselves with such an unusual complication and its management. Displacement of such foreign bodies into the maxillary sinus occurs following dental procedures that create an unplanned or antral perforation.

→ DT page 2A

AD



Dental Collab BETA

FIRST MONTH FREE
CODE: DTDC09

CREATE,
SHARE,
COLLABORATE.

Connect your treatment workspaces with dental professionals invited to join your private network from around the globe.

www.DentalCollab.com

PNDC Conference: Where education meets beauty!



The 122nd annual Pacific Northwest Dental Conference (PNDC) offers two days of continuing education in one of the most picturesque and family-friendly settings. (Photo/Beverly Sparks) → PND Conference, page 10A

Washington cracks down on tobacco, and ADA approves

By Fred Michmershuizen, Online Editor

The American Dental Association (ADA) is applauding new legislation to regulate tobacco. The Family Smoking Prevention and Tobacco Control Act gives the U.S. Food and Drug Administration (FDA) the express authority to regulate the manufacture, marketing and distribution of tobacco products.

The ADA has a long-standing policy that nicotine is a drug and that cigarettes and other tobacco products are

nicotine delivery devices and, therefore, should be regulated.

"Dentists are the first line of defense in the war against oral cancer and many other tobacco-related diseases," said ADA President Dr. John S. Findley. "About nine out of 10 people who will die from oral and throat cancers use tobacco."

"Tobacco products are also associated with higher rates of gum disease, one of the leading causes of tooth loss in adults," Findley said. DT

AD



Is this the first 8th Generation bond?

Futurabond DC Dual-Cured

THE DENTAL ADVISOR *****

- It is dual-cured and works with all light-, self- or dual-cured resins
- It works in a self-cured mode without any light - great for endo
- It takes only 35 sec. from start to finish

More info and FREE SAMPLE at www.vocoamerica.com

- and it has everything you expect from a great self-etch bond
- Virtually no sensitivity
- Over 30 MPa bond strength to dentin and enamel

Futurabond DC - one for all applications

VOCO creative in research

Call toll-free 1-888-658-2584

PRSRRT STD
U.S. Postage
PAID
Permit # 506
Mechanicsburg, PA

Dental Tribune America
215 West 50th Street
Suite #801
New York, NY 10001

Orange juice bad for teeth, scientists say

By Fred Michmershuizen, Online Editor

Scientists at the University of Rochester Medical Center who were recently studying the effects of whitening agents on human teeth discovered something alarming: acidic fruit juices markedly decreased hardness and increased roughness of tooth enamel. No significant change in hardness or surface enamel was found from whitening.

"Orange juice decreased enamel hardness by 84 percent," said YanFang Ren, DDS, PhD, of the university's Eastman Institute for Oral Health.

In the study, "Effects of tooth whitening and orange juice on surface properties of dental enamel," published in the *Journal of Dentistry* (Volume 37, Issue 6, June 2009), Ren and his team determined that the effects of 6 percent hydrogen peroxide, the common ingredient in professional and over-the-counter whitening products, are insignificant compared to acidic fruit juices.

Weakened and eroded enamel may speed up the wear of the tooth and increase the risk for tooth decay to quickly develop and spread.

"Most soft drinks, including

sodas and fruit juices, are acidic in nature," Ren said. "Our studies demonstrated that orange juice, as an example, can potentially cause significant erosion of teeth."

It's long been known that juice and sodas have high acid content and can negatively affect enamel hardness.

"There are also some studies that showed whitening can affect the hardness of dental enamel, but until now, nobody had compared the two," Ren explained. "This study allowed us to understand the effect of whitening on enamel relative to the effect of a daily dietary activity, such as drinking juices."

"It's potentially a very serious problem for people who drink sodas and fruit juices daily," said Ren, who added that dental researchers nationwide are increasingly studying tooth erosion and are investing significant resources into possible preventions and treatments.

"We do not yet have an effective tool to avert the erosive effects, although there are early indications that higher levels of fluoride may help slow down the erosion," he said. **DT**

(Source: University of Rochester Medical Center)

← **DT** page 1A

The procedure associated with the removal of foreign bodies from the maxillary sinuses is considered very invasive. In this case report, the authors describe a systematic approach to the removal of two implants displaced into the right and left maxillary sinuses.

Currently, there are two accepted methods for removing foreign bodies displaced into the maxillary sinus. One method is the endoscopic transnasal maxillary sinus surgery.⁷⁻¹⁰ Access to the maxillary sinus is achieved through the nose via the ostium. The foreign body is captured and removed using an urological retrieval basket through the endoscopic working channel port. The advent of endoscopic techniques has made it the preferable choice, especially for patients with chronic sinusitis.

The most commonly used technique for retrieval of foreign bodies displaced into the maxillary sinus is the Caldwell-Luc procedure. In contrast to the endoscopic technique, which involves accessing the maxillary sinus via the nose, the Caldwell-Luc procedure involves gaining access to the maxillary sinus by the fenestration of the anterior lateral wall of the maxillary sinus or canine fossa.^{11,12}

The Caldwell-Luc procedure offers better direct visual access to the maxillary sinus as compared to the endoscopic approach, but is considered more aggressive with potentially more serious complications. Some of the possible complications are dysesthesia of the infraorbital nerve, numbness of the maxillary teeth, injury to the floor of the orbit and facial edema. This older and perhaps less conservative technique for accessing the maxillary sinus was first introduced by two otolaryngologists (American and French) in 1893.¹¹

Case report

A 50-year-old African-American male Vietnam veteran presented to the VA New Jersey Health Care System Dental Service at East Orange seeking dental care.

A comprehensive oral and maxillofacial examination included an intra-oral and extraoral exam, including cancer screening, full-mouth X-rays, and a cone-beam CT (i-CAT™ 3D CBCT Imaging Sciences International, Hatfield, Pa.) revealing, among other things, two implants displaced into the right and left maxillary sinuses.

Ultimately, the exam revealed a diversity of oral and maxillofacial problems, such as retained roots, decay and missing teeth, to name a few. Nevertheless, the chief complaint noted by the patient, and most profound clinical finding, was "two implants displaced into the right and left maxillary sinuses" (Figs. 1-3). The medical history was non-contributory.

Proceeding with careful assessment of all the available diagnostic information, and upon further discussion with the patient, several treatment options were developed in association with his retained roots, caries and missing teeth. As far as the patient's chief

→ **DT** page 4A

DENTAL TRIBUNE

The World's Dental Newspaper - US Edition

Publisher

Torsten Oemus
t.oemus@dtamerica.com

President & CEO

Peter Witteczek
p.witteczek@dtamerica.com

Chief Operating Officer

Eric Seid
e.seid@dtamerica.com

Group Editor & Designer

Robin Goodman
r.goodman@dtamerica.com

Editor in Chief Dental Tribune

Dr. David L. Hoexter
d.hoexter@dtamerica.com

Managing Editor/Designer

Implant & Endo Tribune
Sierra Rendon
s.rendon@dtamerica.com

Managing Editor/Designer

Ortho Tribune & Show Dailies
Kristine Colker
k.colker@dtamerica.com

Online Editor

Fred Michmershuizen
f.michmershuizen@dtamerica.com

Product & Account Manager

Mark Eisen
m.eisen@dtamerica.com

Marketing Manager

Anna Wlodarczyk
a.wlodarczyk@dtamerica.com

Sales & Marketing Assistant

Lorrie Young
l.young@dtamerica.com

C.E. Manager

Julia E. Wehkamp
E-mail: j.wehkamp@dtamerica.com

Dental Tribune America, LLC
215 West 35th Street, Suite 801
New York, NY 10001
Tel.: (212) 244-7181
Fax: (212) 244-7185



Published by Dental Tribune America
© 2009, Dental Tribune America, LLC.
All rights reserved.

Dental Tribune strives to maintain the utmost accuracy in its news and clinical reports. If you find a factual error or content that requires clarification, please contact Group Editor Robin Goodman, r.goodman@dtamerica.com. Dental Tribune cannot assume responsibility for the validity of product claims or for typographical errors. The publisher also does not assume responsibility for product names or statements made by advertisers. Opinions expressed by authors are their own and may not reflect those of Dental Tribune America.

Editorial Board

Dr. Joel Berg
Dr. L. Stephen Buchanan
Dr. Arnaldo Castellucci
Dr. Gordon Christensen
Dr. Rella Christensen
Dr. William Dickerson
Hugh Doherty
Dr. James Doundoulakis
Dr. David Garber
Dr. Fay Goldstep
Dr. Howard Glazer
Dr. Harold Heymann
Dr. Karl Leinfelder
Dr. Roger Levin
Dr. Carl E. Misch
Dr. Dan Nathanson
Dr. Chester Redhead
Dr. Irwin Smigel
Dr. Jon Suzuki
Dr. Dennis Tartakow
Dr. Dan Ward

ADS

Dental Collab BETA
FINALLY A SOLUTION FOR GETTING THAT SECOND OPINION.
WWW.DENTALCOLLAB.COM
FIRST MONTH FREE
CODE: DTDC09
IT'S NEW

BUY THREE, GET 1 FREE*

Luxatemp® Fluorescence
the ultimate esthetic provisional material

2009 DENTAL ADVISOR Top Provisional Material
2008 REALITY REALITY'S CHOICE
2009 REALITY REALITY'S CHOICE

DMG AMERICA

***SPECIAL OFFER: Buy 3 Luxatemp® or Luxatemp Fluorescence Automix, Get 1 FREE!**
To order, contact your authorized dental supply dealer.
To receive FREE goods, fax dealer invoice to 201-894-0213. All orders billed and shipped through dealer. For more information, call 800-662-6383. Offer valid through 6/30/09. Promotion cannot be combined with any other offers and may be changed or discontinued at any time without notice. Limit 5 offers per dental office. Offer code: DTRIBLTF

SAFER. STRONGER. FASTER.

TF is twisted, not ground – unlike other nickel titanium files – making it more durable. Most endodontic files are made by grinding the flutes, weakening the metal's molecular structure which can lead to separation. Not so with TF.

Our unique manufacturing process produces a file with optimal sharpness and flexibility. TF allows you to work in difficult situations faster, safer and with a stronger file.

Bottom line – TF helps you achieve your goals for saving natural dentition, alleviating your patients pain and managing dental trauma.

Interested in improving your endodontic efficiency? Go to our TF website for the details and the solutions.



TWISTED FILES

www.TFWITHRphase.COM

For more information on TF visit our website or call 800.346.ENDO. You can now shop online at store.sybronendo.com.

← DT page 2A

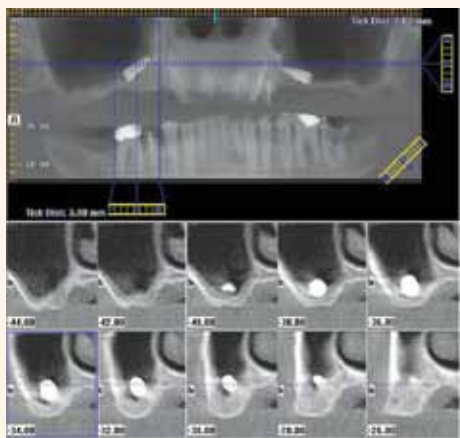


Fig. 1: Pre-operative diagnostic cone-beam CT revealing, among other things, two implants displaced into the right and left maxillary sinuses. By utilizing the i-CAT™ 3D CBCT (Imaging Sciences International, Hatfield, Pa.), which includes clear-cut panoramic and cross-sectional slices of any desired location, one obtains precise anatomical information.

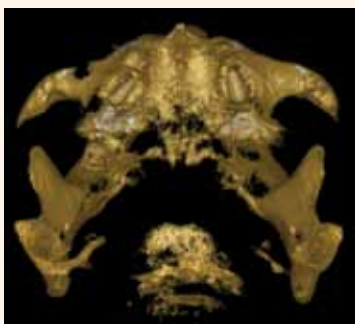


Fig. 3: Three-dimensional virtual rendering (3-DVR) of the displaced implants provides the surgeon feedback as to the surgical approach. In this case, a Caldwell-Luc procedure was performed using a bur to create an access window through the lateral wall of the maxilla, thereby gaining direct access to the displaced implant.

complaint, one treatment option was offered to him, that is, the Caldwell-Luc procedure to remove both displaced implants in his maxillary sinuses. After careful consideration, the patient chose to proceed with the proposed treatment plan.

A Caldwell-Luc procedure was performed bilaterally under general anesthesia. Specifically, the Caldwell-Luc procedure involved making an incision in the bucco-gingival sulcus in the area of the maxillary canine and bicuspid teeth, exposing the anterior lateral wall of the maxilla. Care was taken to avoid injury to the infraorbital nerve as it exits in the infraorbital foramen.

Using a bur and Kerrison's rongeurs, a window was made through the anterior lateral wall of the maxilla, thereby gaining access to the maxillary

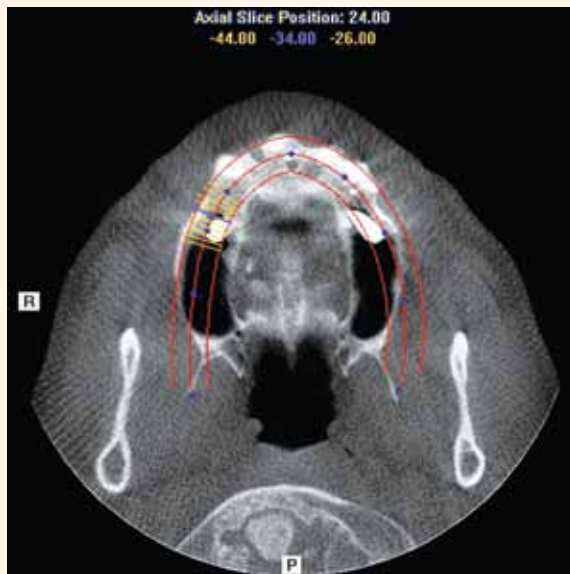


Fig. 2: Axial slice is useful for revealing the two displaced implants from a different angle.

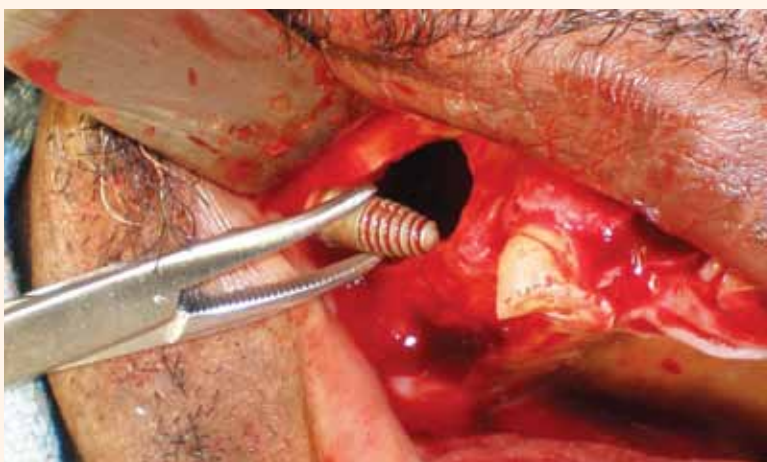


Fig. 4: Caldwell-Luc procedure is useful in gaining access to the maxillary sinus by the fenestration of the anterior lateral wall of the maxillary sinus. Note successful retrieval of implant from the maxillary right sinus through the access window.

sinus. Antral currettes and a hemostat were used to retrieve the displaced implants (Fig. 4). The sinuses were then irrigated and packed with iodoform gauze, which was later removed. The incision was closed. Postoperatively, the patient did well and no complications were reported.

Conclusions

As described in this case report, the clinical management associated with the removal of dental implants displaced into the maxillary sinuses is considered very invasive.

While numerous dental reports described patients treated for displaced implants into the maxillary sinuses, none illustrated those from a preventive standpoint, that is, the use of CBCT-based dental imaging before placing dental implants.

While the quantitative relationship between successful outcomes in dental implant treatment and CBCT-

based dental imaging is unknown and awaits discovery through large prospective clinical trials, the authors strongly believe that using CBCT-based dental imaging is becoming a reliable procedure from a precautionary standpoint based on a series of recent preliminary clinical studies and case reports.

Therefore, the authors strongly believe that by making a CBCT-based study prior to placing dental implants, displacement of dental implants into the maxillary sinus can be avoided. DT

(A complete list of references is available from the publisher.)

About the authors

Dov M. Almog, DMD, Chief of the Dental Service, VA New Jersey Health Care System (VANJHCS)

Kenneth Cheng, DDS, Oral and Maxillofacial Surgeon, VANJHCS

Mohammad Rabah, DMD, Oral and Maxillofacial Surgery Resident, VANJHCS

For reprints:

Dov M. Almog
Chief, Dental Service (160)
VA New Jersey Health Care System
385 Tremont Avenue
East Orange, N.J. 07018
Tel.: (973)-676-1000, ext. 1234
Fax: (973) 395-7019
E-mail: Dov.Almog@va.gov

UPCOMING WEBINARS

DT Study Club
ADAC-E-R-P
DENTAL TRIBUNE AMERICA IS AN ADA CERP RECOGNIZED PROVIDER

29 JULY
World Class Obturation for General Dentists
Dr. David Clark
Wednesday, July 29, 2009, 7-8:30 p.m. EST
The implant era has raised the bar for endodontics as new tools and techniques allow for the next level of endodontic excellence. But can endodontics be minimally invasive? Biomimetic? Last as long as implants?
En 1h 95 CE USD
REGISTER ON WWW.DTSTUDYCLUB.COM

06 AUG
YouTube ... The Video Granddaddy of Social Media (Part 6 of 6)
Mary Kay Miller
Thursday, August 6, 2009, 7-8:30 p.m. EST
YouTube is the No. 1 video networking site on the Internet today. Learn the dos and don'ts when using YouTube to promote your practice.
Pm 1h 95 CE USD
REGISTER ON WWW.DTSTUDYCLUB.COM

08 AUG
DTSC Online Masters, featuring the Roots Summit and the Implants Summit
Various speakers
Saturday, Aug. 8, 2009, 10 a.m.-5:30 p.m. EST
A full day of Webinars covering various topics in endodontics and implantology, taught by opinion leaders in the industry.
En 1m 7h FREE
REGISTER ON WWW.DTSTUDYCLUB.COM

15 AUG
Ortho Tribune Study Club Launch - Online C.E. Festival
Various speakers
Saturday, Aug. 15, 2009, 10 a.m.-5:30 p.m. EST
The DTSC will be launched with a full day of successive Webinars covering various topics in orthodontics taught by opinion leaders in the industry.
Or 7h FREE
REGISTER ON WWW.DTSTUDYCLUB.COM

29 AUG
Getting Started in Digital Imaging
Various speakers
Saturday, Aug. 29, 2009, 10 a.m.-5:30 p.m. EST
Through a succession of focused Webinars, leading specialists provide a general overview. Each lecture will provide an introduction to the techniques, products and practice management impact in digital imagery.
Gd 7h FREE
REGISTER ON WWW.DTSTUDYCLUB.COM

05 SEPT
Getting Started in Lasers
Various speakers
Saturday, Sept. 5, 2009, 10 a.m.-5:30 p.m. EST
Through a succession of focused Webinars, leading specialists provide a general overview. Each lecture will provide an introduction to the techniques, products and practice management impact in laser dentistry.
Gd 7h FREE
REGISTER ON WWW.DTSTUDYCLUB.COM

BECOME A FREE MEMBER
WWW.DTSTUDYCLUB.COM

Dental Collab BETA
FINALLY A SOLUTION FOR MENTORING WITH EXPERTS & PEERS.
WWW.DENTALCOLLAB.COM
FIRST MONTH FREE
CODE: DTDC09
IT'S NEW



**FINANCIAL PLANNING IS NOT JUST
“INVESTMENT PLANNING”.**

RG CAPITAL
INVESTMENT ADVISORY SERVICES

*“In today’s volatile
stock market environment...
dentists are looking for
predictability.”*

Robert S. Graham, RFC, CFM
Certified Financial Manager
President/CEO

*RG Wealth Management Advisors review your practice and
practice tax strategies searching for opportunities... so you
will have the potential to invest more.*

RG CAPITAL

INVESTMENT ADVISORY SERVICES

**RG CAPITAL TAKES A SMARTPLAN
APPROACH TO WEALTH MANAGEMENT.**

- **SMART GROWTH**
- **COST EFFICIENT INVESTING**
- **TAX AVOIDANCE STRATEGIES**
- **INVESTING IN TURBULENT TIMES**
- **DEFINING YOUR VISION AND GOALS**
- **CUSTOM RETIREMENT PLAN DESIGN**
- **FINDING CLARITY FOR YOUR FINANCIAL FUTURE**

1-800-274-4599

rgcapital.net
info@rgcapital.net

RG CAPITAL
INVESTMENT ADVISORY SERVICES

PH 480 612 6400
FAX 480 612 6401

4800 N. Scottsdale Rd.

Suite 2400

Scottsdale, AZ 85251

Registered Principal offering securities through AIG Financial Advisors, Inc. member FINRA/SIPC and a registered broker-dealer not affiliated with RG Capital. Advisory Services offered through RG Capital Investment Advisory Services.

Five of the top 10 reasons why associateships fail

By Eugene W. Heller, DDS

The “American Dream” is still to own a home. The “Dentist’s Dream” continues to be the ownership of a practice. Thirty years ago, the dream was to graduate from dental school, buy equipment, hang out a shingle and start practicing. Today the road to ownership is a little different.

Due to extensive debt, most new graduates enter practice as associates to improve their clinical skills, increase their speed and proficiency and learn more about the business aspects of dentistry.

Most hope the newfound associateship will lead to an eventual ownership position. Instead, many find themselves building up the value of their host dentist’s practice, only to be forced to leave. This forced departure is the result of a non-compete agreement when the promised buy-in/buy-out doesn’t occur.

The following reveal the first five of the top 10 reasons many associateships fail to result in ownership or partnership.

Reason No. 1: purchase price

If the purchase price has not been determined before the commencement of employment, the parties find themselves on different ends of the spectrum as to what the practice is worth and what the buy-in price should be.

When purchase price is established before the commencement of employment, three out of four

associateships lead to the intended equity position.

Conversely, if the purchase price has not been determined, nine out of 10 associateships lead to termination without achieving the ownership intended or promised.

Reason No. 2: the details

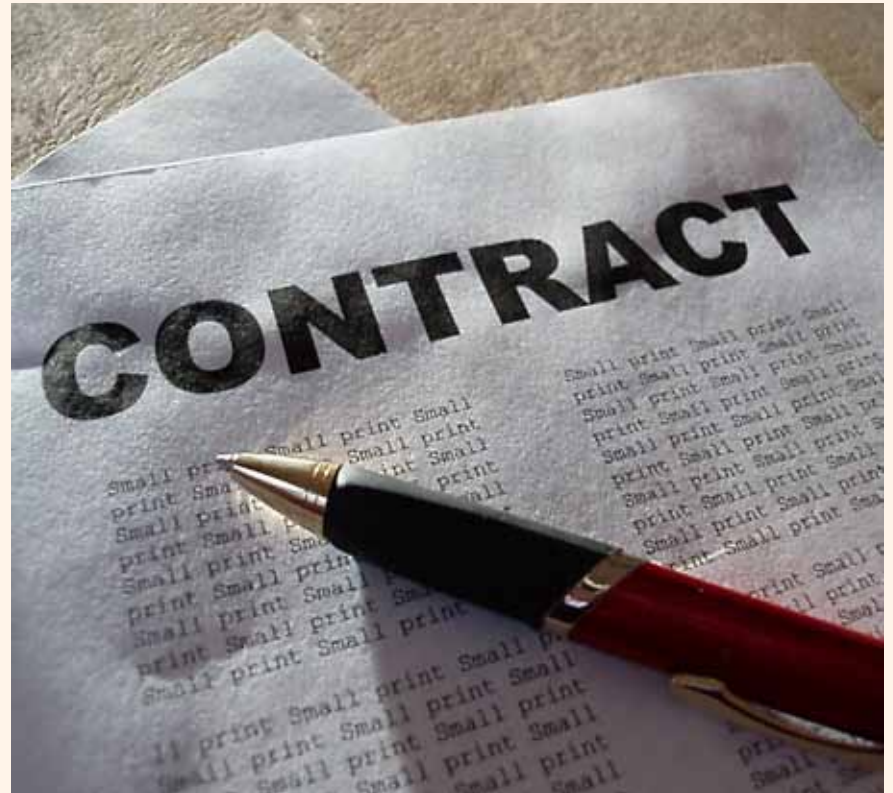The more items discussed and agreed to in writing beforehand, the better the chance of a successful equity ownership occurring as planned.

The written instruments should be two specific documents — an Employment Agreement detailing the responsibilities of each party for employment, and a Letter of Intent detailing the proposed equity acquisition.

Reason No. 3: insufficient patient base

Approximately 1,000–1,200 active patients are required per dentist in a dental practice. If the senior dentist does not intend to restrict or cut back his/her number of available clinical treatment hours, then the conversion from a one-dentist to a two-dentist practice requires an active patient base of approximately 1,400–1,800 patients and a new patient flow of 25 or more new patients per month.

Many senior dentists count their number of active patients by counting the number of patient charts on a wall. However, the best way to estimate the active number



Most hope the newfound associateship will lead to an eventual ownership position. Instead, many find themselves building up the value of their host dentist’s practice, only to be forced to leave.

of patients involves utilizing the hygiene recall count.

Insufficient numbers of patients and/or an insufficient new patient flow signals that all expenses relating to the new dentist are coming directly out of the bottom line. The practice then begins to experience financial pressure.

Creation and maintenance of a sufficient patient base is an

extremely important aspect of the business. If the senior dentist is nearing retirement with the intent that, within one to two years, the senior dentist will turn over total ownership of the practice and intends to cut back shortly after the beginning of the second dentist’s employment, this problem is

→ [DT](#) page 8A

AD



FIRST MONTH FREE
CODE: DTDC09

CREATE, SHARE &
COLLABORATE.

Connect your treatment workspaces with dental professionals that you invite to join your private network from around the globe.

www.DentalCollab.com

FINALLY, A SOLUTION
CONNECTING DENTAL
PROFESSIONALS:

- ▶ 1-on-1 Mentoring **WITH** Experts & Peers
- ▶ GP’s Collaborate **WITH** Specialists
- ▶ Specialists Coordinate **WITH** Referrals
- ▶ On-line Consultation **WITH** Patients
- ▶ Share Cases **WITH** Labs & Suppliers



DENTAL TRIBUNE

WEB APPLICATION HIGHLY RECOMMENDED BY
DENTALTRIBUNE.COM AND DTSTUDYCLUB.COM




SECURE, CLOUD HOSTING
AMAZON WEB SERVICES PLATFORM

POWERED AND MANAGED BY
MODULUS MEDIA INC.



HENRY SCHEIN®

PROFESSIONAL PRACTICE TRANSITIONS

When It's Time to Buy, Sell, or Merge Your Practice

You Need A Partner On Your Side

ALABAMA

Birmingham- 4 Ops, 2 Hygiene Rms, GR \$675K #10108
Birmingham Suburb- 3 Ops, 3 Hygiene Rooms #10106
CONTACT: Dr. Jim Cole @ 404-513-1573

ARIZONA

Shaw Low- 2 Ops, 2 Hygiene Rms, GR in 2007 \$645,995
CONTACT: Tom Kimbel @ 602-516-3219

CALIFORNIA

Alturas- 3 Ops, GR \$551K, 3 1/2 day work week #14279
Bakersfield- 7 Ops, 2,200 sq ft, GR \$1,916,000 #14290
Central Valley- 4 Ops, 2,000 sq ft, 2007 GR \$500K #14266
Dixon- 4 Ops - 2 Equipped, 1,100 sq ft, GR \$132K #14265
Fresno- 5 Ops, 1,500 sq ft, GR \$1,445,181 #14250
Fresno- In professional park. Take over lease. #14292
Lindsay/Tulare- 2 practices, Combined GR \$1.4 Mill #14240
Madera- 1,650 sq ft, 3 Ops, GR \$449K #14269
Madera- 7 Ops, GR \$1,921,467 #14283
Modesto- 12 Ops, GR \$1,097,000, Same loc for 10 years #14289
Oroville-3 ops 3 days of hygiene 2005 GR \$338K #14178
Porterville- 6 Ops, 2,000 sq ft, GR \$2,289,000 #14291
Red Bluff- 8 ops, GR over \$1Mill, Hygiene 10 days a wk. #14252
Redding- 5 Ops, 1950 sq. ft. #14229
San Francisco - 4 Ops, GR 875K, 1500 sq. ft. #14288
San Marino- 6 Ops, 2,200 sq ft, 2008 GR \$762K #14294
South Lake Tahoe- 3 Ops, 647 sq ft, 2007 GR \$534K #14277
Thousand Oaks- General Prac, New Equip, Digital #14275
CONTACT: Dr. Dennis Hoover @ 800-519-3458

Grass Valley- 3 Ops, 1,500 sq ft, GR \$714K #14272
Redding- 5 Ops, 2,200 sq ft, GR \$1 Million #14293
Santa Rosa- Patient records sale - Appox 245 patients. #14286
Yuba City- 5 ops, 4 days hyg, 1,800 sq ft, GR \$500K #14273
CONTACT: Dr. Thomas Wagner @ 916-812-3255

Sunnyvale- 3 Ops - Potential for 4th, GR \$271K #14285
CONTACT: Kelly McDonald @ 831-588-6029

CONNECTICUT

East Hartford- 2 Ops, GR \$450K #16109
Fairfield Area- General practice doing \$800K #16106
New Haven- Perio practice-associate to partner #16107
New Haven Area- Associateship general practice #16102
Southburg- 2 Ops, GR \$250K #16111
CONTACT: Dr. Peter Goldberg @ 617-680-2930

FLORIDA

Miami- 5 Ops, Full Lab, GR \$835K #18117
Ocala- Associate buy-in #18113
Pensacola- 4 Ops, GR approx \$550K, large lot #18116
Port Charlotte- General practice for sale #18109
Port Charlotte- 3 Ops, 1 Hygiene Room, GR \$295K #18115
Southern- General practice for sale #18102
CONTACT: Jim Puckett @ 863-287-8300

GEORGIA

Atlanta Area- 2 Ops, 2 Hygiene Rms, GR \$480K #19114
Atlanta Suburb- 3 Ops, 2 Hygiene Rms, GR \$861K #19125
Atlanta Suburb- 2 Ops, 2 Hygiene Rms, GR \$633K #19128
Atlanta Suburb- 3 Ops, 1,270 sq ft, GR \$438,563 #19131
Dublin- Busy Pediatric practice seeking associate #19107
Mabelton- 6 Ops, GR \$460K, Office shared with Ortho #19111
Macon- 3 Ops, 1,625K sq ft, State of the art equipment #19103
Near Atlanta- 2 Ops, 2 Hygiene Rms, GR \$700K #19109
North Atlanta - Spacious Oral Surg. Office, GR 518K #19123
Northeast Atlanta- 4 Ops, GR \$750K #19129
Northern Georgia- 4 Ops, 1 Hygiene, Est. for 43 years #19110
NW Atlanta Suburb- GR \$780K, Upgraded Equip #19113
Savannah (Skidaway Island)- 4 Ops, GR \$500K #19116
Savannah- Group practice seeking associate. #19108
South Georgia- 4 Ops, 1 1/4 acres #19121
South Georgia- 1,800 sq ft, GR 400K #19124
CONTACT: Dr. Jim Cole @ 404-513-1573

IDAHO

Boise- Dr looking to purchase a general dental practice #21102
CONTACT: Dr. Doug Gulbrandsen @ 208-938-8305

ILLINOIS

Chicago-3 Ops, Condo available for purchase #22108
Chicago-3 Op practice for sale #22108

Chicago- 14 Ops, \$2 Mill specility office, On site lab #22121
Chicago- Established Practice Looking for Dentist #22122
1 Hr SW of Chicago- 5 Ops, 2007 GR \$440K, 28 years old #22123
CONTACT: Al Brown @ 800-668-0629

Kane County- 4 Ops, building also available for purchase #22115

Rockford Area-5 ops solid practice. Very good net #22118
CONTACT: Deanna Wright @ 800-730-8883

INDIANA

St. Joseph County- GR \$270K on a 3 1/2 work week. #23108
CONTACT: Deanna Wright @ 800-730-8883

KENTUCKY

Eastern Kentucky-3 Ops, Good Hyg. Program, Growth Potent.#26101
CONTACT: George Lane @ 865-414-1527

MAINE

Auburn- Looking for Assoc.GR \$2 Million #28111
Lewiston- GP Plus real estate, state of the art office #28107
CONTACT: Dr. Peter Goldberg @ 617-680-2930

MARYLAND

Southern- 11 Ops, 3,500 sq ft, GR \$1,840,628 #29101
CONTACT: Sharon Mascetti @ 484-788-4071

MASSACHUSETTS

Boston- 2 Ops, 2 Hygiene, GR \$650K. #30113
Boston- 2 Ops, GR \$252K, Sale \$197K #30122
Lowell- GR \$400K #30106
Middlesex County- 7 Ops, GR Mid \$500K #30120
Somerville- GR \$700K
Sturbridge- 5 Ops, GR \$1,187,926 #30105
Western Massachusetts- 5 Ops, GR \$1 Mill, Sale \$512K #30116
CONTACT: Dr. Peter Goldberg @ 617-680-2930

New Bedford Area- 8 Ops, \$650K #30119
CONTACT: Alex Litvak @ 617-240-2582

MICHIGAN

Suburban Detroit- 2 Ops, 1 Hygiene, GR \$325K #31105
Grand Rapids Kentwood Area- 3 Ops, Building available. #31102
CONTACT: Dr. Jim David @ 586-530-0800

MINNESOTA

Crow Wing County- 4 Ops #32104
Hastings- Nice suburban practice with 3 Ops #32103
Minneapolis- Looking for associate #32105
Rochester Area- Looking for associate #32106
CONTACT: Mike Minor @ 612-961-2132

MISSISSIPPI

Eastern Central Mississippi- 10 Ops, 4,685 sq ft, GR \$1.9 Mill #33101
CONTACT: Deanna Wright @ 800-730-8883

NEVADA

Carson City- 5 Ops, 2 Hygiene, 2,200 sq ft, GR \$1 Mill #37105
CONTACT: Dr. Dennis Hoover @ 800-519-3458

NEW HAMPSHIRE

Rockingham County- 2 Ops, Home/Office #38102
CONTACT: Dr. Thomas Kelleher @ 603-661-7325

NEW JERSEY

Jersey City- 2 Ops, GR \$216K, 2 days a week #39107
CONTACT: Dr. Don Cohen @ 845-460-3034
Marlboro- Associate positions available #39102
CONTACT: Sharon Mascetti @ 484-788-4071

NEW YORK

Bronx- GR \$1 Million, Net over \$500K #41105
Brooklyn- 4 Ops, 2 Hygiene rooms, GR \$1 Million, NR \$600K #41108
Dutchess County- 80% Insurance, GR \$200K #41106
CONTACT: Dr. Don Cohen @ 845-460-3034
Oneonta- 3 Ops, Approx 1200sq ft. #41101
CONTACT: Deanna Wright @ 800-730-8883
Putnam County-6 Ops, GR \$1.7 Million #41102
CONTACT: Dr. Peter Goldberg @ 617-680-2930
Syracuse Area- 6 Ops all computerized, Dentrix and Dexis #41104
CONTACT: Donna Bambrick @ 315-430-0643

Syracuse- 4 Ops, 1,800 sq ft, GR in 2007 over \$700K #41107
CONTACT: Richard Zalkin @ 631-831-6924
New York City - Specialty Practice, 3 Ops, GR \$400K #41109
CONTACT: Marty Hare @ 315-263-1313

NORTH CAROLINA

Charlotte- 7 Ops - 5 Equipped #42142
Foothills- 5 Ops #42122
Foothills- 30 minutes from Mtn. resorts #42117
Near Pinehurst- Dental emerg clinic, 3 Ops, GR in 2007 \$373K #42134
New Hanover Cty- A practice on the coast, Growing Area #42145
Raleigh, Cary, Durham- Doctor looking to purchase #42127
Wake County- 7 Ops, High end office #42123
Wake County- Beautiful Cutting Edge Digital Office #42139
Wake County- 4 Ops #42144
CONTACT: Barbara Hardee Parker @ 919-848-1555

OHIO

Akron- Excellent Opportunity, 2,300 Active Pts, 6 days of Hyg. #44141
Columbus- 4 Ops, FFS practice for sale #44125
Darke County- 35 yrs, 1200 Act. Pts, GR \$330K #44139
Dayton- 10 Ops, Associateship with buy-in option #44121
North Eastern- 2 Yr. Old Facility, State of Art Tech. GR \$830K #44143
North of Dayton- 6 Ops, 15 days of hygiene/wk #44124
South of Dayton- 6 Ops, 4,000 sq ft, GR \$3 Million Plus #44145
Toledo- 2 Ops, GR \$225K, Est in 1988 #44147
CONTACT: John Jonson @ 937-657-0657

Medina- Associate to buy 1/3, rest of practice in future. #44150
CONTACT: Dr. Don Moorhead @ 440-823-8037

PENNSYLVANIA

Beaver County- Ortho practice for sale. #47118
Mon Valley Area- Practice and building for sale #47112
Pittsburgh Area - High-Tech, GR \$425K #47135
Pittsburgh- 4 Ops, GR over \$900K #47114
70 Miles Outside Pittsburgh- 4 Ops, GR \$1 Million #47137
Northeast of Pittsburgh- 3 Ops, Victorian Mansion GR \$1.2+ Mill #47140
Robinson Township Area- GR \$300K #47108
Somerset County- 3 Ops, 2006 GR \$275K+ #47122
Southside & Downtown Pittsburgh- 2 practices for sale. #47110
CONTACT: Dan Slain @ 412-855-0337

Dauphin County- 6 Ops, GR over \$1,100K, Sale price \$718K #47133
Harrisburg- 3 Ops, GR \$383K, Listed at \$230K #47120
Lackawanna County- 4 Ops, 1 Hygiene, GR \$515K #47138
Lancaster County- Associate positions available #47116
West Chester- 3 Ops, 10 years old, asking \$225K. #47134
CONTACT: Sharon Mascetti @ 484-788-4071

RHODE ISLAND

Southern Rhode Island- 4 Ops, GR \$750K, Sale \$456K #48102
CONTACT: Dr. Peter Goldberg @ 617-680-2930

SOUTH CAROLINA

Charleston Area- 8 Ops fully equipped #49101
Columbia- 7 Ops, 2200 sq ft, GR \$678K #49102
CONTACT: Dr. Jim Cole @ 404-513-1573

TENNESSEE

Chattanooga- For sale #51106
Elizabethon- GR \$400K #51107
Loudon- GR \$600K #51108
Spring Hill- 4 Ops, Good Hyg. Program, Fast Growing Town #51103
Suburban Knoxville- 5 Ops #51101
CONTACT: George Lane @ 865-414-1527

VIRGINIA

Burgess- General practice #55101
Danville Area- 3 Ops #55105
Newport News- 2 Ops, GR \$804,433, Est 1980 #55109
CONTACT: Bob Anderson @ 804-640-2373

For a complete listing, visit www.henryschein.com/ppt or call 1-800-730-8883

← DT page 6A

not as critical.

Often the senior dentist brings in an associate dentist as the answer to increasing business. A practice with insufficient new patient flow

that experiences the addition of a new practitioner may result in termination of employment for the associate.

Reason No. 4: incompatible skills
The incompatibility in clinical

identify the potential pitfalls at the beginning of the relationship

ADS

skills between practitioners may include the possibility of one practitioner's skill level being below standard, but it may also include different practice philosophies. On the surface, it would appear that having different skill levels and philosophies might be desirable. In reality, the patient base that is available to the younger practitioner may not lend itself to various types of dentistry.

Reason No. 5: timeframe

The failure to identify when the buy-in or buy-out is to occur and when to execute it can result in failure to achieve an ownership status.

The Letter of Intent may have stated that the buy-in was to occur in one to two years, but certain behaviors and signs during the continuing employment relationship might give an indication that the senior doctor is having difficulty honoring the intended buy-out or that the associate does not feel ready to consummate the transaction within the original timeframe outlined.

Either position might result in the demise of the buy-in as involved parties lose patience over such delays.

Summary

This article has been aimed primarily at a one-dentist practice evolving to a two-dentist practice; however, the issues apply equally to larger group practices.

One-to-two-year associateships with the senior dentist retiring at the end of the associateship and a three-to-five-year partnership ending with the new dentist purchasing the remaining equity position of the senior dentist at the end of five years can also benefit from the insights provided in this article.

Unfortunately, nothing can guarantee a successful outcome will occur. However, by identifying the potential pitfalls at the beginning of the relationship, chances of success can be greatly improved. DT

Look for the remaining five reasons in the next edition of Dental Tribune.

Six-Year Clinical Study Seals It: EMBRACE™ Sealant 99% Caries Free with Intact Margins after Six Years*

Contains no Bisphenol A

If you're one of the 1,000s of dental professionals who know **EMBRACE™ WetBond Pit & Fissure Sealant** is easier to apply because it bonds to moist tooth surfaces, provides a better seal and is long lasting, you're on top of your profession.

Now after six years of clinical use, **EMBRACE Sealant** sets a new standard of success – intact margins, no leakage, no staining, caries-free.

Six-year followup photo
photo courtesy of Joseph P. O'Donnell, DMD

One call can bring a smile to your face and your patients:

- ✓ Long lasting
- ✓ Easy to apply – only sealant that bonds in a moist field
- ✓ Margin-free seal
- ✓ Fast light cure
- ✓ Fluoride releasing

*Contact Pulpdent for study.

For technical information contact Pulpdent at 800-343-4342


Order through your dental dealer.

PULPDENT® Corporation

80 Oakland Street • Watertown, MA 02471-0780 • USA
pulpdent@pulpdent.com • www.pulpdent.com

About the author

Dr. Eugene W. Heller is a 1976 graduate of the Marquette University School of Dentistry. He has been involved in transition consulting since 1985 and left private practice in 1990 to pursue practice management and practice transition consulting on a full-time basis. He has lectured extensively to both state dental associations and numerous dental schools. Heller is presently the national director of Transition Services for Henry Schein Professional Practice Transitions. For further information, please call (800) 730-8883 or send an e-mail to hsfs@henryschein.com.



CODE NAME: **AMAZING.**

BREAKTHROUGH TECHNOLOGY FOR BREAKTHROUGH PROCEDURES.

COMING SOON.

SDR[™] STRESS
DECREASING
RESIN

TECHNOLOGY

ASK YOUR DENTSPLY CAULK REP OR VISIT WWW.SDRTECHNOLOGY.COM TO SEE WHAT OUR CHEMISTS HAVE BEEN WORKING ON. AND SEE HOW SDR[™] TECHNOLOGY WILL CHANGE THE WAY YOU DO POSTERIOR RESTORATIONS.