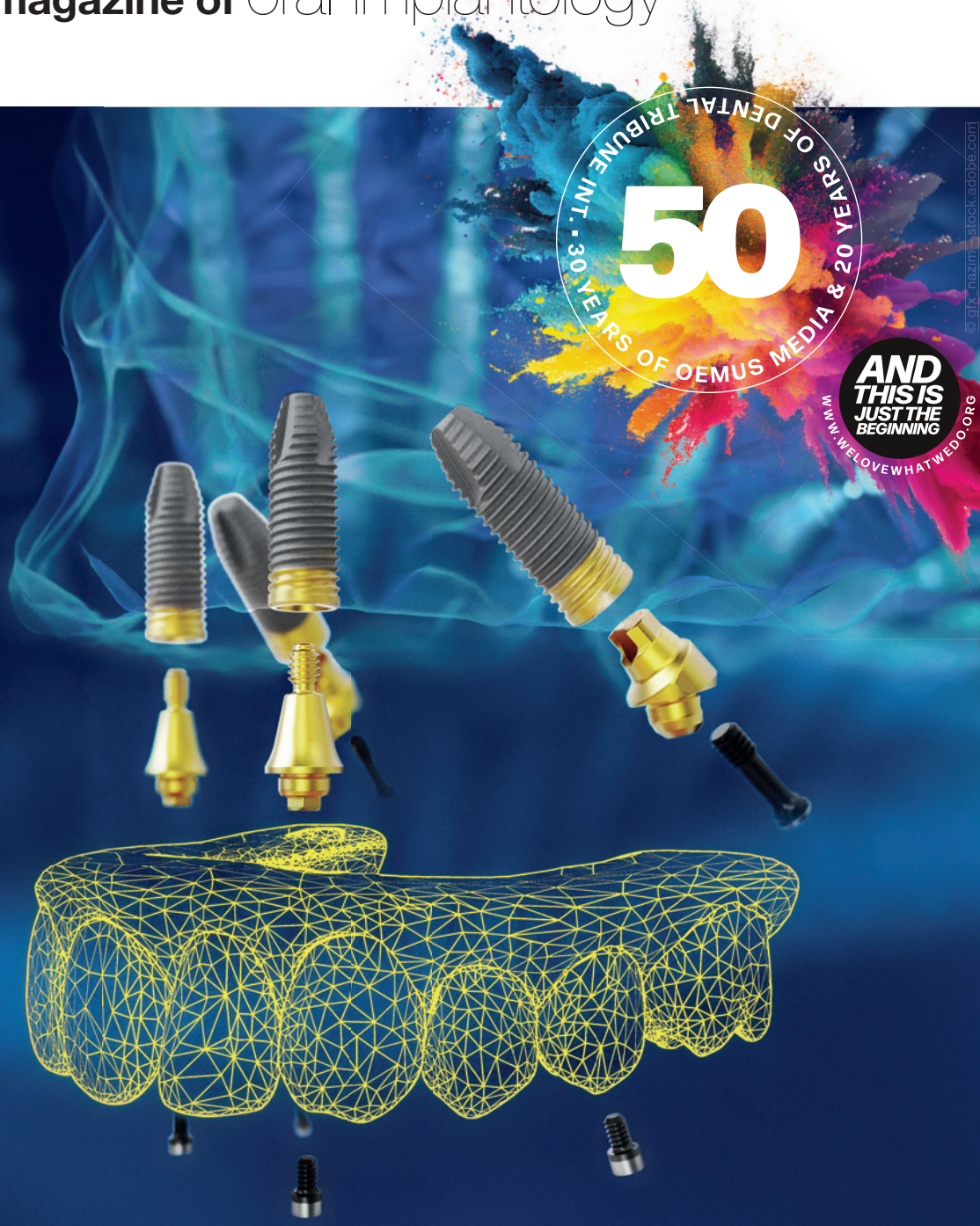

implants

international magazine of oral implantology



research

Laser-assisted protocol for the treatment of peri-implantitis

case report

BLT implants in a periodontal patient with hopeless dentition

interview

Big data in implant dentistry



INTERNATIONAL BLOOD CONCENTRATE DAY

BIOLOGISATION IN
REGENERATIVE DENTISTRY

12-13 SEPTEMBER 2024

RADISSON BLU HOTEL FRANKFURT AM MAIN

REGISTER
NOW!

www.bc-day.info



Dr Georg Bach

President of the DGZI

Before the court and on the high seas...



Dear colleagues!

“Before the court and on the high seas, you are in God’s hands,” goes the oft-quoted adage. A recent verdict by the Berlin Regional Court underscores the profound resonance of this proverb. Despite the assertions of the court-appointed expert to the contrary, the ruling discounted the medical necessity of two-part ceramic implants due to purported lack of evidence. The remarkable aspect lies not merely in the court’s dismissal of expert testimony but in the consequential denial of reimbursement by various insurance companies for procedures involving two-part ceramic implants, citing this ruling.

The ensuing discourse has illuminated a persistent reality: ceramic implants remain a contentious topic in contemporary implantology, even years after their introduction. It falls upon each of us, esteemed colleagues, to discern our stance on ceramic implants, be they one-piece or two-piece, and draw informed conclusions. However, one incontrovertible truth emerges: such a verdict demands a response.

As the representative of the Implantology Consensus Conference, the DGZI (German Association of Dental


Implantology) brought this issue to the forefront during the latest meeting, known internally as the “KK”. The KK issued a succinct yet cogent statement in response. Yet, under the auspices of DGZI’s leadership, a cadre of experts convened to craft a comprehensive analysis and further statement. I urge you to turn to pages 40 and 41 of this edition of *implants* for a detailed exposition. Rest assured, DGZI remains vigilant in monitoring developments on this front and will keep you apprised accordingly.

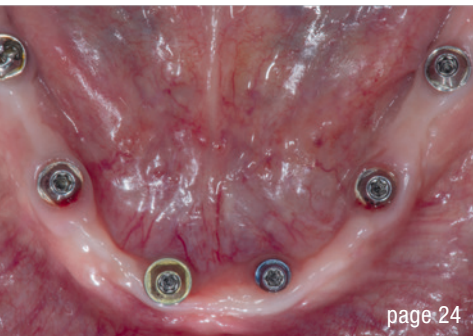
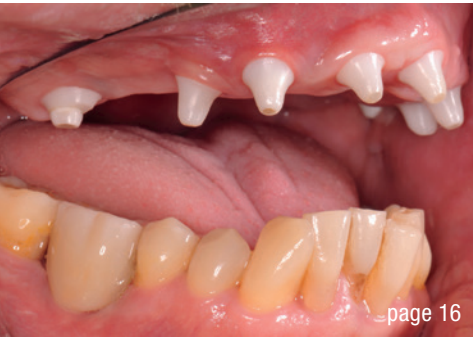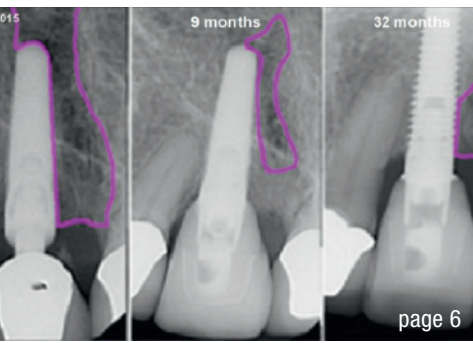
In this vein, I extend my warm regards and encourage you to delve into this issue of *implants* with zeal.

Yours sincerely

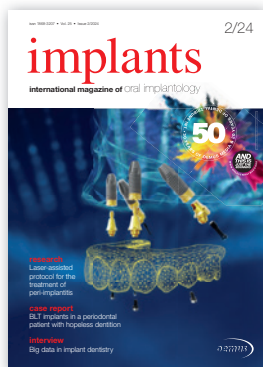Dr Georg Bach

President of the German Association of
Dental Implantology





Cover image courtesy of Nobel Biocare,
www.nobelbiocare.com



editorial

Before the court and on the high seas... 03
Dr Georg Bach

research

Laser-assisted protocol for the treatment of **peri-implantitis**:
A long-term retrospective case series 06
Drs Gary M. Schwartz, David M. Harris & Gregori M. Kurtzman

case report

Full-arch: **Full rehabilitation** of the upper jaw—Part 2 16
Dr Dr Michael Rak, Norbert Wichnalek, Arbnor Saraci & Lukas Wichnalek

Straumann Pro Arch with BLT implants in a **periodontal** patient
with **hopeless** dentition: A five-year follow-up 24
Dr Amin Motamedi

30 years OEMUS MEDIA 31

interview

Big data in implant dentistry 32
An interview with Prof. Arjan Vissink

industry

Commitment to **safety** 34
Insights in **modern dentistry** 36

events

Patient-customised concepts: **“Implantology 4.0”**
in Düsseldorf this November 37

Long-awaited **Digital Dentistry Show** to premiere
in Berlin in June 2024 38

news

manufacturer news 39
Statement on the decision of the Berlin Regional Court regarding
two-piece ceramic implants 40

about the publisher

imprint 42

Visit us at
Booth F55
24 – 26 October
EAO Milan 2024

CONELOG® PROGRESSIVE-LINE conical performance ^[1,2] at bone level

Precise conical connection

- Long conus for reduced micromovements
- Superior positional stability in comparison to other conical systems [1, 2]
- Integrated platform switching supporting the preservation of crestal bone



www.biohorizonscamlog.com/conelog

[1] Semper-Hogg, W, Kraft, S, Stiller, S et al. Analytical and experimental position stability of the abutment in different dental implant systems with a conical implant-abutment connection Clin Oral Invest (2013) 17: 1017.

[2] Semper Hogg W, Zulauf K, Mehrhof J, Nelson K. The influence of torque tightening on the position stability of the abutment in conical implant-abutment connections. Int J Prosthodont 2015;28:538-41.

CONELOG® is a registered trademark of CAMLOG Biotechnologies GmbH. It may however not be registered in all markets.



 **biohorizons
camlog**

Laser-assisted protocol for the treatment of peri-implantitis: A long-term retrospective case series

Drs Gary M. Schwarz, David M. Harris & Gregori M. Kurtzman, USA

Pulsed Nd:YAG dental lasers are surgical tools used to obtain specific surgical objectives as defined in the LANAP (laser-assisted new attachment procedure) for periodontitis and the LAPIP (laser-assisted peri-implantitis procedure) for peri-implantitis. The LANAP using the PerioLase Nd:YAG laser (Millennium Dental Technologies) was introduced in 1998 as Laser ENAP,¹ and in 2004, the LANAP gained US Food and Drug Administration 510(k) clearance (No. K030290) for the claim “laser-assisted new attachment procedure (cementum-mediated periodontal ligament new attachment to the root surface in the absence of long junctional epithelium)”. Subsequently, human histology studies^{2,3} established that the LANAP resulted in “periodontal regeneration—true regeneration of the attachment apparatus (new cementum, new periodontal ligament, and new alveolar bone) on a previously diseased root surface” (2016 510[k] clearance No. K151763).

The LAPIP emerged from the LANAP as a stand-alone procedure.⁴⁻⁷ The indication for the LANAP is moderate to advanced periodontitis, whereas the LAPIP is indicated for peri-implantitis treatment. The basic steps in the two protocols are the same and have adjustments for the whole mouth versus a single site, the responses to irradiation of root cementum versus implant titanium, and differences in surgical objectives.

A recent review of published studies of peri-implantitis laser treatment concluded that laser treatment enhances bone growth, but a quantitative analysis of bone-level changes is limited.⁹ The authors called for greater relevance and translation of the research findings to the clinician. This report addresses those concerns with a detailed analysis

of the clinical outcomes and a quantitative description of changes in radiographic density two to five years after undergoing a LAPIP in a private practice setting.

Dr Schwarz completed training in the LAPIP in September 2013. A retrospective analysis of the 222 sequential patients with 437 failing dental implants that were treated during the following three years was performed.⁷ That study was focused on the short-term efficacy of the LAPIP. A statistically significant reduction of clinical signs of erythema, bleeding and suppuration and reduced probing depth (PD) at the first follow-up visit (median period: 7.6 months; $P < 0.001$) was noted. The survival rate, the percentage of intact implants, was 94% over the longest follow-up period (median: 13.1 months) among those in the analysis.

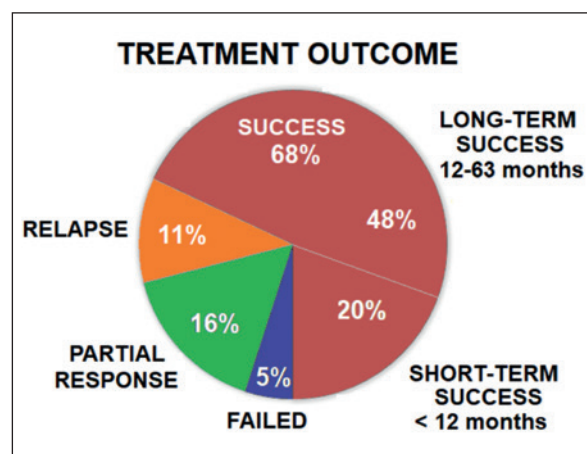


Fig. 1: Proportion of dental implants in each clinical treatment outcome category.

i Periodontitis: “Inflammation of the periodontal tissues resulting in clinical attachment loss, alveolar bone loss, and periodontal pocketing.”⁸

ii Peri-implantitis: “An inflammatory process around an implant which includes both soft-tissue inflammation and loss of supporting bone.”⁸ Clinical signs include inflammation, bleeding on probing and suppuration. It progresses from peri-implant mucositis, which is confined to the soft tissue, to include PD > 4 mm and evidence of bone loss. Peri-implantitis often leads to progressive loss of osseointegration and eventual loss of the implant.

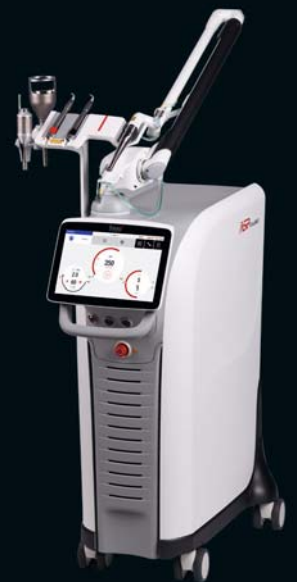Fotona
choose perfection

60
1964
2024
years of innovation

TwinLight® Peri-implantitis Treatment

A simple and effective procedure that offers the power to treat peri-implantitis – an increasing threat to oral health.

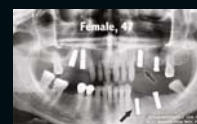
- Minimally-invasive technique
- Fast regeneration/healing
- Reduced inflammatory response
- Highly effective treatment
- No antibiotics needed



LightWalker®

The ultimate all-in-one hard and soft tissue laser

Peri-implantitis treatment video



www.fotona.com

Long-term clinical and radiographic data are presented from the same group of 222 patients. There was a continuum of responses, including long-term successes, partial responses with intact implants and implants lost after two years of maintenance with multiple treatments, as well as cases of successful treatments that relapsed after one to two years. Analysis of radiographic data from a sample of successfully treated implants provided a time course for bone regeneration.

Methods

Collection and analysis were performed of retrospective data, wherein patient records were sorted to find all patients in the practice who had undergone LAPIP treatment within the 37-month interval from the first treatment (October 2013) until the date of institutional review board approval (October 2016). A private institutional review board (Quorum Review) granted a waiver of informed consent and approved the retrospective data collection and analysis protocol. Later, the institutional review board approved the retrospective analysis of the long-term follow-up data that is included in this report. The original study was conducted according to standards established by the Declaration of Helsinki and Good Clinical Laboratory Practice Guidelines. Research standards established in the original study were maintained in the current study.

The purpose of the original study was a precise statistical analysis of the initial clinical outcome of a single treatment, seeking to determine whether there was improvement or a lack of improvement at the first follow-up visit. A review was conducted of patients who received the treatment in the three years after the LAPIP training. All patients were included to eliminate selection bias. A staff member went through the medical records of each LAPIP patient and copied data into case report forms. Any identifying information was excluded, and the case report forms were sent electronically to the statistician for data entry and analysis. Data captured included laser settings, demographics, medical history, implant information, adverse events, PD (mm; for six pockets) and the presence of clinical signs (bleeding, erythema and/or suppuration). Panoramic and/or periapical radiographs were available for analysis. The statistician excluded patients with missing data from the various analyses. The original group included 222 patients with 437 implants. That study enrolment closed in October 2016. Exclusion of patients with incomplete data resulted in 116 patients with 224 implants available for analysis, including 47% men and 53% women with a mean age of 65.8 years (range: 23–98 years).

Two years later (September 2018), a second look at the original group of patients was performed. Several patients had follow-up visits beyond the closing date of the

original analysis. Case report forms of additional follow-up visits were collected, uploaded and added to the original data set. This resulted in 155 patients with 299 implants who had sufficient baseline and follow-up data to determine implant survival and clinical outcomes.

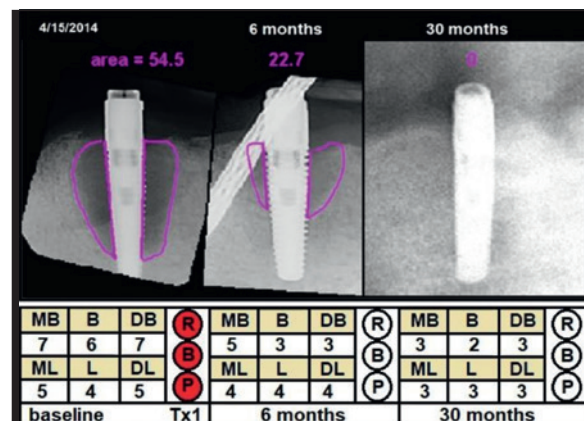


Fig. 2: Example of a successful treatment (Case 1), showing changes in radiographic defect (mm²), probing depth (PD; mm) and clinical signs from baseline to 30 months later. Violet = cross-sectional area; MB = mesiobuccal PD; B = buccal PD; DB = distobuccal PD; ML = mesiolingual PD; L = lingual PD; DL = distolingual PD; R = redness; B = bleeding; P = suppuration; Tx1 = first treatment.

Laser dosimetry

The dental laser was a 6 W pulsed Nd:YAG laser (PerioLase MVP-7, Millennium Dental Technology) utilising an optical fibre that delivered high-energy pulses of light to the tissue. For the LAPIP, the fibre tip is inserted into the periodontal pocket. Parameters that are set on the control panel are energy per pulse up to 300 mJ; pulse duration, variable from 100 to 650 μs; and pulse repetition rate from 10 to 100 Hz. The duration of exposure is controlled with a foot switch.

The LAPIP details have been published elsewhere⁴⁻⁷ and are only summarised as follows for the protocol specifying surgical end points. Achieving those end points is what determines the dosimetry. In Step 2 of the protocol, the distal fibre tip is inserted into the periodontal pocket and passed around the implant several times to initially open the sulcus and then to remove the diseased pocket epithelium and disinfect the tissue, constituting Pass 1 with the laser.¹⁰ In Step 4 of the protocol, the fibre tip is inserted into the pooled blood within the sulcus and again passed around the implant, heating and congealing the blood and forming a fibrin clot, constituting Pass 2 with the laser.¹¹

Hence, real-time dosimetry is based on these clinical conditions. With a constant laser power (output), the time spent lasing within the sulcus determines the total energy delivered. In other words, a prescribed laser dose does



MIS GLOBAL CONFERENCE

September 12-15, 2024 | Palma de Mallorca, Spain

MIS is proud to introduce the Global Conference Speakers Team:



Tara Aghaloo



Juan Arias



Serhat Aslan




Nitzan Bichacho



Darko Božić



Victor Clavijo



Tali Chackartchi



Pablo Galindo



Moshe Goldstein



Gustavo Giordani



Galip Gurel



Hilal Kuday



Stefen Koubi



Alberto Monje



Ariel Raigrodski



Ausra Ramanauskaite



Isabella Rocchietta



Mariano Sanz Alonso



Ignacio Sanz Sanchez



Ventseslav Stankov



Stavros Pelekanos
Live Surgery



Mario Alonso Puig
Guest Speaker

Join us

for 3 days of education, workshops and inspiration alongside the MIS community!