

# laser

international magazine of laser dentistry

2<sup>2011</sup>



| **overview**

The antibacterial effects of lasers in endodontics

| **interview**

New double-wavelength-laser — successful launch at IDS

| **meetings**

XI Congress of SELO

Clean and fully intact  
dentinal tubules after  
laser treatment.

# The universe at your fingertips.



## LightWalker®

**Introducing the highest technology dental laser system**

**Supreme clinical results in:**

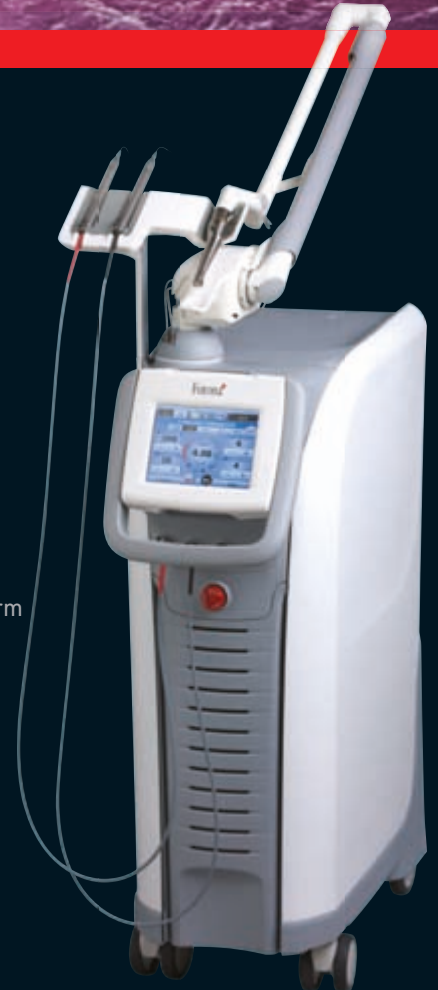- TwinLight™ Perio Treatments (TPT)
- TwinLight™ Endo Treatments (TET)
- No-sutures soft tissue surgery
- Gentle TouchWhite™ bleaching
- Patient-friendly conservative dentistry

**Unmatched simplicity of use:**

- Pre-sets for over 40 applications
- Intuitive user navigation
- Balanced and weightless OPTOflex arm
- Nd:YAG handpiece detection system
- Er:YAG scanner ready

Journey into a new dental experience with speed, precision and great results.  
Visit [www.lightwalkerlaser.com](http://www.lightwalkerlaser.com) today!

**Fotona**  
choose perfection



# IDS approves use of laser in dentistry



Prof Dr Norbert Gutknecht  
WFLD President  
Editor-in-Chief

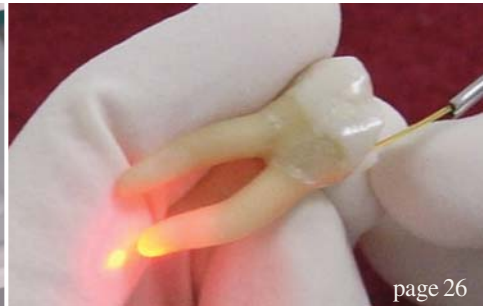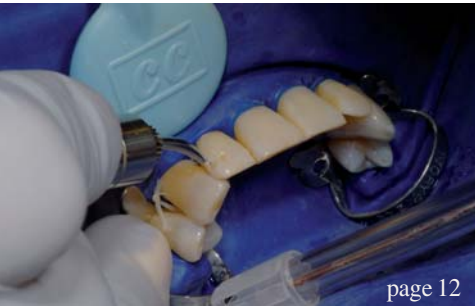\_The IDS—International Dental Show—in Cologne showed once again the further dissemination and awareness of laser therapy in dentistry. A significant higher number of distributors showed their laser devices to the dental world with new innovations and treatment concepts. Seeing this I am even more sure that laser therapy will play an improving role in the wide field of modern dental therapy.

The upcoming European Division Congress of the WFLD in Rome promises to be an outstanding congress, especially with the location Rome as a special attraction. If you have not made your decision to participate in this congress it is more than high time now and I am sure you will not regret it!

Hope to see you in Rome!

A handwritten signature in black ink, appearing to read 'Gutknecht', written in a cursive style.

Prof Dr Norbert Gutknecht  
Editor-in-Chief



| editorial

03 IDS approves use of **laser in dentistry**  
| Prof Dr Norbert Gutknecht

| case report

06 Laser-assisted **immediate implantation** at infected site  
| Drs Avi Reyhanian *et al.*

12 **Enamel alterations**  
| Dr Giuseppe Iaria

14 Utilising **laser technology**  
| Dr Patrick J. Broome

18 Treatment of **gingival hyperpigmentation for aesthetic purposes** using the diode laser  
| Drs M. L. V. Prabhuj *et al.*

| clinical technique

20 **Diode-laser-assisted combination therapy** of a lip haemangioma  
| Dr Georg Bach

23 Periodontitis therapy with **3,000 % more power**  
| Dr Darius Moghtader

| overview

26 The antibacterial effects of **lasers in endodontics**  
| Dr Selma Christina Cury Camargo

| industry report

32 TwinLight™ laser-assisted **endodontics**  
| Dr Kresimir Simunovic

36 TouchWhite™ Er:YAG laser-assisted **Tooth Whitening**  
| Jugoslav Jovanovic

| special

40 **Infection control**  
| Dr Frank Yung

| laser

42 **New double-wavelength-laser—successful launch at IDS**  
| An interview with Frederico Pignatelli

44 **The Joint Fellowship Course of Tehran and Aachen Universities**  
| Reza Fekrazad *et al.*

| meetings

45 **International events 2011 & 2012**

46 **XI Congress of SELO**  
| Paloma Montero *et al.*


48 **Biggest IDS ever**

| news

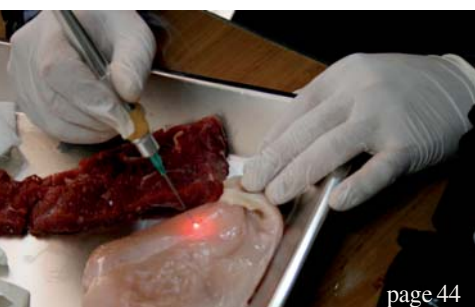49 **Manufacturer News**

| about the publisher

50 | Imprint



Cover image courtesy of A.R.C. Laser GmbH, [www.arclaser.de](http://www.arclaser.de)



*Express  
your mastery*

Join the fast growing success of Syneron Dental Lasers

Presenting

**LITETOUCH™**

The unique fiber-free Er:YAG laser

Dentist's **1<sup>st</sup>** Choice  
for hard and soft tissue procedures



III WFLD-ED European Congress - Sapienza University of Rome - Italy, June 9-11 2011, Booth 13

WWW.SYNERONDENTAL.COM

**Syneron™**  
DENTAL LASERS

# Laser-assisted immediate implantation at infected site

**Authors**\_Drs Avi Reyhanian, Natan Fuhrman, Israel & Costas Ioannou, Cyprus

## Abstract

Osseointegration of dental implants has become a routinely recommended procedure in the clinical practice of dentistry.<sup>1-4</sup> Over the years, patients have begun to demand a shortened treatment time and that treatment be done in one visit, to the extent possible. This clinical case study will discuss and demonstrate the correct use of the Er:YAG laser (2,940 nm) in immediate placement of implants (in one visit) at the infected site: extraction, degranulation, decontamination, placing the implant, and treating the bone defect (guided-bone regeneration—GBR).

This technique using the Er:YAG laser presents several advantages compared with conventional treatment methods, and there are minimal post-operative complications coupled with a high success rate.

### *Introduction of the clinical case*

A 21-year-old soldier presented to the clinic with the chief complaint of mobility of tooth #11. There was no medical history. He had undergone trauma to the tooth a year before, which had been untreated. Clinical examination revealed mobility grade 3+ at tooth #11 with fistula and a change of

**Fig. 1**\_Mobility and fistula of tooth #11.

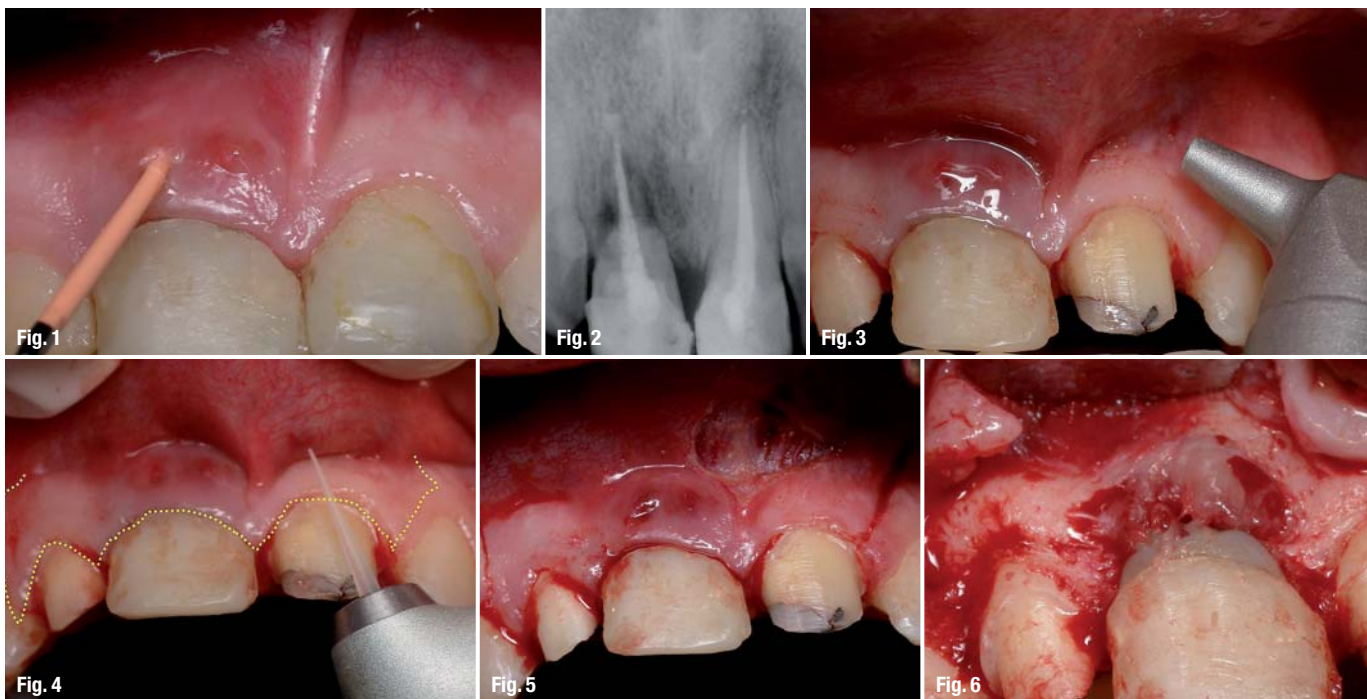
**Fig. 2**\_X-ray image of teeth #11 and 21.

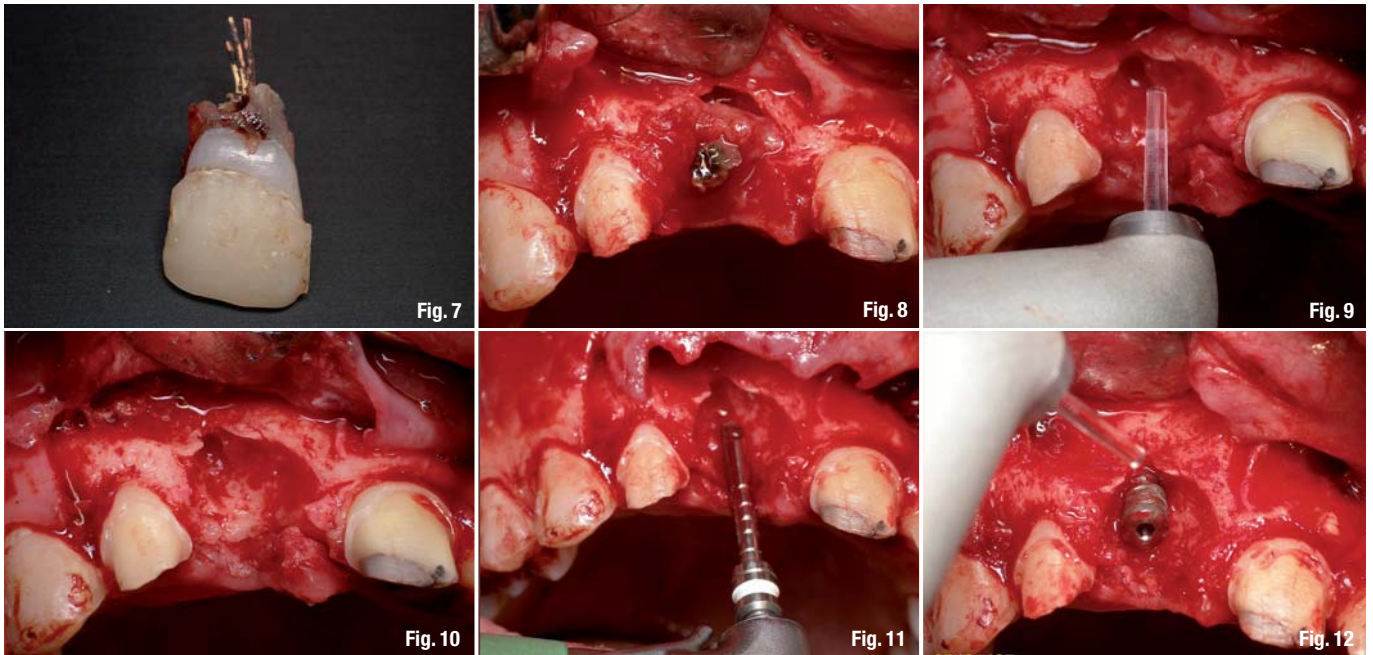
**Fig. 3**\_The CO<sub>2</sub> laser used for the frenectomy.

**Fig. 4**\_The Er:YAG laser used for incision.

**Fig. 5**\_The intrasulcular and vertical incisions and the frenectomy.

**Fig. 6**\_Lifting the flap.





**Fig. 7** \_The extracted tooth.  
**Fig. 8** \_The bone defect.  
**Fig. 9** \_The Er:YAG laser ablates the granulation tissue.  
**Fig. 10** \_The bone defect after ablation and marking the location of the implant with the Er:YAG laser.  
**Fig. 11** \_The pilot hole.  
**Fig. 12** \_Decortication with the Er:YAG laser.

colour of tooth #21. A periodontal probe indicated a depth pocket of 9mm and bleeding on probing. Radiographs revealed horizontal and vertical bone loss due to trauma around teeth #11 and 21 with root canal (Figs. 1 & 2).

Implant indications for laser treatment:

- \_frenectomy using the CO<sub>2</sub> laser;
- \_incision using the Er:YAG laser;
- \_lifting a flap.

Simultaneous (combined) approach:

- \_extraction;
- \_ablation of granulation tissue using the Er:YAG laser;
- \_insertion of immediate implant using the Er:YAG laser—lasing just the cortical bone;
- \_GBR using the Er:YAG laser;
- \_primary closure.

Treatment alternatives:

- \_Using conventional treatment
  - scalpel
  - surgical bur
  - high-speed rotary instruments
  - GBR
  - sutures
- \_Multiple post-operative appointments: staged approach
- \_Placement of the fixture after healing.

*Diagnosis and treatment plan*

Severe periodontitis with massive bone loss around tooth #11 was diagnosed. The treatment plan entailed lifting a flap, extraction of the tooth

and immediate placement of a submerged implant, using a CO<sub>2</sub> laser for the frenectomy, then using an Er:YAG laser for incision, ablation of granulation tissue, bone remodelling and shaping decortication for GBR. Uncovering of the submerged implant with an Er:YAG laser was to be done a year later.

*Rational for treatment*

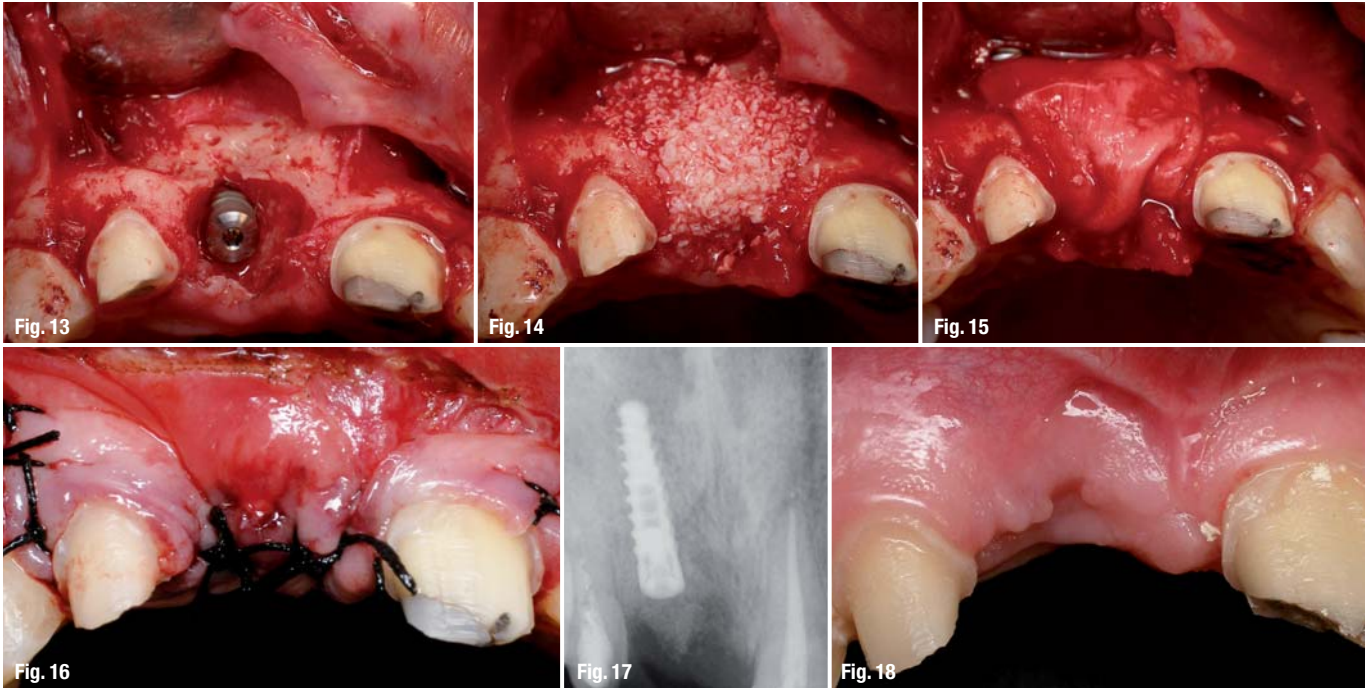
The pulsed Er:YAG laser can cut and ablate tissue with excellent surgical precision without excessive heat or thermal injury. Healing time is shortened when compared with a scalpel or hand instruments. Using a CO<sub>2</sub> laser for a frenectomy results in no bleeding, no pain post-operatively, and a reduced healing time compared with conventional methods.

*Indications/contra-indications and alternative treatment*

There were no contra-indications for use of the laser on this patient. Care must be taken to set proper parameters and use a proper technique, so that both hard and soft tissues are not ablated when only one of the tissues is being targeted. Maximum water spray cooling must be used with the Er:YAG laser to avoid thermal damage.

*Clinical technique, laser wavelength and laser operating parameters*

The lasers selected for the frenectomy were a CO<sub>2</sub> laser (Aqualite, Lumenis Dental; 10,600nm, 6W, SP, non-contact), a free-running, pulsed Er:YAG laser (LiteTouch, Syneron Medical Ltd; 2,940nm, repetition rate of 17–10Hz, 400–700mJ). The tips



**Fig. 13** \_Immediately after decortication.  
**Fig. 14** \_Xenograft using Bio-Oss for GBR.  
**Fig. 15** \_Resorbable membrane.  
**Fig. 16** \_Primary closure.  
**Fig. 17** \_X-ray image immediately post-op.  
**Fig. 18** \_Three months post-op.

used were 200 $\mu$  and 1,300 $\mu$  sapphire tips. The laser selected for uncovering the submerged implant was an Er:YAG laser (LiteTouch) with a 200 $\mu$  sapphire tip and a power setting of 300 mJ/25 Hz.

*Treatment sequence*

Verbal consent was obtained from the patient and his parents after explaining the advantages of laser treatment compared with conventional surgical techniques.

Local anaesthetic was first given to the patient. The frenectomy was then performed with the CO<sub>2</sub> laser set in non-contact mode and to 6 WSP (Fig. 3).<sup>5-7</sup>

Er:YAG lasers can be used to make an incision for flap lifting, such as crestal, intrasulcular or vertical release incisions, and produce a wet incision (some bleeding) as opposed to the dry incision (no bleeding) produced by the CO<sub>2</sub> laser.<sup>8-11</sup>

The Er:YAG laser with a 200 $\mu$  sapphire tip and set in contact mode was used to perform intrasulcular incision and two vertical incisions (Figs. 4 & 5). A full-thickness flap was lifted (Fig. 6) and tooth # 11 was extracted (Fig. 7).

Vaporisation of granulation tissue (if any exists) after lifting a flap can be done efficiently with the Er:YAG laser, with a lower risk of overheating the bone than with the current diode or CO<sub>2</sub> lasers.<sup>11,17,14</sup> There is no need for any hand instruments. Results from both controlled clinical and basic studies have pointed to the high potential of the Er:YAG laser. Its

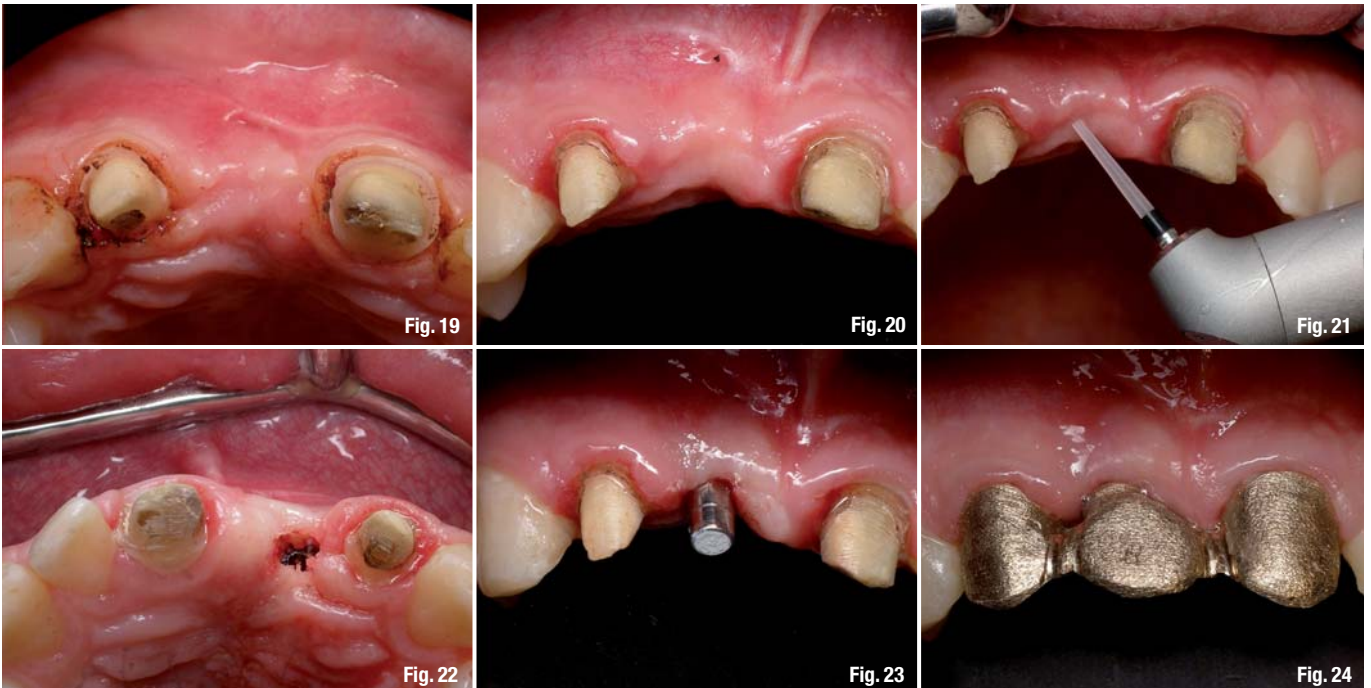excellent ability to ablate soft tissue effectively without producing major thermal side-effects to adjacent tissue has been demonstrated in numerous studies.<sup>12-15</sup>

Granulation tissue was ablated with the Er:YAG laser with a 1,300 $\mu$  tip in non-contact mode and with a power setting of 600 mJ/12 pps (Figs. 8 & 9). Detoxification of the infected site was done by lasing directly on the bone, using a low-energy setting. In this way, the target tissue was disinfected without injuring the bone. The laser is bactericidal.<sup>15,16</sup> The necrotic bone was ablated using the Er:YAG laser with a 1,300 $\mu$  sapphire tip in non-contact mode and with a power setting of 350 mJ/20 pps.<sup>8,10,17,18</sup>

The placement site for the implant was marked with the Er:YAG laser (Fig. 10), and the entire length of the implant was prepared using rotary instruments (Fig. 11). The laser does not replace the pilot drill; it is used to create a pilot hole for the drill. The preparation for the entire length of the implant should not be lased with the laser.

An implant with a length of 13 mm and diameter of 3.75 mm (MIS Implants Technologies Ltd) was placed manually (Fig. 12). The bone defect required GBR. Decortication was performed with the Er:YAG laser with a 1,300 $\mu$  sapphire tip in non-contact mode and with a power setting of 400 mJ/12 pps (Figs. 12 & 13). The bone defect around the implant was filled with Bio-Oss bone substitute (Geistlich Biomaterials) and covered with Bio-Gide (Geistlich Biomaterials), an absorbent, bilayer membrane





(Figs. 14 & 15). Sutures were applied and primary closure was achieved (Fig. 16). An X-ray was taken to confirm the placement of the implants (Fig. 17).

### **Biological rationale for immediate implantation**

- Simplified procedure that reduces the surgical stages;
- conservation of bone volume surrounding natural tooth;
- combination of post-extraction healing phase with osseointegration;
- maximum stimulation of natural healing processes;
- shortened healing phase and rehabilitation time;
- positive psychological effect on the patient.

### **Post-operative assessment**

The patient was prescribed Clindamycin (150 mg x 50 tabs) to avoid infection. He was also given Motrin (800 mg x 15 tabs) for pain. Instructions were given to rinse with a 0.2% chlorhexidine mouthwash, starting the next day for two weeks (three times a day). The patient returned for his first follow-up the next day with a moderate swelling and pain. The flap was closed. At ten days, the patient returned for the stitches to be removed and there were no signs of swelling haematoma or pain. After one month, the soft tissue had healed. A three-month evaluation of the area showed complete healing and no complications (Fig. 18). The soft issue had healed over the bone and there were no bony projections observed under the soft tissue. The prognosis was excellent.

### **Complications**

The patient had no complications related to laser treatment either during or after laser therapy. There was no soft or hard tissue damage.

### **Follow-up and long-term results**

The patient was assessed once a week in the first month, at six weeks, three months and six months after the start of the treatment. At the fifth-month supportive periodontal therapy appointment, the patient had excellent healing and had improved tissue colour, contour and consistency (Fig. 19).

A year post-treatment the submerged implant was uncovered with the Er:YAG laser with an 800µ sapphire tip in non-contact mode and with a power setting of 400 mJ/25 pps (Figs. 20–23). Five months after this, the rehabilitation was completed: three crowns on teeth #12, 11 (eight implants) and 21 (Figs. 24 & 25).

This case was followed-up for three years and two months (Figs. 26 & 27). An X-ray image shows a small absorption of bone around the neck of the implant.

### **Conclusion**

We conclude that using the 2,940 nm wavelength laser for these procedures offers many advantages compared with conventional methods, such as the reduction of patient discomfort, enhancement of the surgical site and reduced treatment time.<sup>21</sup> This

**Fig. 19** Five months post-op, showing complete closure.  
**Fig. 20** A year post-op.  
**Fig. 21** Using the Er:YAG laser to uncover the submerged implant.  
**Fig. 22** The uncovered implant.  
**Fig. 23** The abutment.  
**Fig. 24** The alloy part of the rehabilitation – porcelain-fused-to-gold crowns.