

• implants

the international C.E. magazine of oral implantology

1 2017

_c.e. article

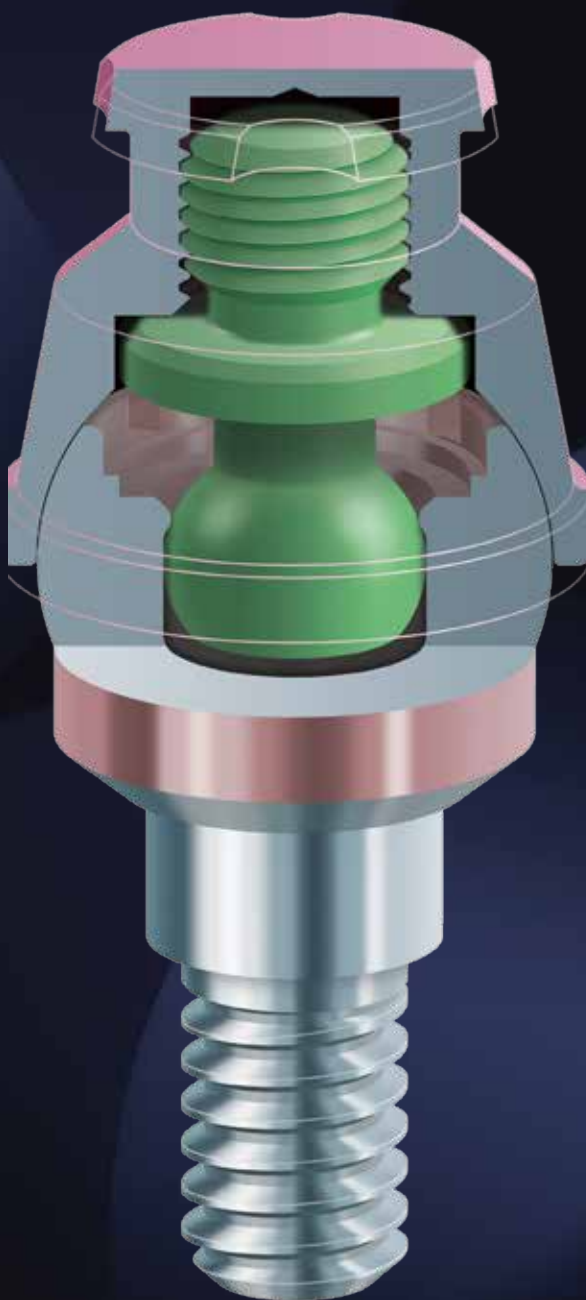
One patient,
one doctor: 30 years
of implant innovation

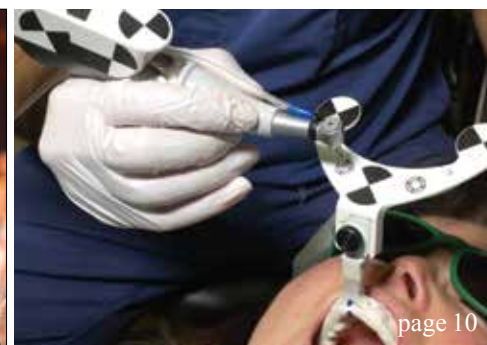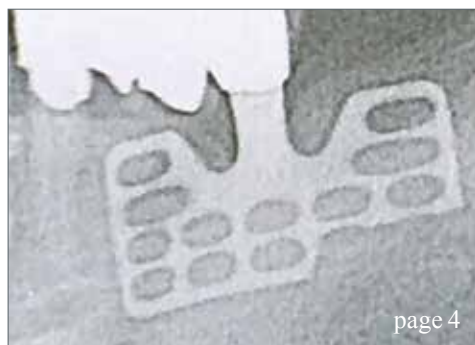
_events

AO keynote to focus
on 'whole person' at
Orlando meeting

_industry

Introducing
LOCATOR
F-Tx





| c.e. article

- 04 **One patient, one doctor:** 30 years of implant innovation
_Jack A. Hahn, DDS

| events

- 9 **AO keynote to focus on 'whole person'** at Orlando meeting
_Jill Helms, DDS, PhD, Professor of Surgery, Stanford Medicine

| case study

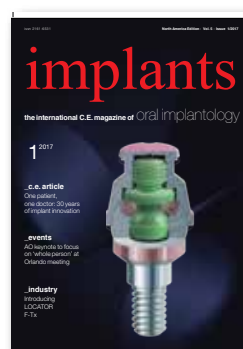- 10 Flapless implant placement with an internal sinus lift using **dynamic guided navigation**
_Naheed Mohamed, DMD

| industry

- 14 Introducing LOCATOR F-Tx: A new way to think about **fixed full-arch restorations**
- 16 Study in JOI finds accuracy of X-Guide navigation is '**11x better than freehand implant placement**'
- 18 **W&H Implantmed SI-1015:** Respects your needs
- 20 Nouvag AG: '**We talk implantology**'

| about the publisher

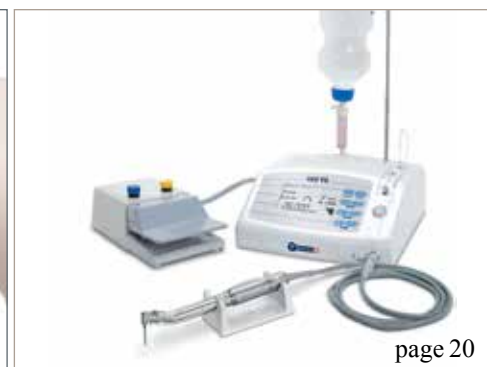
- 22 Imprint




| on the cover

Cover image provided by Zest Dental Solutions. The LOCATOR F-Tx Fixed Attachment System is a simplified, time-saving solution for fixed full-arch restorations.

To learn more about this technology, see page 14.





Dentsply Sirona does not warrant any claim to its trademarks by not using the symbols or ®. 1207111-125X-010 © 2016 Dentsply Sirona. All rights reserved.

Astra Tech Implant System®

Our world is not flat

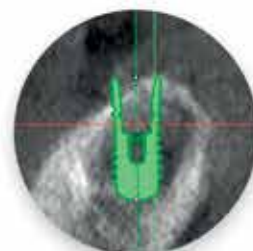
Neither is the anatomy of your implant patients

Your world is already full of clinical challenges so why work harder because of conventional thinking? Instead of augmenting sloped ridges to accommodate flat-top implants, it's time to discover a simpler solution by using an implant that follows the bone. Because sloped-ridge situations call for anatomically designed sloped implants.

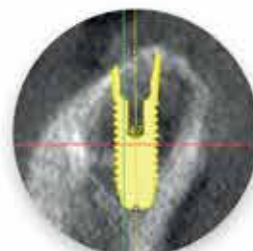
OsseoSpeed® Profile EV – It's time to challenge conventional thinking



www.profiledentalimplants.com



Conventional vs
innovative approach



 **Dentsply
Sirona**
Implants

One patient, one doctor: 30 years of implant innovation

Author _Jack A. Hahn, DDS

_c.e. credit

This article qualifies for C.E. credit. To take the C.E. quiz, log on to www.dtstudyclub.com. Click on 'C.E. articles' and search for this edition (Implants C.E. Magazine — 1/2017). If you are not registered with the site, you will be asked to do so before taking the quiz. You may also access the quiz by using the QR code below.



_Since placing my first dental implant 45 years ago, many implant systems have come and gone, several of which I designed myself. If there's one thing I've learned from the thousands of implant cases I've completed during the course of my career, it's that regardless of the implant system chosen, long-term success depends on following the basic principles of treatment planning, surgery and prosthetic design.

Innovations in implant design have streamlined and simplified treatment, making it easier to produce ideal outcomes. Key advancements, such as the screw-shaped implant body, the internal prosthetic connection and the tapered body design, have been crucial in making implantology the essential mode of tooth replacement it is today.

The following case illustrates more than three decades of implant evolution within the mouth of a single patient. Each implant this patient received throughout the years represents a small but significant step forward, culminating in the placement of the Hahn™ Tapered Implant (Glidewell Direct; Irvine, Calif.), which I designed in order to make treatment simpler, more predictable and as accessible to as many patients as possible.

_The patient

The patient, whom I've been treating for more than 30 years, has received implant therapy several times to treat tooth loss from fracture or decay. Because this treatment occurred episodically through-

Fig. 1 _Dr. Jack A. Hahn and Glidewell Laboratories President and CEO Jim Glidewell display the Hahn Tapered Implant—the culmination of decades of clinical observations and innovation.

(Photos/Provided by
Dr. Jack A. Hahn)



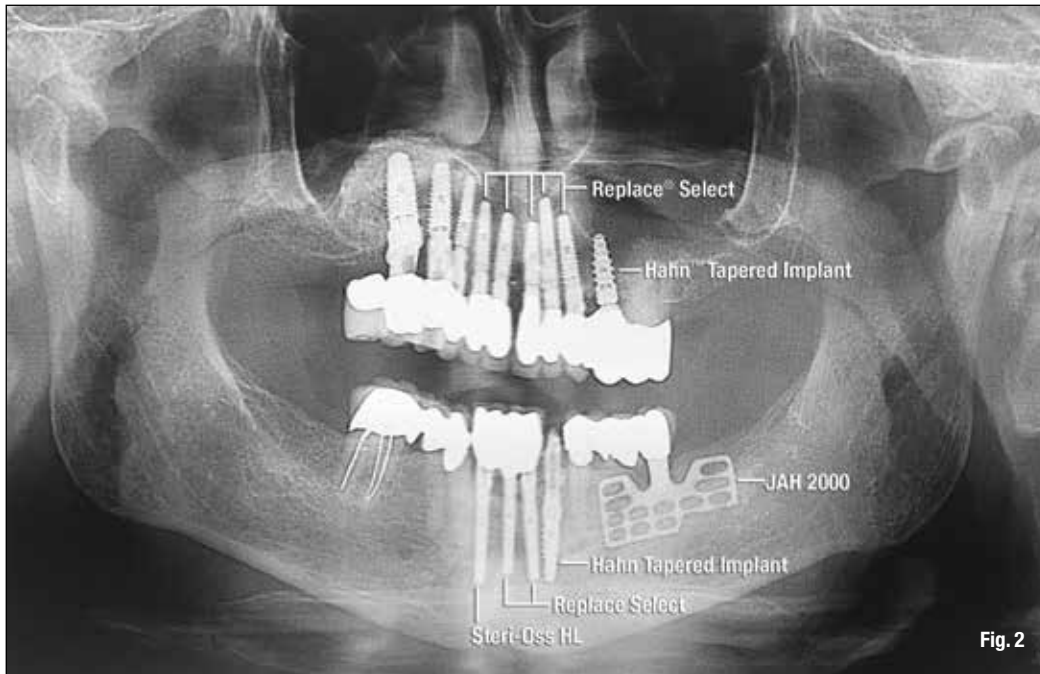


Fig. 2

out many years, I've utilized several different implant systems to replace the patient's teeth. As a result, the patient has implants with internal as well as external hex connections, ranging from an outdated blade-form design to the very latest tapered implant. The experience I've had both designing and placing these implants for this patient and thousands of others has given me the unique opportunity to observe my results and determine what designs and protocols work and what can be improved, as I've strived to advance implant design throughout the years.

The implants

- **JAH 2000 Blade Implant (Fig. 3):** I first placed an implant for this patient in 1988. It was the JAH 2000, which I designed as a flat, two-piece implant with wings. The blade implant was indicated for thin ridges where a root-form implant could not be placed without bone grafting. Blade implants were typically connected to other implants or teeth, and could be cut, shortened and shaped to align with the anatomy of the bone, which was commonly required when placing blade-form implants at the time. For this patient, two teeth anterior to the implant were prepared, an incision was made, a trough was drilled in the patient's very narrow ridge, the implant was placed and a five-unit bridge was delivered to replace three teeth in the posterior mandible. Notice that I adjusted the distal inferior portion of the implant so as not to impinge on the mandibular nerve.

The JAH 2000 was a significant improvement over what was on the market at that time. I designed the neck to extend lower than the tops of the wings, al-

lowing more bone to integrate around the neck of the implant. Decades after implant placement, this blade design continues to serve many of my patients well.

- **Steri-Oss HL (Fig. 4):** The Steri-Oss HL implant in the area of tooth #26 is HA-coated and was placed immediately into an extraction site of a tooth that was lost to severe caries.

Beginning in 1986, my practice was one of multiple centers conducting a 12-year study on nearly 3,000 Steri-Oss implants.¹ We gained provisional ADA approval for extraction with immediate implant placement and loading.

The Steri-Oss HL had a machined collar, which facilitates excellent hard- and soft-tissue preservation. As the clinicians in the 12-year study noted at the two-year follow-up, there was little to no bone loss radiographically around the machined collar. That's why I decided to include a machined collar in my later designs.

- **Replace® Select Tapered (Fig. 5):** I placed several Replace Select implants (Nobel Biocare; Yorba Linda, Calif.) for this patient throughout the years, and the tapered shape simplified positioning within the available bone, especially in the area of the premaxilla. Prior to the Replace Select, most implants were parallel-walled, and in 1993 I came up with the concept of a tapered design, although it didn't come to market until 1997. The idea arose from my experience with single-tooth replacements in the anterior maxilla, where I'd often need to tilt parallel-walled implants to the facial to avoid perforating the subnasal fossa. The roots of natural teeth are tapered, so

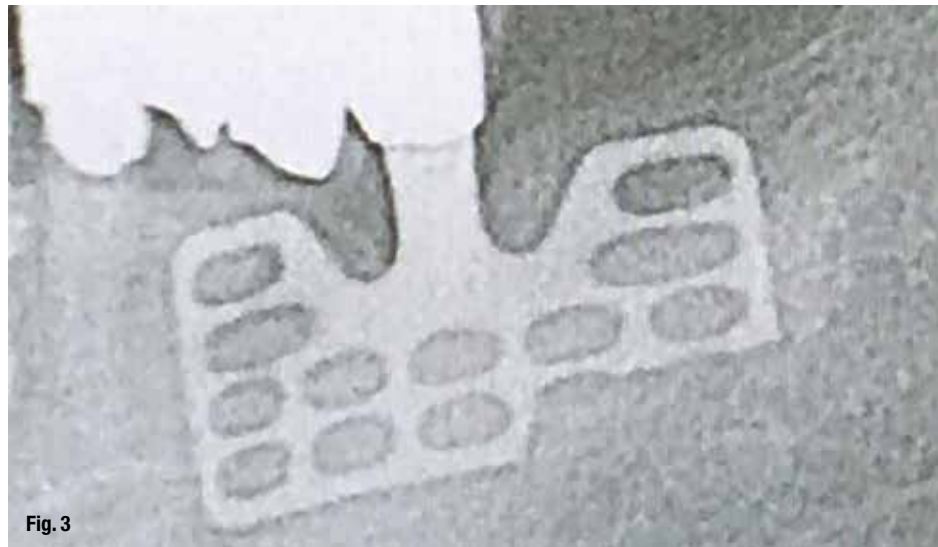


Fig. 3

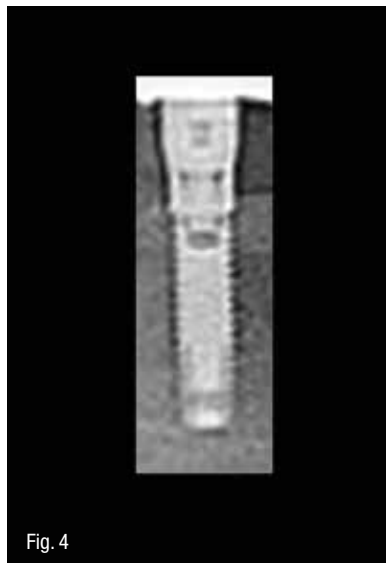


Fig. 4

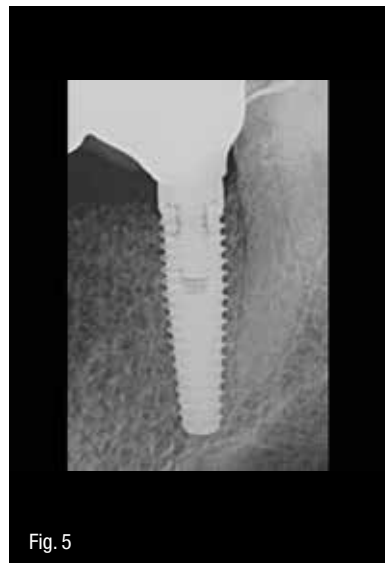

Fig. 5

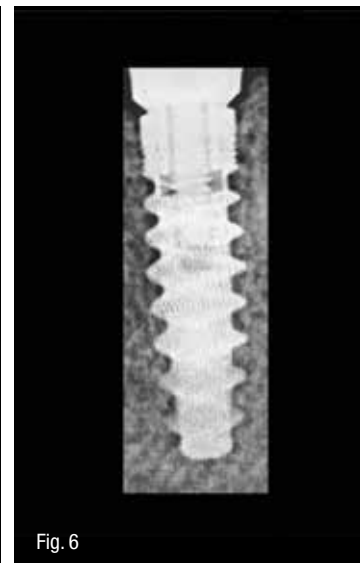


Fig. 6

it occurred to me that implants should be tapered as well. The bone is not square; it's a series of triangles that is best accommodated by a tapered shape.

A flat top with an internal connection offered an esthetic advantage because the implant could be placed at or slightly below the crest of the bone, without an external component causing metal to show through the crown. This led to the design of the tri-lobe internal connection of the Replace Select, which was first introduced by Steri-Oss and became the most popular design in the Nobel Biocare implant portfolio after the company acquired the brand in 1998.

The thread pattern of the Replace Select was similar to that of the parallel-walled Steri-Oss implant, but I wanted to have a variant of aggressiveness in the pitch of the threads as it came up to the apex. I knew that another company was coming out with

four different implants for the different qualities of bone, and I wanted to beat them to the punch. So I said, "Let's put four different thread patterns in one implant," which really helped with the degree of taper and cutting into denser bone.

The tapered shape of the Replace Select was ideal for two-stage treatment, but the thread design wasn't aggressive enough to provide the stability I needed for single-stage surgery. This left me wanting a thread design that was more sharp-edged — but not too aggressive — which was one of the formative ideas behind the Hahn Tapered Implant.

• **Hahn Tapered Implant (Fig. 6):** Like several of the implants I've placed for this patient, the two Hahn Tapered Implants shown in the panoramic radiograph (Fig. 2) were placed immediately following extractions. The patient is active socially and has always wanted an immediate temporary after having



Fig. 7

Fig. 7_ Dr. Hahn in his Cincinnati office holding the patent for the original tapered implant design.

Figs. 8-10_ After recently suffering a fracture, the patient's lower left canine was extracted and replaced with a Hahn Tapered Implant and provisional crown.

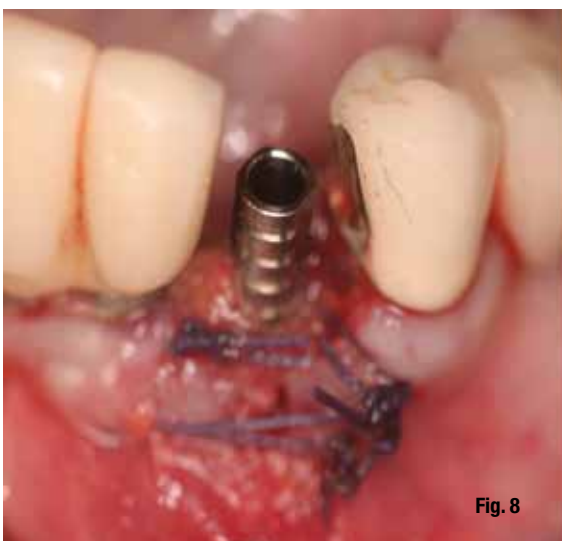


Fig. 8

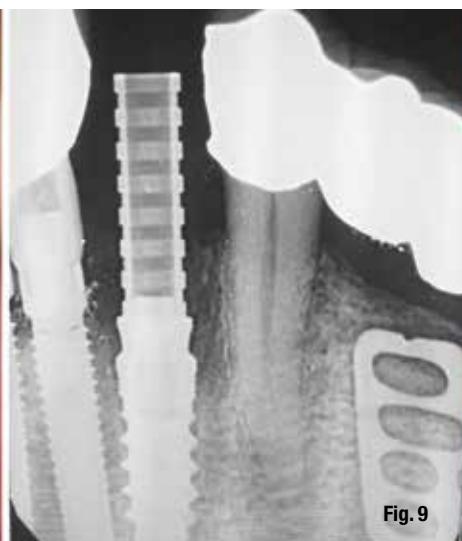


Fig. 9

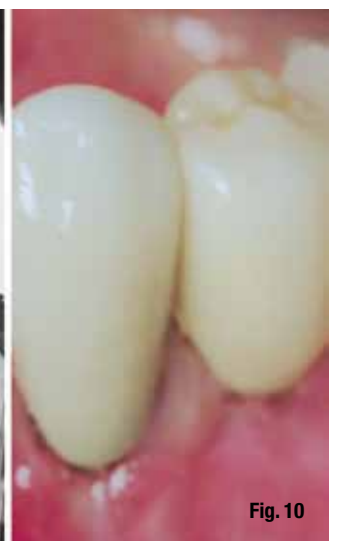

Fig. 10

a tooth extracted. In both cases, I extracted the tooth, prepared the site and placed the implant.

The patient's root-canal-treated mandibular canine needed to be separated from the posterior bridge connected to the patient's JAH 2000 blade implant. Because both of the Hahn Tapered Implants achieved excellent initial stability, immediate provisional crowns were delivered. The patient's other implants have performed well, but required more work to get the outcome I wanted. With the Hahn Tapered Implant, there are fewer steps.

The Hahn Tapered Implant's ability to remain engaged with the palatal bone and attain maximum primary stability is the result of its deep, sharp threads, which I consider the implant's most important design innovation. By the time I began developing the Hahn Tapered Implant, I had concluded that the thread patterns of the previous implant systems I designed weren't aggressive enough. As a result, the implant could wander toward the thin cortical bone of the facial plate during placement. Other implant systems on the market that had a sharper-cutting thread design were too aggressive and could cause microfractures in narrow bone or ridges.

So I designed a new tapered implant, including threads that were just aggressive enough, and brought it to Glidewell Laboratories. The engineers and business leaders at Glidewell, many of whom I've enjoyed working with in past endeavors, were happy to meet with me. I told them, "We need a tapered implant that doctors can easily place, stays right where you want it, and gets maximum primary stability." They looked at my drawings, and their team of engineers helped me fine-tune the design until we got the thread pattern just right.

We ended up with an implant that can be directed against the palatal bone, avoids the facial plate and fits within tight anatomical spaces. The Hahn Tapered Im-

plant includes a 1 mm-machined collar. Because both hard and soft tissue is stable around a machined collar, this design affords doctors the flexibility in crestal positioning they need to meet the esthetic demands of each case. We designed the implant with a conical connection to ensure a strong, stable seal.

The prosthetic connection also facilitates platform switching, which has been shown in numerous studies to preserve bone and gingival tissue around the implant-abutment interface.²⁻⁴ To ensure an optimal restorative outcome, the Hahn Tapered Implant System features contoured healing abutments and matching transfer copings.

Since we launched the Hahn Tapered Implant in 2015 and began working with experienced practitioners, we've received nothing but positive feedback. The comment that I hear repeatedly is: "Jack, I love your implant." Looking back at this patient's radiograph, I know that we've come a long way with implant design.

Conclusion

The various implants I've designed and placed in this patient throughout the years demonstrate that success is highly predictable as long as we adhere to the proper diagnostic, surgical and restorative principles. At the same time, advancements in implant design have simplified surgery and made it easier to establish the implant positioning and stability needed to achieve the best outcome possible. I'm proud to have contributed to this evolution and look forward to the innovations to come.

References available upon request from the publisher.

Editorial note: Reprinted by permission of *Inclusive™* magazine, ©2016, Glidewell Laboratories.

_about the author



Dr. Jack A. Hahn earned his DDS from The Ohio State University College of Dentistry and completed postgraduate coursework at Boston University, New York University, the University of Michigan and the University of Kentucky. A pioneer in the field of implant dentistry, Hahn has been placing and restoring implants for more than 45 years. Hahn developed the Nobel-Replace dental implant system for Nobel Biocare and oversaw the design of the Hahn Tapered Implant. Recipient of the Aaron Gershkoff Lifetime Achievement Award in implant dentistry and the Venue and LEAD magazine Healthcare Leadership Award, Hahn was honored with the Lifetime Achievement Award from the American Academy of Implant Dentistry in June 2015. Hahn is also editor-in-chief and clinical editor of *Inclusive* magazine. He lectures to dentists around the world and maintains a private practice in Cincinnati, Ohio. Contact him at replace7@mac.com.

AO keynote to focus on ‘whole person’ at Orlando meeting

Author Jill Helms, DDS, PhD, Professor of Surgery, Stanford Medicine

Dental clinicians often play instrumental roles in restoring the integrity of a patient's face; they also are in a unique position to help their patients appreciate the internal beauty as well. This is what I plan to address during my keynote presentation, titled "Beauty Reconsidered," at the Academy of Osseointegration's 2017 Annual Meeting.

Neuroscientists tell us that our brains are hard-wired to recognize and respond to beauty. There is a region of the brain where neurons specifically fire when we gaze upon a face. Within months of birth, infants use this brain region to recognize and discriminate among faces and the emotions portrayed by these faces. So, when something disrupts our facial appearance — whether it is caused by disease, deformity or trauma — it

can have a profound impact on how others see us and how we see ourselves. Facial changes affect our sense of well-being.

That's why it is critical for dental clinicians to treat the whole person. You aren't just restoring a part of the patient's anatomy; you are restoring their sense of completeness. There may be surgical limitations to the repair, but as you approach a patient's restorative plan, I urge to you to consider how you can assist them in redefining what is beautiful.

Join me at AO's meeting, taking place March 15-18 in Orlando, Fla. Let's do this together: Let's teach ourselves and our patients that beauty is not determined by a surgical outcome alone. Beauty is defined by authenticity, compassion and perseverance in the face of adversity.



AD

2017 ANNUAL MEETING
March 15-18

Co-Sponsored by:
American Association of Oral & Maxillofacial Surgeons
American Academy of Periodontology
American College of Prosthodontists

For more information, go to osseo.org

SPANISH AND PORTUGUESE TRANSLATION

ACADEMY OF OSSEOINTEGRATION
Good to Great®:
Making Excellence a Clinical Reality
Orange County Convention Center • Orlando, Florida

The 3rd collaborative meeting co-sponsored by:

ASA OMS AAP ACP
2003, 2008

The "GOOD TO GREAT" trademark is owned by The Good to Great Project LLC. Used under license.

Orlando