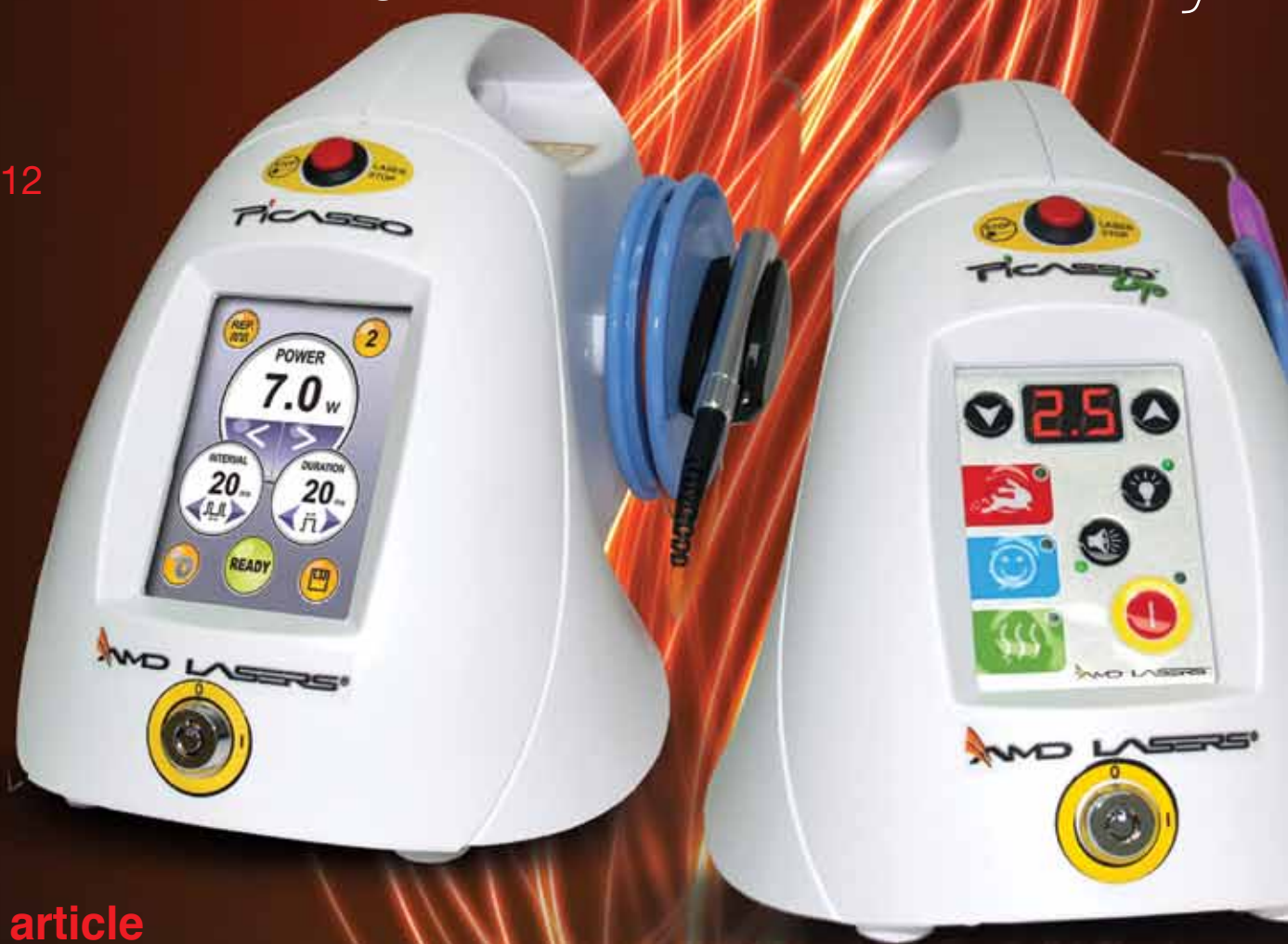

laser

the international c.e. magazine of laser dentistry

3²⁰¹²



C.E. article

Introduction to the LANAP protocol
for the treatment of periodontitis

research

New horizons for Er:YAG lasers

technique

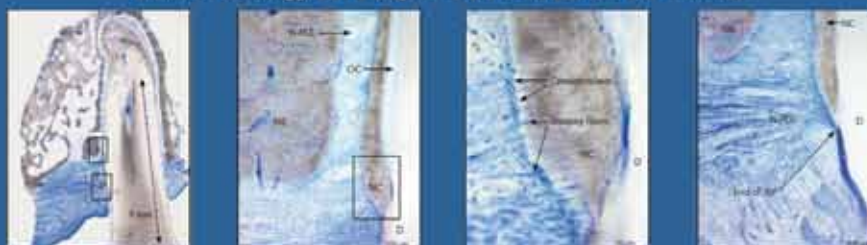
Crown troughing with the 810 nm diode laser

"More" Human Histology supports LANAP

Cementum-mediated periodontal ligament new attachment to the root surface in the absence of long-junctional epithelium.¹

Human histologic
peer-reviewed
published
manuscript #2


Nevins Histology 2012 Sept/Oct IJPRD - LANAP x 9 months



Key: NC = new cementum; NB = new bone; OC = old cementum; d = dentin; JEP = junctional epithelium; N-PDL = new periodontal ligament

Human histologic
peer-reviewed
published
manuscript #1

Yukna Histology 2007 Nov/Dec IJPRD - LANAP x 3 months



Key: N = notch in calculus; B = new bone; C = new cementum; OC = old cementum; JE = junctional epithelium

Periodontal literature rarely has **two Human Histological studies** to review on the same procedure; but whether you look at the histology, the long-term results, or read the FDA clearance - **the clinical results are the same.**

Human Histology Results Support Periodontal Regeneration with the LANAP protocol.^{2,3}

All 12 "hopeless" teeth returned to clinical, radiological, and histologic health.

Cementum-mediated attachment/regeneration achieved with the LANAP protocol is highly competitive with any other studies done on regeneration.⁴

Results you can believe – The LANAP® protocol is no longer a breakthrough periodontitis treatment, it is a paradigm-shifting, well established protocol and standard treatment option with long-term results.⁵

1 FDA 510k clearance K030290 using the PerioLase® MVP-7™

2 Yukna, Carr, Evans, Histologic Evaluation of an Nd:YAG Laser-Assisted New Attachment Procedure in Humans. Int J Periodontics Restorative Dent 2007;27:577-587

3 Nevins, Marc, Camelo, Schupbach, et al., Human Clinical and Histologic Evaluation of Laser-Assisted New Attachment Procedure. Int J Periodontics Restorative Dent 2012;32:497-507

4 Nyman, Lindhe, et al., New attachment following surgical treatment of human periodontal disease. J Clin Perio 1982;9:290-2965

5 Tilt LV, Effectiveness of LANAP as measured by tooth loss. J Gen Dent 2012;60:143-146

See for yourself – Learn why over 15% of practicing AAP clinicians offer the LANAP protocol

- Review the two human histology studies^{2,3}
- Review peer-reviewed long-term tooth survival results⁵
- Review scientific and clinical studies or training session dates at www.lanap.com. (NIH registered study at www.clinicaltrials.gov search "LANAP")

Clinical results guaranteed!

Achieve consistent, reproducible, positive clinical results every time with the award-winning PerioLase® MVP-7™



MILLENNIUM
DENTAL TECHNOLOGIES, INC.



Call today 1.888.49.LASER or visit www.LANAP.com

From LANAP to Elap-p, *laser* has you covered



Torsten Oemus, Publisher
Dental Tribune International

With the development of so many new procedures and techniques, it's sometimes difficult to stay on the cutting edge. That's why the magazine you are holding right now is so valuable.

For this issue of *laser*, we've assembled a valuable collection of articles from some of the most respected names in dentistry. The issue leads off with an introduction to the laser-assisted new attachment procedure for the treatment of periodontitis by none other than Dr. Robert H. Gregg II, who is a pioneer in the field of laser dentistry and one of the inventors of the LANAP procedure itself.

Dr. Glenn A. van As offers an article on crown troughing technique using the 810 nm diode laser. Dr. Darius Moghtader describes the Elap-p I procedure for the treatment of periodontitis. Dr. Evgeniy Mironov offers the results of extensive research on the use of Er:YAG lasers, and Dental Tribune America Group Editor Robin Goodman offers a first-person account of what it was like to be treated for the removal of an uncomfortable fibroma. (Her story has a happy ending.)

In addition, you'll find articles on the treatment of gingival hyperpigmentation for esthetic purposes using the diode laser, and an article on how laser phototherapy can be used to treat Bell's palsy patients.

Remember that every issue of *laser* magazine also contains a C.E. component. By reading the article by Dr Gregg mentioned above, plus the article on infection control by Dr. Frank Yung, then taking a short online quiz about these articles at www.DTStudyClub.com, you will gain one ADACERP-certified C.E. credit. Keep in mind that since *laser* is a quarterly magazine, you can actually chisel four C.E. credits per year out of your already busy life without the lost revenue and time away from your practice.

To learn more about how you can take advantage of this C.E. opportunity, visit www.DTStudyClub.com. Annual subscribers to the magazine (\$50) need only register at the Dental Tribune Study Club website to access these C.E. materials free of charge. Non-subscribers may take the C.E. quiz after registering on the DT Study Club website and paying a nominal fee.

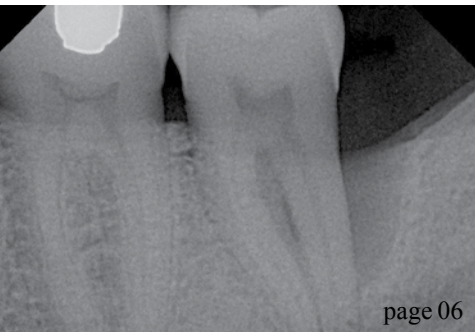
With so much rapidly advancing technology, dentists have the ability to treat patients in new and innovative ways. With *laser*, you have a tool to stay up to date.

As always, if there is a topic you'd like to see covered in this publication, please don't hesitate to let us know by contacting us at feedback@dental-tribune.com.

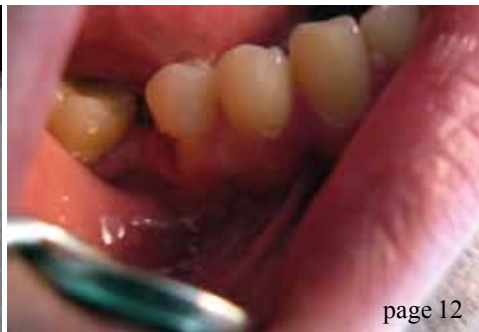We want to hear from you!

Sincerely,

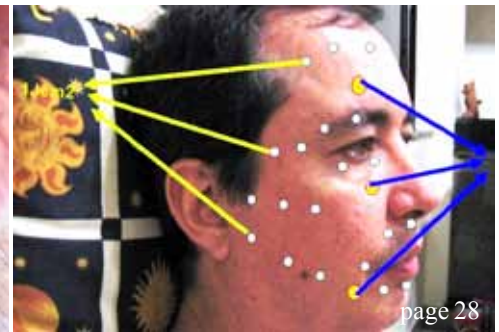
Torsten Oemus
Publisher



page 06



page 12



page 28

C.E. article

- 06 Introduction to the LANAP protocol for the **treatment of periodontitis**
_Robert H. Gregg II, DDS

- 10 **Infection control**
_Frank Yung, DDS

research

- 12 New horizons for **Er:YAG lasers**: QSP mode advantages in the Lightwalker AT
_Evgeniy Mironov, DDS; Assist. Prof. Zhasmina Mironova, DDS; Assoc. Prof. Radosveta Vassileva, DDS and Assoc. Prof. Krassimira Genova

trends

- 20 'Bye-bye **fibroma!**'
_Robin Goodman, Group Editor, Dental Tribune America
- 24 Periodontitis therapy with **3,000 percent more power**
_Darius Moghtader, DDS
- 28 Laser **phototherapy** in Bell's palsy
_Prof. Aparecida Maria Cordeiro Marques, MSci, PhD; Luiz Guilherme Pinheiro Soares, DDS; Cristina Maria do Nascimento, M.Sci; Alberto de Aguiar Pires Valença Neto, DDS; Roberta Cordeiro Marques, Physioterapist (Specialist) and Prof. Antonio Luiz Barbosa Pinheiro, MSci, PhD

case report

- 30 Treatment of **gingival hyperpigmentation for esthetic purposes** using the diode laser
_Prabhujee Munivenkatappa lakshmaiah Venkatesh, MDS; Madhu Preetha, MDS and Archana Vilasan, MDS

technique

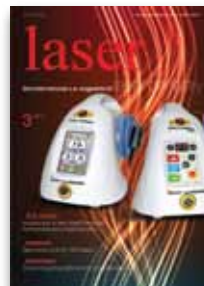- 34 **Crown troughing** with the 810 nm diode laser
_Glenn A. van As, BSc, DMD

industry

- 38 _DC International launches redesigned and advanced soft diode laser: **DCLase 980nm 7 watts**

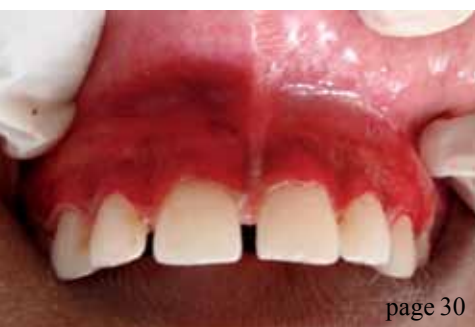about the publisher

- 41 _submissions
42 _imprint

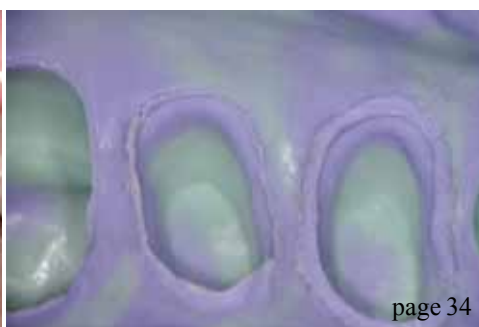

on the cover

Cover image provided by AMD LASERS. Cover background provided by www.portwallpaper.com.



page 30



page 34



page 38

Technology **4** Medicine™

LIGHTWALKER

Dual Wavelength, Er:YAG & Nd:YAG

The Perio, Soft & Hard Tissue Laser

The 2 leading **LASERS**, 1 superior package. Invest Less. **Do More.**



Best of Class

Pride Institute

"red dot" Design Award 2012
Superior Design & Technology



red**dot**



Dentistry Today's
Top 100 Products

ALL tissue laser for treating periodontal disease,
soft & hard tissue procedures

Maximum Versatility with the **ONLY** multi-
wavelength ALL tissue laser

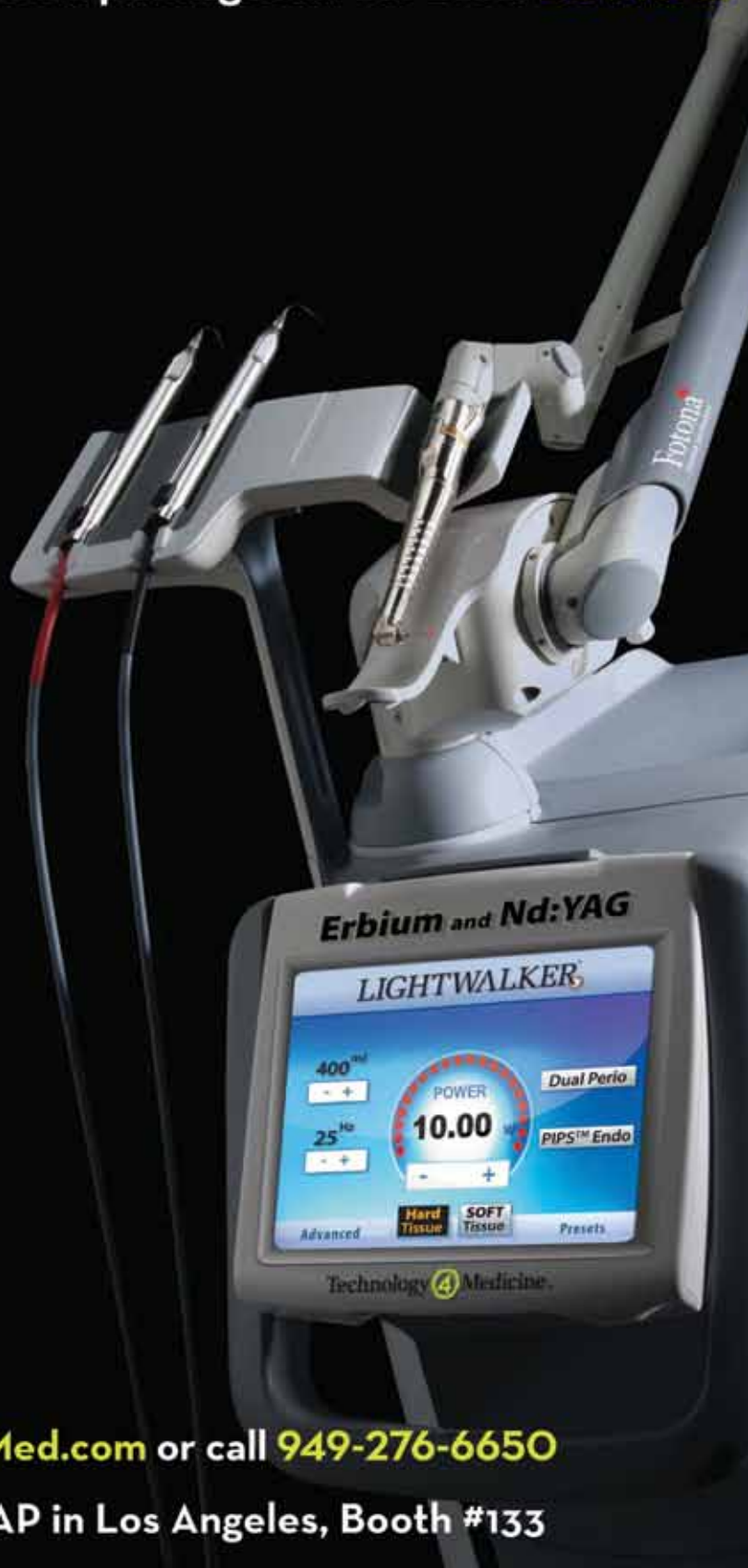Both Nd:YAG (1064nm), the **ONLY** proven wave-
length for periodontal treatment

And Er:YAG (2940nm), the World Class hard tissue
laser for all of your bone procedures

Periodontal disease procedure using both the
Nd:YAG & Er:YAG

Minimally invasive perio treatment only available
with the LightWalker™ dual wavelength laser.

Cost Effective & Excellent Return on Investment



For More Information, visit www.T4Med.com or call **949-276-6650**

Test Drive the Lightwalker at the AAP in Los Angeles, Booth #133

Introduction to the LANAP protocol for the treatment of periodontitis

Author_Robert H. Gregg II, DDS

_c.e. credit part 1

This article qualifies for C.E. credit. To take the C.E. quiz, log on to www.dtstudyclub.com. The quiz will be available Sept. 17.

The breakthrough LANAP* protocol offers many advantages over conventional flap periodontal surgery or scaling and root planing for the treatment of periodontitis. This no-cut, no-sew technique is bringing revolutionary outcomes into the treatment rooms of general dentists and periodontists alike, allowing the profession to battle against a disease that threatens the health of more than 80 percent of Americans. This overview explains what the LANAP procedure is, how it works and what clinical trials are showing about the exciting results this strict protocol can achieve for patients with gingivitis, "garden variety" periodontitis — and even the most extremely severe forms of gum disease.

Most Americans — about 80 percent — suffer with gum disease on some level, according to the U.S. surgeon general. Michael Newman, DDS, PhD, says that only 3 percent of the 100 million-plus Americans with moderate to severe periodontal disease are treated each year, which means an increasing number of worsening cases appear in general dental practices across the country every day.¹ The growing threat requires a greater number of general dentists to take the lead in properly performing a periodontal probing exam. Still, for many offices, the challenge lies in persuading the patient to seek treatment via referral to a periodontist.

A growing number of general practitioners have reached a frustration threshold, seeing one patient after another who either continues with poor gum health or seeks treatment from a periodontist and achieves results that ultimately leave much to be desired. Some of these dentists have discovered a treatment protocol that allows them to take action and provide patients improved care — without even referring them out of the practice. The treatment is achieving unsurpassed results not otherwise attainable with conventional techniques.

Widely known to be closely linked with heart disease and strokes, periodontitis has now been fingered as the cause in a full-term baby's death.² It is believed that the mother's gum disease introduced fatal bacteria to her womb. In an age of burgeoning technology, the news stories linking gum disease to more disastrous results are inevitable. As the dangerous consequences of gum disease become increasingly clear, more dental clinicians must take the reins in educating patients and ensuring their successful treatment.

Dental practitioners have used free-running (FR) pulsed Nd:YAG lasers for longer than 20 years, but only recently has the laser been combined with a specific, successful protocol and research-proven operating parameters to achieve FDA clearance and a track record of success in university-based clinical studies for its efficacy at "cementum-mediated new PDL attachment to the tooth root surface in the absence of long junctional epithelium."^{3,4} The protocol has shown consistent probe depth reduction, histological and clinical new attachment, and radiographic bone growth for periodontally involved teeth with no elevation of the periosteum and minimal patient discomfort.⁵⁻⁷

Its greatest potential may lie in patients' willingness to accept treatment and comply. With 97 percent refusing current protocols, a no-cut, no-sew solution has meant a flock of new patients willing to seek treatment for their gum disease from those dentists who choose to offer the LANAP protocol.

_What is the LANAP protocol?

The procedure combines the PerioLase MVP-7 Free-Running (FR) pulsed Nd:YAG laser with a strict, specific, research-proven protocol that has achieved FDA clearance for the treatment of all forms of gum

disease — from early detection to so-called “hopeless” teeth. The breakthrough is called laser assisted new attachment procedure (LANAP), and it has left a trail of healthy patients in its wake for the inventors of the protocol, Dr. Robert H. Gregg II and Dr. Delwin K. McCarthy, as well as more than 1,000 dentists and specialists who have learned the procedure from the Institute for Advanced Laser Dentistry (IALD).

Gregg and McCarthy pioneered the use of the FR pulsed Nd:YAG laser in treating gum disease in the 1990s. They were astounded by their ability to regenerate bone growth (routine 50 percent defect fill) and stimulate new attachment for their patients with severe gum disease. The results were too good to keep to themselves. The pair continued to fine-tune the procedure after patenting it so they could share it with peers and envision a goal for the new gold standard for the treatment of gum disease across the country.

The LANAP treatment protocol

Designed and refined for 10 years, the LANAP technique's specific clinical steps must be performed properly and in precise order to achieve consistent positive outcomes. The key steps, in order, make up the patented portion of the technique and are the crux of why the LANAP protocol is so successful. The procedure may be performed in all four quadrants in a single appointment, but for patient comfort and case control, laser treatment is typically limited to no more than two non-adjacent quadrants per visit, with several days between visits.

First, the patient is profoundly anesthetized with local anesthetic so that the patient's pocket depths can be probed down to the level of intra-osseous defects (bone sounding). The thin optic fiber is then used parallel to the root surface, to effect the pocket wall. Next, an EMS ultrasonic scaler removes calcified plaque and calculus adherent to the root surface. The first pass with the laser, called laser troughing, is accomplished with the short duration pulse. The FR pulsed Nd:YAG laser is used to achieve optimal reduction of microbiotic pathogens (antiseptis) within the periodontal sulcus and surrounding tissues. Perio pathogens and pathologic proteins are selectively destroyed by the laser's light energy, providing an antiseptic surgical environment that allows healing following the laser hemostasis step.⁸⁻¹⁵

The technique uses selective photothermolysis to remove the diseased, infected and inflamed pocket epithelium while preserving healthy connective tissue, literally separating the tissue layers at the level of the rete pegs and ridges.⁸⁻¹¹ The practitioner is able to achieve both tissue ablation and antiseptic hemostasis with extreme precision by varying the laser's energy density, pulse duration and rate of repetition. The laser assists in the destruction of perio pathogens

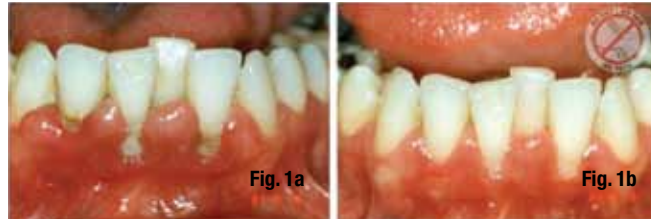


Fig. 1a, 1b_ Before LANAP (1a) and nine days after LANAP (1b). (Photos/ Provided by Robert H. Gregg II, DDS)

while preserving the healthy tissue, allowing for less post-operative discomfort and a much shorter post-surgical recovery perception for the patient.

At this point, a second pass is completed to finish debriding the pocket and achieve hemostasis with a thermal fibrin clot. Gingival tissue is compressed against the root surface as necessary to close the pocket and aid with formation and stabilization of the fibrin clot. No sutures or surgical glue is needed. Mobile teeth above class II mobility are splinted. Occlusal adjustments are performed to remove interferences, minimize trauma, and provide balance to long axis forces and are considered an essential component of the LANAP protocol.

Finally, post-operative instructions specific to the LANAP protocol, diet guidelines and oral hygiene instructions are explained and their importance is stressed, and continued periodontal maintenance is scheduled. Patients are monitored at one week, 30 days and then every three months for periodontal maintenance. No subsequent probing is performed for at least six months to a year, to allow sufficient healing time for the cementum-fiber PDL interface.

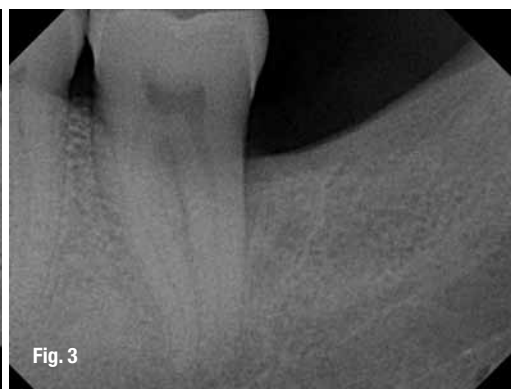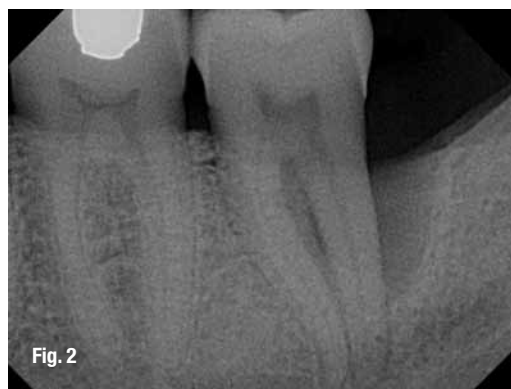
Harnessing the LANAP protocol's results

The availability of a procedure that eliminates cutting and sewing without gum recession is changing the standard of care for periodontitis treatment. Not only is there a treatment protocol that is universally accepted by patients, but it also represents an option that includes both specialists and general practitioners in the solution. A general practitioner who may be reluctant to perform invasive surgery may welcome the opportunity to treat such an overwhelming health issue without referring patients elsewhere. Alternatively, the LANAP protocol practiced by periodontic specialists, becomes a more attractive referral for general practitioners and their patients.

Those who choose to embrace the LANAP protocol do so with a support system in place. Clinicians are required to undergo extensive training and adhere to the protocols that have proven successful before performing the LANAP technique. Millennium Dental Technologies, the manufacturer of the PeriLase MVP-7, requires clinicians satisfactorily complete a three-day lecture course and live, hands-on patient

Fig. 2_ Pre-LANAP, April 2009.

Fig. 3_ Post-LANAP, May 2010.



treatment and patient response before the company will ship the laser and all the essential elements of the protocol. Additional study follows the initial training.

The science behind the LANAP protocol

Early LANAP protocol research showed consistent mean pocket depth reduction (nearly 50 percent) and improved bone density (38 percent) in an eight-year retrospective study of the protocol's earliest clinical results. The Emago imaging system demonstrated that 100 percent of these cases showed bone density increases. The procedure has also proven effective at reducing pocket depth without gingival recession over a six-month period.^{16,17}

In the fourth-largest human histological study in the perio regeneration literature (with a control group), the LANAP protocol using the PerioLase MPV-7 was compared to a blinded examiner (clinical) conventional scaling and root planing without laser assistance. Twelve teeth were removed en bloc and examined by a blinded histologist. When the blinded code was broken, all teeth treated with the LANAP protocol demonstrated 100 percent cementum-mediated new periodontal ligament attachment to the previously periodontally affected tooth roots in all six of the LANAP-treated teeth and in the absence of long junctional epithelium.^{8,11} These results are unique in the perio literature.

Given its unique, predictably regenerative results, it should come as no surprise that the LANAP protocol has inspired its share of imitators. As yet, those copycat protocols have no science to support their continued use. The patented LANAP protocol is the only peer-reviewed and FDA-cleared approach that is proven successful at treating mild, moderate and especially severe periodontitis.

LANAP protocol vs. cut-and-sew procedures

The successful treatment of periodontal disease requires thorough debridement of the root surface.

Pockets of 5 mm or greater depth make it difficult to remove subgingival plaque and calculus. Surgical intervention allows access and visualization for scaling and root planing in these deep pockets.¹⁸ While scalpel surgery can accomplish such access and visualization, it can also result in attachment loss, gingival cratering and gingival recession.¹⁹⁻²² Additionally, the associated pain and discomfort can be deterrents.²³

In any case, many general practitioners would never consider performing conventional flap surgery because of its invasive nature.

LANAP treatment, while an exceptional alternative, is not without its drawbacks. The predominant issues involve cost and time. The initial financial outlay for the laser equipment can be cost-prohibitive for some practices.

Similarly, dental clinicians must be willing and able to take time away from the office to undergo procedural training and learn LANAP treatment with live patients. Following the training, and as with anything new, there can be a learning curve as clinicians grow comfortable and begin to excel at treating patients with LANAP procedures.

For now, cut-and-sew techniques remain the standard of care and additional study will be required to persuade many professionals that any laser system provides clinical value surpassing scaling and root planing techniques and conventional surgical treatment.²⁴ Cautious experts warn that the improper use of the Nd:YAG laser can have detrimental effects on the root surface ranging from heat cracking to charring, cementum meltdown and crater formation.²⁵ These negative outcomes are not typical with adherence to current LANAP protocols and thus far appear to result from improper laser settings. Studies continue, and most researchers agree that laser or laser-assisted pocket therapy is expected to become a new technical modality in periodontics.²⁶

The LANAP treatment protocol achieves the same access to the problem that root planing and scaling or conventional flap surgery does, but it achieves its

success differently. The practitioner uses a quartz fiber in place of a scalpel to achieve both tissue ablation and antibiotic properties. No cutting means a significantly more comfortable recovery.

Patients typically remain on a soft diet for several days to a week following LANAP treatment and are instructed to avoid brushing at the surgical site for that period.

Conclusion

Whereas treatment outcomes with conventional modalities may be variable, in stark contrast the LANAP protocol allows clinicians to achieve predictable positive results — including three-dimensional regeneration of bone. Also, comfort levels associated with this minimally invasive treatment are substantially increasing patient acceptance rates.

Ongoing additional studies are expected to continue to underscore the LANAP protocol advantages and pave the way for its acceptance as a standard of care in treating patients with moderate to severe gum disease.

**LANAP is a registered trademark of Millennium Dental Technologies.*

References

1. Faculty Bio pages. UCLA School of Dentistry Web site. Michael G. Newman, BA, DDS, FACD, www.dent.ucla.edu/bio/bio.asp?id=277. Accessed on March 13, 2008.
2. Carroll, Linda. Mother's gum disease linked to infant's death. www.msnbc.msn.com/id/34979552/. Accessed February 25, 2010.
3. Myers TD, Myers WD, Stone RM. First soft tissue study utilizing a pulsed Nd:YAG dental laser. *Northwest Dent*. 1989;68: 14–17.
4. White JM, Goodis HE, Rose CL. Use of the pulsed Nd:YAG laser for intraoral soft tissue surgery. *Lasers Surg Med*. 1991;11:455–461.
5. Gregg RH II, McCarthy D. Laser periodontal therapy: case reports. *Dent Today*. Oct 2001;20:74–81.
6. Gregg RH II, McCarthy D. Laser periodontal therapy for bone regeneration. *Dent Today*. May 2002;21:54–59.
7. 501(k)s final decisions rendered for July 2004 (PerioLase MPV-7, 510(k) number K030290). US FDA Center for Devices and Radiological Health Web site. www.fda.gov/cdrh/510k/sumjul04.html. Updated August 9, 2004. Accessed January 2, 2008.
8. Yukna RA, Evans GH, Vastardis S, et al. Human periodontal regeneration following the laser assisted new attachment procedure. Paper presented at: IADR/AADR/CADR 82nd General Session; March 10–13, 2004; Honolulu, HI. Abstract 2411. iadr.confex.com/iadr/2004Hawaii/techprogram/abstract_47642.htm. Accessed January 2, 2008.
9. Neill ME, Mellonig JT. Clinical efficacy of the Nd:YAG laser for combination periodontitis therapy. *Pract Periodontics Aesthet Dent*. 1997;9(suppl):1–5.
10. Gregg RH, McCarthy DK. Laser ENAP for periodontal ligament regeneration. *Dent Today*. 1998;17:86–89.
11. Gregg RH, McCarthy DK. Laser ENAP for periodontal bone regeneration. *Dent Today*. 1998;17:88–91.
12. Midda M, Renton-Harper P. Lasers in dentistry. *Br Dent J*. 1991;170:343–346.
13. Moritz A, Schoop U, Goharkhay K, et al. The bactericidal effect of Nd:YAG, Ho:YAG, and Er:YAG laser irradiation in the root canal: an in vitro comparison. *J Clin Laser Med Surg*. 1999;17:161–164.
14. Whitters CJ, Macfarlane TW, MacKenzie D, et al. The bactericidal activity of pulsed Nd:YAG laser radiation in vitro. *Lasers Med Sci*. 1994;9:297–303.
15. Harris DM. Ablation of *Porphyromonas gingivalis* in vitro with pulsed dental lasers. Paper presented at 32nd Annual Meeting and Exhibition of the AADR; March 12–15, 2003; San Antonio, TX. Abstract 855. iadr/2003SanAnton/techprogram/abstract_27983.htm. Accessed January 2, 2008.
16. Harris DM. Dosimetry for laser sulcular debridement. *Laser Surg Med*. 2003;33:217–218.
17. Harris DM, Gregg RH II, McCarthy DK, et al. Laser-assisted new attachment procedure in private practice. *Gen Dent*. 2004;52:396–403.
18. Isidor F, Karring T, Attstrom R. The effect of root planing as compared to that of surgical treatment. *J Clin Periodontol*. 1984;11:669–681.
19. Becker W, Becker BE, Ochsenein C, Kerry G, Caffesse R, Morrison EC, Prichard J. A longitudinal study comparing scaling, osseous surgery, and modified Widman procedures. Results after one year. *J Periodontol*. 1988;59:351–365.
20. Pihlstrom BL, Ortiz-Campos C, McHugh RB. A randomized four-years study of periodontal therapy. *J Periodontol*. 1981;52:227–242.
21. Kaldahl WB, Kalkwarf KL, Patil KD, Dyer JK, Bates RE Jr. Evaluation of four modalities of periodontal therapy. Mean probing depth, probing attachment level, and recession changes. *J Periodontol*. 1988;59:783–793.
22. Hill RW, Ramfjord SP, Morrison EC, Appleberry EA, Caffesse RG, Kerry GJ, Nissle RR. Four types of periodontal treatment compared over two years. *J Periodontol*. 1981;52:655–662.
23. Curtis JW Jr, McLain JB, Hutchinson RA. The incidence and severity of complications and pain following periodontal surgery. *J Periodontol*. 1985;56:597–601.
24. Matthews, Debora C. The truth about soft tissue lasers and nonsurgical periodontal therapy. *JCDA* 2010.
25. Chanthaboury, Rachel, Irinakis, Tassos. The use of lasers for periodontal debridement: marketing tool or proven therapy? *JCDA* Oct 2005.
26. Ishikawa, Isao; Aoki, Akira; Takasaki, Aristeo A.; Mizutani, Koji; Sasaki, Katia M; Izumi, Yuichi. *Periodontology* 2000 May 2009.

about the author laser



Robert H. Gregg II, DDS, is a former faculty member at the UCLA School of Dentistry. He has been using lasers clinically since August 1990, including CO₂, free-running pulsed (FRP) Nd:YAG, both single and variable pulsed; FRP Ho:YAG, surgical Argon, CW diodes and Er:YAG. He has given lectures both nationally and internationally on the subject of clinical laser applications, and he has conducted seminars for the UCLA Department of Continuing Education. In addition to authoring several peer-reviewed articles on the clinical applications of FRP Nd:YAG for endodontic and periodontal uses, he is an author of the Curriculum Guidelines and Standards for Dental Laser Education. Gregg has obtained his mastership and educator's certification in the Academy of Laser Dentistry. He has been appointed as a peer-review member of the Dentistry Today CE Editorial Board. He is a co-developer of the FDA-cleared PerioLase MVP-7 pulsed Nd:YAG laser, and is a founder of Millennium Dental Technologies. Gregg is also a co-developer and patent holder of the LANAP laser periodontitis treatment. He maintains a private practice where he sees patients. He is president and chairman of the board of Millennium Dental Technologies and president of the Institute for Advanced Laser Dentistry. He can be contacted through his website, www.lanap.com.