



Hands-on workshops create additional learning opportunities at the Osteogenics' 2011 Global Bone Grafting Symposium. (Photo/Provided by Osteogenics Biomedical)

Clinicians gather for Osteogenics' Global Bone Grafting event

More than 350 clinicians from 10 countries gathered in Scottsdale, Ariz., on April 1 and 2 to attend Osteogenics' 2011 Global Bone Grafting Symposium, a continuing education event focused on dental bone grafting and treatment planning.

At the event, hosted by Osteogenics Biomedical, world-renowned speakers led lectures, interactive treatment planning sessions and optional hands-on workshops offering a variety of treatment perspectives and protocols. This year's speakers included Drs. Paul Fugazzotto, Suzanne Caudry, Barry Bartee, Tom Wilson, Paulo Coelho, Sascha Jovanovic, Istvan Urban, Dan Cullum and Craig Misch.

"This year's symposium attracted a record group of doctors," said Shane Shuttlesworth, Osteogenics' president. "The growing success of our annual symposium is in a large part thanks to the quality, credibility and variety of speakers that we have been able to partner with."

"Every year the program is unique," said Dr. Stephen Folson, a periodontist from Peoria, Ariz. "They bring speakers in worldwide, and I take home to my office on Monday morning applications that I have gleaned from the meetings on an annual basis."

New to the symposium this year, clinicians had the option to choose one of three pre-symposium hands-on workshops. The limited attendance workshops, led by Caudry, Cullum and Jovanovic, sold out weeks prior to the symposium. Based on the positive feedback from attendees, Osteogenics plans to offer pre-symposium workshops again next year.

→ **IT** page 9B

Bone harvesting: nice and easy

By Dr. Steffen Hohl and Dr. Anne Sophie Brandt Petersen

Introduction

The desire to use bone from your own body to build new bone in another place may be almost as old as humanity itself. We call this procedure autologous bone grafting.

In the case of autologous bone grafting, the bone is removed from the same organism that the graft is to be incorporated in. The body's own bone cells have the greatest potency for rebuilding of bones and are the gold standard in oral augmentation surgery. Donor areas are: the tuber maxillae, the retromolar space, the chin region or the iliac crest, the ribs or the shin.

Gaining the required quantity is sometimes elaborate (large surgical interventions, in-patient stay) and afflicted with particular problems,

→ **IT** page 2B

Figs. 1, 2: Initial situation. State three months after the removal of the teeth. The vestibular lamella has completely collapsed.

Fig. 3: Noticeably visible three-wall bone defect.

Fig. 4: After drilling the implant shafts, the areas showed to be significantly atrophied.

Fig. 5: The implant shafts are dilated using condensers and the periimplantational bone is condensed.

Fig. 6: Implant insertion. It is visible that a vestibular augmentation must take place.

Fig. 7: The implant body must be vestibularly covered with autologous bone over about two-thirds of its surface.

Fig. 8: Retromolar stab incision with an 11 scalpel.

Fig. 9: A conventional implant drill is used to drill directly in the area of the inea obliqua through the stab incision. A "two-spade drill" is excellently suited to bone extraction.

Fig. 10: Bone excavation via simple shaft drilling with the conventional "two-spade drill."

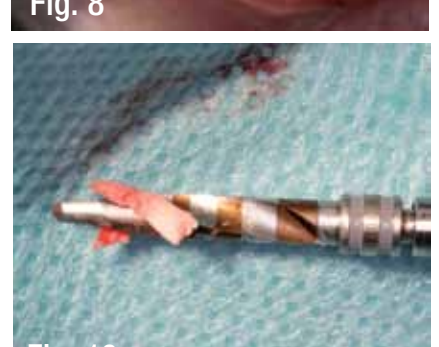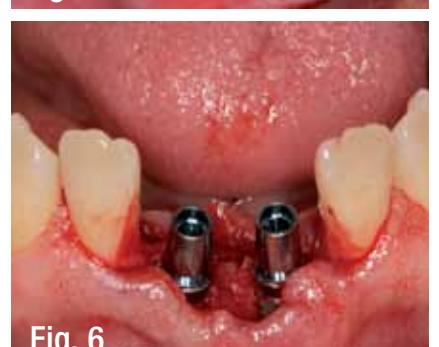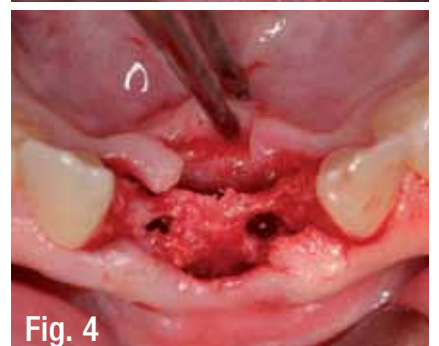
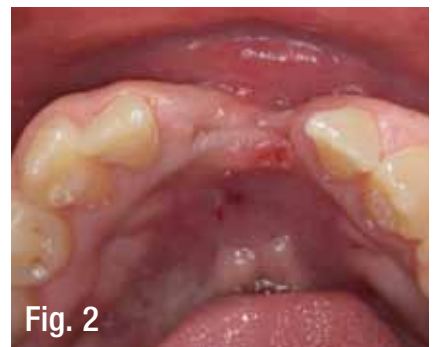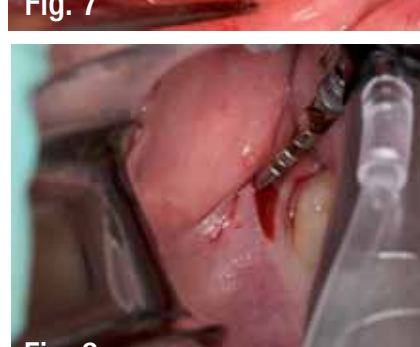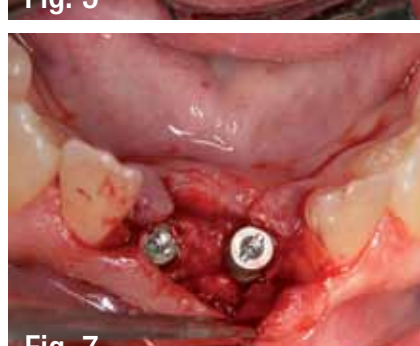


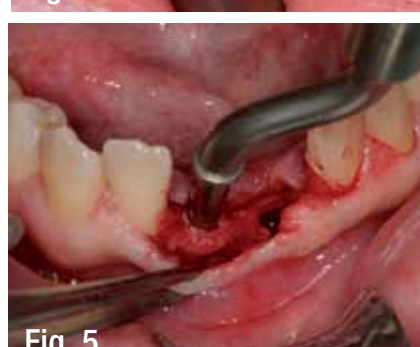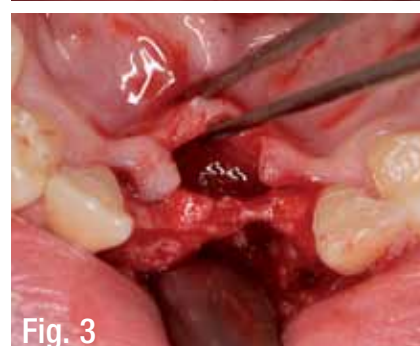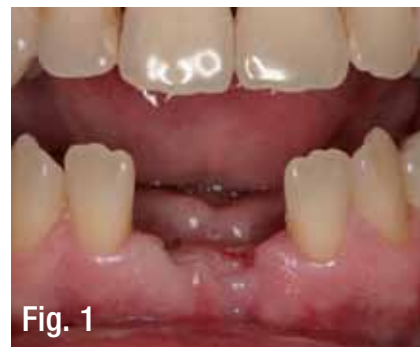Fig. 11: Additional bone excavation by hollowing out the shaft drill hole in the linea obliqua with the excavator.

Fig. 12: Implants and autologous bone augmentation in situ. In order to achieve this result, it was necessary to drill only into the retromolar.

Fig. 13: Covering the implants and augmentations with a simple collagen membrane.

Figs. 14, 15: The stab incision of the retromolar extraction region is glued with cyanoacrylate. Hereby the patient only incurs a microscopic extraction defect.

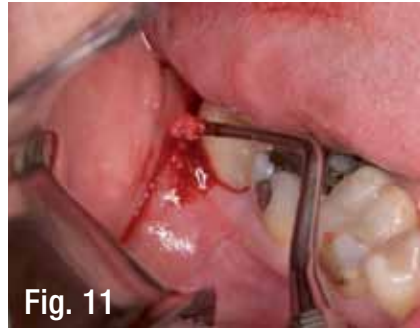

Fig. 11

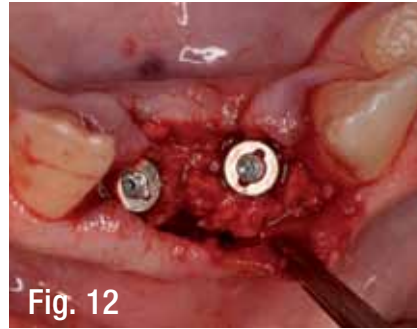

Fig. 12

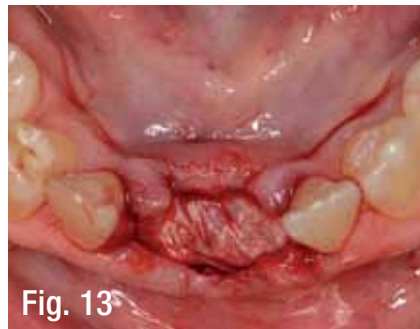

Fig. 13

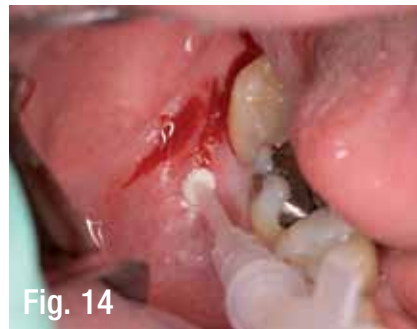

Fig. 14

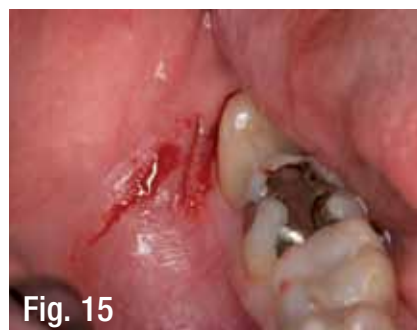

Fig. 15

← **IT** page 1B

especially when it comes from regions far away from the oral cavity (e.g., the iliac crest).

The extraction of autologous bone grafts from the retromolar space find the best acceptance with patients. Particularly in implantology, lateral augmentations are necessary in more than 75 percent of cases. These augmentative measures mostly require low bone volumes of less than 0.5 mg. If the decision is made intraoperatively that the patient's own bone must be used, as a rule the following question must be asked: "Which region should the bone be taken from and how can it

be removed quickly?"

The retromolar space is chosen here in more than 70 percent of cases. Until now, block grafts have been used exclusively,

Case description

The 56-year-old patient wants the gaps in his teeth to be filled with implants due to his otherwise intact dentition. However, in this situation, the question is raised of whether implantation and necessary augmentation of the crestal

jaw line can occur synchronously.

It was planned for the patient to have autologous bone adhered in the region of the 051 vestibular. Hereby the right retromolar space and the right tuber area were considered as donor areas.

The patient was assured preoperatively that an extraction defect would only involve minor postoperative symptoms. Intraoperatively, the crestal incision was begun in the areas 051 and 041.

After forming a minimally invasive mucoperiosteal flap, region 051 in particular showed strong vestibular atrophies. Initially implant drilling was carried out and the bore shaft was extended using a bone condenser, i.e., the periimplantational bone was condensed.

Subsequently, the implant bodies were inserted. Here it became obvious that the implant was two-thirds exposed on its vestibular side in region 051. Both implants were primarily stable.

After measuring the missing bone volume, a stab incision was made in the right retromolar. Then a conventional implant drill was driven through the gums and drilled precisely 9 mm deep. When withdrawing the drill, the bone meal was retained.

Additionally, further spongy bone was extracted with a mini-excavator. The transplant bone was able to be adsorbed into the implant body in an ideal manner. Finally, a thin collagen membrane was applied for complete coverage.

The soft-tissue defects were closed with absorbable materials. The stab incision in the retromolar was glued with cyanoacrylate. In regions 051/041, the wound closure was carried out using absorbable suture material and

IMPLANT TRIBUNE

The World's Newspaper of Implantology · U.S. Edition

Publisher & Chairman

Torsten Oemus
t.oemus@dental-tribune.com

Chief Operating Officer

Eric Seid
e.seid@dental-tribune.com

Group Editor & Designer

Robin Goodman
r.goodman@dental-tribune.com

Editor in Chief

Sascha A. Jovanovic, DDS, MS
sascha@jovanoviconline.com

Managing Editor/Designer

Implant, Endo & Lab Tribunes
Sierra Rendon
s.rendon@dental-tribune.com

Managing Editor/Designer

Ortho Tribune & Show Dailies
Kristine Colker
k.colker@dental-tribune.com

Online Editor

Fred Michmershuizen
f.michmershuizen@dental-tribune.com

Account Manager

Humberto Estrada
h.estrada@dental-tribune.com

Marketing Manager

Anna Wlodarczyk
a.wlodarczyk@dental-tribune.com

Marketing & Sales Assistant

Lorrie Young
l.young@dental-tribune.com

C.E. Manager

Julia Wehkamp
j.wehkamp@dental-tribune.com

International C.E. Sales Manager

Christiane Ferret
c.ferret@dtstudyclub.com

Dental Tribune America, LLC
116 W. 23rd St., Suite #500
New York, NY 10011
Phone: (212) 244-7181, Fax: (212) 244-7185

Published by

Dental Tribune America

© 2011 Dental Tribune America.
All rights reserved.

Dental Tribune makes every effort to report clinical information and manufacturer's product news accurately, but cannot assume responsibility for the validity of product claims, or for typographical errors. The publishers also do not assume responsibility for product names or claims, or statements made by advertisers. Opinions expressed by authors are their own and may not reflect those of Dental Tribune International.

Editorial Advisory Board

Dr. Sascha Jovanovic, Editor in Chief

Dr. Bernard Touati

Dr. Jack T. Krauser

Dr. Andre Saadoun

Dr. Gary Henkel

Dr. Doug Deporter

Dr. Michael Norton


Dr. Ken Serota

Dr. Axel Zoellner

Dr. Glen Liddelou

Dr. Marius Steigmann

AD




- Quality Esthetic Restorations
- Meticulous Implant Case Fabrication


Implant Specialist —
CREATING A WORLD OF SMILES

A 37-year record of providing precision made dental products with minimal insertion time, combined with quality and consistency, has earned the trust, confidence and reliability of dentists who consider Dutton Dental Concepts to be a leader in quality restorations and implants.


Attention to detail, quality materials, communication, education and the desire to provide the best possible restoration has been the constant theme at Dutton Dental Concepts.




LAYERED ZIRCONIA BRIDGE



ALL ON SIX



DUTTON AESTHETIC ABUTMENT



Dutton DENTAL CONCEPTS INC.
800.426.2427
330.874.9333
duttondental.com
ddc@duttondental.com

11020 INDUSTRIAL PARKWAY | BOLIVAR, OHIO 44612

→ **IT** page 6B

NuOss™ DS

Delivery Syringe

DELIVERY SIMPLIFIED

A NATURAL BONE MINERAL MATRIX DELIVERY SYRINGE SYSTEM

NuOss™ — A natural, porous bone mineral matrix. It is produced by removal of all organic components from bovine bone. Due to its natural structure the anorganic bone mineral of NuOss™ is physically and chemically comparable to the mineralized matrix of human bone.

NuOss™ DS — Our NuOss™ cancellous granules pre-loaded into an easy to hydrate **delivery syringe** for ease of product placement.

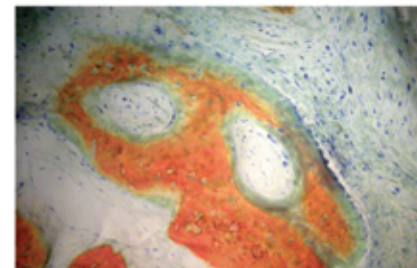
NuOss™ DS DELIVERY SYRINGE

Number	Description	Particle size	Volume	Price
509-9025	NuOss™ DS Cancellous Granules	.25-1.0mm	.25cc	\$54.99
509-9050	NuOss™ DS Cancellous Granules	.25-1.0mm	.50cc	79.99
509-9010	NuOss™ DS Cancellous Granules	.25-1.0mm	1.0cc	121.99

*Clinical Histology: 5 Months

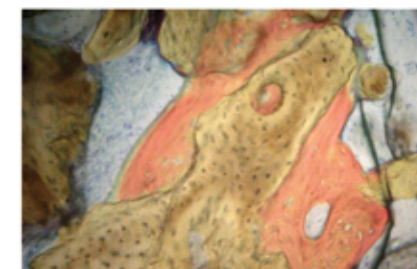
Area of newly formed woven bone with osteoblasts lining the bone.

- Osteoblasts - blue
- Soft Tissue - white/grey



Vital bone apposition can be seen directly on the particles of NuOss.

- New Vital Bone - red
- NuOss - tan



* Rohrer, Michael, DDS, MS; Prasad, Hari, BS, MDT; University of Minnesota, Hard Tissue Research Lab
 Insets: Stevenel's Blue and Van Gieson's Picro Fuchsin, 100x magnification

To place an order, please call **800.441.3100**

Manufacturer: Collagen Matrix, Inc., 15 Thornton Road, Oakland, NJ

ScrewPlant®

Legacy™

SwishPlant™


ReActive®

ScrewDirect®
Straight Snap-on

GoDirect™
Attachment

ScrewIndirect®
Screw-Receiving

ScrewRedirect®
Angled Contoured



Two-Piece Implants



One-Piece Implants

There's no need to buy abutments when most of our implants' All-in-1 Packaging gives you a fixture-mount that functions as both transfer and abutment. Our multiple one-piece implant designs eliminate the need for an abutment all together. Restorative dentists, when working in the team approach, request our implants to assist in reducing or even eliminating the cost of prosthetic components.

When the clinical situation necessitates the purchase of a specific abutment, remember that our broad line of industry-compatible prosthetics offers improved designs at a low cost.

Our industry-compatible connections for ultimate versatility



ScrewPlant®
Internal Hex
with External Bevel
ID Proprietary



RePlant®
Internal Tri-Lobe
Compatible with
NobelReplace™



SwishPlant™
Internal Octagon
Compatible with
Straumann Tissue Level

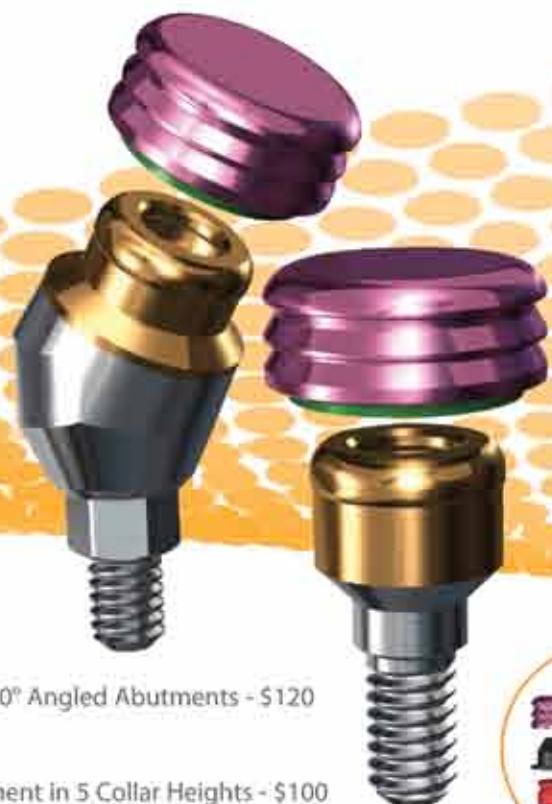

Legacy™
Internal Hex
Compatible with
Zimmer, BioHorizons, MIS®

Find the industry-compatible implant solution that fits your practice today.


US list prices as of April 2011.
Compatible with Zest LOCATOR® System
Available for industry-standard internal hex and internal tri-lobe connections only.
Comparison based upon Straumann's CARES custom titanium abutment. Price varies depending upon the laboratory.
LOCATOR® is a registered trademark of Zest Anchors Company. The GoDirect™ and GPS™ Systems are neither authorized, endorsed nor sponsored by Zest Anchors Company.

Smarter



15° & 30° Angled Abutments - \$120

Abutment in 5 Collar Heights - \$100



Zirconia Abutment on Anodized Titanium Bases - \$120

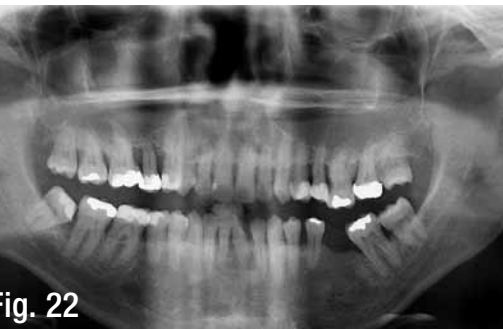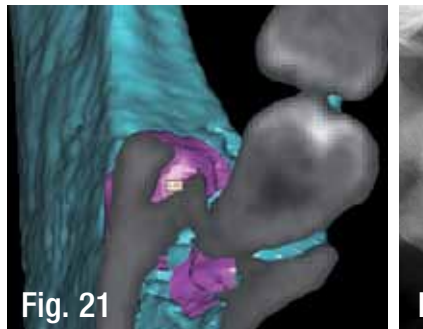
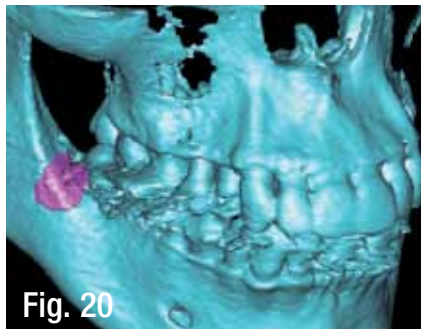
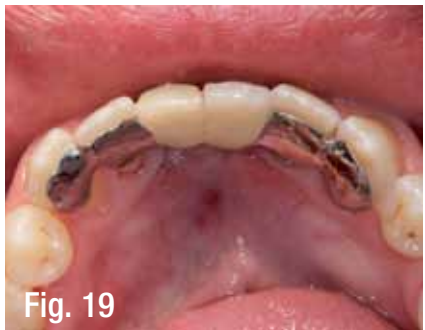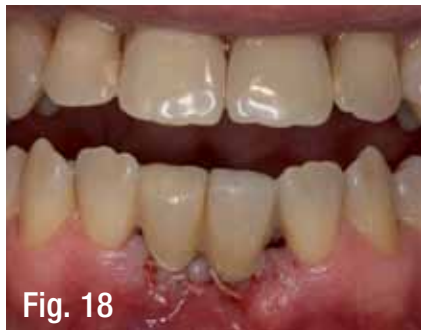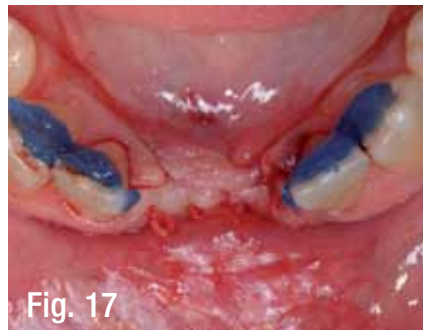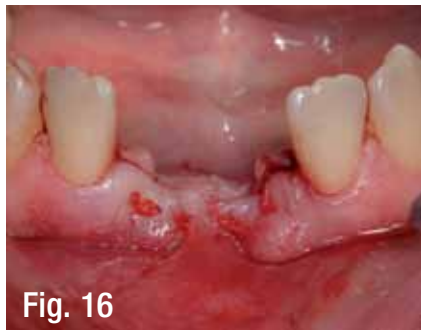Anodized Titanium Bases for Custom Zirconia Abutments - \$60

GPS™ Overdenture Attachment System features Straight & Angled Abutments that provide a retentive platform compatible with LOCATOR® attachments. All-in-1 Packaging includes Anodized Housing with 4.5lbs Retentive Cap & Transfer. Straight Abutments accommodate up to 20° divergence while 15° & 30° Angled Abutments are suited for overdentures on angled implants.

Zirconia Abutments on Titanium Bases combine esthetics with strength & precision for restorations in the esthetic zone. The titanium base is gold anodized to maintain the natural tooth color of the zirconia while providing structural support. These stock abutments with contoured margins are provided in 0°, 8° & 15° with 1 & 2mm collar heights to minimize the need for preparation, thereby providing the benefits of custom abutments at less than half the price.

Our full line of industry-compatible, simply smarter prosthetics

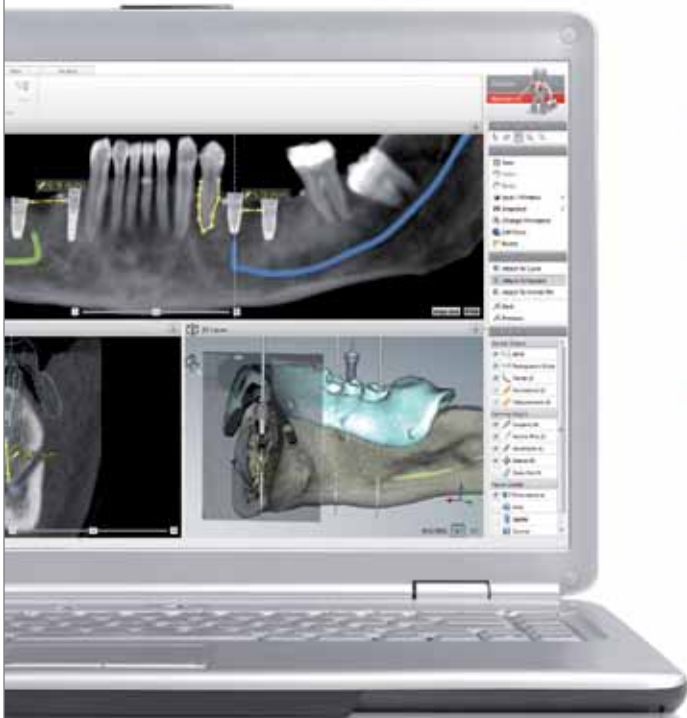	Laboratory Abutment	Straight Snap-On	Straight Contoured	15° Angled Contoured	Gold/Plastic	Zirconia/Ti Abutment	Angled Zirconia/Ti Abutment	Plastic Temporary Abutment	Ball Attachment	GPS™ Attachment	Angled GPS™ Attachment	Multiple-Unit w/Cap & Transfer Straight	Multiple-Unit w/Cap & Transfer Angled
Our price	\$75	\$85	\$85	\$85	\$100	\$120	\$120	\$35	\$107	\$100	\$120	\$85	\$100
Zimmer Dental*	\$155	\$210	\$165	\$180	\$190	\$232	\$247	\$65	\$172	\$160	N/A	\$167	N/A
Straumann*	N/A	\$181	\$182	\$203	\$157	\$339	\$339	\$61	\$192	\$193	N/A	\$169	N/A
Nobel Biocare™	\$145	\$186	\$170	\$225	\$216	\$285	\$285	\$72	\$217	\$149	N/A	\$229	\$274



Figs. 16, 17: The soft tissue in the implant region is closed with absorbable suture material. The neighboring teeth (#43, #42, #32, #33) are lingually cauterized. Figs. 18, 19: Insertion of a Maryland provisional prosthesis directly after the augmentative-implantological intervention. Fig. 20-22: Digital volume tomography of the excavation defect.

AD

Take diagnostics and planning to the next level.



Maximize treatment safety and predictability.

Enhance quality and efficiency through digital diagnostics.

Enjoy planning flexibility for optimized function and esthetics.



It's called NobelClinician Software. You can diagnose and plan treatments with a new level of predictability and safety. Enhance your diagnostics with combined 2D and 3D views and optimize implant placement based on patient anatomy and prosthetic needs. Using NobelClinician Software, you can collaborate with your treatment partners through the integrated NobelConnect functionality and

present treatment options to your patients. In addition, you have the option to complete the digital path with the proven guided surgery concept NobelGuide. When you partner with Nobel Biocare, a pioneer in digital dentistry, you benefit from proven technology that ensures superior function and natural-looking esthetics.

Their smile, your skill, our solutions.

nobelbiocare.com/digital



Nobel Biocare USA, LLC, 22715 Sayl Ranch Parkway, Yorba Linda, CA 92867, Phone 714 262 4800, Toll free 800 993 8100, Tech. support 888 725 7100, Fax 714 262 9023
Nobel Biocare Canada, Inc. 9133 Leslie Street, Unit 100, Richmond Hill, ON L4B 4N1, Phone 905 762 3500, Toll free 800 939 6394, Fax 905 900 4243
© Nobel Biocare Services AG, 2011. All rights reserved. Nobel Biocare, the Nobel Biocare logo and all other trademarks are, if nothing else is stated or is evident from the context in a certain case, trademarks of Nobel Biocare. Disclaimer: Some products may not be regulatory cleared/released for sale in all markets. Please contact the local Nobel Biocare sales office for current product assortment and availability.

← **II** page 2B

horizontal mattress stitches.

Finally, as a provisional restoration, a Maryland temporary prosthesis was affixed, which additionally ensured good soft-tissue stabilization. A digital volume tomography (DVT) was produced in order to evaluate the removal defect and document the augmentative result.

Summary

Autologous bone grafting represents the gold standard in augmentation surgery. Particularly with implant operations, it is often only shown intraoperatively that a small quantity of autologous bone is needed for augmentation.

In this situation, a quick reaction is often indicated. The retromolar space is frequented most often for this purpose. As the patient should have the least possible discomfort because of the bone extraction, minimally invasive procedures are the means of choice.

The technique presented above is a new method, which is impressive due to its minimally invasive and simple characteristics. The procedure is especially ideal for augmentation planning with volumes up to 0.5 mg. Of course, larger bone volumes can also be extracted using this minimally invasive method.

Soft tissues can be closed discreetly using adhesive techniques that are hardly noticeable to the patient. Minimally invasive procedures in implantology can be perfectly planned and executed by including modern 3-D-diagnostics (DVT). **II**

II Contacts


Dr. Steffen Hohl
DIC Dental Implant
Competence
Estetalstr. 1
21614 Buxtehude, Germany
www.dr-hohl.de

Dr. Anne Sophie Brandt Petersen
Tandlaegerne i Kogade
Kogade 4
6270 Tonder, Denmark
www.dentist.dk


OSTEOGENICS

B I O M E D I C A L

Introducing
enCore™
COMBINATION
ALLOGRAFT



enCore™ Combination Allograft - the first allograft particulate bone grafting product **combining mineralized and demineralized bone in a single bottle**. Already a popular combination among many specialists, enCore™ leverages the complementary benefits of space-maintaining mineralized bone with osteoinductive demineralized matrix to optimize the environment for the regeneration of vital bone. **Patent pending.*

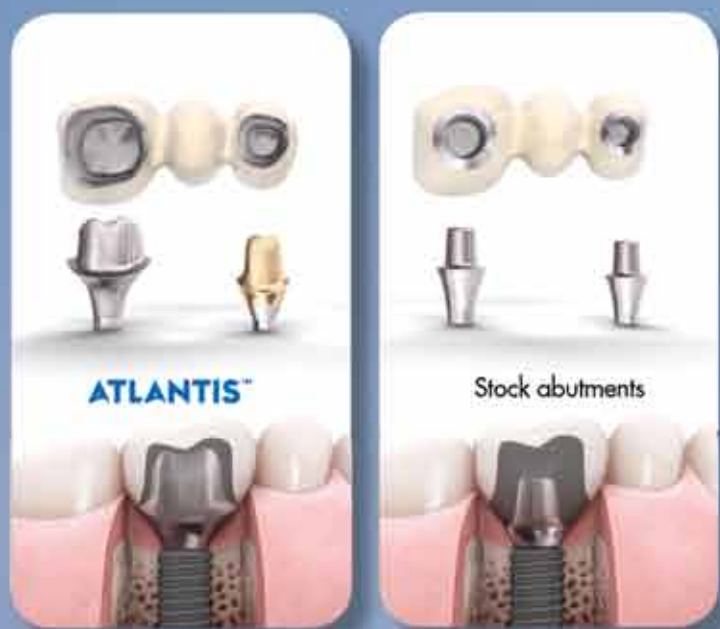

Representative histology taken at 6 months from a case using combination allograft.
Histology by Michael Rohrer, DDS, MS, University of Minnesota

86% vital bone, 14% residual graft
51% bone, 49% marrow

ATLANTIS™

Patient-specific abutments for all major implant systems



Patient-specific abutments provide several advantages over stock abutments:

- The anatomically optimal emergence profile of the abutment supports long-term esthetics
- Margins can be designed at an ideal level for safe and easy cement removal
- The abutment provides optimal support and retention for the final restoration
- Simple restorative procedure - just take an impression, send it to your laboratory and ask for Atlantis

LATEST ATLANTIS™ ADDITIONS:

Astra Tech - OsseoSpeed™ TX Profile
Keystone - PrimaConnex™

Visit us at booth #1321 at the
JDIQ meeting in Montreal, QC,
May 30-31, 2011.

 **ASTRATECH
DENTAL**
Get Inspired.

ASTRA
ASTRA TECH

 A company in the
AstraZeneca Group

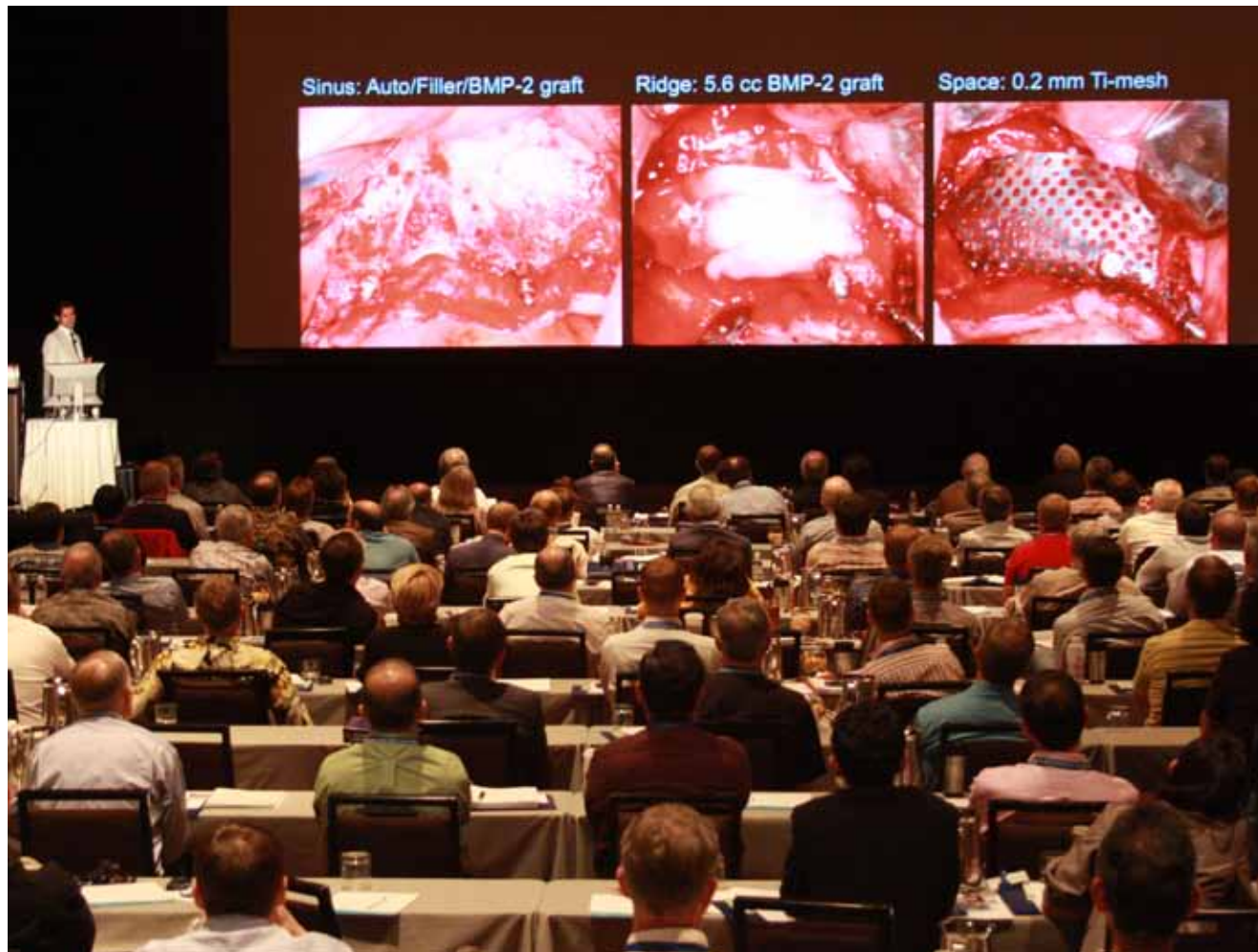800-531-3481 • www.astratechdental.com

← **IT** page 1B

Osteogenics Biomedical established Osteogenics Clinical Education in 2008 with a mission of providing interactive hands-on clinical education in bone grafting and implant dentistry. Since then, Osteogenics Clinical Education has hosted the Global Bone Grafting Symposium annually every spring. Each year the symposium offers clinicians the opportunity to improve their comprehensive treatment planning skills and integrate the latest technologies, materials and techniques into their treatment planning process.

About Osteogenics Biomedical

Headquartered in Lubbock, Texas, Osteogenics Biomedical is a leader in the development of innovative dental bone-grafting products serving periodontists, oral and maxillofacial surgeons and clinicians involved in regenerative and implant dentistry throughout the world. Osteogenics offers a complete line of bone grafting products including enCore™ Combination and Mineralized Allografts, Cytoplast® PTFE membranes, Cytoplast® collagen membranes, Cytoplast® PTFE suture and the Pro-fix™ Precision Fixation System.



Dr. Sascha Jovanovic, world-renowned speaker and editor in chief of Implant Tribune, lectures on horizontal and vertical ridge augmentation at the Osteogenics' 2011 Global Bone Grafting Symposium in April in Arizona. (Photo/ Provided by Osteogenics Biomedical)

(Source: Osteogenics Biomedical)

AD

MEISINGER Bone Management®

Benex®-Control
Root Extraction System

Benex®-Control (Root Extraction System) are ideally suited for the extraction of roots and root fragments. Due to the innovative construction of the extractor, the root can be removed very easily and in an extremely controlled manner without causing injury to the bone.

BBE00

MEISINGER

GERMANY USA

MEISINGER USA, L.L.C.
7442 South Tucson Way • Suite 130 • Centennial • Colorado 80112 • USA
Tel.: +1 (303) 268-5400 • Fax: +1 (303) 268-5407
E-Mail: info@meisingerusa.com • www.meisingerusa.com • www.bone-management.com • www.occlusalrouter.com