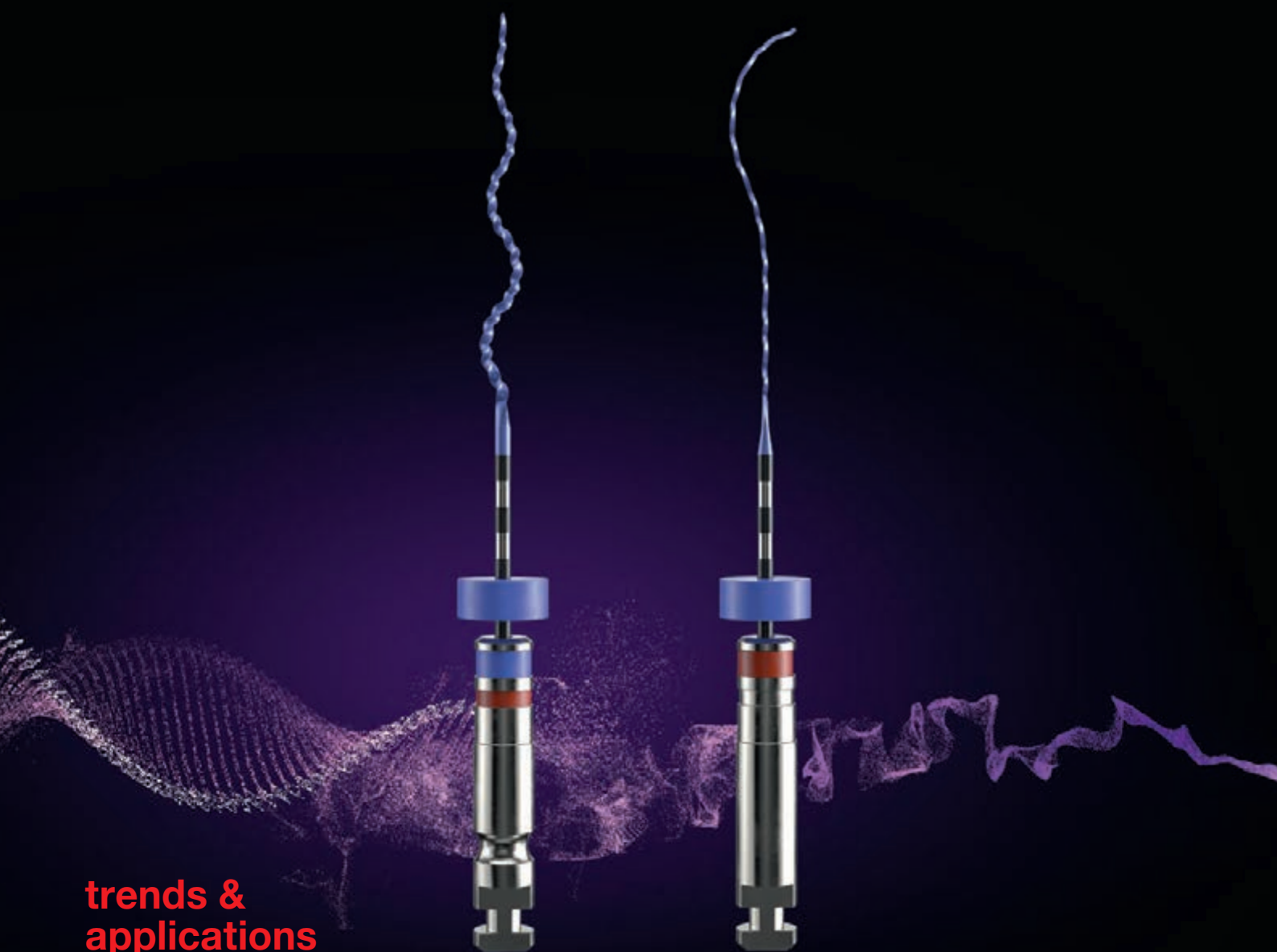

roots

international magazine of endodontics



trends & applications


Dynamic navigation—
The future of endodontics

case report

Endodontic follow-up in strongly curved root canals

study

Tooth-preserving endodontic surgery



VDW.ROTATE™ NiTi Root Canal File

The remix taking rotary
preparation to the next level

VERSATILITY

VDW.ROTATE™ includes an intuitive 3 file basic sequence plus a wide range of larger files for various clinical cases with matching paper points and obturators.

Be virtuoso!

RESPECT OF THE NATURAL CANAL ANATOMY

The instruments follow the natural canal anatomy smoothly thanks to its specific heat treatment making the file more flexible without compromising its cutting efficiency.*

Get in the swing!

EFFICIENT DEBRIS REMOVAL

The adapted S cross section gives more space for debris removal and provides control of the instrument for a swift, thorough and safe preparation.*,**

Set the beat!

*compared to other VDW continuous rotary instruments
**compared to a centred rotary cross section

Dr Philippe Sleiman

Guest Editor



In patient or on paper?

During the evolution of humankind, revolutionary discoveries (like gravity from Newton with the apple tree), new techniques and medicines came from the field and from life experience. That is how we learnt about plants and their various benefits in our life, and this gave us some of the drugs we use today.

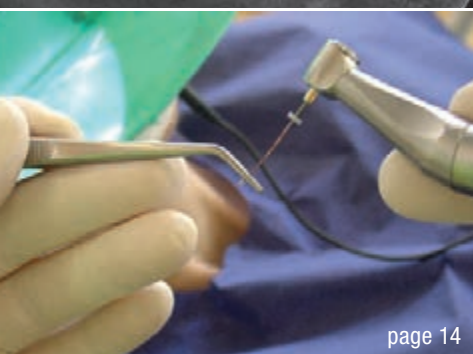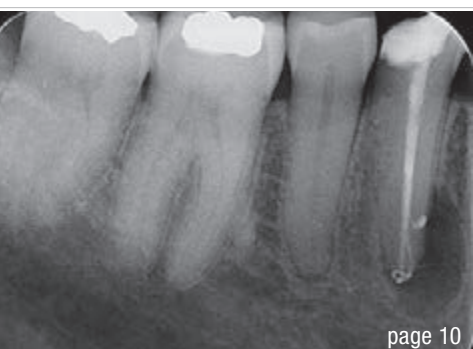Recently, this modality of learning has been changing, it seems, and we are starting to see a big gap in the treatments we are using between what works on paper according to marketing materials, and what works for our patients in practice. It may be because while research is being conducted, the human factor or actual environment in which the potential future products will be used is not taken fully into consideration; it is not always easy to replicate the clinical environment in the laboratory. Therefore, we need to be reminded that it is not accurate to consider the laboratory results sufficient to start manu-

facturing, promoting and eventually using some products that may later be discovered to have some major deficiencies.

Denying the simple rules of treatment just for the sake of marketing is not right. Our only goal should be to deliver the best treatment for our patient, bearing in mind that a miracle product is not yet (and may never be) available and that each product has its limitations and indications. Doctors should understand this, and companies as well.

Clinical results should be our gold standard for any treatment, since what may work on paper and in statistical analysis may, sadly, fail in a patient.

Dr Philippe Sleiman
Guest Editor



Cover image courtesy of FKG
www.fkg.ch



editorial

In **patient or on paper?**
Dr Philippe Sleiman

03

trends & applications

Dynamic navigation—The future of minimally invasive **endodontics**
Dr Kenneth S. Serota

06

case report

Shaping a Type V mandibular premolar with VDW.ROTATE
Dr Vittorio Franco

10

Endodontic follow-up in strongly **curved root canals**
Dr Thomas Rieger

14

study

Tooth-preserving endodontic surgery—
A retrospective **survival study** from the general dental practice
Drs Robert Teeuwen & Monika Kriner

18

special

Diverse **applications** of **lasers** in dentistry
Dr Igor Cernavin

30

Treatment of oral **leukoplakia** with a **980 nm** diode laser
Dr Maziar Mir, Prof. Norbert Gutknecht, Dr Masoud Mojahedi,
Dr Jan Tunér & Dr Masoud Shabani

34

Facial swelling caused by infected teeth
Dual wavelengths for immediate healing
Dr Imneet Madan

36

interview

Irrigation in endodontics—**New standards** in the dental office

40

practice management

Successful **communication** in your **daily practice**
Part VIII: How to take away the patient's fears
Dr Anna Maria Yiannikos

42

meetings

International events

46

about the publisher

submission guidelines

48

international imprint

50

THE NEW NiTi FILE GENERATION

HyFlex™ CM & EDM

Stays on track

- Safer use
- Preparation following the anatomy
- Regeneration for reuse

BIOACTIVE SEALING AND FILLING

GuttaFlow® bioseal

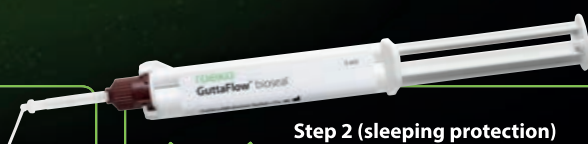
Double safety level

- Cost efficient root filling
- Excellent flow properties even at room temperature
- Fast working, fast curing, safe sealing (about 12-16 minutes)



Step 1 (direct protection)

Protection already at filling, e.g. with bioactivity due to possible residual moisture in the root canal



Step 2 (sleeping protection)

Regenerative protection against possible moisture ingress, e.g. by cracks

Dynamic navigation—The future of minimally invasive endodontics

Dr Kenneth S. Serota, Canada

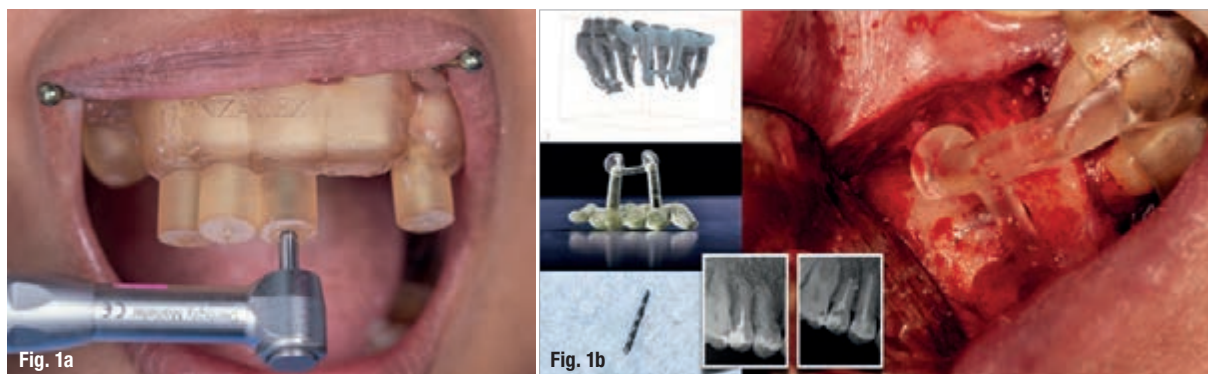

Fig. 1a: Static navigation stent used for endodontic access cavity preparations. The pre-planned stent does not allow for reorientation of the drill during the preparation. This can be consequential in accessing calcified, sclerosed canals. (Courtesy of Dr Paula Villa) **Fig. 1b:** Three-dimensional stent printed for static navigation guidance to facilitate removal of an instrument in the periapex. Stents are cumbersome, bulky and restrictive in posterior regions. Once planned, the osteotomy path cannot be altered. (Courtesy of Dr Hugo Sousa Dias)

Dynamic real-time surgical navigation

Digital imaging, diagnostics and impressions, and the use of computer-aided design/computer-aided manufacture (CAD/CAM) for prosthesis fabrication and lasers for

soft and hard tissue augmentation are altering the developmental framework in dentistry.¹⁻⁵ Nowhere is this more prevalent than in the foundational pillar of endodontics.

The magnification and illumination properties of surgical operating microscopes enhance the accuracy of freehand navigation access cavity preparation and microsurgical osteotomy. This has engendered a transformational shift to conservative, more restricted endodontic access cavity preparation.⁶ This preserves coronal and radicular tooth structure by optimising the long-axis entry point, the drill angulation and the glide path to the terminus of the root canal space.

Limitations

In spite of these advances, there are limitations in endodontic clinical scenarios where canals sclerotically regress in a coronal-apical direction and surgical access is space restricted. While the clinician's experience is a positive factor, altered vertical and lateral angulation of the long-axis orientation of the endodontic access cavity presents iatrogenic risk. In endodontic microsurgery, a small bone volume or a misdirected osteotomy can injure the inferior alveolar nerve or perforate the maxillary sinus and other critical anatomical structures.^{7,8}

The advent of cone beam computed tomography (CBCT—DICOM files) and 3D printing has transformed pretreatment planning. DICOM files are converted into stereolithic files,

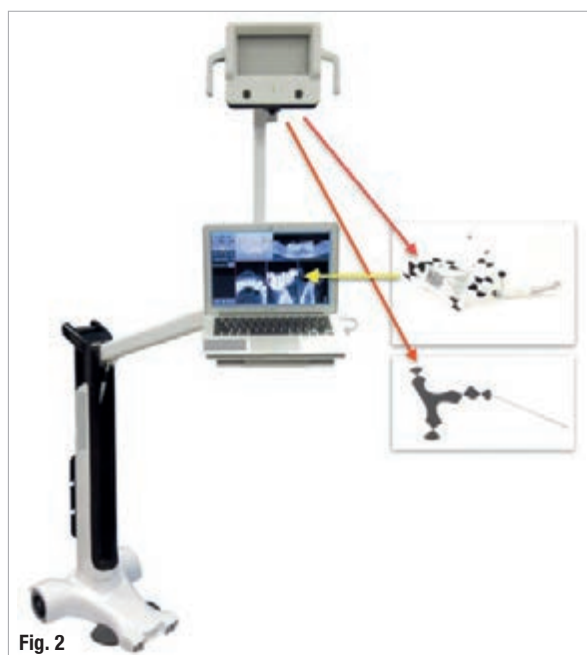

Fig. 2: An optical tracking sensor tracks the Jaw-Tracker, Tracer-Tracker, Drill-Tracker and instrument.

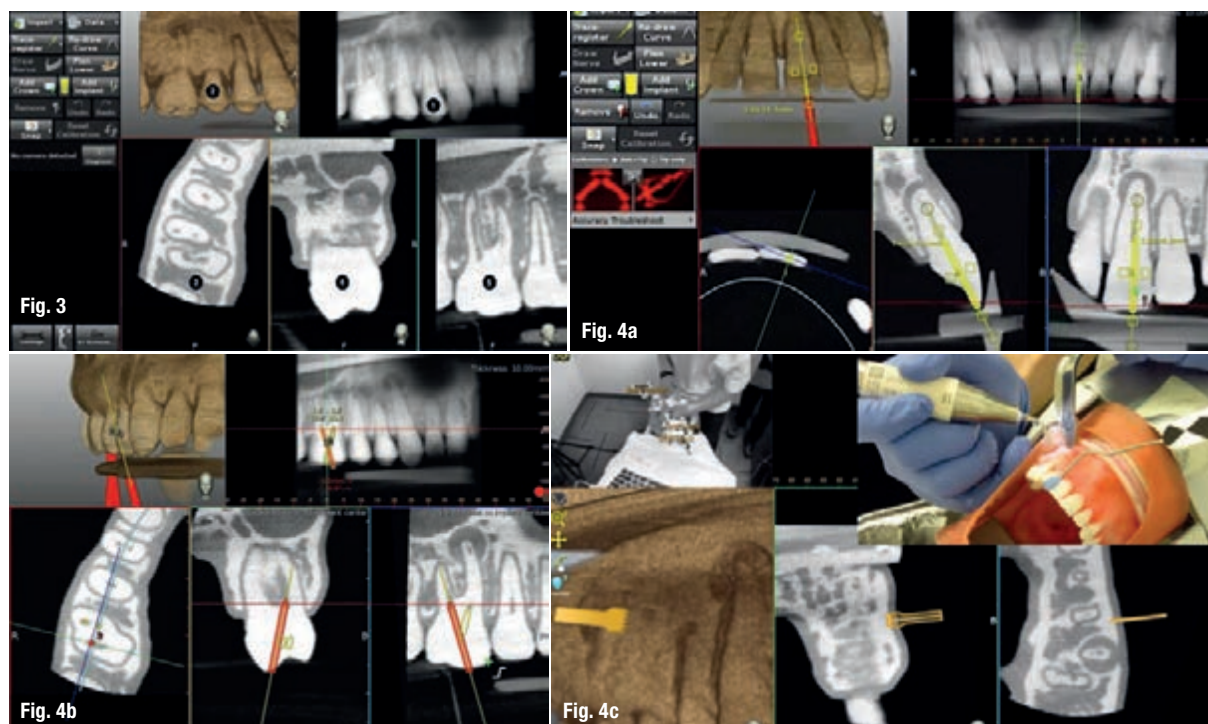


Fig. 3: The screen is divided into (1) panoramic view, (2) 3D reconstruction, (3) axial view, and (4) buccolingual and (5) mesiodistal section views. **Fig. 4a:** The planned axis angulation and orientation of the virtual drill are exacting in targeting calcified canals. (Courtesy of Dr Bobby Nadeau) **Fig. 4b:** The red virtual pathway reflects an off-angle positioning. (Courtesy of Dr Bobby Nadeau) **Fig. 4c:** Piezotome planning. (Courtesy of Dr Bobby Nadeau)

which are used to create static navigation stents (CAD/CAM-fabricated). The stents direct the access cavity preparation and microsurgical orientation, thus avoiding removal of unnecessary tooth and bone structure (Figs. 1a & b).

Dynamic navigation offers new prospects for computer-guided endodontic protocols. Enhanced accuracy owing to real-time feedback diminishes the complex impact of access cavity preparation of calcified canals, retreatment and microsurgical procedures.^{9–11}

Each navigation protocol has disadvantages. With free-hand navigation used for dentoosseous access and surgery, clinical judgement is the pilot. Freehand navigation depends upon visualisation of the anatomical scenario from information provided by casts and radiographs. Significantly more time is required with a freehand navigation technique in contrast to a guided technique. Determining the canal path position is more complex.

Stereolithic stents (static navigation) require a medium field of view CBCT scan. Polyvinylsiloxane impressions of

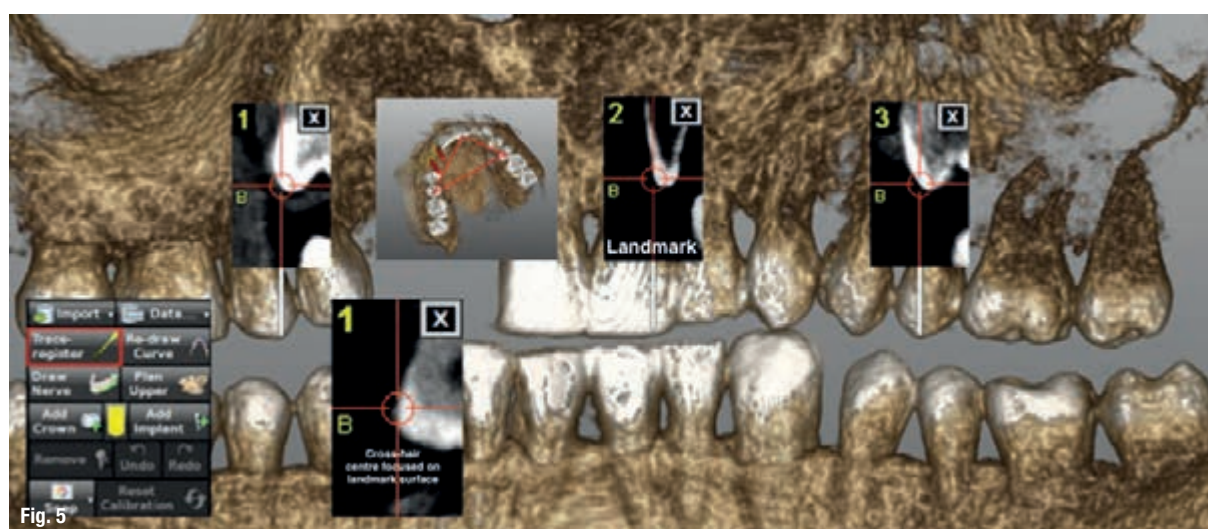


Fig. 5: The three landmarks chosen are not collinear, and the centre of the thin red cross-hair that appears is focused on the surface of the landmark.




Fig. 6




Fig. 7

Fig. 6: (1) The Jaw-Tracker is installed. (2) During tracing, the system presents the percentage sampled up to 100%. **Fig. 7:** The Tracer-Tag and the Tracer-Tool are attached, the Tracer-Tool calibrated. The software shows the number of points contacted as a percentage.

the arch to be treated are poured and a digital 3D scan of the stone model merged with the patient's DICOM files. The use of an intra-oral scanner is preferable.

In the case of dynamic navigation, virtual planning of the endodontic access preparation or the osteotomy can be affected by the resolution of the CBCT scan.¹² Flaws in the process of fiducial integrated stent fabrication can result in inaccurate image acquisition.

Innovation navigation

Dynamic navigation facilitates real-time computer guidance technology using an imported CBCT data set. This is analogous to the use of GPS and satellite navigation. An innovative computer-guided technology, Trace and Place (TaP), has been developed by the Canadian company ClaroNav. TaP obviates the need for a fiducial stent, with the resultant increase in the accuracy of dentoosseous penetration. An optical tracking device (Fig. 2) tracks a Jaw-Tracker, the optical tracking tag connected to the patient's jaw, and a Drill-Tag, which is the optical tracking tag connected to an instrument specific to the procedure. The tip is superimposed on the CBCT scan, which is mapped to the patient's jaw.

The heightened level of accuracy of TaP technology enhances the facility of treatment for restricted access cavity preparation and minimises the size of cortical window osteotomies (high-speed; Piezotome, ACTEON). Ultrasonic

tips used for root end retro-preparation can also be tracked by dynamic navigation software.

TaP workflow planning and trace registration

Estimates place the global population over 65 at 615 million.¹³ Years of dentate and periodontal disease can impact on the pulp, the periapex and the periradicular tissues. With longevity will come increasing numbers of a mosaic of endodontic procedures, as age and treatment induce sclerotic changes in the root canal space. As such, the use of dynamic navigation will prove to be of significance in a myriad of endodontic treatment protocols.

Prior to the appointment

The first stage of TaP workflow is the importation of the patient's CBCT data set (as DICOM file) into the dynamic navigation planning software to reveal the dentition. The screen shows the streaming video, panoramic view, target view, depth indicator, and buccolingual and mesiodistal section views (Fig. 3). The access point of entry, the axis orientation/angulation and the depth of the access cavity are planned. For microsurgical procedures, the Piezotome pathway is based on the dimensions of the osseous pathology surrounding the root apex (Figs. 4a–c). The planning stage can be done at any time prior to the procedure, provided the CBCT scan is consistent with the current dentate condition. As a preliminary step prior to the trace registration, three to six trace starting points (landmarks) are chosen and marked on visible and accessible teeth.



Fig. 8a



Fig. 8b

Fig. 8a: Calibration of the drill axis and the instrument tip. **Fig. 8b:** The Drill-Tag (optical tracking tag).

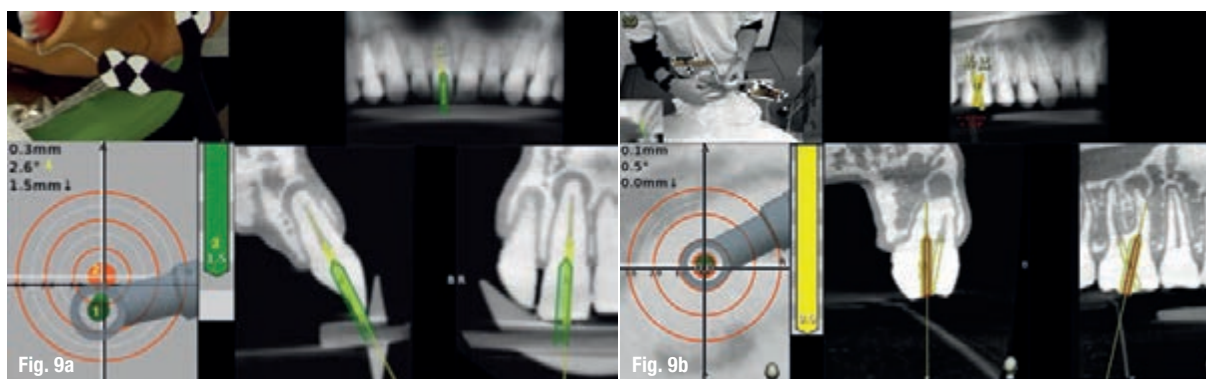


Fig. 9a: Calcified central incisor: (1) the drill is green; (2) the central axis of the glide path or osteotomy; (3) the depth indicator; (4) the angle between the drill and central axis of the planned osteotomy. When the drill and the central axis overlap, the depth indicator turns yellow. (Courtesy of Dr Bobby Nadeau) **Fig. 9b:** Maxillary molar: the planned canal location is on target (yellow: 0 mm). (Courtesy of Dr Bobby Nadeau)

When the computer mouse is positioned over the 3D model, a 2D cross-sectional view appears. The red cross-hair sticks to the landmark, its centre on the surface (Fig. 5). The software advises the clinician if it suspects that the landmark is in an incorrect position.

Trace registration

The Jaw-Tracker (mandible or maxilla) or Head-Tracker (maxilla) is securely fastened to the jaw to be treated (Fig. 6). It should be noted that the Jaw-Tracker can be positioned at a distance from the rubber dam, unlike a Jaw-Tracker attached to a fiducial stent, which is more positionally restricted. Once the three landmarks have been determined, the optical tracking sensor tracks the Tracer-Tag/Tracer-Tool as it is brushed around the landmarks on the facial, lingual and occlusal surfaces in a manner similar to applying etching or bonding solutions. The software shows the number of points contacted as a percentage (Fig. 7).

Calibration of the drill

The Drill-Tag is attached to the handpiece, and the drill axis and drill tip are calibrated. The optical tracking sensor continuously tracks the Drill-Tag, and the software shows the position of the drill or Piezotome. The software will issue a warning if the Drill-Tag or the Jaw-Tracker is out of view of the camera (Figs. 8a & b).

Dentoosseous real-time navigation

The navigation screen is active when the system identifies the calibrated instrument as it approaches the patient's jaw. The target view measures the distance between the instrument's tip and central axis of the designated access penetration point, the glide path or the osteotomy. The central axis length of the planned procedure is represented by the centre of the static white target, and the tip of the drill is indicated by the moving black cross following the drill tip movement. The real-time direction of the drill is represented as a cone in the head of the handpiece (Figs. 9a & b).

During the drilling, the moving cross and cone are tracked. The cone will turn green when the instrument tip is within 0.5 mm and has an angulation of less than 3° to the planned glide path or osteotomy. When the drill tip reaches a distance of 1 mm from the apical or horizontal extent of the planned depth landmark, the depth indicator turns yellow.

Conclusion

Dynamic navigation is an additional value chain in digital workflow sequencing. Minimally invasive protocols are the trajectory of dentistry's future. Dynamic navigation is proving to be both the pilot and co-pilot of this new milestone in patient-centric care. All innovation requires seminal exploration of both the incentives for and barriers against prior to acceptance of a new technology as a contributing protocol. Early adoption is osmotic: general acceptance occurs by diffusion. Improvements in the resolution of computer screens, optical markers and the reference array will herald an unprecedented level of accuracy in endodontic procedures. Digital has replaced analogue as the societal norm. The transition in the dental profession is in process.

Editorial note: A list of references is available from the publisher.

about



Dr Kenneth Serota obtained his DDS from the University of Toronto Faculty of Dentistry in Canada in 1973 and received his Certificate in Endodontics and Master of Medical Sciences from the Harvard-Forsyth Dental Center in Boston in Massachusetts in the US. Active in online education since 1998, he is the

Founder of the ROOTS endodontic forum (started in 2000) and the NEXUS interdisciplinary forum. Dr Serota is an adjunct clinical instructor in the University of Toronto postdoctoral endodontics department. He has been a contributor to and author of clinical articles for the **roots** magazine since its launch in 2004.