

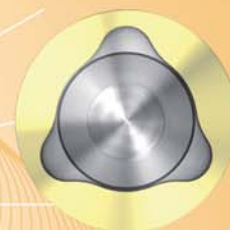


implants

international magazine of oral implantology

1 2010



| case report

Dental Implants—Treatment options for compromised clinical situations

| case report

Safe and effective alternatives to sinus elevation in the atrophic posterior maxilla



| meetings

7th Conference of the Australasian Osseointegration Society



80 Ncm

Powerful for surgery



The new Elcomed from W&H: logical and easy to use. Uncompromising in performance: with a torque of up to 80 Ncm on the rotating instrument, the surgical drive unit guarantees smooth usage, which can be completely documented at no further cost thanks to an integrated USB interface. These are just three of the many advantages of the new W&H Elcomed.

wh.com

elcomed
Captivation and precision

Dear Colleagues,



Dr Friedhelm Heinemann

The new year has just begun, and will be characterized by very special challenges. One thing is already certain—not all economic problems caused by the banking crisis will be solved in 2010. Many large-scaled problems need to be solved in respect to general economic conditions, and also in regard to health policy. Since it is a mostly privately financed treatment, even implantology, is a focal point. However, with the integration of implantological treatment in your practice's portfolio, you have already established an important basis for your existence.

Even so, implantologically active dentists must concentrate on concepts and strategies for further development of their "dental practice business" in the future. At the moment, industry is setting a new technological course, which is of crucial importance for long-term developments in dentistry in general, and implantology in particular. Through linkages in 3-D diagnosis, navigation, planning, and even CAD/CAM manufactured prostheses, opportunities are constantly growing emerging in the field of prosthetic implantology; implying a redefinition of the cooperation between dentist and dental technician.

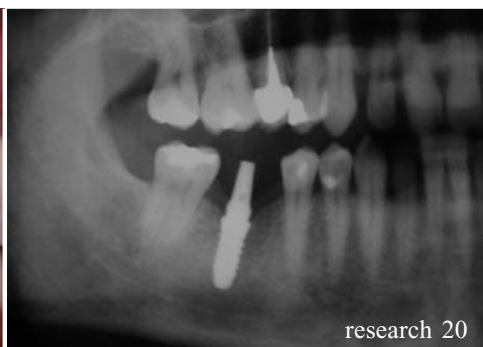
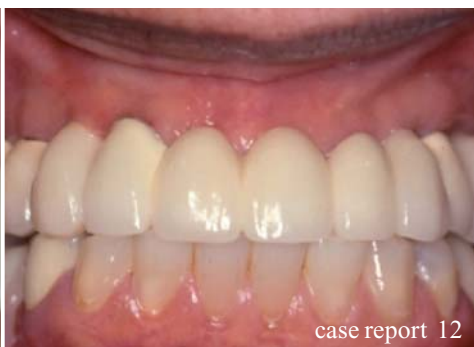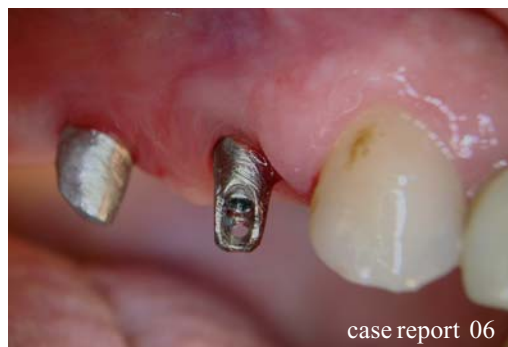The occupational image of dental technicians has been changing and extending for quite some time, due to the digital capabilities of technicians, and a growing number of dental laboratories that realize the great opportunity in their skills. In this context, dental technicians increasingly consider themselves to be digital service providers for dentists. Technicians invest in techniques and offer new cooperation platforms, which broadens and improves already established procedures. These make them into competent and professional partners for dentists, especially when it comes to finding complex restoration alternatives in implantology and implant prosthetics. In addition, technicians support dentists in diagnosis and in the course of treatment. This intensive cooperation between dentist and his local dental technician leads to high esteem, and recommendation of the patients.

One prerequisite for taking advantage of technicians' services, however, is for dentists to be in a position and willing to accept the offered service, and integrate it into everyday practice. Thus, the implantologist must face the applicabilities and the limits of planning systems, and learn to make practical use of them. Nevertheless, it is the treating dentist who is responsible to the patient, even with regard to applied digital techniques. The dentist will have to combine his operative expertise, practical skills and medical knowledge and add modern techniques to his work. This will make his work become much more complex but more interesting at the same time.

DGZI's infrastructure, with its multiple possibilities for professional training in this field is well prepared to address this emerging situation, and we will continue to expand our programs to help meet members' needs.

Yours,

Dr Friedhelm Heinemann



| editorial

- 03 Dear **Colleagues**
| Dr Friedhelm Heinemann

| case report

- 06 Safe and effective alternatives to **sinus elevation**
in the atrophic posterior maxilla—Part II
| Dr Adel A. Chidiac
- 12 **Dental implants**—Treatment options for
compromised clinical situations—Part II
| Suheil M. Boutros
- 16 The treatment of **toothless jaws**
| Dr Sven Rinke

| research

- 20 The concept of “**platform switching**”
in implants dentistry—Part I
| Virgil Koszegi Stoianov

| user report

- 26 Cross-linked or natural collagen **membrane?**
| Dr Heike Wanner
- 28 **Buccal dehiscence and sinus lift cases**
| Dr Sérgio Alexandre Gehrke & Dr Giuseppe Maria Famà

| feature

- 32 “**Patients’ satisfaction** towards functional
Reconstruction is very high”
| Daniel Zimmermann
- 34 Filipino specialists back up plans for **improved
implant education**
- 34 CEREC 25th **Anniversary Celebration** in Las Vegas

| meetings

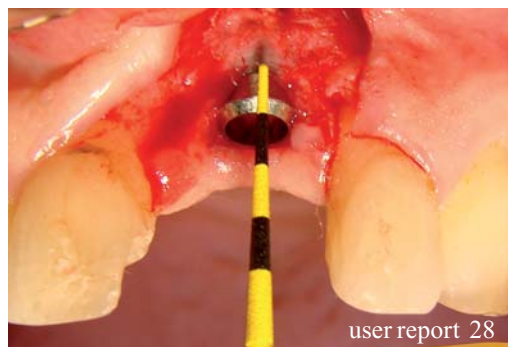
- 36 7th Conference of the Australasian Osseointegration
Society
| Dr Rolf Vollmer & Dr Mazen Tamimi
- 38 ITI World Symposium 2010
- 40 **International events 2010/2011**

| news

- 42 **Congratulations** and **Happy Birthday** to all DGZI-
members around the world
- 44 **Manufacturer news**

| about the publisher

- 49 | submission guidelines
- 50 | imprint



NobelReplace™

The world's most used implant system.*

Internal tri-channel connection for accurate and secure prosthetic restorations.

TiUnite® surface and Groovy™ to enhance osseointegration.

Implant design that replicates the shape of natural tooth roots.



Color-coded system for accurate and fast component identification and ease of use.

Color-coding: step-by-step drilling protocol for predictable surgical procedures.

10 YEARS WITH
TIUNITE® SURFACE
New data confirm
long-term stability.

* Source: Millennium Research Group

Versatility, ease-of-use and predictability have made NobelReplace Tapered the most widely used implant design in the world.* NobelReplace Tapered is a general use, two-piece implant system that performs both in soft and hard bone, one- and two-stage surgical procedures, while consistently delivering

optimal initial stability. NobelReplace Tapered is a system that grows to meet the surgical and restorative needs of clinicians and their patients – from single-tooth restorations to more advanced multi-unit solutions. Whether clinicians are just starting or are experienced implant users, they will benefit from a system that

is unique in flexibility and breadth of application. Nobel Biocare is the world leader in innovative and evidence-based dental solutions. For more information, visit our website.

www.nobelbiocare.com

Safe and effective alternatives to **sinus elevation** in the atrophic posterior maxilla

Part II—A master thesis

Author_Dr Adel A Chidiac, Kuwait

Fig. 1 _Diagram of implant insertion in the maxilla.

a _Conventional straight vertical position

b _Mesio-distal angulations of the implants permitting longer implants posterior as well as better distal support of the denture.

Fig. 2 _Sagittal cross-section reconstructed perpendicular to the alveolar crest. From the 4-mm level (1), the distance to the bottom of the maxillary sinus and the nasal cavity (2) can be determined.

Fig. 3 _Presurgical radiography.

_Maxillary sinus elevation and bone augmentation are acceptable techniques that may provide sufficient bone quantity and quality for implant support in the posterior atrophic maxilla (Wallace SS et al. 2003). Yet, given the morbidity risk plus cost and time consuming effects, these techniques are to be reconsidered. Simpler and safer protocols are therefore required for the posterior maxilla where bone resorption, deficient posterior alveolar ridge, and increased pneumatization of the sinus all result in a minimal hard tissue bed thus render implant placement difficult (Frank R et al. 2005).

Part I of this publication reported about the aim of the master thesis and materials and methods. Part II follows up with the surgical techniques, dis-

cussion and conclusions avoiding a sinus lift procedure.

_Surgical techniques

Tilted implants

The standard procedure is to install the implant, totally covered with bone, in a vertical position. This requires the bone volume in the maxillary alveolar crest to be at least 10 mm vertically and 4 mm horizontally. The success rates of implant treatments as per such procedure are 95 to 99 % (Triplett RG et al. 2000). In case of less bone volume, bone grafting is one of several procedures to reach the required bone volume. An alternative, however, was presented for severely resorbed alveolar crest (CI IV, V) in which im-

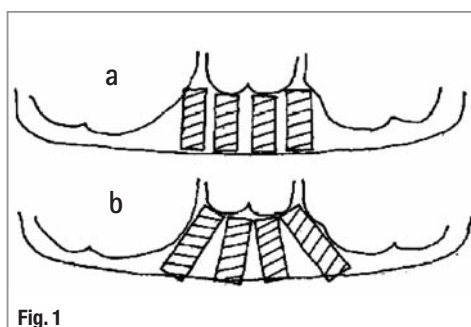


Fig. 1

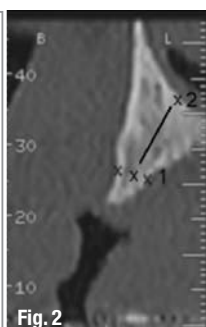


Fig. 2

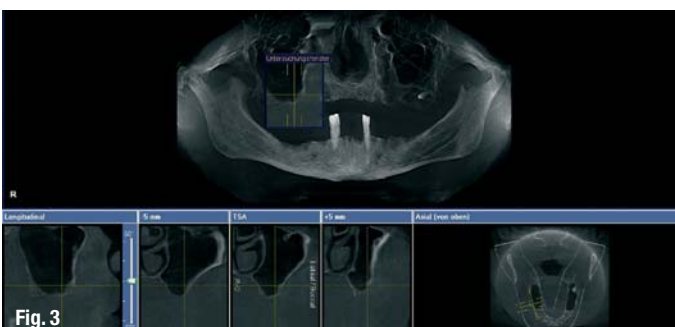


Fig. 3



Fig. 4a

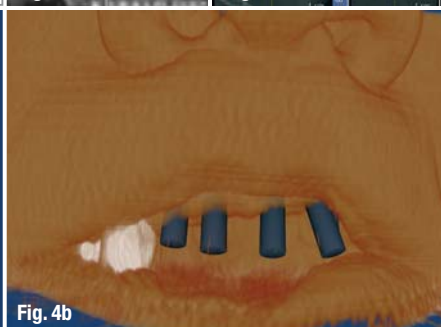

Fig. 4b

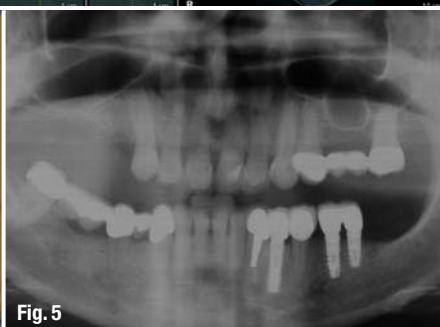

Fig. 5

plants were placed without bone grafting (Mattsson T et al. 1999). Theoretically, tilted implants in the residual crestal bone lead to (Aparicio et al. 2001):

- (a) Placement of longer implants that increases implant-to-bone contact area and implant primary stability;
- (b) Longer distance between implants that allows the elimination of cantilevers in the prosthesis thus improving load distribution;
- (c) Placement of implants in residual bone that avoids further complex techniques such as sinus lifting or bone grafting.

Clinically, the anatomy of the bone within the margins of the nasal cavity, the maxillary sinuses, and the alveolar crest margin all allow alternative mesio-distal angulations of implants. The height at the 4 mm width of an alveolar crest, being the measure to describe the available bone volume for total coverage of the implant, is often not enough for implant installation in severely resorbed maxillae.

Mesio-distal angulations of the implant thus provides better primary stability than conventional straight vertical positioning as it permits the use of a longer implant. A surgical technique was developed to make use of the maximum amount of available bone and to allow the installation of longer implants as indicated from computed tomography parasagittal reconstructions (Fig. 1; Mattsson T et al. 1999).

Mattsson et al. described a surgical technique to visualize the total amount of maxillary bone and to place posterior implants at a more than 30 degree

angle to the horizontal plane. By this technique the fixed bridge can be extended to at least the first molar position without previous bone grafting.

Presurgical examinations include a panoramic radiograph. Yet, in most cases, the extension of the maxillary sinus or the nasal cavity and the volume and density of the remaining bone are evaluated by maxillary computed tomography (Fig. 2). The estimation of bone quantity and bone quality is based on presurgical radiography and computer aided planning (Figs. 3 & 4) as well as on the resistance of bone to drilling during surgery (Kerkmanov et al. 2000).

Significantly, tilted implants can be anchored in the bone pyramid anterior to the maxillary sinus where anatomic vital structures, such as arteries or nerves, are absent. Multiunit implantation thus allows the extension of prosthetic support posteriorly and reduces cantilever arms. The results of biomechanical analyses and animal study indicate that tilting implants has no adverse effect on bone resorption (Gotfredsen K et al. 2001).

This alternative is in fact less time-consuming for the patient and the dentist; scientific investigations support the concept of immediate and early function as a modern therapeutic option (Testori T et al. 2004). Table 1 shows different degrees of angulations

| Number of implants per angulation | | |
|-----------------------------------|--------|------|
| Inclination | 15-30° | >30° |
| Mesiodistal | 0 | 23 |
| Distomesial | 4 | 0 |

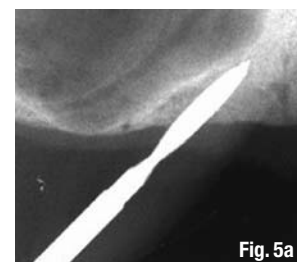


Fig. 4a Presurgical computer aided planning (IMPLA 3D).

Fig. 4b Presurgical soft tissue appearance (IMPLA 3D).

Fig. 5 Situation pre operation (Courtesy Dr R. & M. Vollmer).

Fig. 5a Drilling of the tilted implant site. Placing mesial axial implants before tilted ones. Intrasurgical radiographs or navigation are necessary to assess the precise drilling direction.

Fig. 5b After the pilot drilling for the tilted implant osteotomes are used for enlargement and final preparation of the implant site. First the axial implant was inserted.

Fig. 5c Tilted implant insertion following the direction of the initial hole.

Fig. 5d Tilted implant in site.

Fig. 5e Radiograph after insertion.

Fig. 5f Exposure and insertion of the abutments.

Fig. 5g Final result.

Table 1 Degrees of angulations of tilted implants.

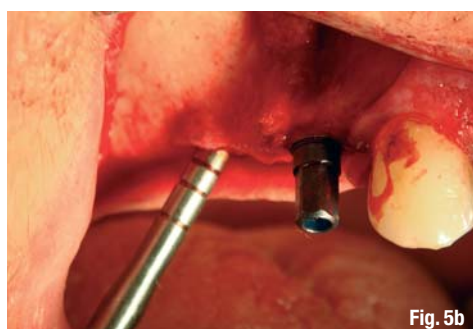


Fig. 5b

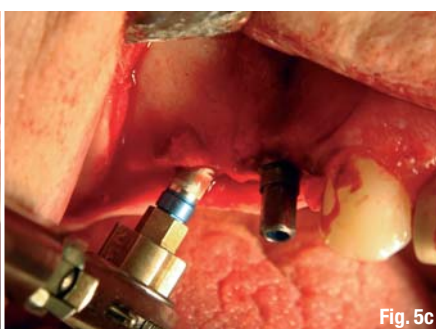


Fig. 5c

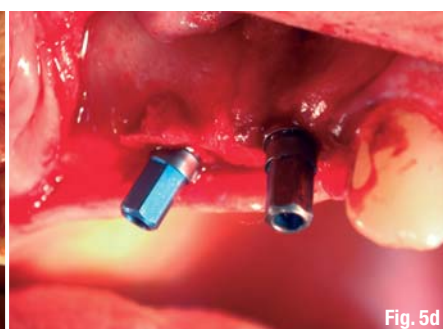

Fig. 5d



Fig. 5e

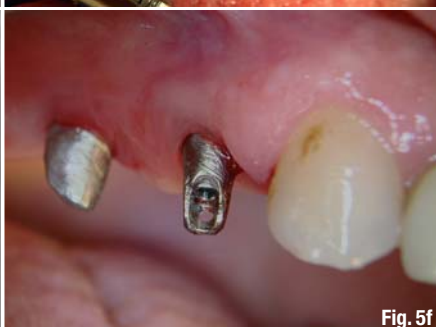

Fig. 5f

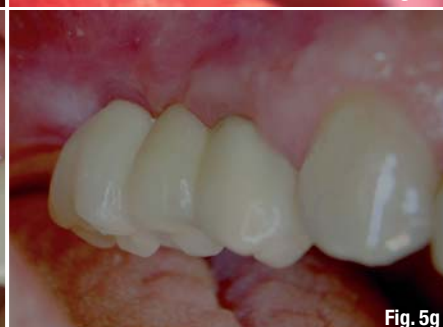

Fig. 5g

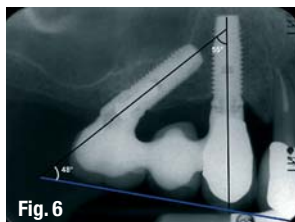


Fig. 6

Fig. 6 _Surgical placement of an axial implant following the anterior wall of the maxillary sinus is shown. The mesial axial implant will be the guide for the orientation of the tilted implant.

Fig. 7 _Implant inserted in the tuberosity.

Fig. 8 _Situation pre surgery with a small sinus situation.

Fig. 9 _Osteotomes.

Fig. 10 _Modified osteotomes (Zepf) for bone harvesting and condensing.

Fig. 11a _Insertion of modified osteotomes (Zepf acc. to Vollmer and Valentin).

Fig. 11b _Implants in site (IMPLA 3D, Schütz).

Fig. 11c _Fixation of the angulated abutment.

of tilted implants. Figure 5 (Vollmer R et al. 2008, Ca-landiello R et al. 2005), and Figure 6 illustrate the insertion of tilted implants (Aparicio C et al. 2001).

Tuberosity implants

Recently the maxillary tuberosity region has been increasingly utilized in preprosthetic implantation surgery especially when sinus floor elevation and bone grafting are rejected by patients due to high cost, longer healing time and increased risk of intra-operative complications. Implants, however, can be inserted in the maxillary tuberosity region as an alternative to sinus floor elevation (Fig. 7; Regeev E et al. 1995).

Osteotomy during the implantation in the maxillary tuberosity is most likely performed by an expansive and bone condensing technique with almost no bone removal like in the clinical case (Figs. 8 & 11a-e). Such osteotomy is certainly achieved in Type D IV bone acc. to the C. E. Misch classification in the tuberosity by avoiding drilling and thus reducing complications mainly hemorrhage from the palatine artery (Fernandez V. 1997).

Efficient in the maxillary tuberosity, Summers Osteotomes favor osseointegration by minimizing bone heating, dilating and compacting spongy bone, and maintaining the remaining maxillary bone (White GE 1993; Fig. 9). Summers osteotomes were modified to improve the access in the challenging areas through a double shaft design involving less pressure and less tension on the labial commissural. These modified

osteotomes allow obtaining best handling of the implant receiving site (Fig. 10; Valentin, Vollmer & Vollmer, 2002). Figures 11a-e demonstrate the final clinical case (Courtesy of Dr R. Vollmer & Dr M. Vollmer and Dr R. Valentin).

Disk implants

Disk Implant or basal osseointegrated implant can be installed where the vertical bone supply is reduced. This applies to the posterior areas of the maxilla (Ihde S et al. 2004). The insertion of the disk-design implant is laterally performed. The technique is less invasive than bone grafting and allows a tricortical or multicortical anchorage (Bocklage R. 2001).



Fig. 10

_Discussion

Short implants

Implantation in the atrophic posterior area of the maxilla is a challenge. The placement of short implants in this area is yet another alternative to sinus elevation and bone augmentation. The use of short implants (10 mm) has been a source of debate in the past decade. Some studies report higher failure rates with short implants; others report comparable results to longer implants (Buser D et al. 2000). Frequently affected by minimized bone volume, edentulous sites in the posterior maxilla prevent the placement of 10 mm implants without sinus augmentation. If shorter implants are used nevertheless, the need for more extensive sinus floor elevation is diminished and both treatment duration and morbidity are reduced (Toffler M. 2006).

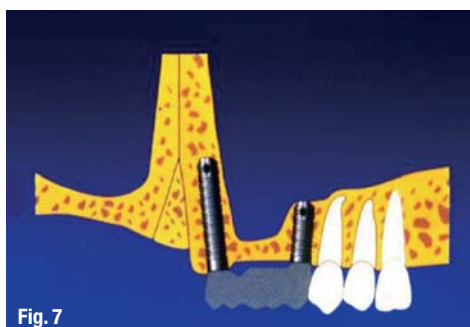


Fig. 7

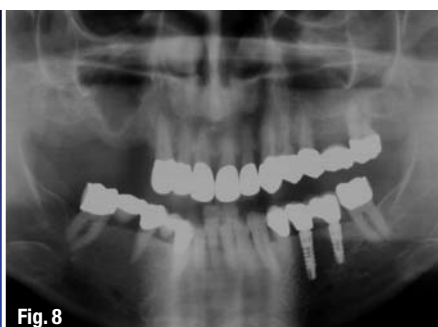

Fig. 8



Fig. 9

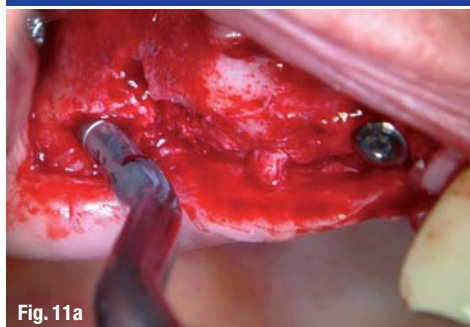

Fig. 11a

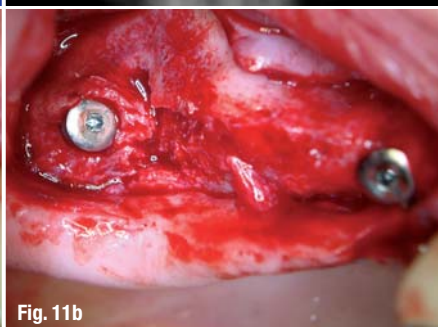


Fig. 11b

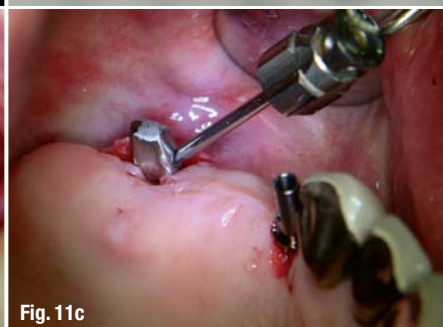

Fig. 11c

With the reduced amounts of bone, the use of long implants would be a difficult option. Although several studies in the literature have shown that short implants have risk factors therefore higher failure rate (Winkler S et al. 2005), the recent studies prove the good long term prognosis of short implants (Tawil G et al. 2006).

A review of the results displayed above show a range of success between 92 % and 96 % approximately. Failure rates were minimized by using the short implants due to several variables, including among others, change in implant design, splinting implants together, absence of cantilevers in the prosthesis, and additional methods to decrease stress to the implant interface. According to the same results, it is possible to use short implants to support fixed restorations in the atrophic posterior maxilla (Misch et al. 2006).

Implant sizes did not appear to compromise the effectiveness (Romeo E et al. 2006), and the short length was not associated with reduced survival rates (Arlin ML 2006). Researchers using finite elemental analysis (FEA) demonstrated that vertical and horizontal occlusal forces placed on implants were distributed primarily in the crestal bone rather than along the implant/bone interface. The group of Lum concludes that short implants serve as well as longer ones. Short implants show a survival rate exceeding five years and crestal bone level maintenance similar to longer implants. They can be successfully used in maxilla with limited bone length (Venuelo C et al. 2008).

Tilted implants

The results of applying the technique of using posterior tilted implants are comparable with the more resource demanding techniques applying bone grafting which often necessitates general anesthesia and hospitalization and could often lead to the following implications, including but not limited to, postoperative infection problems with the graft or maxillary sinusitis, host morbidity, lower implant success rates, and higher cost of treatment (Yerit KC et al. 2004). In fact, by tilting the posterior implants in the maxilla, the compromised bone of the sinus antrum could be circumvented with the clinical advantage of avoiding cantilever arms and using fewer implants (Calandriello R et al. 2005).

Mattsson et al. were the first to report well functioning fixed prostheses with no symptoms after treatment with the tilted implant technique (Annika R et al 2007). The success rate for the patients included in the study was 97%. Krekmanov et al also demonstrate that biomechanical measurements in tilting implants showed no negative effects on load

cosmetic dentistry _ beauty & science



One issue free of charge!



Subscribe now!

*Prices include shipping and VAT

☐ I hereby agree to receive a free trial subscription of **cosmetic dentistry** (4 issues per year). I would like to subscribe to **cosmetic dentistry** for € 44* for German customers, € 46* for customers outside Germany, unless a written cancellation is sent within 14 days of the receipt of the trial subscription. The subscription will be renewed automatically every year until a written cancellation is sent to OEMUS MEDIA AG, Holbeinstr. 29, 04229 Leipzig, Germany, six weeks prior to the renewal date.

► **Reply** per Fax +49-(0) 3 41/4 84 74-2 90 to OEMUS MEDIA AG or per E-mail to grasse@oemus-media.de

IM 1/10

Last Name, First Name

Company

Street

ZIP/City/Country

E-mail

Signature

Notice of revocation: I am able to revoke the subscription within 14 days after my order by sending a written cancellation to OEMUS MEDIA AG, Holbeinstr. 29, 04229 Leipzig, Germany.

Signature

OEMUS MEDIA AG Holbeinstr. 29, 04229 Leipzig, Germany

Tel.: +49-(0) 3 41/4 84 74-0, Fax: +49-(0) 3 41/4 84 74-2 90, E-Mail: grasse@oemus-media.de

