

Ortho

the international C.E. magazine of orthodontics

2²⁰¹²

_c.e. article

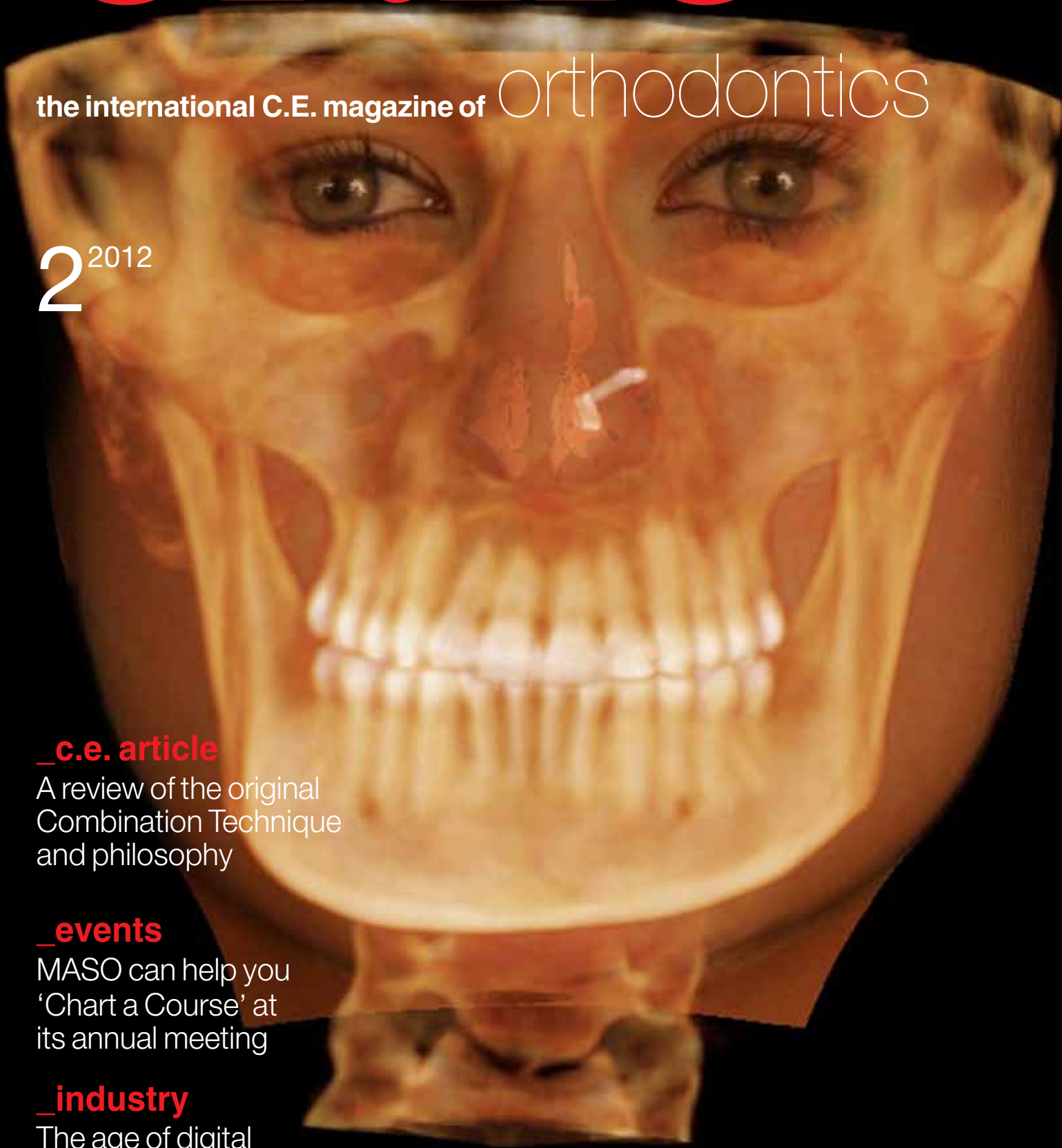A review of the original
Combination Technique
and philosophy

_events

MASO can help you
'Chart a Course' at
its annual meeting

_industry

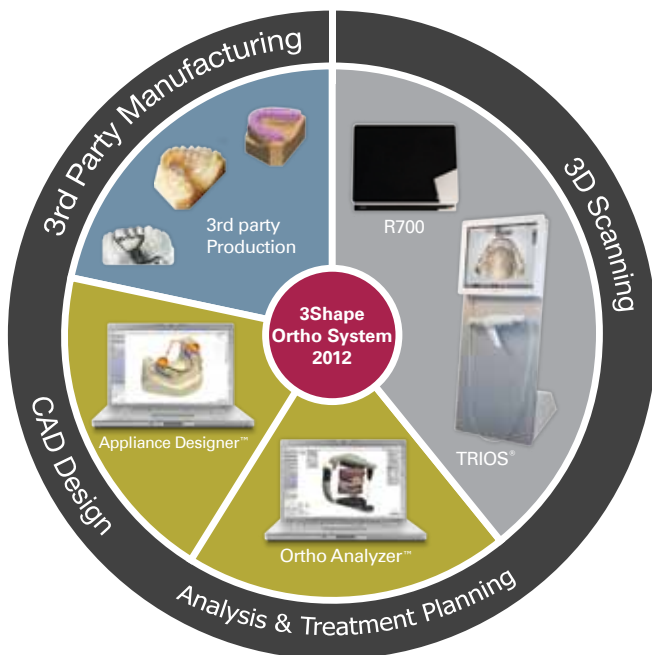
The age of digital
orthodontics is here





Closing the digital loop

The first open CAD/CAM system for orthodontics



3Shape TRIOS® is the new ultra-fast and easy to use chair-side scanner to create accurate digital impressions in open format.

3Shape Ortho System

- Intraoral scans, impression/model scanning, open format STL
- Customizable analysis workflows
- Full treatment simulation, including virtual setups
- Virtual articulators for easy validation
- CAD design of any orthodontic appliance
- Free choice of manufacturing equipment and materials

See the full digital loop at an exhibition near you



Scan the QR code
& sign up for our newsletter

Note: TRIOS® will be available in the US and Canada in 2012

ortho offers tips, hints and C.E. opportunities



Publisher Torsten Oemus

The goal of this quarterly magazine, *ortho*, is twofold. First, it seeks to share practical orthodontic knowledge that can be put to use in your day-to-day practice. Second, it is a vehicle to help you chip away at your continuing education (C.E.) requirements.

The amount of new information available in the orthodontic field about new products, techniques and research data is astounding. Running a practice and seeing patients leaves little time for catching up on the latest clinical news and product information. Thus, we hope *ortho* will not only be a welcome respite for those rare chunks of time you can devote to leisurely reading but one that provides a practical return on your investment by providing information that you can actually put to immediate use.

In addition, we know that taking time away from the practice to pursue C.E. credits can be costly in terms of lost revenue and time. As a quarterly magazine, *ortho* is here to help you chisel at least four C.E. credits per year out of your already busy life.

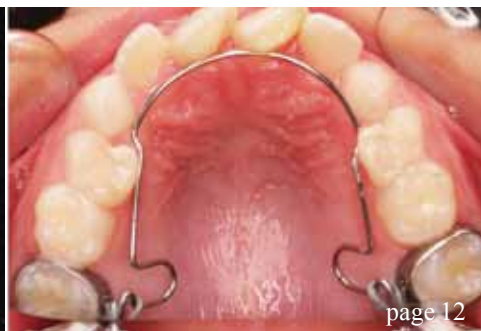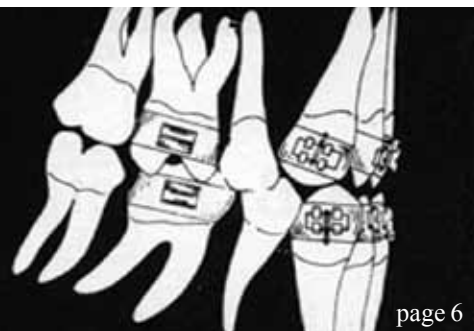
To that end, every edition of *ortho* will include at least one hour of ADA CERP-certified C.E. credit in which readers can answer questions about the materials at www.dtstudyclub.com to earn this credit. Annual subscribers to the magazine (\$50) need only register at the Dental Tribune Study Club website to access these C.E. quizzes free of charge. Even non-subscribers may take the C.E. quiz after registering on the DT Study Club website and paying a nominal fee.

If you are a practitioner with a penchant for words, it might also interest you to know that authors of the C.E.-accredited articles receive 15 percent of the fees collected from the non-subscribers who take the C.E. quiz online. The C.E. quiz for the articles in this edition will be available online on Sept. 17.

Dental Tribune America is part of the largest dental publishing network in the world, Dental Tribune International (DTI), which consists of 23 license partners around the globe. The DTI network publishes a variety of dental publications that are distributed in more than 90 countries. Please visit us online at www.dental-tribune.com to see the variety of publications we offer and at www.dtstudyclub.com to see the complete list of online and offline C.E. opportunities available. In the meantime, we hope you enjoy this edition of *ortho*, and we welcome your feedback.

Sincerely,

Torsten Oemus
Publisher



c.e. articles

- 06 A review of the original **Combination Technique** and philosophy
_Dennis J. Tartakow, DMD, MEd, EdD, PhD,
editor in chief, Ortho Tribune
- 12 How to **avoid extractions when treating malocclusions**
_German O. Ramirez-Yañez, DDS, PhD,
and Chris Farrell, BDS

subject

- 20 MASO can help you '**Chart a Course**' at its annual meeting
_Sierra Rendon, Managing Editor
- 24 **OrthoVOICE 2012** on slate for October

education

- 25 **Dr. Cristina Teixeira** named chair of the department of orthodontics at NYUCD

research

- 26 Study: 20-30 percent of **bib clips harbor bacteria** even after disinfection

charity

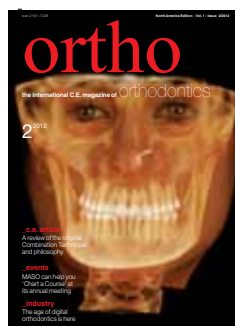- 30 ClearCorrect reaches new milestone with **charitable clean water project**

industry

- 32 **Edge management, imaging, communication system** from Ortho2: It's all you really need
- 34 Planmeca introduces a **new analysis tool** for planning orthodontic treatments
- 36 The age of **digital orthodontics** is here

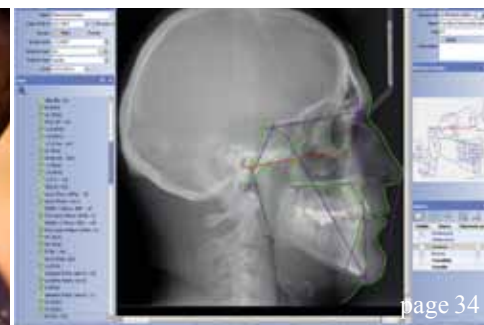
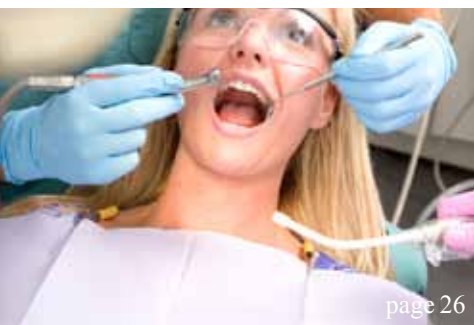about the publisher

- 37 _submissions
- 38 _imprint



on the cover

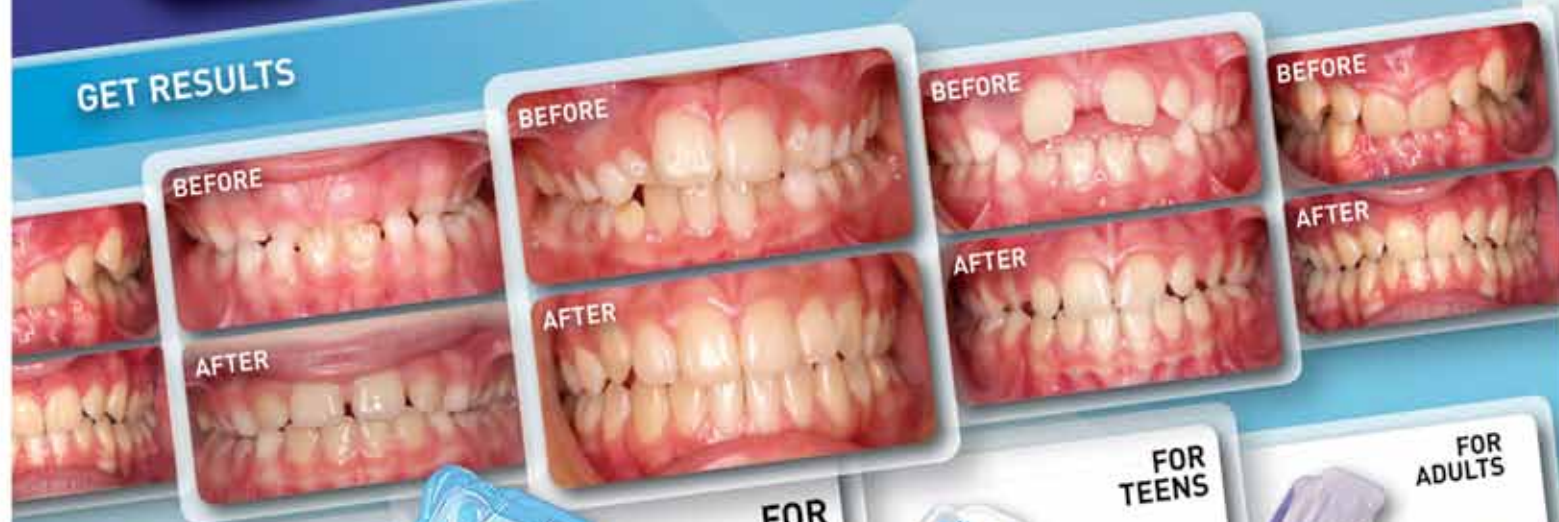Cover image/Provided
by Imaging Sciences



THE WORLD'S LEADING MYOFUNCTIONAL
ORTHODONTIC SYSTEM JUST GOT BETTER

myobrace®

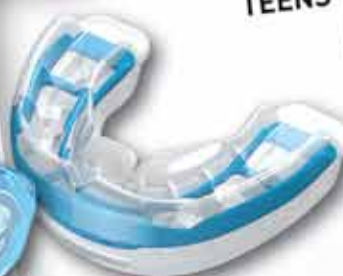GET RESULTS



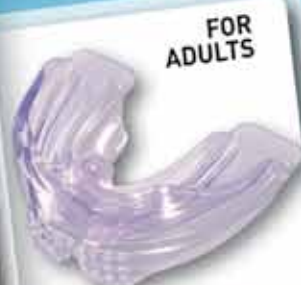FOR
JUNIORS



FOR
KIDS



FOR
TEENS



FOR
ADULTS

BECOME A MYOBACE® PROVIDER

- Treat a wider range of patients.
- Increase patient flow in your practice.
- Less chair-side time required.
- Financial benefits for you and your patients.

Visit: www.myoresearch.com/courses



FIND OUT HOW AT WWW.MYORESEARCH.COM OR PHONE 1866 550 4696

A review of the original Combination Technique and philosophy

Author_Dennis J. Tartakow, DMD, MEd, EdD, PhD, editor in chief, Ortho Tribune

_c.e. credit part I

This article qualifies for C.E. credit. To take the C.E. quiz, log on to www.dtstudyclub.com. The quiz will be available on Sept. 17.

Introduction

_During the 1960s, when the Begg lightwire and the Tweed edgewise were the mainstream techniques of orthodontic therapy, Dr. Maxwell Fogel and Dr. Jack Magill introduced their "Combination Technique" (Fogel & Magill, 1969).

The Combination Technique's philosophy was based on combining the positive and significant attributes of Begg lightwire and Tweed edgewise techniques to produce a system that corrected malocclusions quickly and easily for the orthodontist, with much less pain and a shorter period of time for the patient, while producing American Board of Orthodontics quality, standards and results.

_Outline of the Combination Technique

Stage I: Light-wire phase (Tipping)

1. Reduce protrusion
2. Un-crowd incisors
3. Open the bite (restore vertical dimension)
4. Class I molars and cuspids
5. Begin closing extraction spaces
6. Upright mandibular incisors
7. Cephalometric X-ray to check uprighing of the mandibular incisors

Stage II: Bracket alignment phase (Leveling)

1. Level and align maxillary and mandibular arches
2. Closure of extraction spaces
3. Preliminary uprighing of cuspids and bicuspid
4. Preliminary correction of rotations
5. Preliminary correction of axial positions

Stage III: Edgewise phase (Uprighting)

1. Detailed axial positioning of all teeth
2. Lingual root torque for labial axial inclination of the maxillary incisors
3. Root paralleling in extraction areas
4. Desired uprighing of molars
5. Artistic positioning of incisor segments
6. Complete correction of rotations
7. Residual space closure

Retention

Two years — indefinite

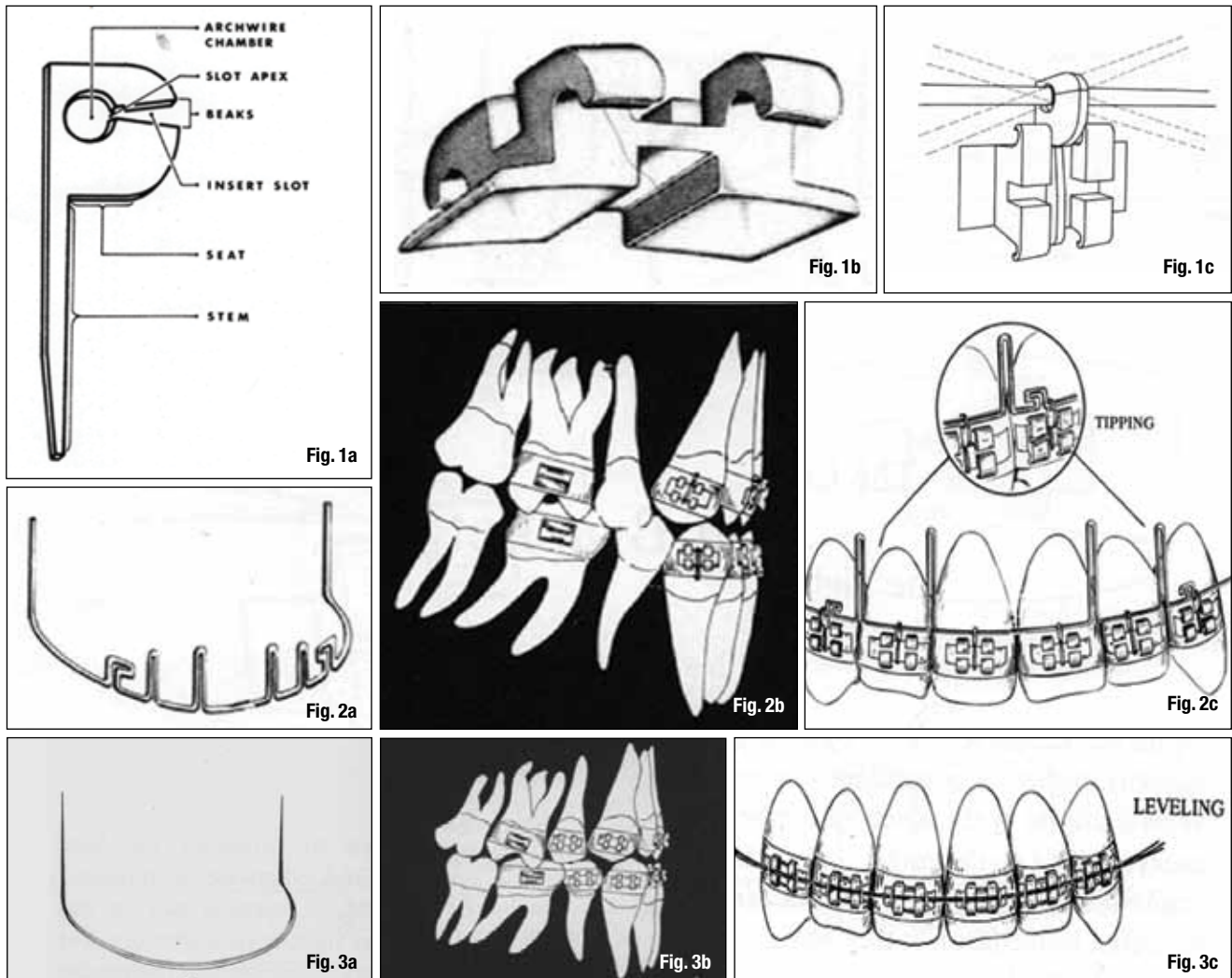
_Overview of the Combination Technique philosophy

The Combination Technique incorporated three stages of appliance therapy:

Stage I

The initial stage was called the light-wire or tipping phase, employing 0.014, 0.016 and 0.018 round wires, which required approximately four to eight months to achieve desired results. This first phase employed Dr. Raymond Begg's concept of light, continuous forces to uncrowd anterior teeth, open the bite (restore vertical dimension), reduce the protrusion, begin closing extraction spaces and uprighing mandibular incisors, all without straining the posterior anchorage unit. The Begg philosophy and mechano-therapy produced light, physiologic forces through the use of one-point contact, free-sliding, non-binding and continuously moving teeth that were connected to the archwire (Begg, 1961).

Drs. Fogel and Magill created this appliance by



uniting the light-wire vertical insert pin (Fig. 1a) with the widely spaced twin edgewise bracket (Fig. 2b) into a single appliance unit (Fig. 1c). The joining together of these two attachments enabled the development of a system for controlled light-wire therapy in the first stage of the Combination Technique. (All figures are from Fogel and Magill's "The Combination Technique in Orthodontic Practice.")

During Stage I (light-wire and tipping), a single light archwire with multiple loops and hooks was snapped into the vertical insert pins to produce simple tipping of the incisors, placing them in harmony with and upright over the apical base (Fig. 2a, 2b). This included correction of overjet, overbite and jaw relationships by means of controlled anchorage through the use of differential inter- and intra-arch elastic forces.

Stage II

The second stage was the called the leveling phase, employing a multi-stranded light wire, which

was later replaced by 0.014, 0.016 and 0.018 round flexible wires, ligated into the edgewise brackets, requiring approximately three to four months to achieve the desired results. This second phase included leveling and aligning maxillary and mandibular arches, closing extraction spaces, uprighting cuspids and bicuspid and correcting rotations of all teeth.

During Stage II (bracket alignment and leveling), a multi-stranded light-wire (Fig. 3a, 3b) was used to create controlled general alignment of all teeth, including leveling, correction of rotations, preliminary correction of axial positions, continued overbite correction and establishment of general arch form. Stage II prepared the brackets for the edgewise phase.

Stage III

The third stage was the called the edgewise phase, employing 0.016 x 0.016 square wires, followed by 0.017 x 0.025 rectangular wires, also ligated into the edgewise brackets and taking approximately six to 12

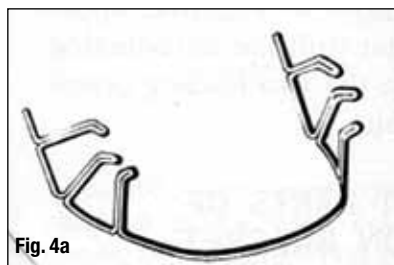


Fig. 4a

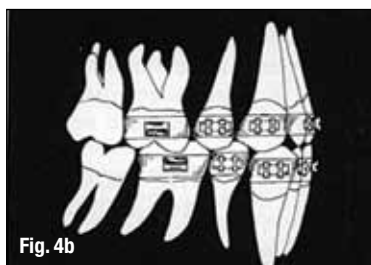


Fig. 4b

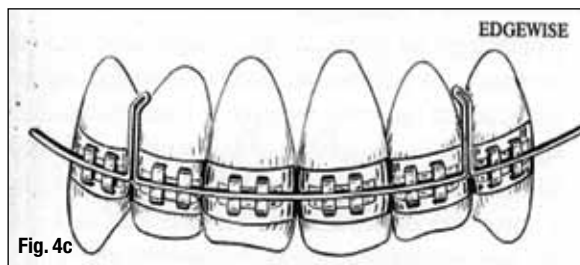


Fig. 4c




Fig. 5

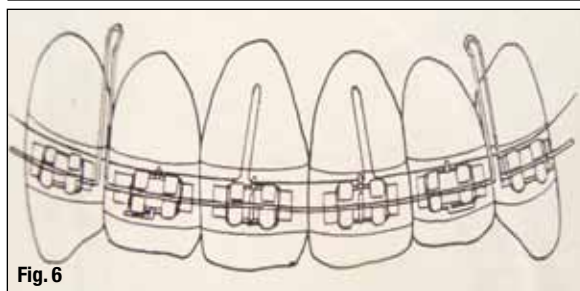


Fig. 6

months to achieve results. This third phase included detailed positioning, proper uprighting and ideal axial inclinations of all teeth. The Combination Technique was excellent for treating extraction cases and difficult malocclusions, as well as being very capable of obtaining outstanding results in non-extraction cases.

During Stage III (edgewise), the rectangular archwire (Fig. 4a–4c) was used to achieve ideal arch form and detailed axial positioning of both the crowns and roots of all teeth. This included: (a) root paralleling of teeth adjacent to the extraction areas, (b) uprighting of molar teeth, (c) artistic positioning of the incisor segments, (d) continued overbite correction if necessary, (e) final closing of residual extraction spaces, and (f) lingual root torque for labial axial inclination of the maxillary incisors.

Torquing auxiliary

During the correction of many severe malocclusions, the maxillary incisors required root torque as a result of lingual crown tipping. In order to accomplish incisor root torquing, an auxiliary wire was employed similar to that used by Dr. Begg during Stage III. The torquing auxiliary (Fig. 5) was an 0.014 wire

constructed with two loops in the same plane as the archwire, which when snapped into the insert pins placed the loops onto the maxillary central incisors slightly sub-gingival. After snapping the torquing auxiliary into the insert pins anteriorly (Fig. 6), it was cinched behind the molar tubes posteriorly.

This torquing auxiliary was used in addition to the main edgewise wire, which had been ligated into the horizontal slot of the widely spaced twin edgewise bracket to carry out the desired objectives of Stage III as well as providing anchorage and stability during the torquing procedure. The torquing auxiliary forces produced approximately one degree of lingual root movement per month. This was substantiated by cephalometric and visual examination.

Example of the Combination Technique in a severe malocclusion

Treatment of a Class II, Division I severe maxillary protrusion and deep overbite is shown, using maxillary first and mandibular second bicuspid extractions (Fig. 7a–7j).

Incisor coverage biteplate (Fig. 8a–8c) was required as a preliminary step as a result of the severe

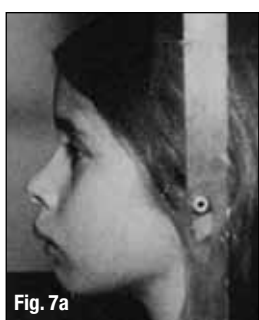

Fig. 7a



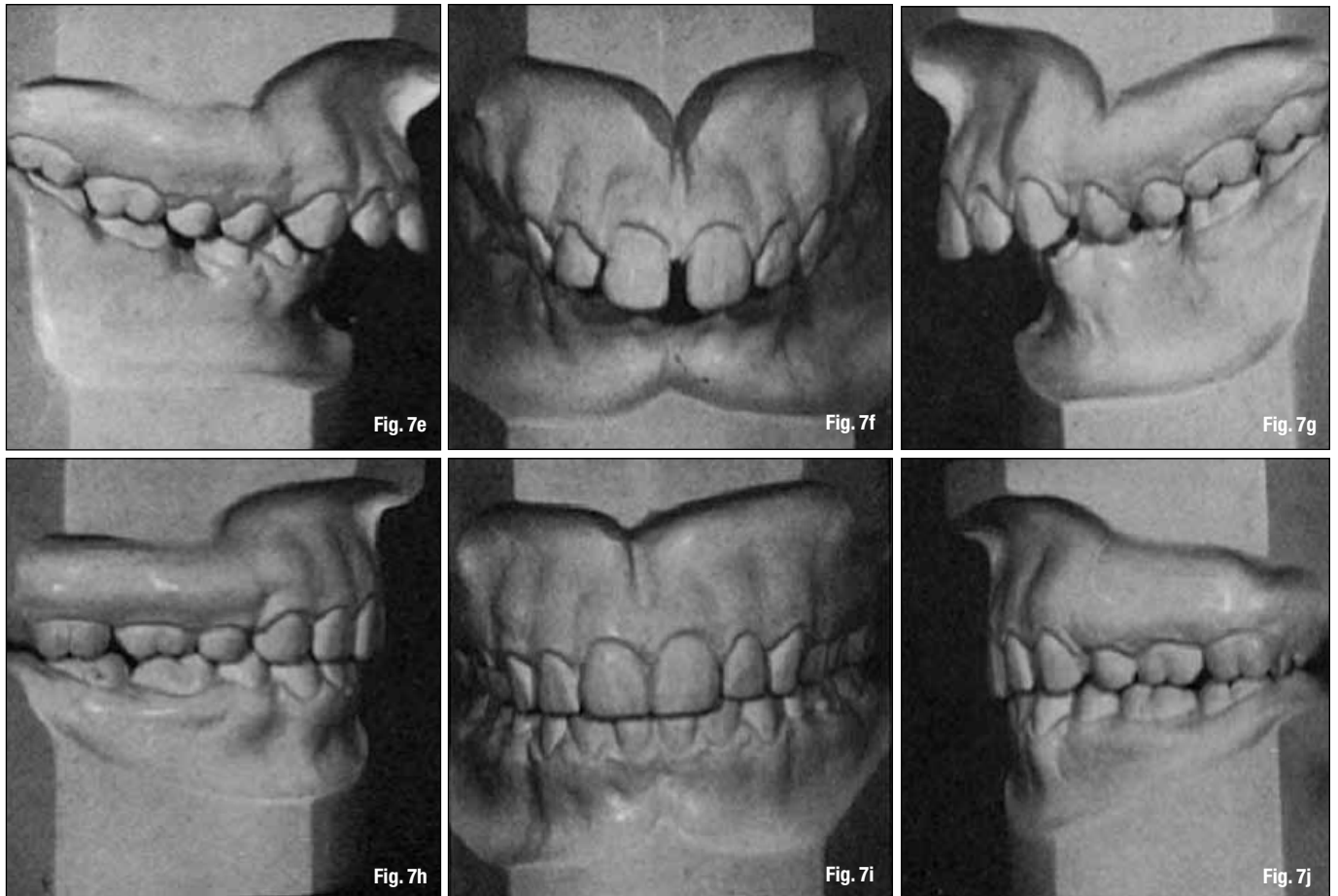
Fig. 7b

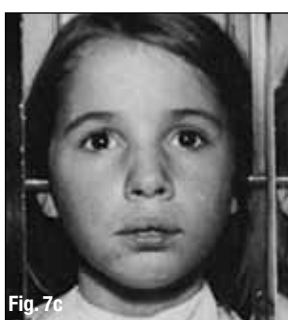

Fig. 7c



Fig. 7d



deep anterior overbite. This created initial bite opening and avoided shearing of brackets, tearing of bands and occlusal interferences.

Combination Technique mechanics

Stage I – Single strand light-wire stage (Figs. 9a–9c).

The objectives of Stage I were to achieve: (a) reduction of the protrusion (edge-to-edge incisor relation), (b) bite opening (molar uprighting and incisor intrusion), (c) incisor uncrowding and (d) Class I cuspid and molar relationships.

Stage II – Leveling with a multi-strand light-wire stage (Figs. 10a–10c).

The objectives of Stage II were to achieve: (a)

leveling and aligning of all brackets for edgewise archwire placement, (b) preliminary uprighting of cuspids and bicuspid, (c) correction of rotations and labiolingual malpositions, (d) continued bite opening, and (e) arch symmetry.

The advantages of the multiple leveling appliance when compared to the single strand wire included a longer range of action, better resistance for distortion, increased flexibility, gentler forces and less fatigue.

Stage III – Edgewise stage (Figs. 11a–11c).

The objectives of Stage III were to achieve: (a) a stable anchorage for Class II elastics, (b) correct axial inclinations, (c) root paralleling in extraction areas, (d) uprighting of the molars and bicuspid, (e) ideal arch form, (f) continued overbite correction and (f)

