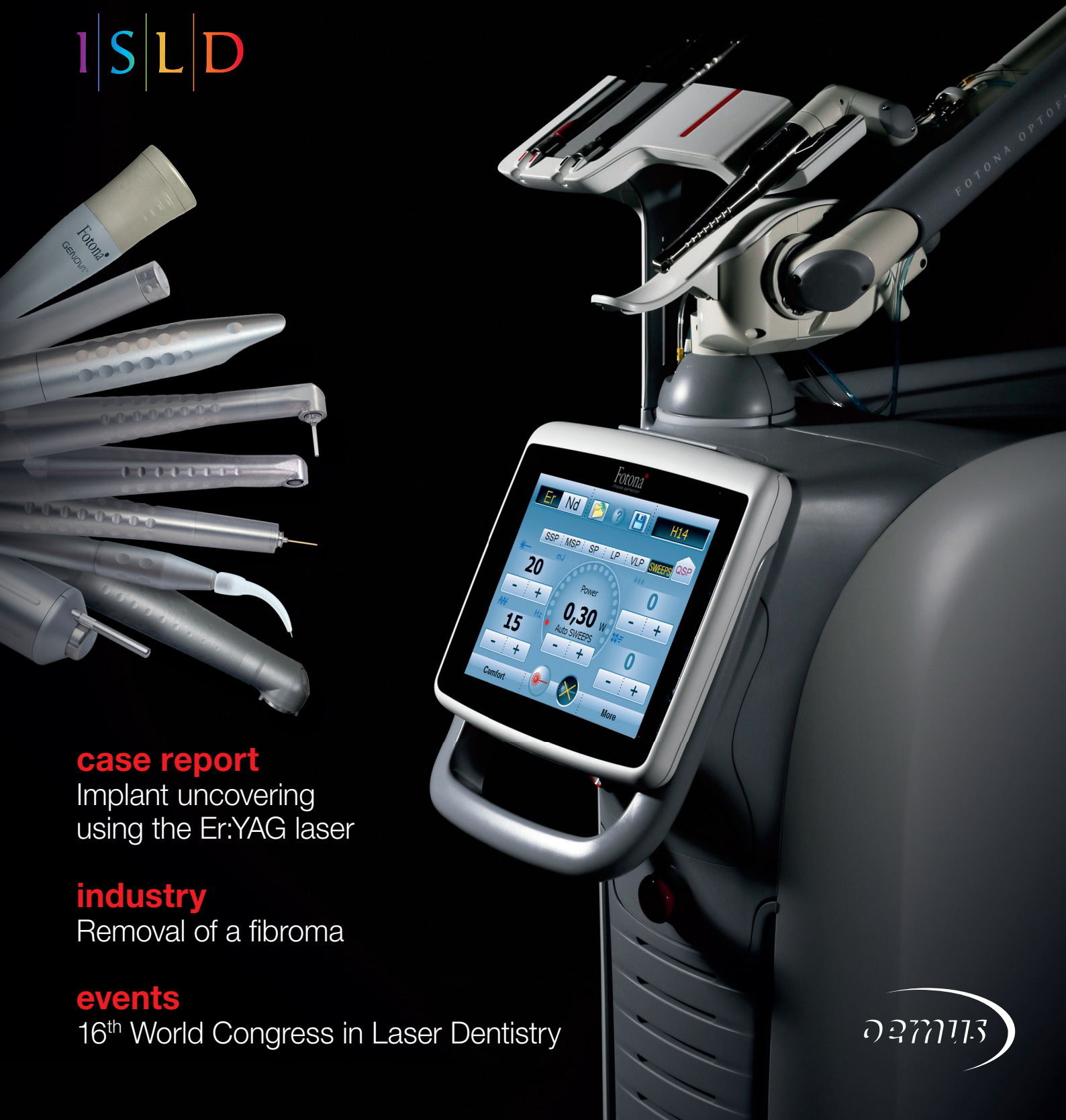

laser

international magazine of laser dentistry



I | S | L | D



case report

Implant uncovering
using the Er:YAG laser

industry

Removal of a fibroma

events

16th World Congress in Laser Dentistry





M.Sc. Lasers in Dentistry

Specialist in dental laser therapies

Next Start: **23rd September 2019** | Aachen, Germany | 4 semesters

Aachen Dental Laser Center - AALZ
Pauwelsstraße 17 | 52074 Aachen | Germany
phone +49241 47 57 13 10 | fax +49 241 47 57 13 29
info@aalz.de
www.aalz.de

RWTH International Academy
Kackertstraße 10 | 52072 Aachen | Germany
phone +49 241 80 23543 | fax +49 241 80 92525
info@academy.rwth-aachen.de
www.academy.rwth-aachen.de



Aachen Dental Laser Center

**INTERNATIONAL
ACADEMY**

**RWTHAACHEN
UNIVERSITY**

PROFESSIONAL EDUCATION PROGRAMMES

Your contact for more information: Leon Vanweersch • vanweersch@aalz.de - www.aalz.de

Prof. Dr Norbert Gutknecht

ISLD President



30 years of ISLD—an anniversary, a milestone and a new beginning

Dear friends of laser dentistry,

Back in 1988, laser pioneers from different countries met in Tokyo, Japan, to discuss the application of laser technologies in dentistry. Since there were already scientific associations for general medicine at that point, the idea was formed to found one for dentistry as well. As a result, the International Society for Laser Dentistry (ISLD) was born. This year, the ISLD celebrated its 30th birthday with the 16th World Congress in Laser Dentistry, which was held at the RWTH Aachen University in Germany. The event lasting multiple days was hosted by three associations: The DGL, the WFLD (in 2006, the ISLD changed its name to WFLD) and the WALED, an alumni organisation of the RWTH Aachen University.

The congress welcomed over 540 participants from 49 countries, 38 speakers and virtually all major laser manufacturers. Over the course of three days, 125 short lectures and 89 digital poster presentations were given. Looking back, it is not without a certain pride that we can say that the event was the largest and most successful congress in laser dentistry of the last thirty years. At the closing ceremony and the membership meeting, it was proposed to bring the name ISLD and the association's original organisational structure back to life, thus embracing its former academic dignity and scientific objective. By an overwhelming majority, the proposal was accepted and put into practice. The vast amount of incoming membership applications from entire national laser societies, private laser practitioners, as well as scientists from all over the world has exceeded everyone's expectations.

At last, the ISLD is the ISLD again. The society will continue to focus on scientific, academic and clinical issues regarding laser dentistry on a global scale—in medical, dental and social professional associations.

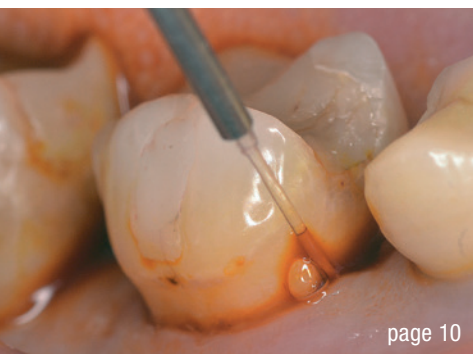At this point, I would like to take the opportunity to express my deepest gratitude to all visitors, speakers, exhibitors and my entire organisational team, who have contributed to making the World Congress in Aachen such a great success.

I wish all our readers and our colleagues, who were not able to attend the anniversary celebrations, all the very best for the coming year 2019 and much success in the laser assisted treatment of patients and in conducting scientific research at universities. In addition, I wish all laser manufacturers, and our exhibitors in particular, a successful business year 2019.

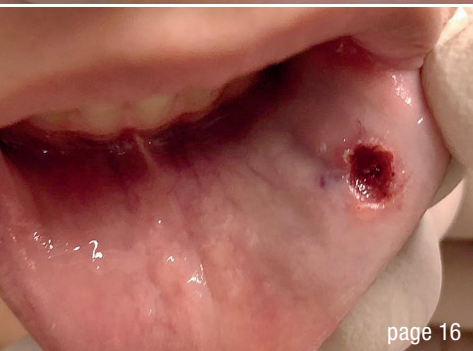
On behalf of the ISLD Executive Board, I am sending you my warmest greetings and I am looking forward to welcoming you at the ISLD International European Congress in Plovdiv, Bulgaria, next June.

Yours

Prof. Dr Norbert Gutknecht



page 10



page 16



page 26

Cover image courtesy of Fotona d.o.o.
www.fotona.com



editorial

30 years of ISLD—an **anniversary**, a milestone and a **new beginning** 03
Prof. Dr Norbert Gutknecht

case report

Implant uncovering using the Er:YAG laser 06
Dr Piotr Roszkiewicz

industry

Modern technologies in the treatment of **periodontal disease** 10
Dr Carmine Prisco

Removal of a fibroma using an Er:YAG laser 16
Dr Sigalit Blumer & Prof. Roly Kornblit

practice management

Successful **communication** in your **daily practice** 20
Dr Anna Maria Yiannikos

Communication skills in the dental practice 22
Dr Imneet Madan

events

International **dental laser community** gathered for World Congress 26

interview

The World Congress as a **turning point** for laser dentistry 28

news

manufacturer **news** 30

news international 31

DGL

30 Jahre **ISLD** – ein Jubiläumsjahr, ein **Meilenstein**, ein Neuanfang 35
Prof. Dr. Norbert Gutknecht

16. **Weltkongress** in der Laserzahnheilkunde 36
Prof. Dr. Dr. Siegfried Jänicke

news germany 40

about the publisher

imprint 42

The universe at your fingertips.

● LightWalker

The highest technology dental laser system

Supreme clinical results:

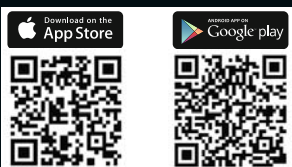
- TwinLight® Perio Treatments
- TwinLight® Endo Treatments
- No-sutures soft-tissue surgery
- Patient-friendly conservative dentistry
- Pre-sets for over 40 applications


Unmatched simplicity of use:

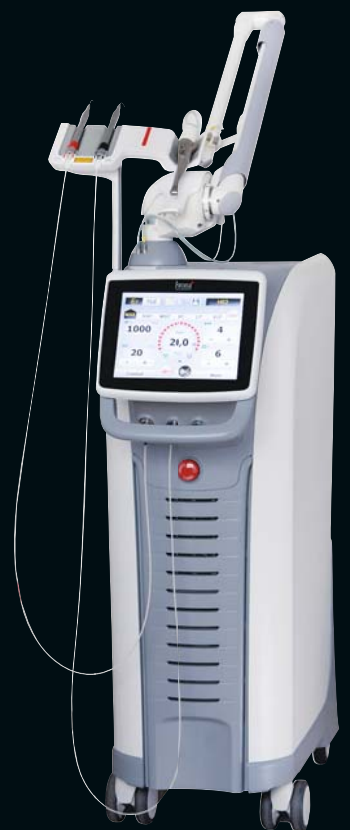- Balanced and weightless OPTOflex® arm
- Nd:YAG handpiece detection system
- Quantum Square Pulse technology for fast minimally invasive treatments
- X-Runner™ - the first digitally controlled Er:YAG dental laser handpiece

Journey into a new dental experience with speed, precision and great results.

Visit www.fotona.com today!



 Fotona App



Implant uncovering using the Er:YAG laser

Dr Piotr Roszkiewicz, Poland

Implantology, both in Poland and worldwide, is currently a strongly growing field of dentistry. In order to obtain long-term outcomes with the highest possible aesthetics, an implant must be placed as least invasively as possible. Another important factor is the implantation technique and the management of the surrounding soft tissue, both during the implantation procedure and in the prosthetic stage.

The technique used for flap incision and suturing the mucosa over the implant affects the wound healing time. The next important stage in the two-stage technique is implant uncovering. There are various ways to perform this procedure, for example by an incision according to the conventional technique, then uncovering the implant and attaching the healing cap. This, however, is often associated with suturing, which prolongs the time before impressions can be taken.

If bone grows on to the cover screw, its unscrewing is more difficult. Then, in order to place the healing cap, bone removal or scraping, as well as alveoplasty, needs to be performed. Many implant companies offer special sets called bone profilers that facilitate the work, but the procedure time and the duration of the prosthetic stage are nonetheless prolonged.



An alternative method of uncovering an implant is with the use of laser. Diode, carbon dioxide, Nd:YAG or Er:YAG lasers can be applied for this purpose. Diode and Nd:YAG lasers can only be used if the bone has not grown on to the cover screw. The advantage of the Nd:YAG laser application is no bleeding during the preparation of the mucosa and after the procedure; however, there is the drawback of thermal effects on the bone surrounding the implant and on the implant itself. The optimal solution is the application of the Er:YAG laser, which works perfectly on the mucosa and bone without negative effects.

Both the first and second stages of implant treatment are associated with discomfort and temporary pain for the patient. In their pilot study, Arnabat-Domínguez et al. proved that the application of Er:YAG lasers in implant uncovering eliminated the necessity for local anaesthesia and minimised postoperative pain, as well as the healing time before the prosthetic stage.¹ In the study, no differences were observed regarding the success of implant treatment. Further advantages of laser application are the antimicrobial effect and the ease of the procedure.

The incision or removal of a mucosal fragment covering the cover screw leads to disruption of the microcirculation in the operation area. Kulakov et al. showed significant

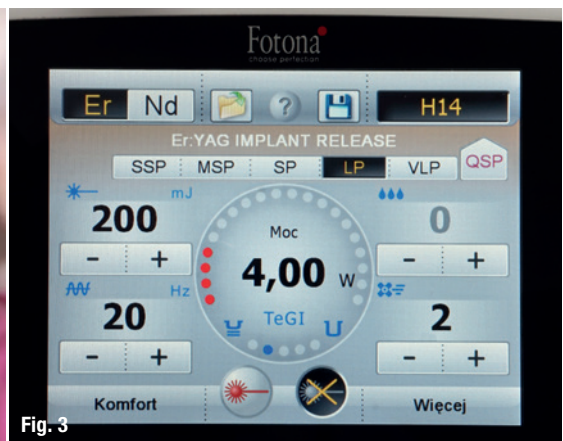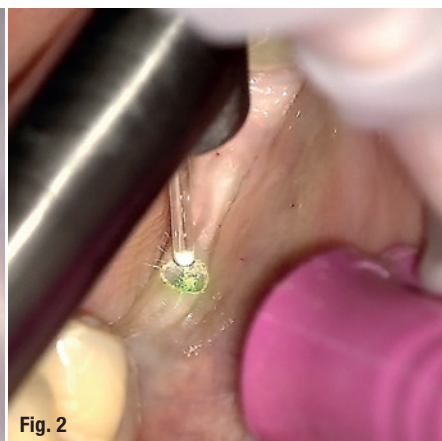
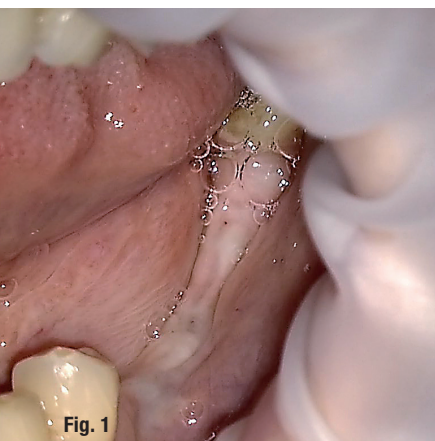


Fig. 1: Determining the location of the implants. **Fig. 2:** Uncovering of the cover screw with Er:YAG laser contra-angle handpiece H14 and a cylindrical tip of 1.3 mm in diameter. **Fig. 3:** Laser parameters used during the procedure.

differences in the critical time for restoring the microcirculation in the operation area.² After conventional implant uncovering—by the use of a scalpel—the time needed is 14 days, while with the use of an Er:YAG laser, it is only three days.

Esposito et al. showed that implant uncovering with the use of an Er:YAG laser compared with the classic flap technique led to smaller postoperative side effects.³ This difference was statistically significant.

Fornaini et al. compared four wavelengths (532; 810; 1,064 and 2,940 nm) for implant uncovering in their study and registered thermal changes with the use of thermal cameras.⁴ They concluded that the Er:YAG (2,064 nm) causes the smallest temperature increase in the implant and the surrounding tissue. The *ex vivo* study also showed that, during laser application with the recommended parameters, there is no risk of a dangerous temperature increase in the implant and tissue.

As observed by Maden, the Er:YAG laser works perfectly for contouring the bone surrounding the implant, gingival correction or implant uncovering in a two-stage technique, not causing thermal damage in soft and hard tissue, or in the implant itself.⁵⁻⁷ Such damage occurs while using standard rotary tools. In accordance with the procedure, during implant uncovering with the use of the Er:YAG laser, there is no need to admin-

ister local anaesthesia. Another advantage is the possibility of taking impressions of the implant area in the same visit because the gingiva is not overheated and it will retain its shape and position later on. Owing to the application of the Er:YAG laser and cold ablation, there is no risk of damaging the bone surrounding the implant or the implant itself.

Case presentation

A 37-year-old female patient appeared for the planned procedure of implant uncovering in regions #35–37. TSI111 implants (Osstem Implant) had been placed four months earlier by applying the classic flap technique.

In order to minimise the postoperative effects and to shorten the healing time, it was decided to apply an Er:YAG laser (LightWalker, Fotona) in this procedure. By means of a positioner used in the first part of implantation, the approximate location of the implants was established. Under local anaesthesia with articaine, the cover screws were located and their locations marked (Fig. 1).

In the procedure, the H14 contact contra-angle handpiece and a cylindrical tip with a 1.3 mm diameter were used. The tip, despite its name, was kept at 1 mm from the tissue (Fig. 2). The laser parameters used during the procedure are shown in Figure 3. In the final stage of implant uncovering, when the operation area was in the

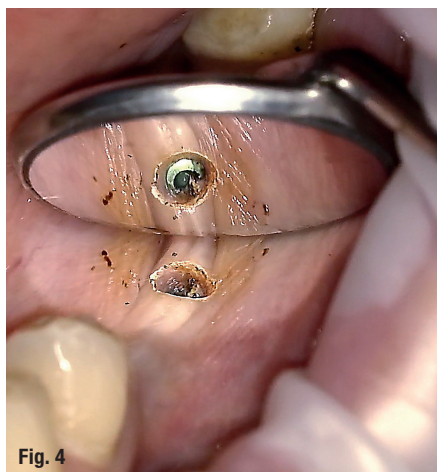


Fig. 4

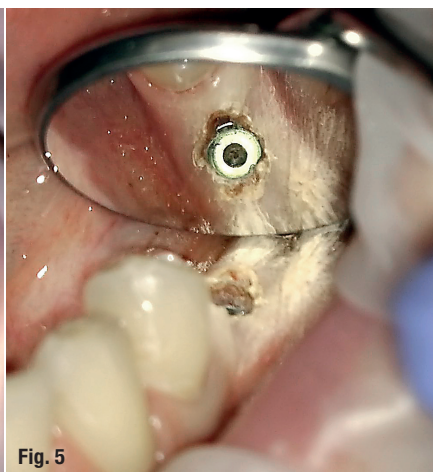
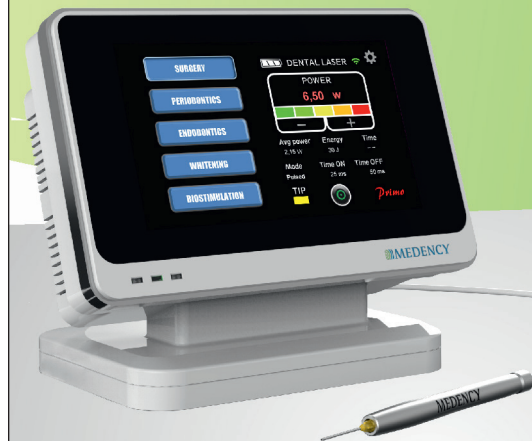
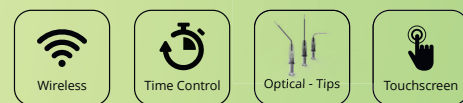
Fig. 5

Figs. 4 & 5: Final stage of implant uncovering with adjusted laser parameters to avoid thermal damage.

EXCEED YOUR EXPECTATIONS

The most innovative Dental Laser technology for your practice



PRIMO

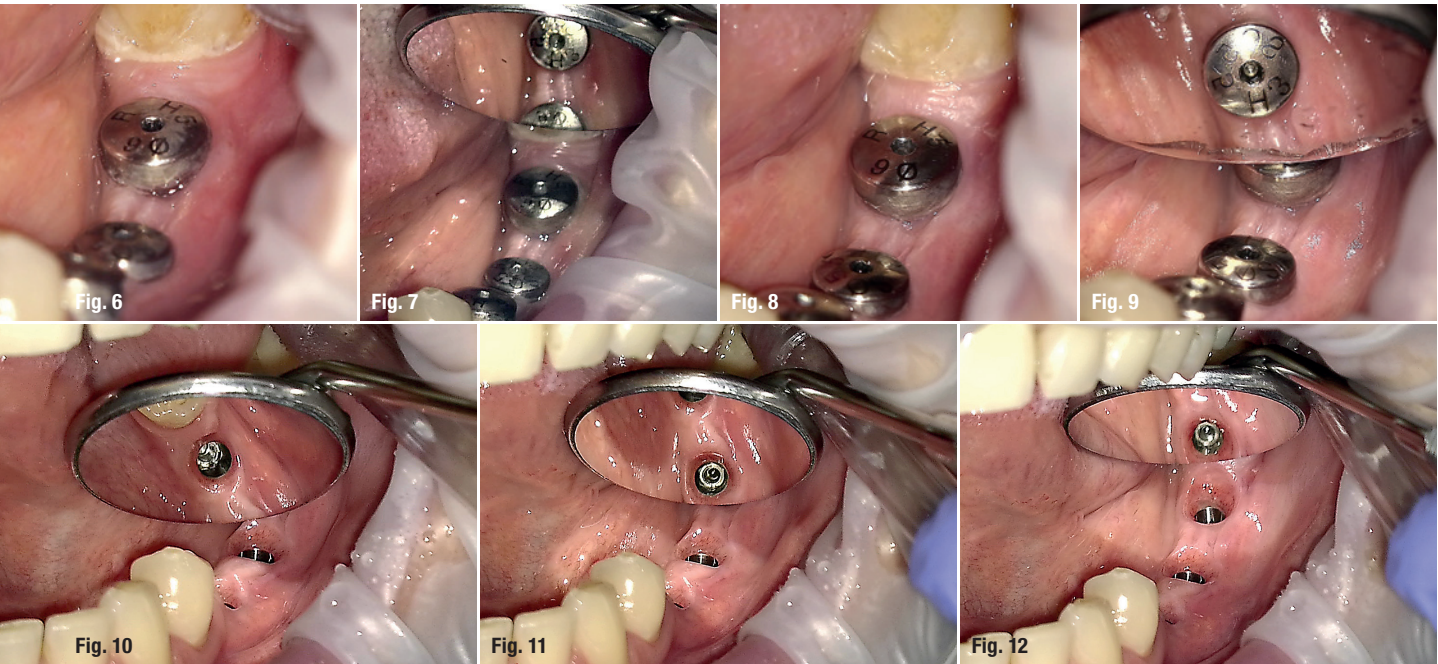


<p>One-touch TECHNOLOGY</p> <p>Stress-free software, fully automatic parameter selection offers the ideal way to boost productivity.</p>	<p>+35 pre-set TREATMENT</p> <p>Versatile, fast and accurate selection of protocols from a large variety of programs.</p>	<p>5-Top FAVORITES</p> <p>Every functional aspect of Primo has been developed with end users in mind. Most useful programs at your finger touch.</p>
<p>Active Time ASSIST</p> <p>Designed to help users to improve patient's care by stopping the laser by stopping the laser output to potentially avoid tissue overheating.</p>	<p>Multi-function HANDPIECES</p> <p>The ergonomic lightweight hand-piece gives the user a total control of movements. Wide selection of optical tips, whitening arch biostimulation and cosmetic tools.</p>	<p>Master-mode FOR EXPERTS</p> <p>Advanced software-enabled mode allows experienced users to achieve outstanding performance and to generate new protocols.</p>



medency.com





Figs. 6–9: Healing caps screwed on to the implants. Uneventful healing. **Figs. 10–12:** Properly healing tissue at the time of impression taking.

immediate vicinity of the implant-to-bone border, in order to avoid thermal effects, parameters were modified as follows: water to 2 and air to 4 (Figs. 4 & 5). Other parameters remained unchanged.

The healing caps were then screwed on to the implants. The patient did not complain of any discomfort. No inflammation or any abnormalities were reported during the healing time (Figs. 6–9). At the time of impression taking, properly healing tissue was observed (Figs. 10–12).

Conclusion

Implant uncovering in a two-stage technique using an Er:YAG laser is a faster method and better tolerated by patients than the classical flap technique. Through cold ablation, the Er:YAG laser allows the operator to sig-

nificantly shorten the treatment time without causing thermal damage to the implant or the tissue surrounding it. It further considerably reduces wound healing time, as well as the risk of infection. Problems experienced by patients are also less significant.

contact

Dr Piotr Roszkiewicz
 Member of PTSL, PSSM
 Director of the Laser and Health Academy Poland Training Center
 Klinika na Brzozowej
 Brzozowa 41
 05-080 Laski, Poland
 klinikanabrzozowej@wp.pl



Kurz & bündig


Das Freilegen von Implantaten mithilfe des Er:YAG-Lasers stellt eine schnellere und besser verträgliche Alternative zur klassischen Zahnfleischöffnung mittels Inzision dar. Hat sich über dem Implantat bereits Knochen gebildet, wird diese konventionelle Behandlung weiter erschwert und die prothetische Phase verlängert. Durch Kaltablation ermöglicht der Er:YAG-Laser es dem Behandler, die Behandlungszeit deutlich zu verringern ohne Hitzeschäden am Implantat oder dem umliegenden Gewebe zu verursachen. Des Weiteren wird die Heilungsdauer beachtlich verkürzt und das Infektionsrisiko reduziert. Der Autor beschreibt dieses Vorgehen am Fallbeispiel einer 37-jährigen Patientin. Die Freilegung der Implantate erfolgte im Anschluss an eine viermonatige Einheilphase in einem zweiphasigen Verfahren. Die je Phase angewendeten Laserparameter zur Implantatfreilegung mithilfe des LightWalker Er:YAG-Lasers von Fotona werden detailliert wiedergegeben. Die Einheilkäppchen konnten im Anschluss problemlos aufgesetzt werden. Die Patientin klagte über keinerlei Beschwerden und die folgende Einheilzeit verlief unauffällig ohne Entzündungen. Nach Verwendung des Lasers zur Freilegung der Implantate ist keinerlei Wundnaht notwendig womit die notwendige Einheildauer vor Abdrucknahme weiter verkürzt werden kann.

SUBSCRIBE NOW!

ceramic implants—international magazine of ceramic implant technology

Interdisciplinary, transparent & market orientated

ONLINE
SUBSCRIPTION HERE



www.oemus-shop.de

laser 4/18



stay updated:

research
**Guided regeneration
of lamellar bone tissue**

case report
**Immediate placement
in the aesthetic zone**

interview
**Clear trend towards
metal-free reconstructions**

Fax: **+49 341 48474-290**

I would like to subscribe for the following journals:

- ceramic implants—international magazine of ceramic implant technology 2 issues p.a. € 30*
- implants—international magazine of oral implantology 4 issues p.a. € 44*

Terms & Conditions: The subscription may be cancelled in written form without due justification within 14 days of order by contacting OEMUS MEDIA AG, Holbeinstraße 29, 04229 Leipzig, Germany. Dispatching notification in good time will suffice. The subscription is automatically extended by another twelve months if it is not cancelled in written form 6 weeks prior to the end of the reference period.

* All prices include VAT, shipping and handling.

Last Name/First Name

Company

Street

ZIP/City/Country

E-Mail

Signature

Credit Card Number

Expiration Date

Security Code