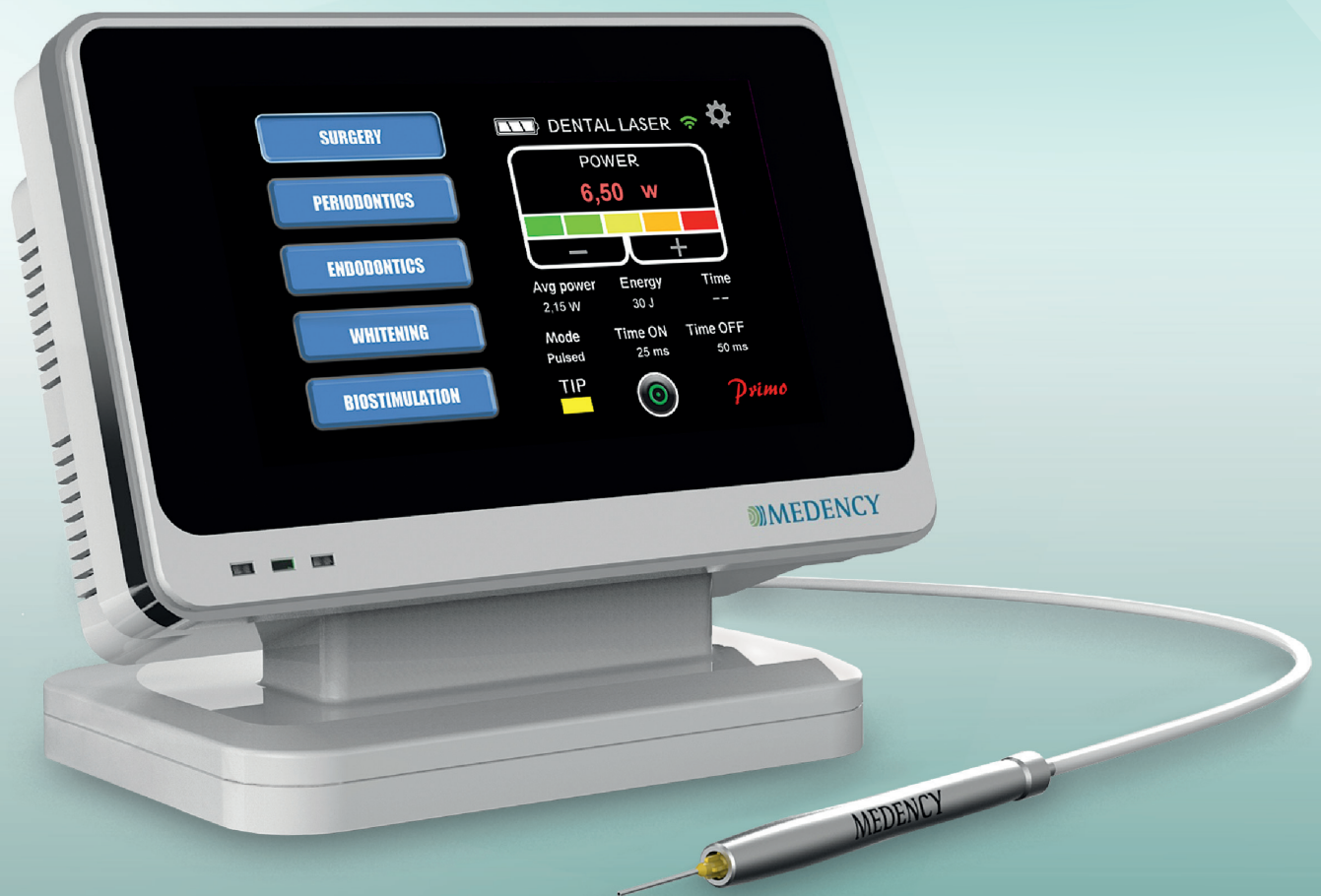

laser



international magazine of laser dentistry



case report

Peripheral giant cell granuloma surgery

industry

Erbium laser in ankyloglossia therapy

events

WFLD's Pearl Anniversary World Congress 2018



Fotona
choose perfection

The universe at your fingertips.

● LightWalker

The highest technology dental laser system

Supreme clinical results:

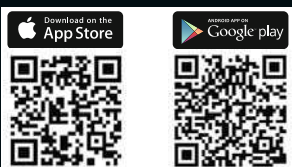
- TwinLight® Perio Treatments
- TwinLight® Endo Treatments
- No-sutures soft-tissue surgery
- Patient-friendly conservative dentistry
- Pre-sets for over 40 applications


Unmatched simplicity of use:

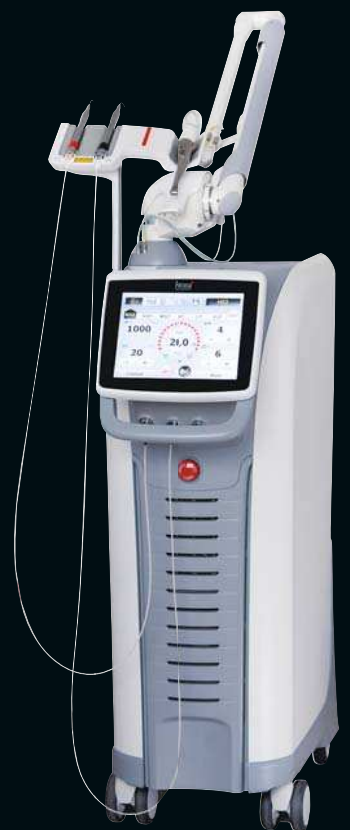- Balanced and weightless OPTOflex® arm
- Nd:YAG handpiece detection system
- Quantum Square Pulse technology for fast minimally invasive treatments
- X-Runner™ - the first digitally controlled Er:YAG dental laser handpiece

Journey into a new dental experience with speed, precision and great results.

Visit www.fotona.com today!



 Fotona App



Prof. Adam Stabholz

Former Dean of the Faculty of Dental Medicine,
Hebrew University Hadassah, Israel



From Maiman's 1st laser to the Laser World Congress 2018

Dear colleagues and friends,

One hundred years ago Albert Einstein envisioned that under the right conditions a special kind of light could be created—a light that nobody has ever seen before. It would be a single colour, it would not scatter and it would be intense.

Almost sixty years ago, in 1960, Theodore Maiman presented the first laser device on earth. Maiman identified five potential uses for the laser, among them concentrating light for industry, chemistry and medicine. The search for new devices and technologies for dental procedures has always been challenging and in the last four decades much experience and knowledge have been gained. Pioneering research in the mid-sixties paved the way for the use of lasers in dental medicine and the development of pulsed technology with CO₂ wavelengths in the eighties made lasers popular in this medical area. In 1990, the first laser designed specifically for general dentistry, the dLase 300 Nd:YAG, was introduced and in 1997, following the FDA approval of the Er:YAG laser for caries removal, cavity preparations and modification of dentine and enamel, a new era in laser dentistry began.

With the rapid development of laser technology, new lasers with a wide range of characteristics are now available and are being used for soft-tissue procedures, caries diagnosis and removal, curing composites, tooth bleaching, paediatric dentistry, endodontics, periodontics, preventive and implant dentistry, control of bleeding in vascular lesions and Low Level Laser Therapy.

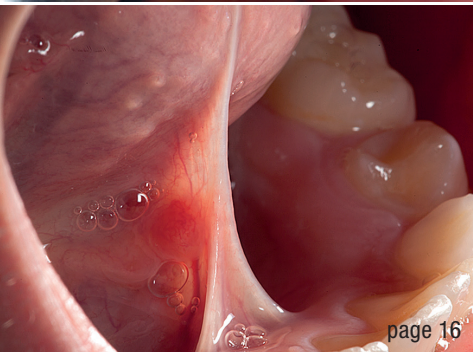
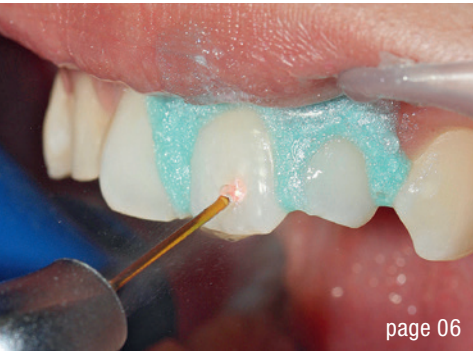The WFLD congress in Aachen from 1 to 3 October 2018 will mark the 30th anniversary of the WFLD/

ISLD and will provide a perfect stage for friends and colleagues to get together, to exchange knowledge based on latest research, to learn about the newest developments in laser dentistry and how to implement this knowledge in the various disciplines mentioned above. It will be a perfect time as well for building new friendships and planning new collaborations for the future. Do not miss this unique opportunity to be part of the largest scientific laser in dentistry meeting ever—organised in the beautiful city of Aachen, Germany, known as the cathedral city of Europe. It is located on the border to Belgium and the Netherlands and is a city that lives and breathes Europe. When not attending one of the lecture halls, where the world's most renowned speakers will be presenting, or participating at one of the workshops or learning at the posters session, a visit to the Aachen Cathedral is a must. It is certainly both a local landmark and a monument of Europe's illustrious past.

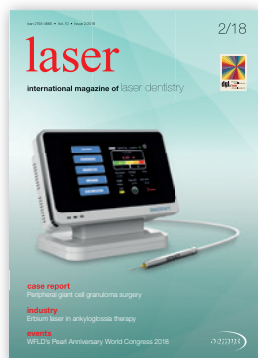
The preparations for the world congress are in full swing and a tremendous effort is made to ensure its success. Our thanks and our deepest appreciation go to the wonderful team headed by Prof. Dr Norbert Gutknecht, Prof. Dr Lynn Powell, Leon Vanweersch, Dr Dimitris Strakas, Dr Stefan Grümer, the DGL local organising team and to all members on the international organising committees.

I look forward to meeting you all in Aachen at this outstanding high-level international scientific event jointly organised by WFLD, DGL and WALED. On 1 October 2018 all roads will lead to Aachen.

All the best and see you soon in Aachen,
Prof. Adam Stabholz



Cover image courtesy of MEDENCY Srl
www.medency.com
 Original Background:
 © Thaview/Shutterstock.com



editorial

From Maiman's 1st laser to the Laser World Congress 2018 03
 Prof. Adam Stabholz

case report

Minimally invasive dentistry with Er,Cr:YSGG 06
 Drs Christina Karanasiou & Dimitris Strakas

Peripheral giant cell granuloma surgery with diode laser 10
 Drs Maziar Mir, Masoud Mojahedi, Jan Tunér & Masoud Shabani

industry

Erbium laser in ankyloglossia therapy 16
 Dr Adam J. Wolniewicz

practice management

Successful communication in your daily practice 20
 Dr Anna Maria Yiannikos

Six Sigma in the management of laser-assisted dental practices 22
 Dr Imneet Madan

interview

Technology, innovation and passion 26
 Timo Krause

events

“The Future of Dentistry is Here” 28
 Dr Diana Constantinescu

WFLD's Pearl Anniversary World Congress 2018 30
 Dr Dimitris Strakas & Leon Vanweersch

news

manufacturer news 32

news international 33

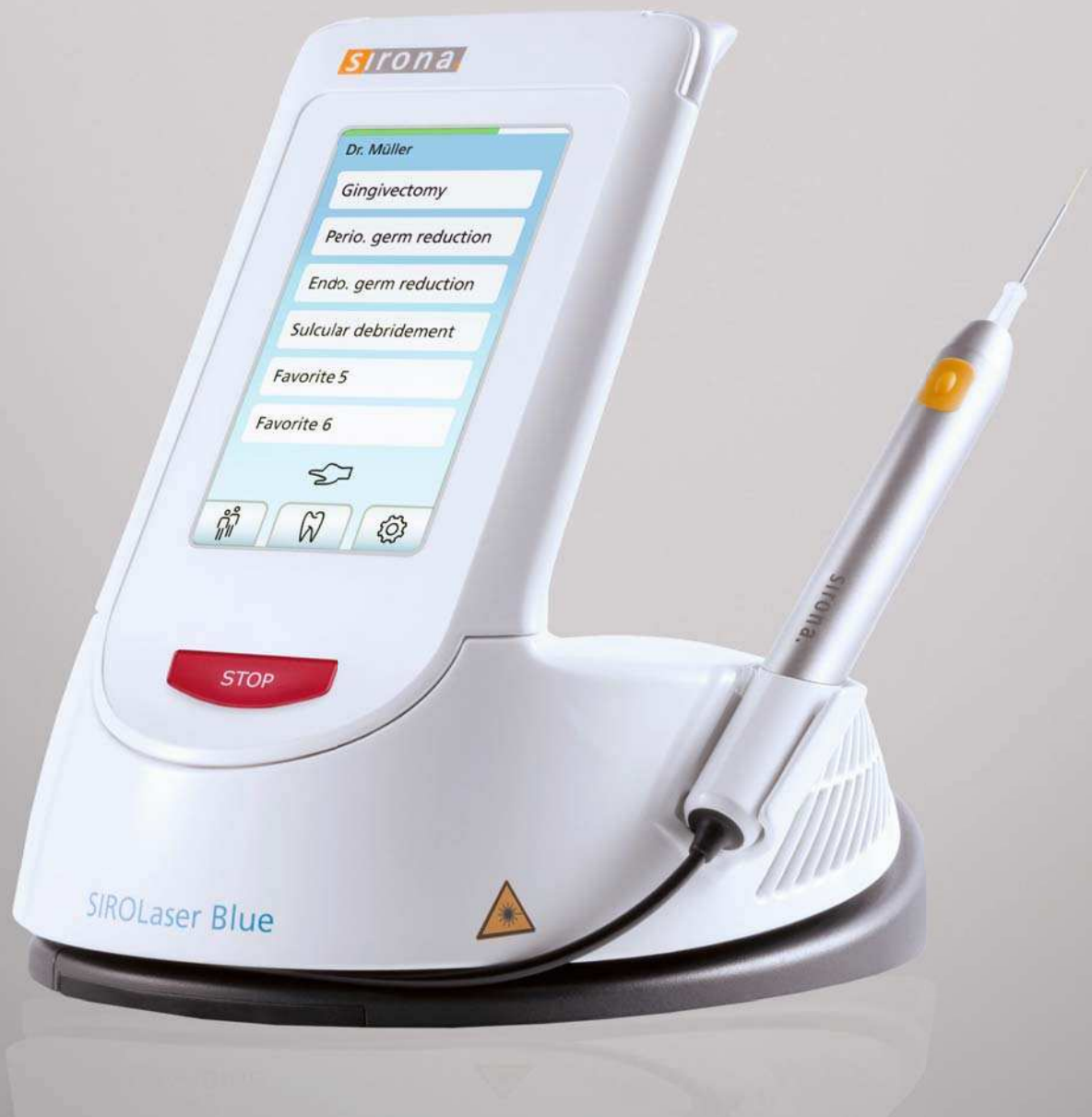DGL

DGL-Jahreskongress in Aachen am 2. und 3. Oktober 2018 36
 Prof. Dr. Norbert Gutknecht

news germany 38

about the publisher

imprint 42



SiroLaser Blue

Versatile Possibilities

SiroLaser Blue: Efficient cutting performance meets a variety of treatments. 3 wavelengths. More than 20 indications. Versatile applications.

dentsplysirona.com

THE DENTAL
SOLUTIONS
COMPANY™

 Dentsply
Sirona

Minimally invasive dentistry with Er,Cr:YSGG

Drs Christina Karanasiou & Dimitris Strakas, Greece

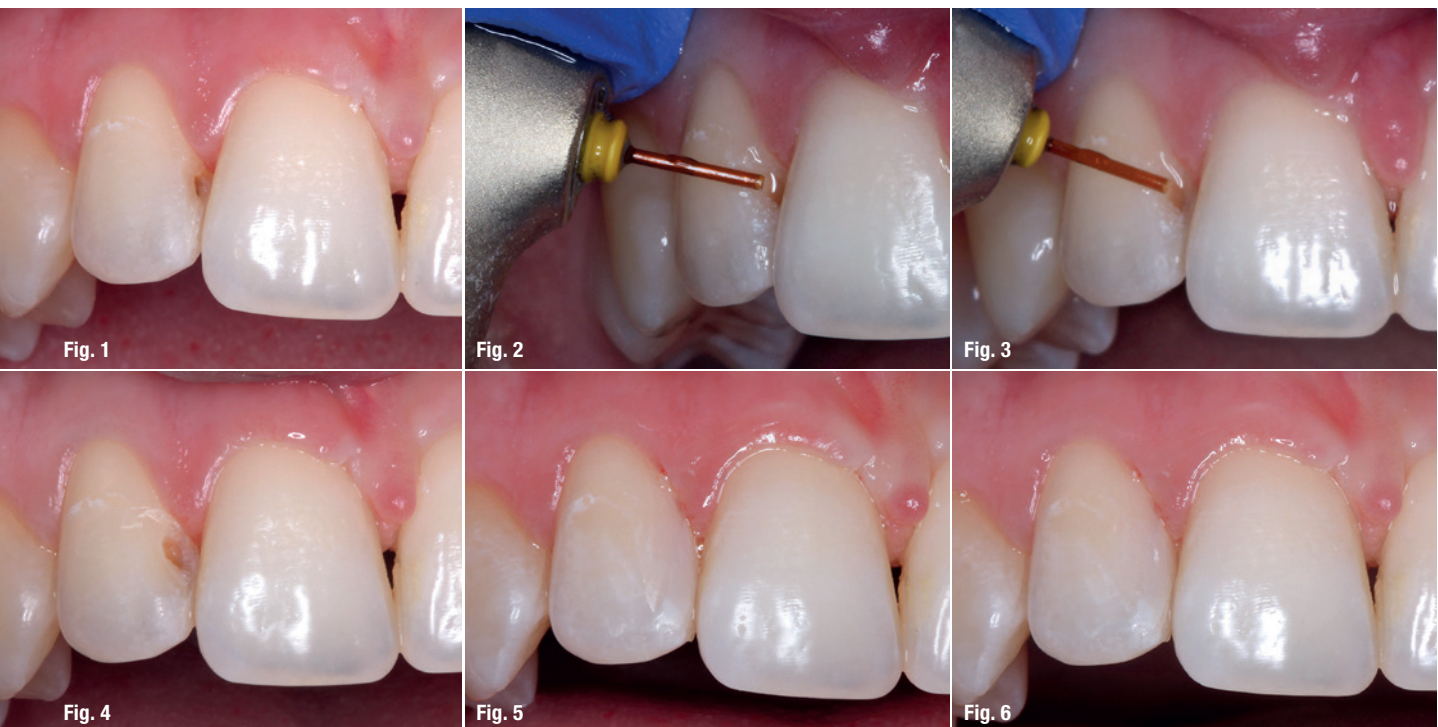Introduction

The concept of minimally invasive dentistry can be defined as the maximal preservation of healthy dental structures, involving the minimal removal of carious lesions for example. Modern dentistry and its minimally invasive concepts are supported by the development of innovative materials and cutting-edge techniques.

Lasers have been widely used in many fields of dentistry and several wavelengths have been investigated as substitutes for a high-speed handpiece. Conventional cavity preparation refers to the removal of infected hard tissue using rotary instruments. However, dental hard-tissue ablation for cavity preparation by means of irradiation with the erbium family of lasers has attracted many researchers, and we can affirmatively state today that the procedure is safe and can be performed without anaesthesia in the ma-

ajority of cases, and the resulting prepared cavity is free of a smear layer. Moreover, noise and vibration caused by dental burs are contributing factors to the development of dental fear. The use of laser ablation for tooth preparation has made it possible to avoid these discomforts, thus making the procedure a life-changing experience for patients. With lasers, the minimal removal of healthy tooth substance in operative dentistry can be achieved.

The erbium family of lasers (located in the mid-infrared region of the electromagnetic spectrum) was introduced in dentistry for cavity preparation owing to the wavelength's high absorption in water and hydroxyapatite (hydroxyl radical). Enamel removal occurs by explosive thermomechanical ablation. Light is rapidly absorbed in water molecules leading to a micro-explosion which consequently results in enamel, dentine and carious tissue removal due to strong subsurface pressure.



Case 1 – Fig. 1: Initial situation: dental caries of the right maxillary lateral incisor. **Figs. 2 & 3:** Caries removal by Er,Cr:YSGG laser. **Fig. 4:** Area after laser treatment. **Fig. 5:** Restorative procedure performed freehand with composite resin. **Fig. 6:** Final polishing with medium-fine and superfine oxide discs.

Pulp chamber temperature rise during cavity preparation with Er,Cr:YSGG laser irradiation has been reported by several studies to be lower than with a conventional method using a bur, suggesting that this system has no adverse thermal effect.

The Er,Cr:YSGG laser (2,780nm) has been studied in dental hard tissue, especially for cavity preparation in clinical situations, and it has proven to be ideal for minimally invasive ablation of carious lesions without any side effects.

Case 1

A 25-year-old female patient came to the postgraduate dental clinic of the Department of Operative Dentistry at the Aristotle University of Thessaloniki, Greece. The patient's major complaint was sensitivity and pain at her right maxillary lateral incisor when exposed to cold water. After taking the medical and dental anamnesis, clinical and radiographic examination were performed. They revealed dental caries affecting the right maxillary lateral incisor (Fig. 1).

Therefore, a fast and minimally invasive method for caries removal was decided on. An Er,Cr:YSGG laser (2,780nm, Waterlase MD Turbo, Biolase) was used for

this purpose (Figs. 2 & 3). For the procedure, the gold handpiece of the device and a Z-type glass tip of 500µm in diameter (MZ5) were used. The laser parameters utilised for this case were as follows: average output power of 6W, pulse duration of 140µs (H-Mode), pulse repetition rate of 20Hz (300mJ per pulse, 153J/cm² energy density) and under water spray (air: 60%, water: 80%). All margins received etch modification with the same laser device (Fig. 4). The power settings for bond preparation were as follows: MZ6 tip, average output power of 4.5W, pulse repetition rate of 50Hz and H-Mode.

After drying the tooth with an air blower, the cavity was treated with an adhesive system in accordance with the manufacturer's instructions (Single Bond Universal Adhesive, 3M ESPE). The restorative procedure was performed freehand with composite resin (Fig. 5). In order to achieve the final two colour shades, A2 for dentine and A1 for enamel (Clearfil Majesty ES-2 A2D and Clearfil Majesty ES-2 A1E, Kuraray Noritake Dental) were used. Final polishing was performed with medium-fine and superfine oxide discs (Sof-Lex, 3M ESPE; Fig. 6).

The laser treatment was performed with no local anaesthesia. The patient reported no sensitivity at any stage of the procedure.

AD

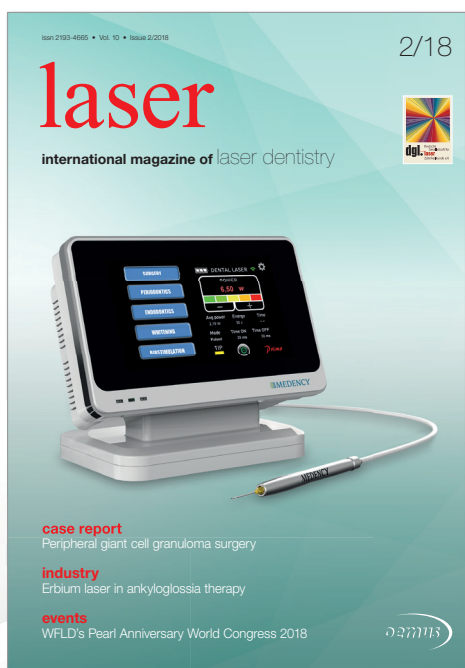BECOME AN AUTHOR

for laser — international magazine of laser dentistry

Interdisciplinary and close to the market



www.oemus.com



Become part of a successful network and benefit from a wide reach and high level of awareness

Your benefits:

- author's profile at ZWP online
- specimen copies
- offprints
- speaking engagement*

Please contact Mr. Georg Isbaner:
g.isbaner@oemus-media.de
Phone: +49 341 48474-123

*according to the required profile



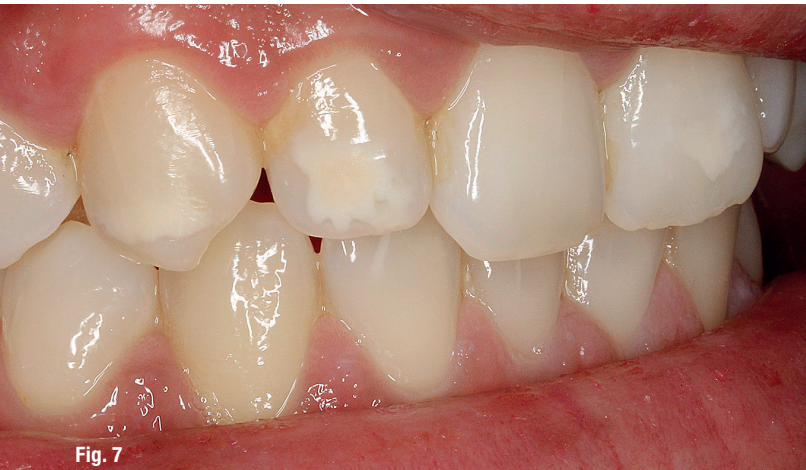

Fig. 7

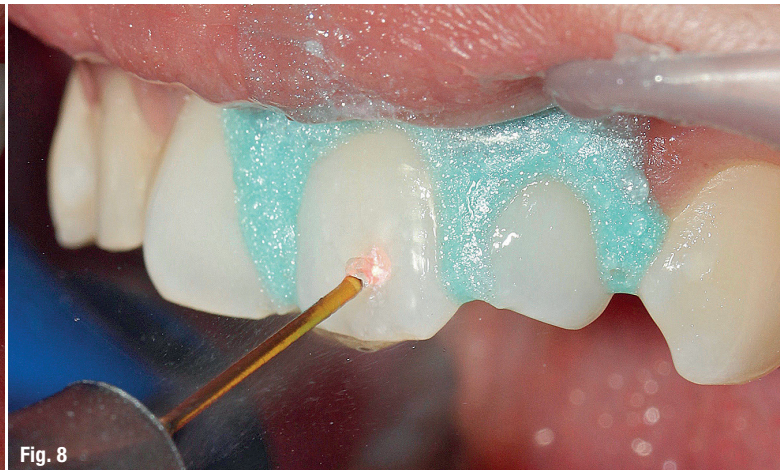

Fig. 8

Case 2 – Fig. 7: Initial situation: enamel hypomineralisation spots on anterior teeth. **Fig. 8:** Laser treatment with the gold handpiece and a Z-type glass tip (MZ6).

Case 2

A 27-year-old female patient presented with the main complaint of white spots on her anterior teeth. The patient required a minimally invasive solution to improving her smile. A thorough medical and dental history were taken prior to the clinical examination (Fig. 7).

According to the patient's clinical examination, the white spots were non-carious and were associated with enamel hypomineralisation. The aetiology of hypomineralised enamel can be genetic, acquired or idiopathic. General factors include infections during the critical age of two to three years—especially upper respiratory tract infections that require treatment with antibiotics in combination with corticosteroids—and nutritional deficiencies of vitamins A, C and D, calcium and phosphorus. Local factors include dentoalveolar infections or trauma of primary predecessors, surgical operations, and infections due to environmental factors, such as dioxins, which may be present even in breast milk.

When enamel hypomineralisation is observed in the anterior teeth, aesthetic problems arise, affecting not only the psychological state but also the social behaviour of the patient. Minimal intervention is an ideal approach in managing such white spots. The patient's expectations are vital to the decision-making process.

For this case, an Er,Cr:YSGG laser (2,780nm, Waterlase iPlus, Biolase) was used. For the procedure, the gold handpiece of the device and a Z-type glass tip of 600µm in diameter (MZ6) were used. The laser parameters utilised for this case were as follows: average output power of 3.25W, pulse duration of 60µs (H-Mode), pulse repetition rate of 20Hz (163mJ per pulse, 58J/cm² energy density) and under water spray (air: 60%, water: 70%; Fig. 8). All margins received etch modification with the same laser device. The power settings for bond preparation were as follows: MZ6 tip, average output power of 4.5W, pulse repetition rate of 50Hz and H-Mode (Fig. 9).

After drying the tooth with an air blower, the cavity was treated with an adhesive system in accordance with the manufacturer's instructions (Bond Force II, Tokuyama Dental; Fig. 10). The restorative procedure was performed freehand with composite resin. In order to

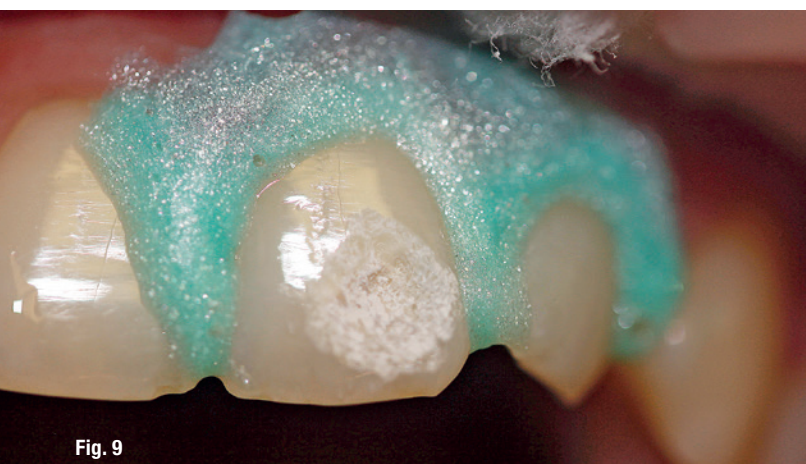

Fig. 9

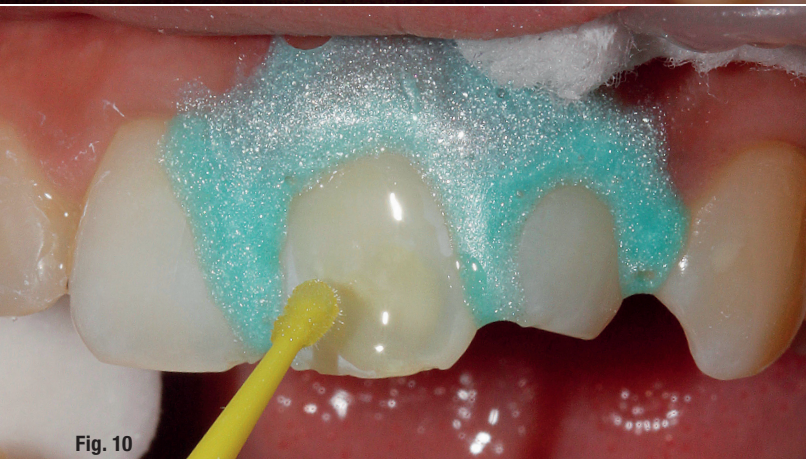

Fig. 10

Case 2 – Fig. 9: Bond preparation. **Fig. 10:** Cavity treated with adhesive system.

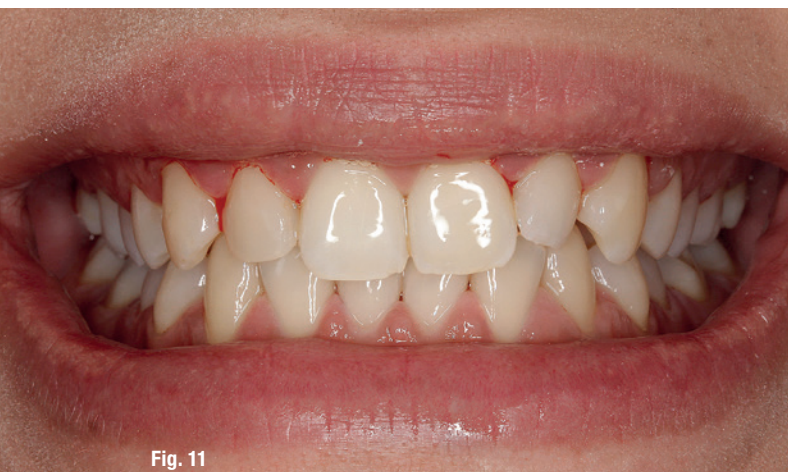

Fig. 11

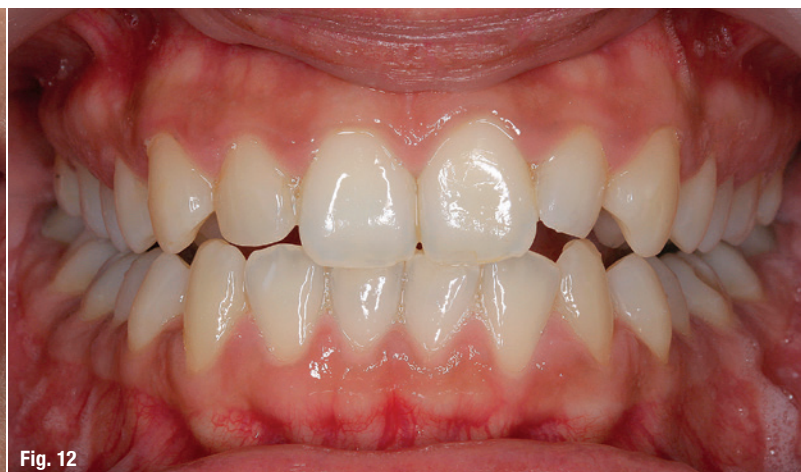

Fig. 12

Case 2 – Fig. 11: Final polishing with medium-fine and superfine oxide discs. **Fig. 12:** Final situation after rehydration of the teeth.

achieve the final two colour shades, A2 for dentine and A2E for enamel (IPS Empress Direct, Ivoclar Vivadent) were used. Final polishing was performed with medium-fine and superfine oxide discs (Sof-Lex; Fig. 11).

The laser treatment was performed with no local anaesthesia. The patient reported no sensitivity at any stage of the procedure. The final result after rehydration of the teeth can be seen in Figure 12.

Discussion

As dental technology continues to develop, new, innovative methods will continue to replace those that were once thought to be the peak. Lasers are now widely used in minimally invasive treatment in routine clinical procedures. According to the literature, treatments performed with Er,Cr:YSGG laser can be considered efficient and

viable in clinical practice, without damage to the pulp or periodontal tissue, and with great acceptance by patients owing to decreased vibration and noise, reduction of pain sensitivity and, in some cases, no need for the application of local anaesthesia.

contact

Dr Dimitris Strakas
DDS, M.Sc., PhD
Aristotle University of Thessaloniki
Spiridi 28
38221 Volos, Greece
dstrakas@dent.auth.gr



Author details

Kurz & bündig

Moderne Zahnheilkunde und minimalinvasive Konzepte werden besonders durch die Verfügbarkeit innovativer Materialien und hochmoderner Technologien unterstützt. Laser werden heute häufig für minimalinvasive Behandlungen vorrangig bei medizinischen Routineeingriffen wie bspw. im Fall von Kavitäten verwendet. Studien zufolge, gelten mit dem Er,Cr:YSGG-Laser durchgeführte Behandlungen als effizient und erfolgreich in der klinischen Praxis ohne die Zahnpulpa oder das parodontale Gewebe zu beschädigen. Aufgrund der gesenkten Vibration und Lärmbelastung sowie reduzierter Schmerzempfindlichkeit und in manchen Fällen sogar keiner Notwendigkeit einer Lokalanästhesie, findet diese Behandlungsmethode bei Patienten hohe Akzeptanz.

Die Autoren stellen zwei Fallbeispiele und Behandlungsabläufe ihrer Arbeit für die Abteilung für Zahnchirurgie der Aristoteles Universität in Thessaloniki, Griechenland, unter Verwendung des Er,Cr:YSGG-Lasers vor. Im ersten Fall wurde erfolgreich eine Kavität am rechten oberen lateralen Schneidezahn behandelt, während im zweiten Fall durch Molaren-Inzisiven-Hypomineralisation verursachte ästhetische Beeinträchtigungen in Form von weißen Arealen an den Inzisiven entfernt wurden. In beiden Fällen war keine Lokalanästhesie erforderlich, beide Patienten berichteten über keinerlei Schmerzempfindlichkeit während der Behandlung. Die je Fall verwendete Laserausstattung sowie die jeweiligen Einstellungsparameter werden detailliert wiedergegeben. Zudem sind auch die folgenden restaurativen Prozesse dargestellt und bildlich dokumentiert. Dank des Einsatzes der Er,Cr:YSGG-Laser konnten für beide Patienten mit nur minimalinvasiven Eingriffen die Beschwerden eliminiert und zufriedenstellende Ergebnisse erzielt werden.