

roots

international magazine of endodontics

trends & applications

Conservative root canal treatment

case report

Guided endodontic access
of calcified anterior teeth

feature

Bioceramic dispersion root filling



My choice?
All-in-one!


Endo
it your
way!

Find the VDW
endo motor
that matches
your style

VDW.GOLD[®] RECIPROC[®]
Comprehensive endo motor
with integrated apex locator



RECIPROC[®] blue
one file endo





Dr Philippe Sleiman

Guest Editor

Ecological Endodontics

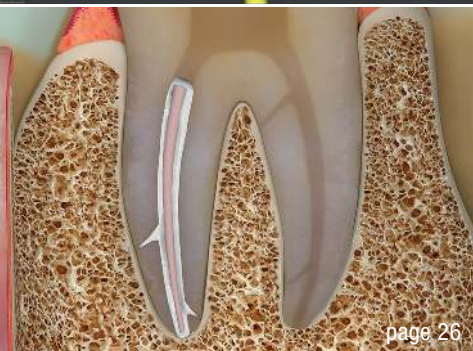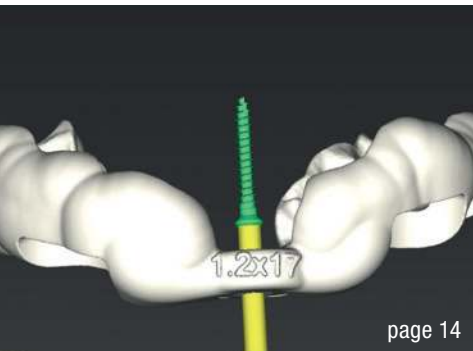
When you think about endodontic treatment, it might sound so simple: access cavity, some files, a bit of irrigation, a cone with a sealer, and that's it. Unfortunately, this is not the reality. The armamentarium that we use is almost as sophisticated as the one used during the brain surgeries. Ironically, we bring in so much heavy equipment to deal with a bit of pulp tissue and some microorganisms. The equipment that, if used on other tissues, can cause irreversible damage. The question is, do we really need it?

Is there a more ecological and tissue-friendly way to accomplish the endodontic treatment? Cryotherapy studies have demonstrated that a simple technique using cold water can solve such a major issue in endodontics as postoperative pain. Our sequence of irrigation is proving that with appropriate timing and alternation of solutions, as well as with the use water between the two main chemicals we can almost disinfect the root canal system—and also more efficiently than any other heavy equipment. The question, thus, is if we really have to bring a one-ton hammer to break open a pumpkin seed?

Learning from history, when mummification was performed in Ancient Egypt, the use of simple materials and procedures in a very strict order was consistently giving an effect lasting for several thousands of years.

Is it possible to modify our thinking to incorporate a similar approach? Thinking out of the box and using the modern technology to more ecological and bio-friendly materials may be the way of the future for our profession. Providing body's defense cells an environment and conditions to fight infections and limiting the use of antibiotics, using cold water to reduce inflammation and therefore pain, limiting the use of pain killers and so on—I think this is how we could remain biological in the world of ever more complicated technology.

Dr Philippe Sleiman
Guest Editor



Cover image courtesy of MANI, INC.
(www.mani.co.jp/en)



editorial

Ecological Endodontics 03
Dr Philippe Sleiman (Guest Editor)

trends & applications

Conservative root canal treatment 06
File selection and other important factors
Dr Jenner Argueta

case report

Tactile **smart approach** with nickel-titanium **files** 10
Dr Andreas Habash

Guided endodontic access of calcified anterior teeth 14
Drs Hugo Sousa Dias, Inês Pampulha & Maria João Valadas

Post-anaesthetic **necrosis of palatal bone** 32
Drs Pamela Kassabian, Valerie Batrouni,
Edgard Jabbour, Philippe Sleiman

feature

Irrigation in endodontics—**new needle** for better results 22
Drs Franck Diemer, Maël Diemer, Amaury Beaugendre,
Vincent Blasco-Baqué, Jean-Philippe Mallet

Bioceramic dispersion **root filling** 26
Revision of legacy obturation protocols
Dr Kenneth S. Serota

industry report

Ceramic implant **vs endodontic** treatment 34
Dr Dr Johann Lechner

practice management

Successful **communication** in your **daily practice** 38
Part VI: Economic crisis
Dr Anna Maria Yiannikos

manufacturer news 40

meetings

ROOTS SUMMIT 2020 is coming to Prague 44
International events 46

about the publisher

submission guidelines 48
international imprint 50


EQ-S

Effective 3D irrigation for a successful root canal treatment.

Let it flow!

Easy, quick and safe irrigation system:

- Active Flow Technology
- Flexible access to curved canals
- The ultimate solution to safely and efficiently clean the root canal system.



Come visit us at
IDS 2019
Hall 11.1
Booth B060

Conservative root canal treatment

File selection and other important factors

Dr Jenner Argueta, Guatemala

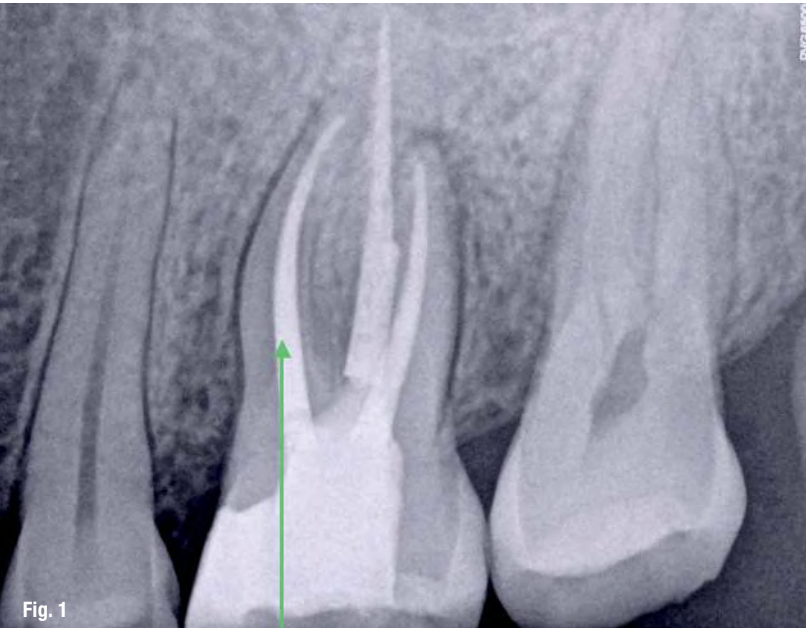


Fig. 1: Green arrow is showing a straight-line access to the mesiobuccal canal, dentinal interferences were eliminated during the preflaring protocol.

The final goal of endodontic therapy is to provide the patient with an appropriate biological environment that can host a symptom free and long-term functional tooth with healthy periapical tissues. To achieve this objective, taking care of the valuable dental structure, and preserving peri-cervical dentine and proximal margins, are important factors to have in mind.¹ Minimally invasive procedures are quite popular nowadays, applying them with the objective to preserve sound natural structure is a noble action that has the patient's best interests, but, on some occasions, the decision of proceeding with a conservative way relies more on the desire of the clinician for showing their clinical ability without being aware of the inherent risks of what a conservative approach entails during endodontic therapy.

The conservative approach to the pulp chamber is not in concordance with the traditional philosophy of straight-line access, in which the main objective is to reduce the stress points to the files as much as possible,^{2,3} eliminating dentinal interferences located at the entrance of the root canal from the beginning of the treatment (Fig. 1). Working in a conservative way applies for mono and multi-radicular

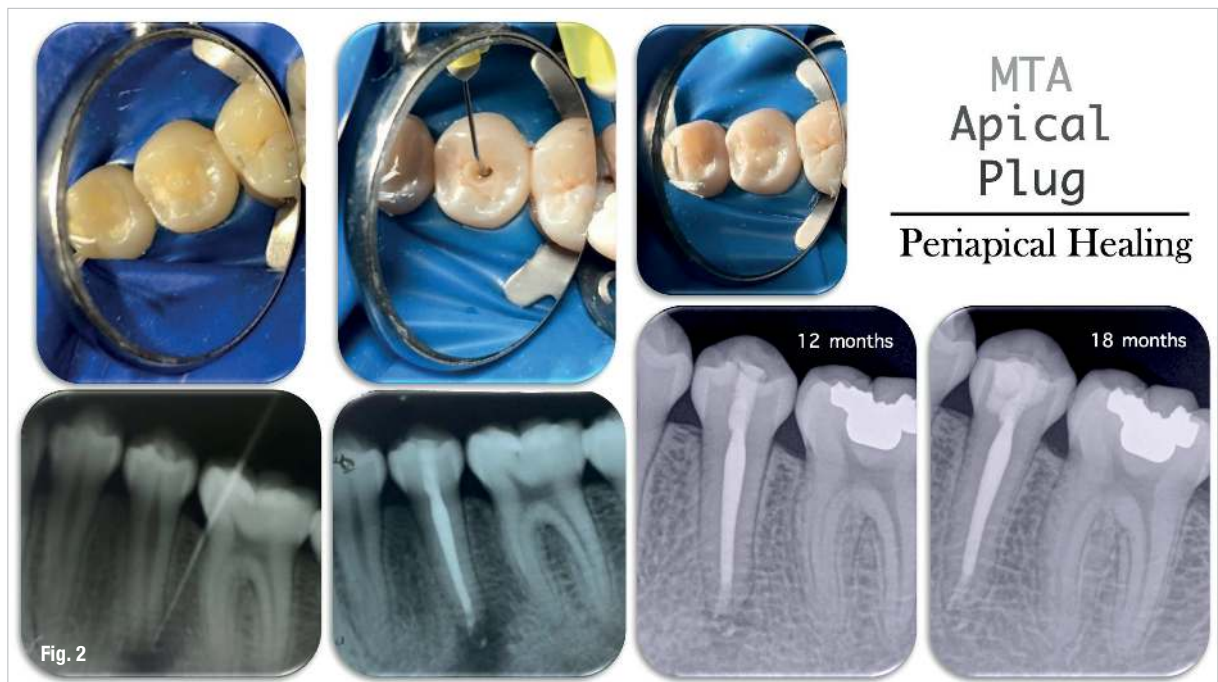


Fig. 2: Root canal treatment with conservative access in a lower premolar that went necrotic due to a dens invaginatus. At some point, this coronal anatomic variation allowed bacteria migration inside of the pulp space; after 18 months, a complete periapical healing can be seen. GL153 instrumentation system was used to preserve the cervical structure.

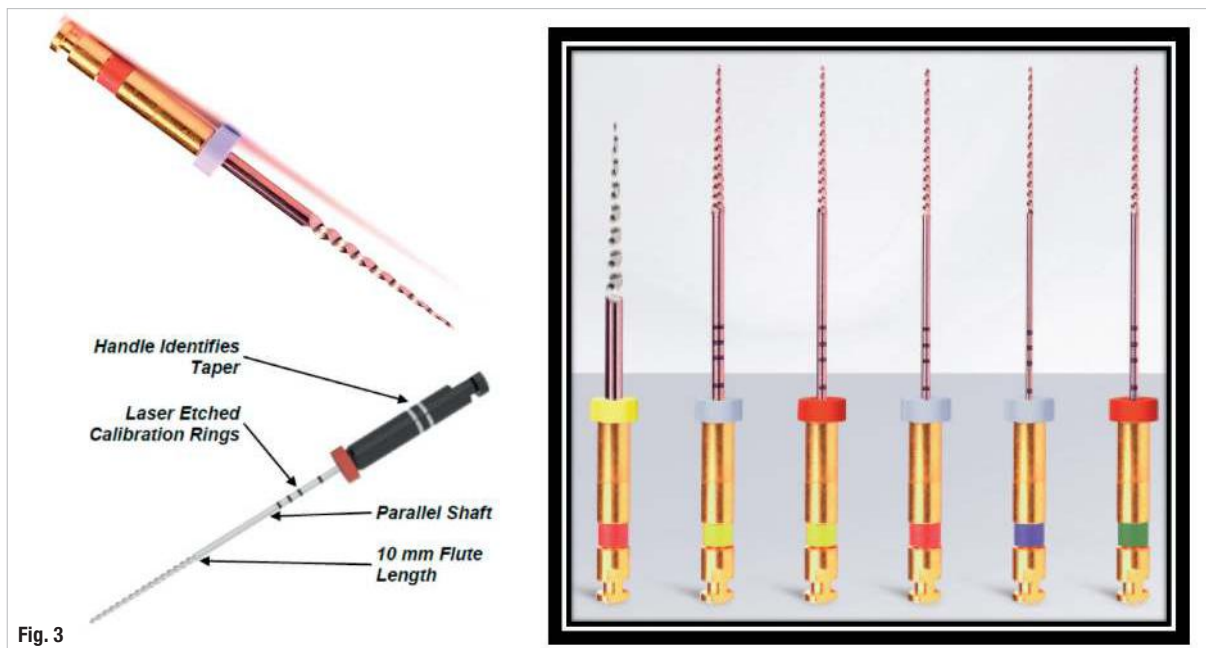


Fig. 3: GL153 sequence and main characteristics.

teeth, it is advisable to use this method on intact teeth when, for any particular reason, a root canal treatment is necessary. One of the most common group of teeth that become necrotic with intact crowns are lower premolars as a result of anatomical variations and incisors with pulp pathology provoked by traumatism in the area.⁴ A good example of conservative access in premolars is presented in Figure 2.

Some of the aspects related to contracted or ninja endodontic access openings that can jeopardise the outcome of a root canal treatment include: missed anatomy, inappropriate delivering of irrigant solutions, increased flexural stress to the files, poor visibility and/or illumination, remaining pulp tissue at the pulp chamber, perforations at the coronal level, inefficient instrumentation. The endodontist's experience and expertise play a critical role during a conservative root canal treatment due to these possible risk factors.^{2,3,5-8}

One of the bigger risks when working through conservative access is the increased flexural stress the files undergo during the procedure, being higher at the entrance of the root canal due to the lack of straight-line access. Cyclic fatigue might also increase at curvature levels, triggering greater transportation and changing the original root canal anatomy.⁹ If cyclic fatigue is one of the major risks related to conservative endodontic openings, using files with enhanced cyclic fatigue resistance is advisable.

Controlled memory files have demonstrated better distribution of stress at bending points, have much more flexibility and increased cyclic fatigue resistance when compared with stainless steel and super elastic NiTi files.^{10,11}

The behaviour of controlled memory files can be explained by the presence of stable martensite stage in their microstructure. Stable martensite alloy provides the instruments with the shape memory effect^{12,13} and the characteristics that have been already mentioned.

Aurum Blue and GL153 (Meta Biomed Inc.) are endodontic files with stable martensite; because of this physical characteristic, both instrumentation systems offer outstanding cyclic fatigue resistance, pre-bending ability and high flexibility.

GL153 is a system composed by six files with cross sections with rounded angles, a 10 mm active part and 23 degrees helical angle (Fig. 3). The cross section with rounded

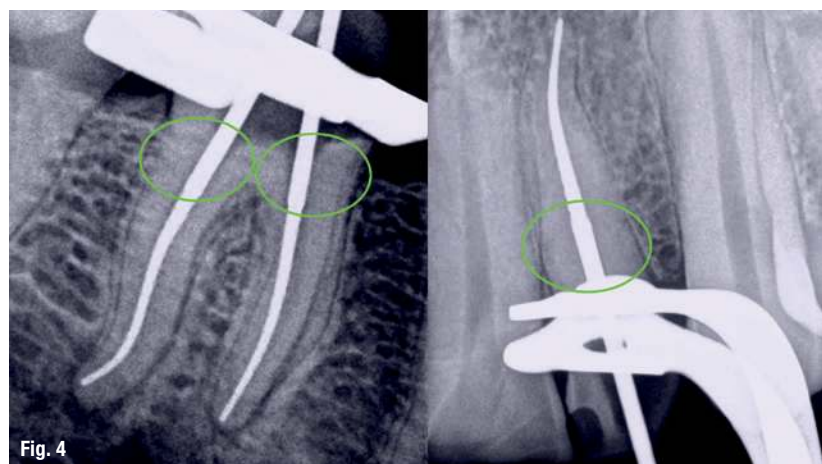


Fig. 4: 10 mm active part is long enough for shaping the canals while preserving cervical radicular dentine, this image shows how conservative are the files in that area.

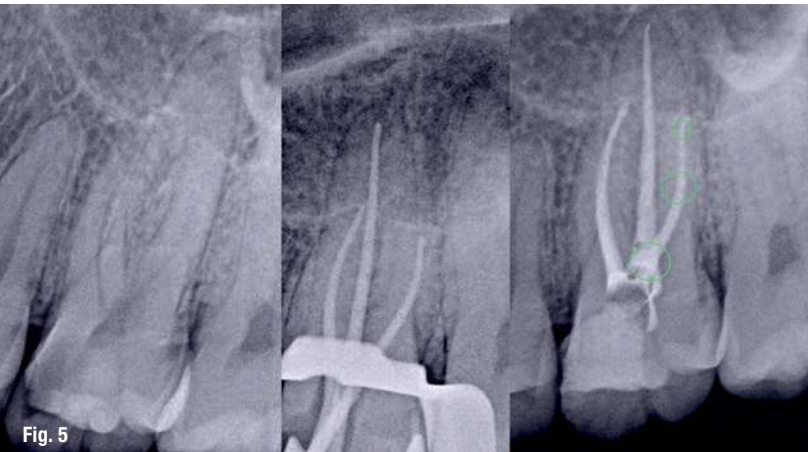

Fig. 5

Fig. 5: Root canal treatment performed with GL153 files, caries driven access was the opening of choice, despite the lack of straight-line access to the distal root, the possibility of pre-bending the files was really helpful for entering easily in the root canal. Areas at green circles are showing major stress points the files went through.

angles provides high resistance to torsional failure and the ability to maintain the original anatomy of the root canal system while enlarging it. The 10 mm active part was designed with the objective of preserving cervical radicular dentinal structure (Fig. 4), which is important for the resistance of the endodontically treated tooth,^{14,15} while the 23 degrees helical angle will prevent the screw-in effect. GL153 files are recommended to use at 500rpm with 2.5Ncm torque.

In Figure 5, it is possible to observe a root canal treatment performed on an upper molar with GL153, the endodon-

tic opening was a caries driven one for preserving dentinal structure; it is possible to notice in the radiographs that there was not a straight-line access to the distal canal. Despite the double curvature at the middle and apical third, it was possible to work safely, shaping to the complete working length, maintaining the original anatomy and a conservative enlargement at cervical radicular third at the same time.

Aurum Blue (Meta Biomed Inc.) is a four file root canal instrumentation system (Fig. 6) in stable martensitic stage, the cross section, taper, NiTi alloy and electropolish surface treatment were designed and combined together to provide a good balance between cyclic and torsional fatigue resistance and high flexibility. All files below and 25.04 are square cross section and higher sizes are convex triangular. These files are recommended to use at 500rpm with 2.0Ncm torque.

Figures 7 and 8 are examples of root canal treatments performed with Aurum Blue files. In both cases, contracted access was made to preserve the healthy dentinal structure. It is possible to notice that in both cases there was not a straight-line access to the canals. Despite the double curvature on the mesial root of tooth #17, it was possible to work safely all along the complex anatomy. In tooth #19, it was possible to manage the apical abrupt curvature in the distal canal successfully.

Current technology advances in terms of endodontic materials, digital imaging and adhesive protocols have made minimally invasive dentistry possible.^{5,16} The endodontic cavity access is one of the most important first

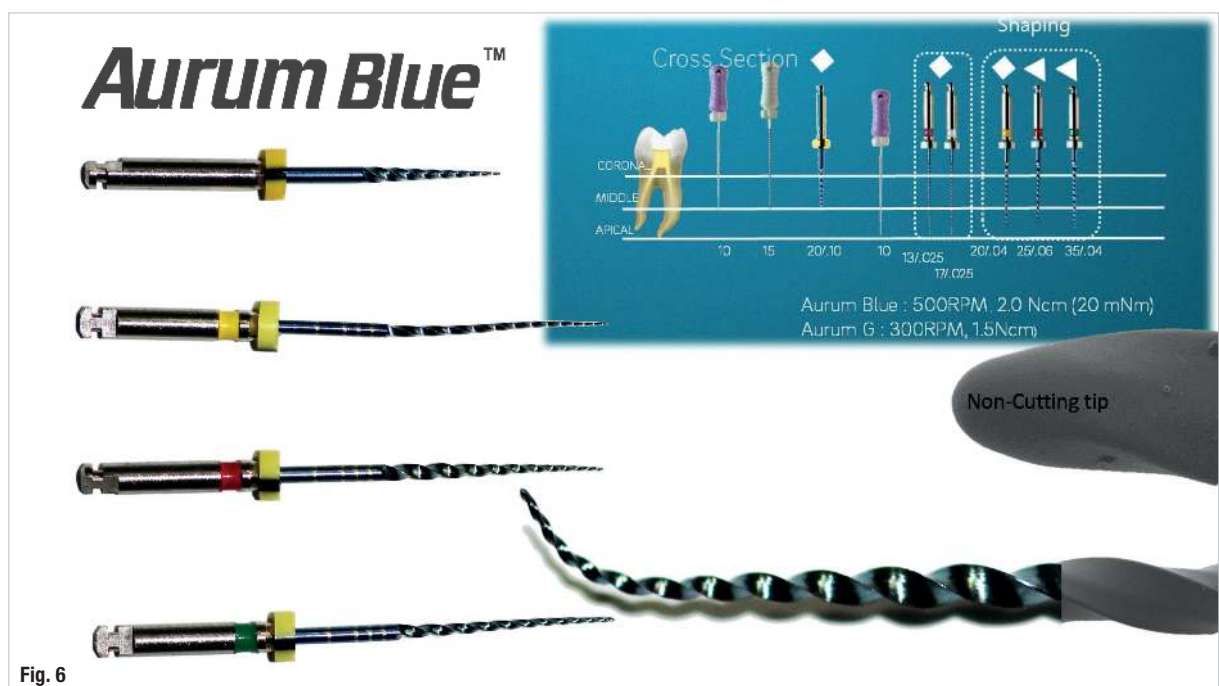


Fig. 6

Fig. 6: Aurum Blue basic sequence, 20.10 as an opener, 20.04, 25.06 and 35.04. There are additional sizes, offering the clinician a wide range of possibilities. The file choice will depend on the clinical scenario; however, 90 per cent of the cases can be managed with the basic sequence.

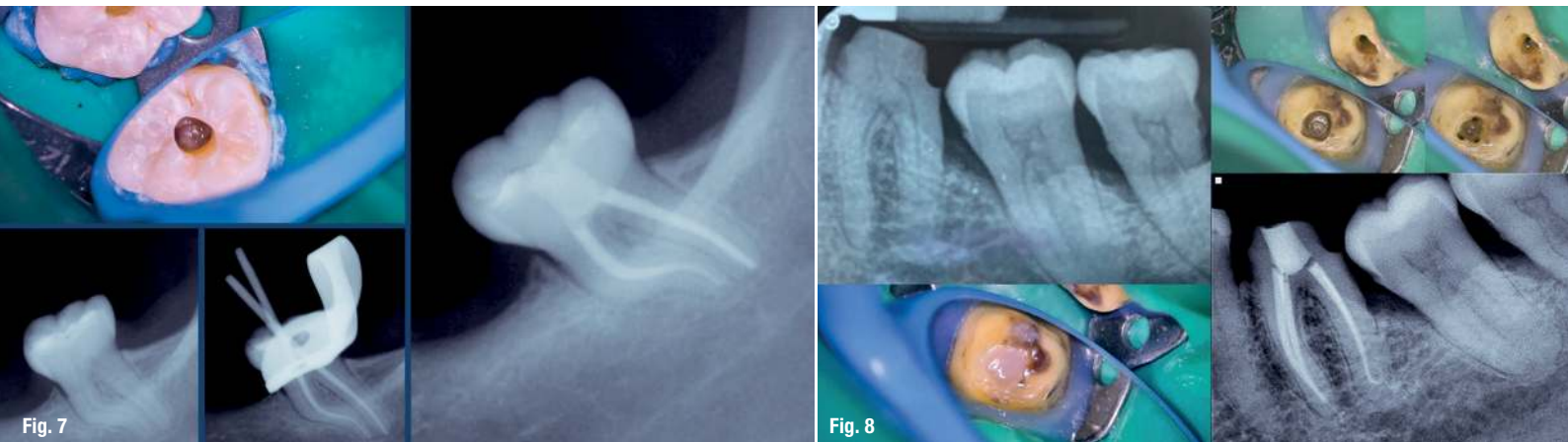


Fig. 7: Root canal treatment performed with Aurum Blue files, contracted access was the opening of choice, despite the lack of straight-line access, the possibility of pre-bending the files, cyclic fatigue resistance and flexibility were helpful to enter the root canal easily. Pictures taken under the magnification of a Seiler Alpha Air microscope. **Fig. 8:** Root canal treatment performed with Aurum Blue files. To preserve healthy dentinal structure, a contracted access was made. It was possible to manage the abrupt curvature in the apical third of the distal canal because of the high flexibility and cyclic fatigue resistance of the files. Pictures taken under the magnification of a Seiler Alpha Air microscope.

steps in the final outcome of the treatment; an inappropriate endodontic opening can make locating, negotiating, cleaning and filling the root canal system time consuming and extremely difficult to handle;^{6,7} however, the extension for prevention concept in endodontics is not advisable to be followed in this era, in which, diagnostic modern tools allow the clinician to have a better understanding of the anatomy, for an enhanced treatment planning.^{5,17}

Among the different developments in dentistry that make conservative approaches in the endodontic practice possible include flexible endodontic files with controlled memory, alloy, and enhanced cyclic fatigue resistance, visual magnification and improved illumination and cone beam computer tomography.^{3,18,19} The development of this technology was crucial in making conservative endodontics possible, prioritising the preservation of dentine, especially in the cervical region.⁵

Despite all the benefits that an operative microscope can offer during dentistry treatments regarding high quality procedures, and for the operator's posture and general comfort, it is surprising how long it took to become popular and be implemented in daily clinical practice.²⁰ The main advantage of the operative microscope is the ability to provide visual feedback through magnification and enhanced illumination, both of which are key factors for analysing the dental coronal anatomy to establish an adequate design of the access cavity.²¹

Root canal treatments are performed with the purpose of keeping teeth functioning and healthy; however, coronal fracture is a risk factor after the treatment because almost all dental pieces undergoing a root canal treatment have significantly lost dental structure. This is why maintaining as much of the dental tissue as possible during the endodontic

procedure is fundamental.¹ Although the benefits of conservative access opening have not been clearly demonstrated, there are reports indicating that contracted endodontic cavities improve fracture strength in unrestored teeth with root canal treatment, but it can also compromise other important factors such as instrumentation efficiency and increasing the risk of file separation due to cyclic fatigue.²²

If the clinician decides to go for a conservative approach, it is important to consider the fact that the absence of a straight-line access will increase the stress of the file at the most coronal point, the area in which the instruments are weaker when facing cyclic fatigue because of the large size of the core at that level.²³ The selection of high cyclic fatigue resistance files could be advisable to decrease the risk of file separation. Heat treated files in stable martensitic stage have demonstrated higher cyclic fatigue resistance when compared to super elastic nickel-titanium and stainless-steel instruments.^{10-13,24} Adequate selection of the endodontic instrumentation system to be used is an important factor to consider when performing a conservative endodontic access opening.

Editorial note: A list of references is available from the publisher.

about

Dr Jenner Argueta completed his DDS at the Universidad de San Carlos de Guatemala's dental school in Guatemala in 2011. He also earned a master's degree in endodontics from the same university in 2014. Dr Argueta is a researcher of the Guatemalan National Council for Science and Technology. He is President of the Academia de Endodoncia de Guatemala [Guatemalan academy of endodontics]. He has run a private clinical practice focusing on micro-endodontics and micro-restorative dentistry since 2011.