

laser



international magazine of laser dentistry


2²⁰¹⁶

research
Laser treatment
of gingival melanin
hyperpigmentation

case report
Diode laser treatment
of recurrent aphthous stomatitis

industry
Laser-activated irrigation with PIPS®





Master of Science (M.Sc.) in Lasers in Dentistry

Next Start: **26th September 2016**
Aachen, Germany
4 semesters

Become part of the International Dental Elite

- Create new economic potential for your practice
- Two year career-accompanying postgraduate programme at the University of Excellence RWTH Aachen
- Combination of lectures, skill training sessions, live ops, tutorials, and practical workshops
- Internationally accepted and accredited by the German Government, the European Union, the Washington Accord and the Bologna Process
- Science-based and practice-orientated on highest national and international level
- Increased patient satisfaction: minimal contact reduced vibration and pain



**RWTH INTERNATIONAL
ACADEMY
AACHEN UNIVERSITY**

RWTH International Academy
Kackertstraße 10 | 52072 Aachen | Germany
phone +49 241 80 23543 | fax +49 241 80 92525
info@academy.rwth-aachen.de
www.academy.rwth-aachen.de

PROFESSIONAL EDUCATION PROGRAMMES

AALZ

Aachen Dental Laser Center

AALZ GmbH
Pauwelsstraße 17 | 52074 Aachen | Germany
phone +49 241 47 57 13 10 | fax +49 241 47 57 13 29
info@aalz.de
www.aalz.de



Dr Georg Bach

And yet it **moves!**

Dear colleagues,

When I first learned about the content of this issue of *laser* international magazine of laser dentistry which you are now holding in your hands, the following famous quote by Galileo Galilei came to my mind: When leaving the court of inquisition, where he was forced to renounce the Copernican world view, he notoriously whispered, "And yet it moves"!

In this line, I would like to tell you that, after all, laser light does make a difference by setting things – and sometimes even people—into motion. I highly recommend this issue of *laser*; it proves a good read and illustrates this sentiment perfectly. The removal of melanin hyperpigmentation, the treatment of recurrent aphthous stomatitis or tissue biomodulation—this large of variety of laser applications leaves no doubt that laser therapy is an enrichment to dentistry. Even if our immediate environment—which forms, by the way, yet another interesting parallel to Galilei and his time—may not always be ready to accept these findings, I am convinced that the application of monochromatic and coherent light has been a substantial enhancement of the scope of dental therapy in the past decades. This is, indeed, a therapeutic gift!

The current issue of *laser* is an eloquent testimony to this view on laser dentistry. If you wish to learn more about the rich spectre of laser dentistry, you will be given ample opportunity in the upcoming weeks, as two assets of modern laser dentistry have organised exciting events this year:


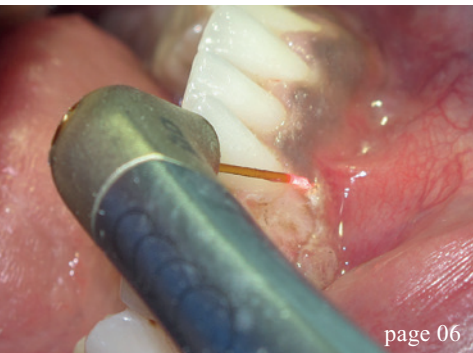
On the one hand, the 15th WFLD Congress will be held in Japan, and on the other hand, DGL will host its 25th anniversary congress in Munich, Germany, in autumn. Both of the two events feature high-calibre speakers and will guarantee an excellent scientific programme within an attractive setting. Make sure to use these opportunities!

Thus, I hope you will enjoy reading this issue of *laser* with a maximum gain in knowledge and that, furthermore, laser light will give many beneficial impulses to you and your day-to-day work.

Warm regards

Your colleague

Dr Georg Bach



| editorial

- 03 And yet it **moves!**
Dr Georg Bach

| research

- 06 **Er,Cr:YSGG** treatment of **gingival melanin hyperpigmentation**
Dr Habib Zarifeh *et al.*

| case report

- 10 **Recurrent** aphthous stomatitis
Dr Foteini Papanastasopoulou

| industry

- 14 **Biomodulation** in dentistry
Alberico Benedicenti *et al.*
- 20 **Laser-activated irrigation** with PIPS®
Dr Ralf Schlichting
- 40 Introducing LASOTRONIX—
lasers **for generations**

| practice management

- 26 Eleven **tips for success** in your dental clinic
Dr Anna Maria Yiannikos

| events

- 30 **15th International WFLD Congress**—Preview
Claudia Jahn
- 32 “I want to spend the rest of my life
studying **light**”
Claudia Jahn

| news

- 34 manufacturer **news** international
- 36 **news** international

| DGL

- 43 Und es **bewegt** doch etwas!
Dr. Georg Bach
- 44 **news** germany

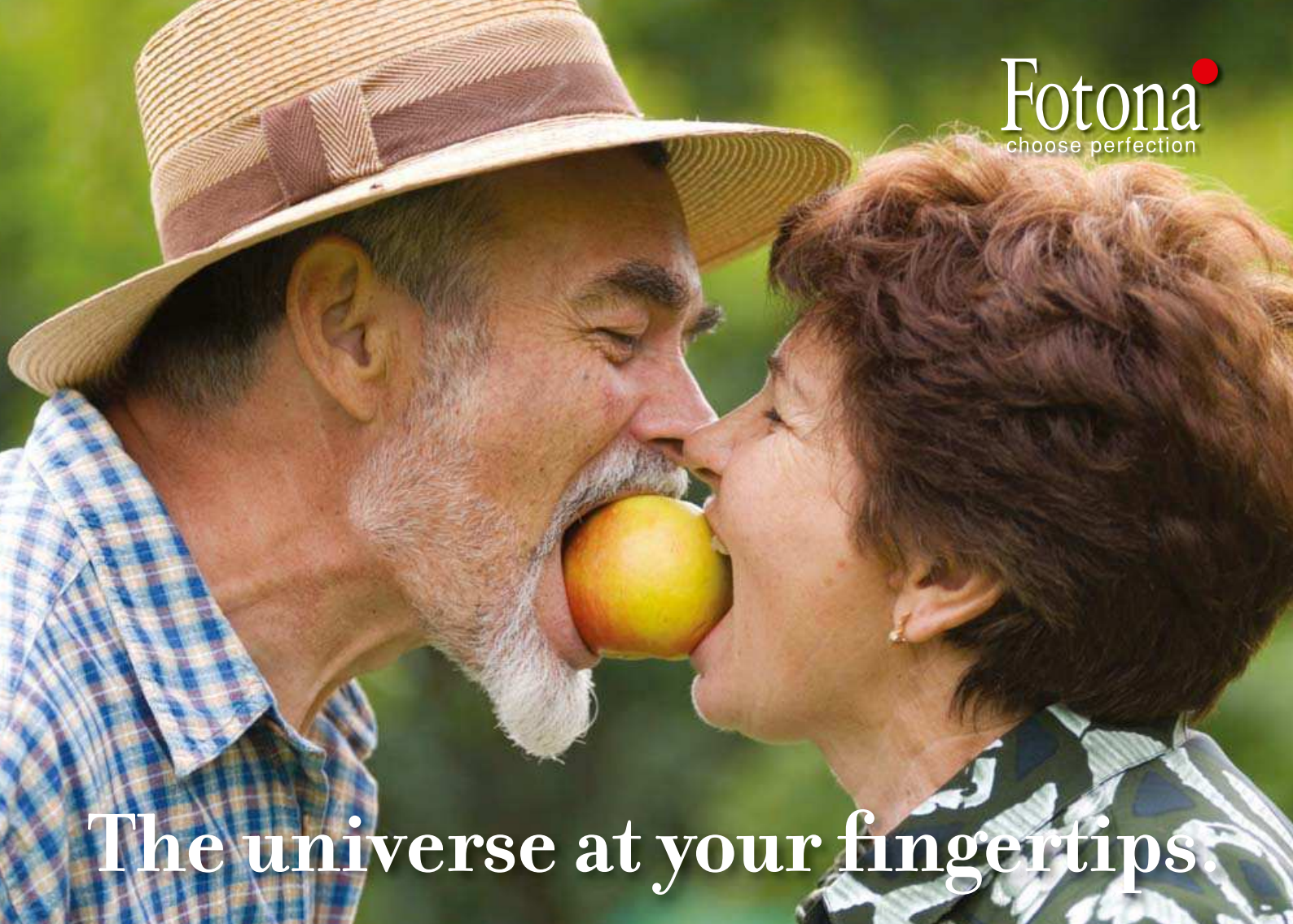| about the publisher

- 50 imprint



Cover image courtesy of Fotona,
www.fotona.com

Original Background: ©Tumanyan/Shutterstock.com



The universe at your fingertips.

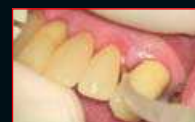TwinLight[®] Periodontal Treatment

Want to expand your practice with periodontal laser treatments?

- No need to refer patients out to other specialists
- No scalpels, no sutures
- High success rates with no need to repeat procedures
- Minimal or no-pain procedure



TwinLight[®] treatment video



Er,Cr:YSGG treatment of gingival melanin hyperpigmentation

Authors: Dr Habib Zarifeh, Dr Monique Hanna & Dr Dany Salameh, Lebanon

Introduction

In the past few decades, the improvement of intraoral soft tissue aesthetics has become a significant element in clinical dentistry, including gingiva, which is the most commonly affected intraoral tissue, causing an unpleasant appearance.^{1,2} In fact, oral pigmentation is a discoloration of the oral mucosa or gingiva due to several exogenous and endogenous factors, such as drugs, heavy metals, genetics, endocrine disturbance, and inflammation.³⁻⁵

Also, melanin produced by melanocytes can cause melanin pigmentation,³⁻⁵ varying from light to dark brown or black, according to the quantity and distribution of active melanin in the tissue.⁴ Oral pigmentation occurs in people of all races.⁶ Indeed, oral pigmentation increases in darker-skinned individuals. However, there is no difference in the number of melanocytes between fair-skinned and dark-skinned people. The variation is related to differences in the activity of melanocytes.⁷

Several procedures have been suggested for gingival depigmentation, varying from bur abrasion, surgical scraping, cryotherapy, and electrosurgery to

laser therapy. Various lasers, such as carbon dioxide (CO₂) laser, Nd:YAG laser, semiconductor diode laser, argon laser, Er:YAG laser and Er,Cr:YSGG laser, have been indicated as an efficient, pleasant and reliable method with minimal postoperative discomfort and faster wound healing for depigmentation procedures.⁸

A healthy 39-year-old male with no previous surgical history and no allergies and no current medication had a chief complaint of dark pigmented areas in the anterior part of the upper and lower maxillary gingiva, stating that he was an occasional smoker. During the clinical examination, no abnormalities nor gum disease were revealed, but deep melanin pigmentation in the upper and lower mucosa, along with the marginal gingiva, was noticed. This led to a dark gum colour and by consequence a less aesthetic smile (Fig. 1). Laser depigmentation procedure was planned. The process was explained to the patient and his consent obtained.

Digital images of the pigmented gingiva were taken preoperatively and on postoperative visits. Laser safety protocols were respected. The patient was treated with local anaesthesia. A Er,Cr:YSGG laser of

Fig. 1: Melanin pigmentation (preoperative photo).

Fig. 2: Melanin depigmentation procedure.

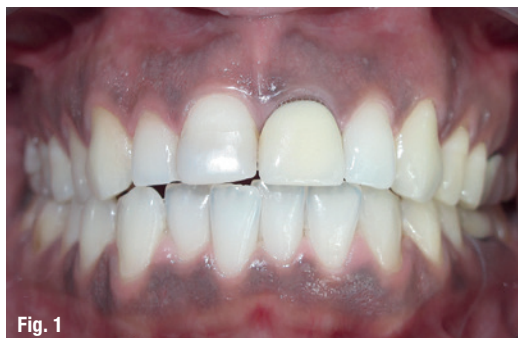

Fig. 1

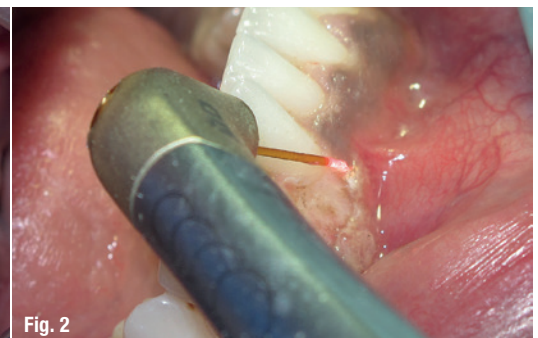

Fig. 2

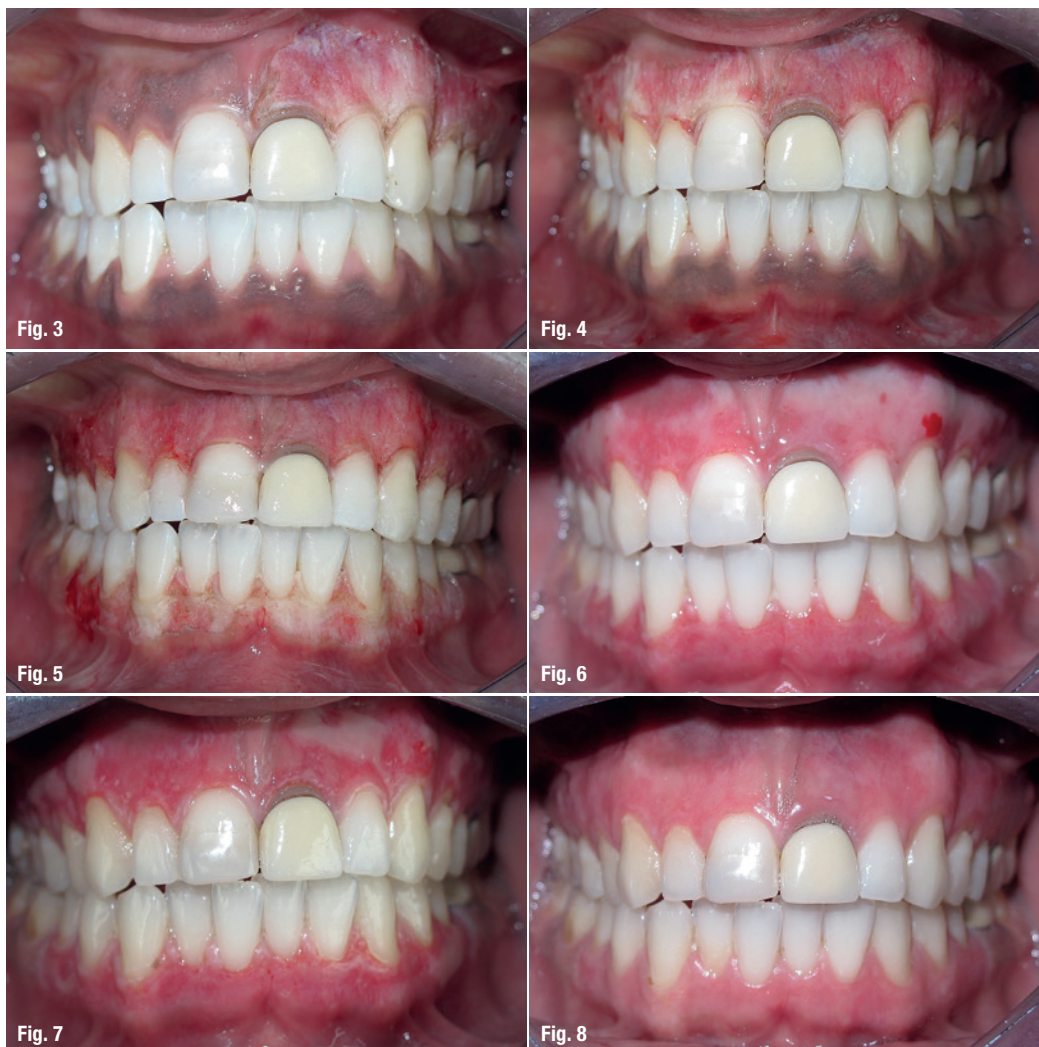

Fig. 3: Immediate comparison after depigmentation of half of the upper-maxilla gingiva.

Fig. 4: Immediate comparison after depigmentation of the upper-maxilla gingiva.

Fig. 5: Immediate postoperative photo of the depigmentation of the upper and lower maxillary gingiva.

Fig. 6: Postoperative appearance of the gingiva after two days.

Fig. 7: Postoperative appearance of the gingiva after four days.

Fig. 8: Postoperative appearance of the gingiva after seven days.

2,780 nm was used with the following parameters: gold handpiece, Z6 tip, 60% water, 40% air, H Mode, 3.0W, 20 pps, direction of the tip was slightly parallel or with 30 degree to the gum surface (Fig. 2), up to the second premolar on both the right and left side of the maxillary and mandibular anterior gingiva. We worked at a distance of 2 to 3 mm in non-contact mode with 30 degrees to the gum surface, with slow shaving movements until the removal of the pigmented layers of the epithelial cells and the connective tissue to remove melanin pigmentation (Figs. 3 & 4).

After the total removal of the pigmented layers of the gum (Fig. 5), an additional application of the Er,Cr:YSGG of 2,780 nm was done using different parameters: gold handpiece, Z6 tip, 0% water, 0% air, non-contact mode, S Mode, 2.0W, 50 pps, direction of the tip 45 degrees to the gum surface. The aim of this procedure was to dehydrate the surface of the connective tissue and by consequence melting the nerve endings, which in the end leads to a reduction or absence of postoperative pain. This method is also referred to as "laser bandage".

The patient was prescribed saline mouthwash three times daily for one week, as well as application of vitamin E three times daily for seven days and paracetamol 500 mg, two tablets every eight hours in case of pain. The patient was advised to avoid hot meals during the first couple of days after surgery.

No infection or significant postoperative complications, such as pain or bleeding, were encountered. The patient was reviewed two, four and seven days after the procedure (Figs. 6–8). The fifteen-month follow-up showed no signs of recurrence of the pigmentation.

Discussion

Numerous modalities for depigmentation have been used and described in the literature. First, removing pigmented layers can be performed by using chemical methods⁹ or surgical methods such as surgical scalpel technique¹⁰, surgical abrasion⁹, cryosurgery^{11,12}, electrosurgery¹³ and laser^{14–17}.

Chemical methods are not recommended because the chemical action cannot be restricted to the oper-

ative area¹¹. The scalpel technique is the most economical procedure compared to other methods requiring a more sophisticated armamentarium. However, this technique causes unpleasant bleeding during and after the operation, and it is necessary to cover the surgical site with periodontal dressing for seven to ten days.

Abrasion involves eliminating the epithelium of pigmented areas using a round diamond bur in a high-speed handpiece with copious irrigation.¹⁸ The use of a large-size diamond bur is recommended, because small burs do not smooth surfaces easily.⁹

Cryosurgery is a treatment method in which the tissue is destroyed by rapid freezing as described by Tal et al.¹⁹ It can be followed by considerable swelling, and it is accompanied as well by increased soft tissue destruction because of its uncontrolled depth of penetration. Electrosurgery has its own limitations because of its repetitive and prolonged use, provoking heat accumulation and undesired tissue destruction.²⁰

The documented advantages of lasers for depigmentation consist of removing the melanin pigmentation by a less invasive procedure in order to eliminate a thin layer of epithelium²¹, less bleeding during the procedure²², reduced infection, swelling and scarring^{22,23}, decreased postoperative pain²⁴, a fast healing process and increased patient satisfaction regarding aesthetics.²² The Er:YAG laser used in this case report produced the desired results efficiently. The patient was pleased with the result, which is the definitive objective of any treatment accomplished.

Yet, there is no scientific evidence to establish that laser depigmentation is superior to scalpel depigmentation. On the other hand, techniques masking pigmented gingival from less pigmented gingival areas can be done using free gingival grafts^{25,26} or acellular dermal matrix allografts²⁷.

Conclusion

Considering the results of this case report, the depigmentation procedure was successful and the patient was satisfied. It may be concluded that the application of Er,Cr:YSGG laser appears to be secure and efficient for the treatment of gingival melanin pigmentation.

Editorial note: A list of references is available from the publisher.

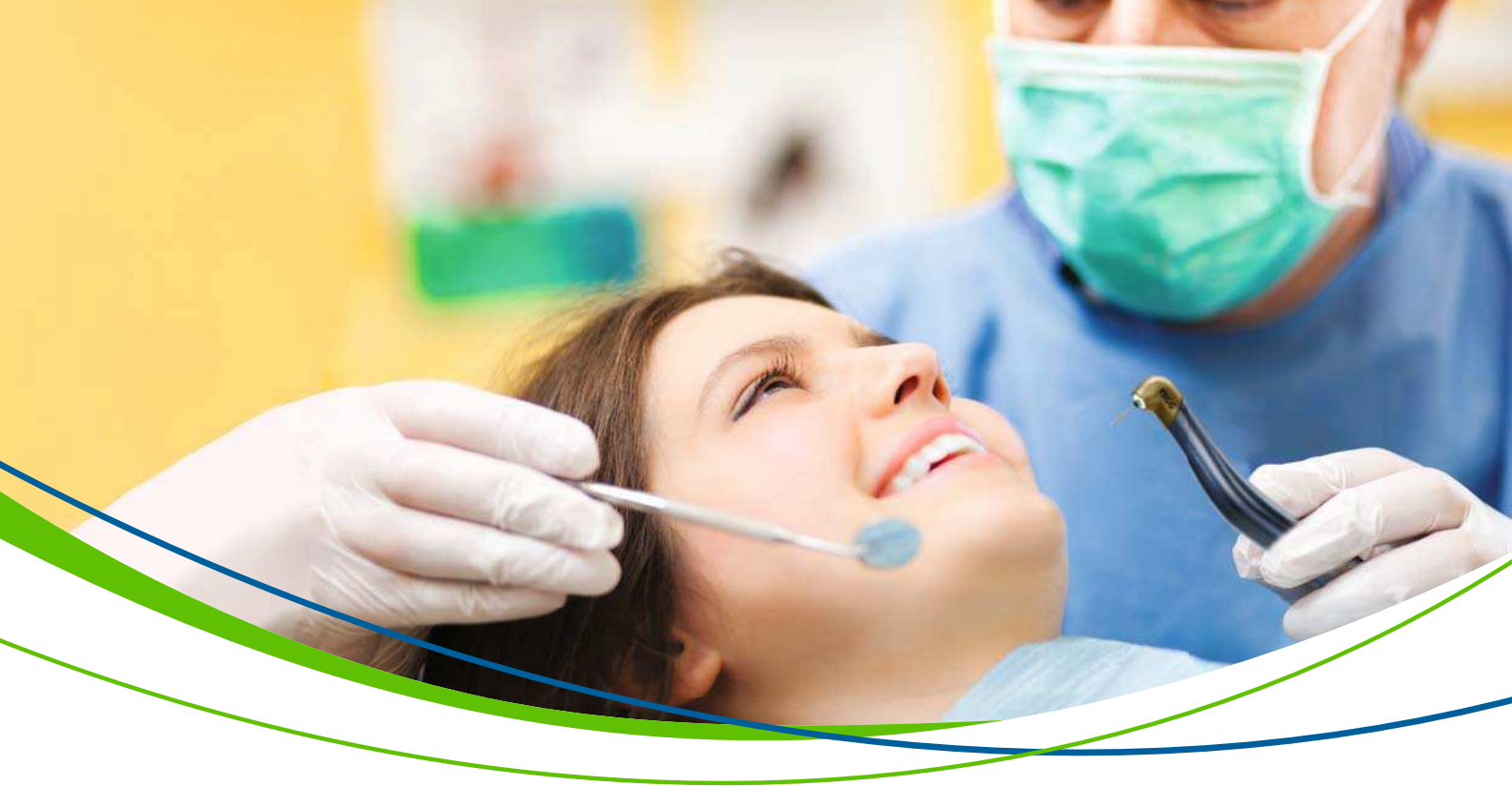contact

Dr Habib F. Zarifeh

DDS, MS in Oral surgery, MSc in Laser dentistry
RWTH Aachen University
Head Of Clemenceau Medical Center dental
department affiliated with Johns Hopkins International,
Head of HIMC Hospital dental department
Tel.: +96 11488842
Fax: +96 19933338
Habib Zarifeh, PO box: 90993, Jdeidet el-Metn, Lebanon
info@habibzarifeh.com
www.habibzarifeh.com

Kurz & bündig

Im vorliegenden Artikel vergleicht der Autor anhand einer Zusammenfassung der Erkenntnisse aus der Fachliteratur konservative Ansätze zur lasergestützten Behandlung einer Melaninhyperpigmentation der Gingiva. Ein Fallbericht aus seiner eigenen Praxis beschreibt das mögliche Vorgehen bei einer Laserbehandlung dieser Pigmentationsstörung, welche meist aufgrund einer individuellen Kombination endo- und exogener Faktoren auftritt. Im Vergleich mit der chemischen Behandlung einer Melaninhyperpigmentation oder chirurgischen Ansätzen wie der Skalpelltechnik, der chirurgischen Abrasion, Cryochirurgie oder Elektrochirurgie besitze die Lasertherapie laut Autor und Literatur bereits gut dokumentierte Vorteile: Zum einen werde die Melaninpigmentation durch ein weniger invasives Vorgehen entfernt, indem nur eine dünne Schicht des Epitheliums abgetragen werde.²¹ Des Weiteren gäbe es eine geringere Blutungsneigung²², weniger Infektionen, Schwellungen oder Narbenbildung^{22,23}, einen weniger starken postoperativen Schmerz²⁴, einen schnellen Heilungsverlauf und eine gesteigerte Patientenzufriedenheit hinsichtlich der Ästhetik.²² Im Folgenden beschreibt der Autor anhand des Falles eines 39-jährigen männlichen Patienten die lasergestützte Behandlung dunkel pigmentierter Areale im anterioren Bereich der oberen und unteren maxillaren Gingiva. Der Patient rauchte gelegentlich, wies aber darüber hinaus keine auffällige Krankengeschichte, Allergien oder Medikation auf. Im Anschluss an die Behandlung kam es zu keinen signifikanten postoperativen Komplikationen und der Patient zeigte sich hoch zufrieden mit dem ästhetischen Ergebnis. Anhand der Studienlage und des vorliegenden Fallberichts ist laut Autor der Rückschluss zulässig, dass die Anwendung eines Er,Cr:YSGG-Lasers eine sichere und effiziente Methode der Behandlung einer gingivären Melaninpigmentation sei.



The World's Most Trusted All-Tissue Laser, *Now Even Better!*

*WaterLase***iPlus*[™]

- ✦ Cut Hard-Tissue 250% Faster with Less Sensitivity¹
- ✦ World's first turnkey apps to assist in the management of periodontitis and peri-implantitis
- ✦ Unrivaled versatility, providing unmatched results in treatment outcomes and outstanding ROI
- ✦ Open a new world of clinical capabilities with the most intuitive and easy-to-use graphic user interface
- ✦ SureFire™ Delivery System, ergonomically designed for enhanced flexibility, increased precision, and maximum uptime

Limited Time Offer*

Last Chance to trade-in your old all-tissue laser towards a WaterLase iPlus. Contact your distributor for details.



BIOLASE

biolase.com

Contact your BIOLASE Authorized Distributor
to your upgrade your practice to *WaterLase Dentistry*.

©2016 BIOLASE, Inc. All rights reserved. *Trade-in program ends on 9/30/2016. ¹ Data on file