

# DENTAL TRIBUNE

The World's Dental Newspaper • Pakistan Edition

PUBLISHED IN PAKISTAN

www.dental-tribune.com.pk

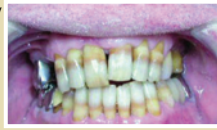NOVEMBER, 2014 - Issue No. 06 Vol.1

New research ties tobacco use to higher risk of oral HPV infection



► Page 2

Contribution of CAD/CAM technology in dental implantology



CLINICAL PRACTICE

► Page 4

Karachi first ever Style Italiano Restorative Workshop



► Page 8

## Karachi first ever Style Italiano Restorative Workshop



President PDA encourages students to attend the forthcoming Symposium



### DT Pakistan Report

**K**ARACHI: Keeping up with its tradition of bringing the dental fraternity together with outstanding symposiums, seminars and other related events, the very first Style Italiano Restorative Workshop was organized on the 19th of October at Pearl Continental Hotel, Karachi, in collaboration with Pakistan Dental Association. Amidst countless uncertainties pertaining to the political scenario and law and order situation of the

city, the workshop received an overwhelming response and was attended by house officers, trainee residents, private practitioners and students from leading institutes of Karachi and Hyderabad.

The Expert Symposium started with the recitation from the Holy Quran followed by the National Anthem. The programme started on time with the lecture of Dr Arshad Hasan, Head of the

*Continued to page 08*

### DT Pakistan Report

**K**ARACHI: Dr Saqib Rashid, President Pakistan Dental Association (PDA) addressed the participants of the Style Italiano Restorative Workshop, and encouraged them to attend similar events and workshops arranged in the future as they offer an excellent learning platform for all aspiring dental practitioners.

He invited them to attend the forthcoming PDA Symposium to be held on the 30th of November. The event was previously postponed owing to the uncertain political, and law and order situation of the city, keeping the safety of participants in mind.

Upon its initial announcement, the Symposium had received an overwhelming response. Distinguished professionals of Pakistan's dental community will be presenting their lectures at the event and hand-on workshops will also be organized. He stated that the Pakistan Dental Association has organized the Symposium aiming to equip young minds with new skills, techniques and knowledge and that all students must register for it.

## FDI Annual World Dental Congress held in India



### DT International Report

**N**EW DELHI, India: After a decade, the Annual World Dental Congress of the FDI World Dental Federation made its first return to India. Over a period of four days, dental professionals, public health stakeholders and the dental industry came together in Greater Noida near

professionals came to India from all over the globe.

It is the second time that India hosted the prestigious dental event since 2004. While the country has made large strides since then in the improvement of health and now boasts the world's largest dental workforce,

*Continued to page 11*

New Delhi to discuss and exchange information on the newest methods and concepts in dentistry, as well as the latest issues and developments concerning oral health. From India alone, the organisers expected more than 10,000 participants to attend the event, which was held at the India Expo Centre and Mart in Greater Noida, a satellite town with a population of 100,000 outside the Indian capital. They were joined by hundreds of dental

# New research ties tobacco use to higher risk of oral HPV infection



## DT International Report

**B**ALTIMORE, USA: A recently published study has shown that infection with the oral human papillomavirus Type 16 (HPV 16), which is also thought to cause oropharyngeal cancer, is more common among people who have recently used or been exposed to tobacco. The researchers found that even modest tobacco use, like three cigarettes per day, is associated with higher oral HPV prevalence.

The study included 6,887 participants, who were originally enrolled in the National Health and Nutrition Examination Survey, a program of studies designed to assess the health and nutritional status of adults and children in the U.S. Current tobacco users accounted for 28.6 percent (2,012) of the study population and 1 percent (63) were infected with HPV 16.

Examination of blood and urine, as well as oral rinsing and gargling to collect mouth and throat cells, found that participants with higher levels of tobacco-related biomarkers in their blood and urine, which can come from any tobacco source—even secondhand smoke—were more likely to have oral HPV 16 DNA compared with those who had no detectable levels of the compounds, explained Dr. Carole

Fakhry, an assistant professor of otolaryngology—head and neck surgery at the Johns Hopkins University School of Medicine, where the study was conducted. According to the study, oral HPV 16 prevalence was greater in current tobacco users (2.0 percent) than in former tobacco users or those who had never consumed tobacco (0.6 percent).

In addition, a dose-response relation was found. The equivalent of three cigarettes per day increased the risk of HPV 16 by 31 percent, and the equivalent of four cigarettes per day increased the risk by 68 percent.

HPV 16 is primarily transmitted through oral sex, and current tobacco users in the study were more likely to have a higher number of lifetime oral sexual partners compared with nonusers. Thus, although the study found an independent relationship between tobacco use and HPV 16 infection, it cannot be ruled out that participants who used more tobacco might also have had more oral sex and were therefore at higher risk of infection.

The study, titled “Tobacco Use and Oral HPV-16 Infection,” was published in the Oct. 8 issue of the Journal of the American Medical Association.

## Chicago Crash claims the lives of three gifted Pakistani doctors



## DT Pakistan Report

**C**HICAGO: According to the NTSB investigators, an airplane headed towards Lawrence disappeared off radar and later crashed near a suburban area of Chicago on the eve of Sunday. The investigators confirmed that three passengers killed in the crash were identified as Dr Tausif Rehman M.D., Dr Ali A. Kanchwala M.D. and Dr Maria Javid Kanchwala M.D. Dr Rehman was an esteemed neurosurgeon at Cotton-O’Neil Topeka, Dr Ali was a pulmonologist at the same clinic, and Dr Maria was an interventional cardiologist at the Kansas City Providence Medical Center.

The plane reportedly crashed in the Palos

Hills area on an empty lot, and therefore did not cause any casualties on the ground. According to the reporters, the three passengers on board were flying to Chicago for a shopping trip. Only five minutes after it had left the Midway Airport in Chicago, the plane crashed after it was lost on the radar.

Based on the debris scatter and damage at the scene, the investigators have assumed that the six-seat plane had made a ‘nose-dive’ crash landing. John Brennan, a National Transportation Safety Board air safety investigator, explained that the aircraft had impacted at an almost vertical position.

*Continued to page 11*

# DENTAL TRIBUNE

The World's Dental Newspaper • Pakistan Edition

### Publisher/CEO

Syed Hashim A. Hasan  
hashim.hasan@dental-tribune.com.pk

### Editor Clinical Research:

Dr. Inayatullah Padhiar

### Editors Research & Public Health

Prof. Dr. Ayyaz Ali Khan

### Editorial Executive

Dr. Tehmina Khan

### Editor - Online

Haseeb Uddin

### Graphics Designer

Sh. M. Sadiq Ali

### Dental Tribune Pakistan

3rd floor, Mahmood Centre, BC-11, Block-9  
Clifton, Karachi, Pakistan.

Tel.: +92 21 35378440-2 | Fax: +92 21 35836940

www.dental-tribune.com.pk info@dental-tribune.com.pk

Dental Tribune Pakistan cannot assume responsibility for the validity of product claims or for typographical errors. The publisher also does not assume responsibility for product names or statements made by advertisers. Opinions expressed by authors are their own and may not reflect of **Dental Tribune Pakistan.**

## International Imprint

### Group Editor

**Daniel Zimmermann**

newsroom@dental-tribune.com

Tel.: +49 341 48 474 107

### Clinical Editor

**Magda Wojtkiewicz**

### Online Editors

**Yvonne Bachmann**

**Claudia Duschek**

**Sabrina Raaff**

**Hans Motschmann**

### Copy Editors

### Publisher/President/CEO

**Torsten Oemus**

### Chief Financial Officer

**Dan Wunderlich**

### Business Development Manager

**Claudia Salwiczek**

### Events Manager

**Lars Hoffmann**

### Media Sales Managers

**Matthias Diessner**

(Key Accounts)

**Melissa Brown**

(International)

**Peter Witteczek**

(Asia Pacific)

**Maria Kaiser**

(North America)

**Weridiana Mageswki**

(Latin America)

**Hélène Carpentier**

(Europe)

### Marketing & Sales Services

**Nadine Dehmel**

**Nicole Andrä**

### Accounting

**Karen Hamatschek**

**Anja Maywald**

**Manuela Hunger**

### Executive Producer

**Gernot Meyer**

### Dental Tribune International

Holbeinstr. 29, 04229 Leipzig, Germany

Tel.: +49 341 48 474 302 | Fax: +49 341 48 474 173

info@dental-tribune.com | www.dental-tribune.com

### Regional Offices

#### Asia Pacific

Dental Tribune Asia Pacific Limited

Room A, 20/F, Harvard Commercial Building,

105–111 Thomson Road, Wanchai, Hong Kong

Tel.: +852 3113 6177 | Fax: +8523113 6199

#### The Americas

Tribune America, LLC

116 West 23rd Street, Ste. 500, New York, N.Y. 10011, USA

Tel.: +1 212 244 7181 | Fax: +1 212 244 7185



CROIXTURE

PROFESSIONAL MEDICAL COUTURE



THE NEW 2014-2015 COLLECTION

EXPERIENCE OUR ENTIRE COLLECTION ON [WWW.CROIXTURE.COM](http://WWW.CROIXTURE.COM)

# Contribution of CAD/CAM technology to implant-supported screw-retained restorations

## Use of a full-arch bridge in the maxillae: A case report

Author Dr Richard Marcelat, France

In dental implantology, the optimal and truly passive fit of the framework is essential for the long-term success of a restoration owing to the physiology of bone tissue around implants. For a multiple-unit implant-supported restoration, the traditional pouring technique is rather complex and challenging. The difficulty of achieving a passive fit is directly correlated to the number of components used and the volume of the framework. CAD/CAM technology provides such a high level of accuracy that it has revolutionised the field of restorative dentistry.

Today, many implant manufacturers collaborate with industrial companies to develop state-of-the-art machining solutions for their implant-supported frameworks. In that regard, the concept developed by Sameda (Anthogyr) is innovative and supported by many years of proven success in the fabrication of CAD/CAM dental restorations. The major advantage of CAD/CAM technology is that it guarantees a highly accurate and predictable fit ( $< 10 \mu$ ). This clinical case report demonstrates the high potential of this novel digital solution.

### Patient presentation

The male patient was a former smoker and 51 years old when the treatment was initiated. He presented with high blood pressure and took Tahor (pFizer) on a daily basis. In addition, he had been on Kardegic (Sanofi) therapy since a heart attack in 2005. For functional and aesthetic reasons, he wanted a fixed prosthesis in his maxillary arch (Figs. 1a & b).

### Debridement and pre-implant surgery

Owing to the periodontal condition of his remaining maxillary teeth, all of them were atraumatically removed. Then, mechanical debridement was performed through alveolar curettage and copious irrigation with Betadine. A maxillary complete overdenture was fabricated and placed on the same day of the extractions.

After a healing period of four months, DentaScan images (GE Healthcare) were obtained to evaluate the bone height. The scans showed significant bone resorption in the posterior sections of the maxillae (Figs. 2a-c): SA-4, according to Misch's classification, since the residual ridge height was less than 5 mm. Sinus grafting was deemed necessary and implant placement had to be delayed by five to six months, until complete healing and good initial stability had been achieved.

Bilateral sinus lift was performed under local anaesthesia from a lateral approach using the technique described by Tatum. The Schneiderian membrane was lifted gently. As there were no perforations, platelet-rich fibrin was used for coverage of the sinus floor. Maxgraft (botiss biomaterials) allografts were placed to elevate the maxillary sinus floor, and then covered with a Bio-Gide (Geistlich) collagen membrane and platelet-rich fibrin.

After a healing period of five months, the patient underwent a CT scan wearing a scan prosthesis of acrylic resin and commercially available teeth for visibility of the desired tooth location in the CT images. The CT examination showed adequate bone volume in the grafted posterior regions and an even sinus floor with homogeneous allografted areas. The dome-like shape of the vestibulo-lingual crosssections was indicative of the absence of material leakage into

the maxillary sinuses (Fig. 5a).

### Osteogenic activation

I performed osteogenic activation of the processed maxgraft bone used for sinus lift using the technique described by Scortecchi.

A trans-parietal approach was used for insertion of the Bone Matrix Osteotensor (Victory) after a minimally invasive flapless protocol. Endosteal stimulation results in osteogenic activation and allows evaluation of the mechanical strength of the grafted areas by probing. Owing to this simple and minimally invasive technique, the initial quality of the future recipient bone site is easily assessed.

These techniques have been successfully used in orthopaedics for ten years. In view of the excellent response to osteogenic activation, it was decided that implants would be placed 45 days later.

### Treatment planning

The case was planned in the SIMPLANT (DENTSPLY Implants) treatment planning software. The scan prosthesis is critical for determination of the correct position and axial alignment of the implants; visualisation of the emergence profile; and determination of the size, position and axial alignment of the abutments. Furthermore, it allows optimal use of the available bone height. At this stage, special attention should be paid to 3-D positioning of the implants and particularly to the emergence profile in order to facilitate the fabrication process of the final restoration. Straight or angled conical abutments are now clearly visible on the vestibulo-lingual cross-sections. Ten Axiom PX implants (Anthogyr) were planned for a maxillary screw-retained bridge restoration (Figs. 5a-c).

### Implant placement

Implant placement was performed under local anaesthesia using the case-specific surgical guide. For this patient, I used a specific implant design (Axiom PX, Anthogyr) with symmetrical double-lead threads (selfdrilling and self-tapping) and a reverse conical neck. Its unique design, combined with a special drilling protocol, promotes bone condensation even in soft bone, ensuring excellent initial fixation. The BCP (biphasecalcium phosphate) sandblasting technique yields an implant surface with superior osteoconductive properties that positively influence the development of osteoblastic cells in the early stage of osseointegration. A flapless technique was used for implant placement. The flapless technique has definite advantages: preservation of the subperiosteal blood vessels, and improved patient comfort owing to a shorter operating time and simple post-operative care.

### Temporary bridge and immediate loading

It was agreed with the patient that the implants would be immediately loaded, provided that good initial stability was obtained. The temporary removable prosthesis would be worn for a limited period. Fortunately, adequate stability was achieved, allowing for immediate loading. Each implant (except #27) was torqued to 35 Ncm or more. On the same day, an impression was made using the pick-up technique, with a previously prepared impression tray. First, the final straight conical abutments were hand tightened into the implants

The Axiom PX implant system offers two major

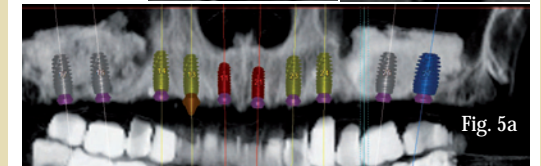
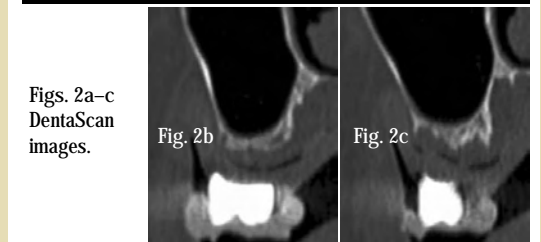
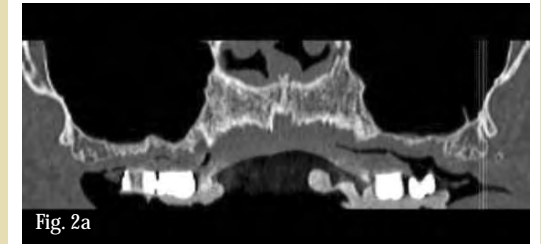
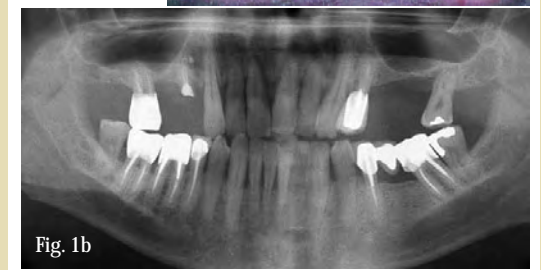
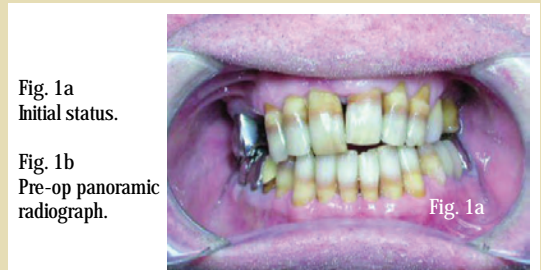
Fig. 5a Implant placement planning in SIMPLANT (DENTSPLY Implants) software.  
Fig. 5b Implant placement planning in SIMPLANT (DENTSPLY Implants) software.  
Figs. 5c-d CT cross-sections.

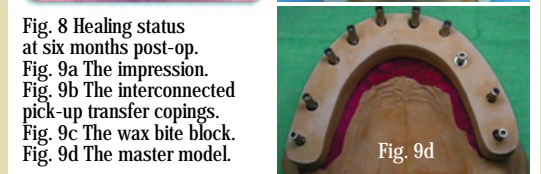
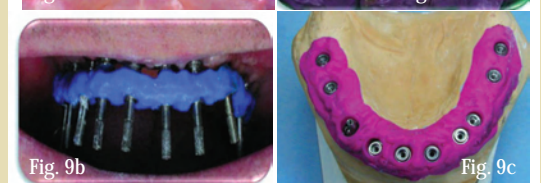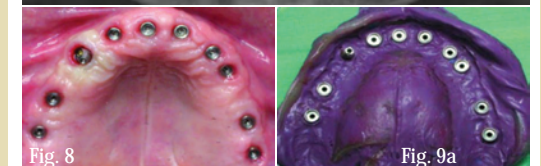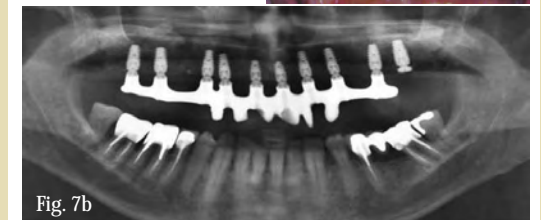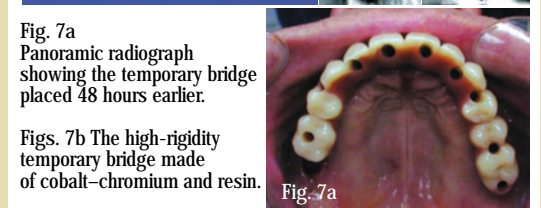
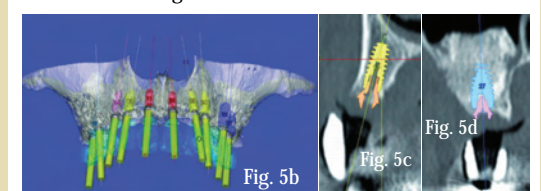


Fig. 8 Healing status at six months post-op.  
Fig. 9a The impression.  
Fig. 9b The interconnected pick-up transfer copings.  
Fig. 9c The wax bite block.  
Fig. 9d The master model.

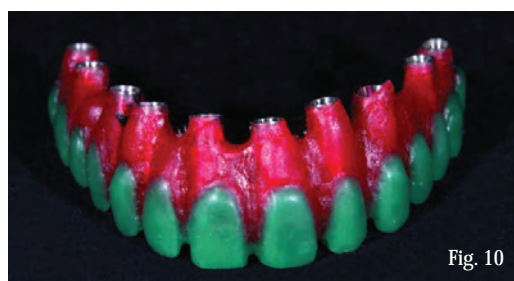

Fig. 10



Fig. 11a

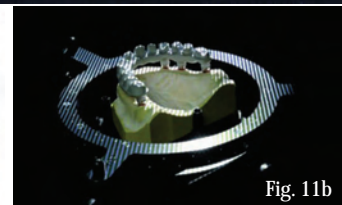


Fig. 11b

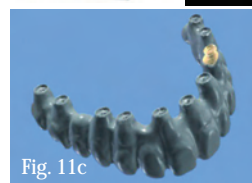

Fig. 11c

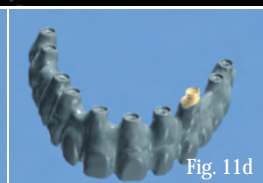


Fig. 11d

Fig. 10 A wax-up of the framework.  
Figs. 11a-d CAD of the model.



Fig. 12a

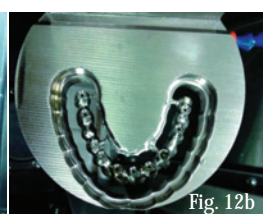

Fig. 12b



Fig. 12c

Figs. 12a-c Machining from a titanium block.

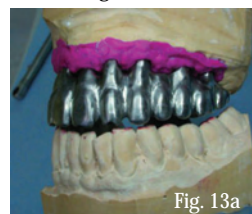


Fig. 13a

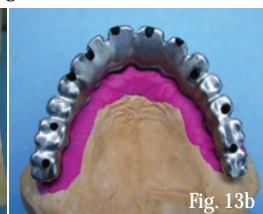

Fig. 13b

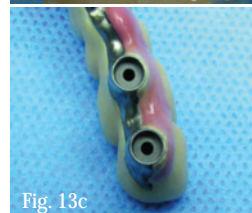

Fig. 13c

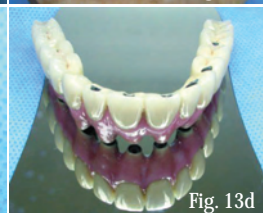

Fig. 13d

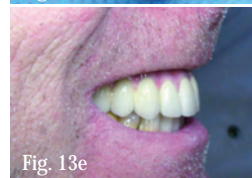

Fig. 13e

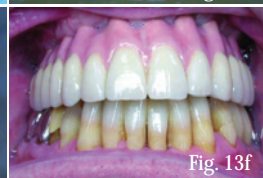

Fig. 13f

Figs. 13a & b The machined titanium framework.  
Figs. 13c-f The final bridge.

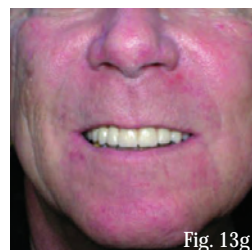

Fig. 13g

Fig. 13g The patient's new smile.

Fig. 13h A post-op panoramic radiograph with the bridge in place.

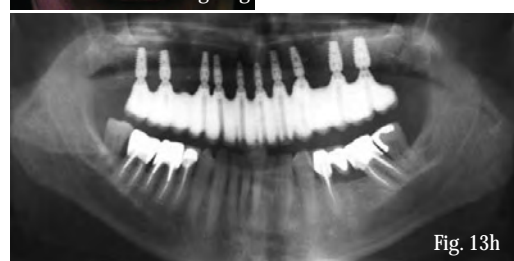


Fig. 13h

advantages: platform switching and indexing trilobe morse taper connection. The latter greatly facilitates abutment placement. A tight stable connection guarantees integrity of the soft tissue (Fig. 8).

In the laboratory, the master model with the embedded analogue was used to fabricate a master plaster cast. A high-rigidity cobalt-chromium and resin temporary bridge was fabricated, tried in, and transferred to the patient's mouth 48 hours after the implants had been placed. This provisional device would serve as an external fixator during osseointegration of the implants.

A control radiograph was taken to confirm the passive fit of the framework. The temporary bridge was hand tightened to a torque of 10 Ncm. The occlusion was accurately adjusted (Figs. 7a-b). The patient wore the temporary bridge for six months. During that period, a number of parameters were evaluated, including occlusion, osseointegration status, oral hygiene, mastication, phonetics, aesthetics and lip support. The temporary bridge should be rigid (framework) and easily removable (screw fixation). Site #27 healed uneventfully, protected as it was from mechanical stress.

### Final bridge

At the end of the six-month healing period, preparation for the final restoration began. Wearing the temporary bridge had allowed adjustment of the abovementioned parameters (e.g. aesthetics, phonetics and lip support) and validation of the vertical dimension and intermaxillary relationship.

The temporary bridge was removed, an implant stability percussion test was performed, and control radiographs were taken. The straight conical abutments that had been placed concomitant with the implants were tightened to 25 Ncm (as recommended by the manufacturer), except abutment #23, which was angled (Fig. 8).

An impression of the final bridge was taken with the same impression tray used for the temporary bridge.

Pick-up transfer copings were interconnected using LuxaBite resin (DMG), and the impression was made using Impregum (3M ESPE). The master model, including the conical abutment analogues and silicone soft tissue (representing the patient's gingiva), was fabricated and then validated in the dentist's office via a wax bite block (into which extra-hard plaster material was poured). The wax bite block was then tried in (Figs. 9a-d).

Using silicone indices (vestibular, occlusal and palatal) from the temporary bridge, a wax-up was fabricated in the laboratory (Fig. 10). The wax-up had to meet the aesthetic demands of the patient and be an exact replica of the temporary bridge (both anatomically and aesthetically). The validated master model and wax-up were sent to the SIMEDA machining centre, where the master model was scanned and a CAD model was designed (Figs. 11a-d). A PDF 3-D file is used to validate the design, after which the manufacturing process can be initiated. All pieces are machined from titanium blocks using high-precision five-axis milling machines (Figs. 12a-c).

Titanium is a lightweight material and, more importantly, it is highly biocompatible and has superior mechanical properties. It is four times lighter than commonly used semiprecious alloys. Actually, it is the lightest metal used in dentistry. Furthermore, titanium is a self-passivating metal: it readily reacts with oxygen in air to form a tough layer of oxide, which protects against corrosion. Titanium is known to resist corrosion and chemical attacks extremely well. Furthermore, it is bactericidal, a key advantage for dental implants.

Material density is a crucial factor in implantology. We believe that the weight of a maxillary implant-supported prosthesis is the most important factor for the outcome of the restoration.

A few days later, we received the framework for try-in. It had a perfect passive fit and was returned

to the laboratory for veneering. The metal preparation in the laboratory entailed sandblasting, titanium etching and the application of opaque porcelain to conceal the metal core. The bisque-baked restoration was then tried in to allow the patient to validate the aesthetics of the restoration. This step is necessary to assess static and dynamic occlusion and perform minor adjustments (Figs. 13a-g). The bisque-baked restoration was then returned to the laboratory for fine tuning and glazing.

### CAD/CAM benefits

Although conventional casting techniques have evolved, they are still fraught with inaccuracies owing to the nature of the materials and to their handling. This includes the risk of errors during investment processing, risk of metal deformation and poor metal homogeneity. The CAD/CAM technologies used for producing metal frameworks are essential to the quality of the final restoration. The CT scan data is converted into a format that allows the 3-D images to be utilised by the selected treatment planning software. The case is then planned in the software.

The CAD software has databases that allow the creation of virtual models for the desired restoration using different materials, including zirconia, titanium, cobalt-chromium, IPS e-max and PMMA.

If the dental laboratory has its own scanner, an STL file is sent directly to the production centre by e-mail. Otherwise, both the model and the wax-up are forwarded to the production centre by courier.

If the computer settings are correct, one is ensured of perfect reproducibility in the manufacturing process and consistency in the result (i.e. a truly passive framework fit). Optimal setting of the coping thickness parameter or the pontic connection parameter may prevent torsion or deformation of the framework during firing of the ceramic. Subtractive manufacturing, combined with digital modelling, eliminates the risk of alteration of the material structure. The resulting metal framework will have optimal homogeneity and density.

As regards fabrication of implant superstructures, machining is the technique of choice for achieving high precision and near passive fit. Practitioners can expect consistent and reproducible results, excellent framework fit, and regular, accurate prosthetic seals.

### Conclusion

Today, dental laboratories are using high-tech scanning equipment, which allows digitisation of the master model (to determine the implant index) and the wax-up. CAD/CAM offers a level of quality and accuracy unsurpassed by any of the traditional techniques. Passive fit, which is critical to the outcome of an implant-supported prosthesis, is a determinant of the long-term success of a restoration. Passive fit of the framework for a long-span restoration is much easier to achieve and reproduce with CAD/CAM than with the traditional pouring techniques.

The use of CAD/CAM machining for implant-supported restorations guarantees a highly accurate and predictable framework fit (< 10 µ). In addition, machining centres can produce restorations using fully biocompatible materials, such as titanium and zirconia. In order to take advantage of the accuracy of CAD/CAM, using safe and reliable implant systems with superior biological and biomechanical characteristics is required.

CAD/CAM will soon be essential. Current CAD/CAM solutions are easily accessible to any dentist and do not require fundamental changes to his or her work habits.

*Acknowledgement: Special thanks to G. Nauzes and J. Bellany, laboratory technicians at Socalab.*

## World's Best Goalkeeper sits for dental impression for Madame Tussauds



### DT International Report

**B**ERLIN, Germany: Manuel Neuer, currently the World's Best Goalkeeper, has attended a sitting to be measured for the creation of his wax twin, which is soon to be exhibited in Madame Tussauds wax sculpture museum in Berlin. In addition to body size, and eye and hair colour, the experts from London needed a dental cast to create a true-to-life smile for the wax figure.

The 28-year-old goalkeeper, who together with his team won this year's World Cup, has achieved many football successes: World's Best Goalkeeper in 2013, German footballer of the year in 2011 and 2014, Golden Glove Award in 2014, UEFA Champions League winner in 2013 (FC Bayern München).

"Manuel Neuer is one of the most popular football players and since the World Cup the most desired football figure of our visitors," said Sandra Schmalzried, General Manager of Madame Tussauds Berlin. "We would love to show the whole world champion team; however, unfortunately, at a cost of approximately €200,000 per figure that is not possible." Thus, Neuer's wax figure will represent the entire national team.

For the sitting, during which all of the necessary measurements were captured, a Madame Tussauds team of three travelled all the way from London with several boxes of equipment. With a tape measure and callipers, they took 226 measurements and more than 150 photographs of Neuer's head and body from different angles. Using colour scales, his skin, hair and eye colour were determined.

### Dentures produced by external dental laboratory

Even though a small part of the body, the wax figure's teeth require precise work and collaboration with a dental laboratory. "When we meet the celebrity for a sitting, we create a dental impression, like a dental cast, which we cast out of silicone or putty. We then send this straight to the dental laboratory to replicate and create a denture," a Madame Tussauds wax artist explained to Dental Tribune ONLINE.

"When we receive the teeth, the gingivae are made out of wax and the teeth from acrylics. We analyse them, look at them and check measurements. We try them in the wax head by inserting them through the neck. If they are signed off by the senior sculptor, we send them back to the same dental laboratory for processing. The wax gingivae are replaced with hard acrylic, a type of resin used for manufacturing dentures. When we receive the final set, we reinsert them through the neck to be fitted properly into the wax figure's head."

For historical figures, or when the wax figure creators are not able to meet with a celebrity and take a dental impression, they create a research file of information about that person's teeth, containing photographs of him or her smiling and photographs that show his or her gingival colour. They blow up the photographs to be life-size and then the dental laboratory produces a set of dentures based on the information they have collated, including measurements, and tooth and gingival shades—always working from an anatomical standpoint to ensure that the teeth would function in theory in an actual head.

### Wax figure reflects personality and character

During his sitting, Neuer was also closely observed by the wax artists to establish every detail, including the way he

*Continued to page 11*

## Barts study on severe periodontitis reveals looming crisis



### DT International Report

**L**ONDON, UK: Figures by the National Health Service indicate that at least one in 15 adults in the UK currently suffers from the most severe form of periodontal disease. Worldwide, the situation looks even more devastating with the condition to be found in roughly 11 per cent of the earth's population. An international review published by researchers from Barts and The London School of Medicine and Dentistry and dental institutions in Australia and US in the Journal of Dental Research has recently provided the first insights into the global dynamics of the disease and where it is most prevalent.

According to the paper, prevalence as well as incidence of severe periodontitis was reportedly highest in East Sub-Saharan Africa and most parts of South America. Several countries including Australia, Indonesia or Greece, among others, also ranked below the global average.

Regions with low occurrence were North America, followed by developed countries in the Asia Pacific region, as well as Oceania and Western Europe.

While no statistically relevant difference could be found between genders, the researchers said the condition seemed to increase with age throughout all surveyed countries. Hence, people at age 38 and beyond are most at risk for developing severe periodontitis.

Overall, the study found that more than 700 million new cases of severe periodontitis worldwide add to the already large burden every year, which makes the condition rank among the six most prevalent diseases worldwide. If untreated, it can lead not only to physical pain and psychological discomfort, but also to functional limitation, as well as physical and psychological disabilities, according to the author, Director of Research at Barts Health NHS Trust Prof. Wagner Marcenes, who headed the study.

"The number of severe periodontitis cases has increased dramatically between 1990 and 2010. Since we did not include other types of periodontitis such as its mild and moderate forms, we are facing an even more serious problem in the population's oral health," he commented on the results.

He said that the data are currently being evaluated further to find out what might cause this high prevalence including socio-economic indicators and other risk factors.

One of the largest assessment ever conducted on the disease, the review was looking at epidemiological data from more than 70 studies involving 300,000 patients from 37 countries. While it provides insight into the realities of the disease, according to the researchers, the results will have to be treated with caution owing to the problem on how to actually measure periodontal disease. A new standard introduced by the American Academy of Periodontology and the US Centres for Disease Control and Prevention in 2007, for example, made it difficult to compare any data collected prior.

In the report, the researchers indicated any site with Community Periodontal Index of Treatment Needs 4, clinical attachment of larger than 6mm and pocket depth of 5 as periodontitis.

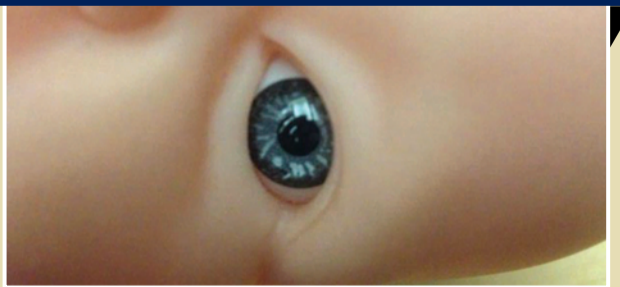## Little progress recorded in historical cleft lip and palate treatment

### DT International Report

**N**EW YORK, N.Y., USA: The Cleft Palate-Craniofacial Journal recently presented a historical review of what Western doctors and scientists knew about defects

known as cleft lip and palate. The authors of the review sought to verify that treatment and surgical techniques for these malformations were largely esthetic and unchanged until the 19th century.

When the printing press was invented in



the mid-1400s, it had an unexpected effect on the practice of Western medicine. With the creation of moveable type, works by ancient and medieval doctors could be preserved, and contemporary surgeons were

*Continued to page 11*



Tribune CME



# 1 Year Clinical Masters™ Program in Aesthetic and Restorative Dentistry

November 12-15, 2014, a total of 4 days in Dubai (UAE)

On location sessions, hands-on in each session + online learning and mentoring

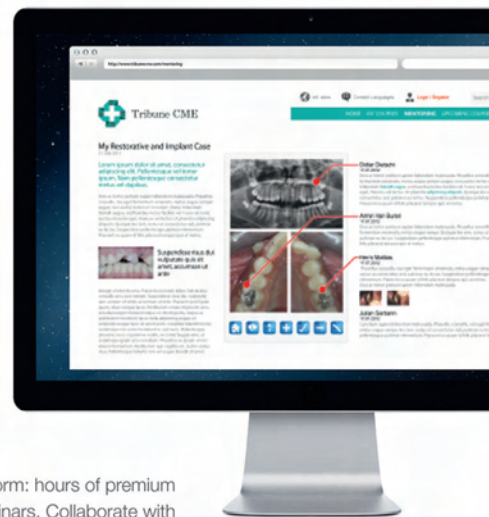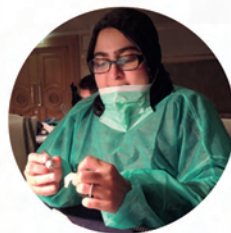Learn from the Masters of Aesthetic and Restorative Dentistry:



Prof. Francesco Mangani



Prof. Angelo Putignano



Access our online learning platform: hours of premium video training and live webinars. Collaborate with peers and faculty on your cases.

## Registration information:

November 12-15, 2014  
a total of 4 days in Dubai (UAE)

Session fee: € 3,450

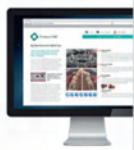(you can decide at any time to complete the entire Clinical Masters Program and take the remaining session)

Details on [www.TribuneCME.com](http://www.TribuneCME.com)

contact us at tel.: +49-341-484-74134  
email: [request@tribunecme.com](mailto:request@tribunecme.com)

Collaborate on your cases

and access hours of premium video training and live webinars



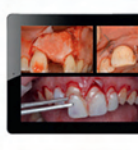University of the Pacific

you will receive a certificate from the University of the Pacific



Latest iPad with courses

all registrants receive an iPad preloaded with premium dental courses



50 C.E. CREDITS



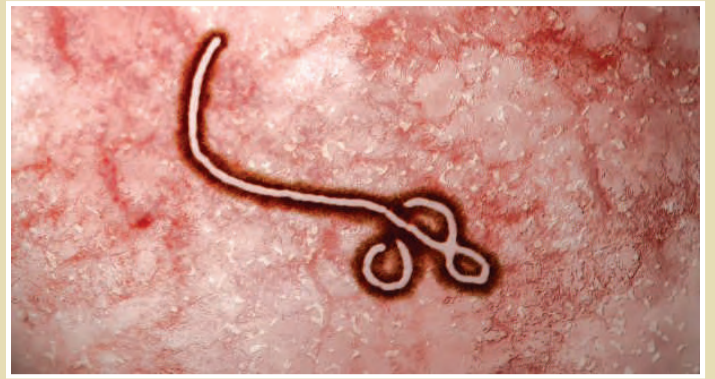ADA CERP®  
Continuing Education Recognition Program

Tribune Group GmbH is the ADA CERP provider. ADA CERP is a service of the American Dental Association to assist dental professionals in identifying quality providers of continuing dental education. ADA CERP does not approve or endorse individual courses or instructors, nor does it imply acceptance of credit hours by boards of dentistry.



Tribune Group GmbH is designated as an Approved PACE Program Provider by the Academy of General Dentistry. The formal continuing dental education programs of this program provider are accepted by AGD for Fellowship, Mastership, and membership maintenance credit. Approval does not imply acceptance by a state or provincial board of dentistry or AGD endorsement.

# Health authorities offer Ebola guidance for dentists



## DT International Report

**A**TLANTA & CHICAGO, USA: In close collaboration with the Centers for Disease Control and Prevention (CDC) and the Organization for Safety, Asepsis and Prevention, the American Dental Association (ADA) has released information for dental professionals on Ebola virus disease, which is epidemic in West Africa. Among other recommendations, it provides advice on the treatment of patients recently returned from the region.

CDC and its partners are currently working to help prevent Ebola and other infectious diseases from being introduced into and spread in the U.S. As of Oct. 17, the ADA advises dental professionals of the following:

A person infected with Ebola is not considered contagious until symptoms appear. Owing to the virulent nature of the disease, it is highly unlikely that someone with Ebola symptoms will seek dental care when he or she is severely ill. However, according to CDC and the ADA Division of Science, dental professionals are advised to take a medical history, including a travel history, from their patients with symptoms in whom a viral

infection is suspected.

As recommended by the ADA Division of Science, any person within 21 days of returning from the West African countries Liberia, Sierra Leone and Guinea may be at risk of having contacted persons infected with Ebola and may not exhibit symptoms. If this is the case, dental professionals are advised to delay routine dental care of the patient until 21 days have elapsed from their trip. Palliative care for serious oral health conditions, dental infections and dental pain can be provided if necessary after consulting with the patient's physician and conforming to standard precautions and physical barriers.

In general, providers of dental health care services should continue to follow standard infection control procedures in the clinical setting as described in CDC's 2003 Guidelines for Infection Control in Dental Health-Care Settings, the organization stated.

Signs and symptoms of Ebola include fever greater than 38.6 C or 101.5 F and severe headache, muscle pain, vomiting, diarrhea, stomach pain, or unexplained bleeding or bruising.

CDC emphasized, "The virus is spread through direct contact with blood and body fluids of an infected person, or with objects, like needles, that have been contaminated with the virus. Ebola is not spread through the air or by water or, in general, by food."

The 2014 Ebola epidemic is the largest in history, affecting multiple countries in West Africa, including Guinea, Liberia, Nigeria and Sierra Leone. Its outbreak was first officially recognized in March this year. According to estimates by the World Health Organization (WHO), about 9,000 people have been infected with the disease and about 4,500 have died.

The first Ebola case to be diagnosed in the U.S. in a person who had travelled to Dallas from West Africa was confirmed on Sept. 30.

On Oct. 17, WHO officially declared the Ebola outbreak in Senegal over and commended the country on its diligence in ending the transmission of the virus. Three days later, WHO officially declared that Nigeria is now free of Ebola virus transmission.

## Karachi first ever Style Italiano Restorative Workshop

*Continued from front page*

Operative Department at DOW Dental.

In his very enlightening presentation Dr Arshad Hasan shared comprehensive details about hue, chroma and value of restorations, the importance of maintaining a graduated difference between dentin and enamel shades to ensure excellent aesthetics, an introduction to the Style Italiano technique, and how to make it successful in clinical practice. The presentation also included patient cases with tooth re-creations done using the layering technique.

This was followed by Dr Urooj Mumtaz Khan's highly interactive lecture, who is currently the Consultant Aesthetics Specialist at Khan's Dental Institute. The Sheffield graduate used outstanding everyday examples to explain the Style Italiano technique and how students can achieve excellent results using simple guidelines. 'It isn't always possible to purchase the Style Italiano kit, which is rather expensive,' she said 'but in my clinical practice, I find that I can achieve almost the same results with my regular instruments like probes and plastic instruments. I also used the common plumbing tape; it offers excellent isolation for a fraction of the cost'. Dr Urooj's presentation too included her own patient cases with excellent before and after restoration photographs.

Dr Salman Ashraf, Head of the Operative Department at University of Lahore and visiting consultant at Shaukat Khanum Memorial Hospital, Lahore for the dental rehabilitation of cancer patients was the last speaker. His presentation not only highlighted the salient features and techniques of Style Italiano, but also included pictures of patients from Shaukat Khanum before and after

their dental restorations. Dr Salman also presented an additional lecture on the measures that must be taken in medical and dental operatories for patients suffering from osteo-radio necrosis.

Dr Saqib Rasheed also addressed the gathering, appreciating the commendable efforts put in by the organizers for the event. He also invited the participants for the PDA symposium which is to be held on the 30th of November, and encouraged the participants to attend future events and seminars.

Dr Mumtaz Khan expressed his gratitude and shared his words of wisdom with the young minds. The three then presented shields to the guests, Dr Arshad Hasan, Dr Salman Ashraf and Dr Urooj Mumtaz. Sumptuous lunch was served at the Tai-Pan restaurant at PC before the hands on workshop.

During the workshop, the participants were divided into two groups that were supervised by Dr Arshad Hasan and Dr Salman Ashraf. Both the mentors diligently taught the youngsters how to master the Style Italiano technique. All material for the workshop was supplied by 3M Pakistan. Dr Urooj Mumtaz guided the participants as they proceeded with their work.

3M Pakistan, AusPak International and DIO Implants were the key sponsors of the event, and IADSR offered its support in the form of 5 international credit hours to all participants of the workshop.

Towards the end of the event, the attendees received certificates of participation. All attendees were encouraged to share their views, experiences and pictures online.

The prominent amongst those who attended the event were Prof Saqib Rashid President Pakistan Dental Association, Dr Mumtaz Khan, Dr Azmat Mumtaz and Brigadier Shoaib representing AIDM.



The next workshop would soon be announced on orthodontics with aim to equip the participants with new techniques and expertise.

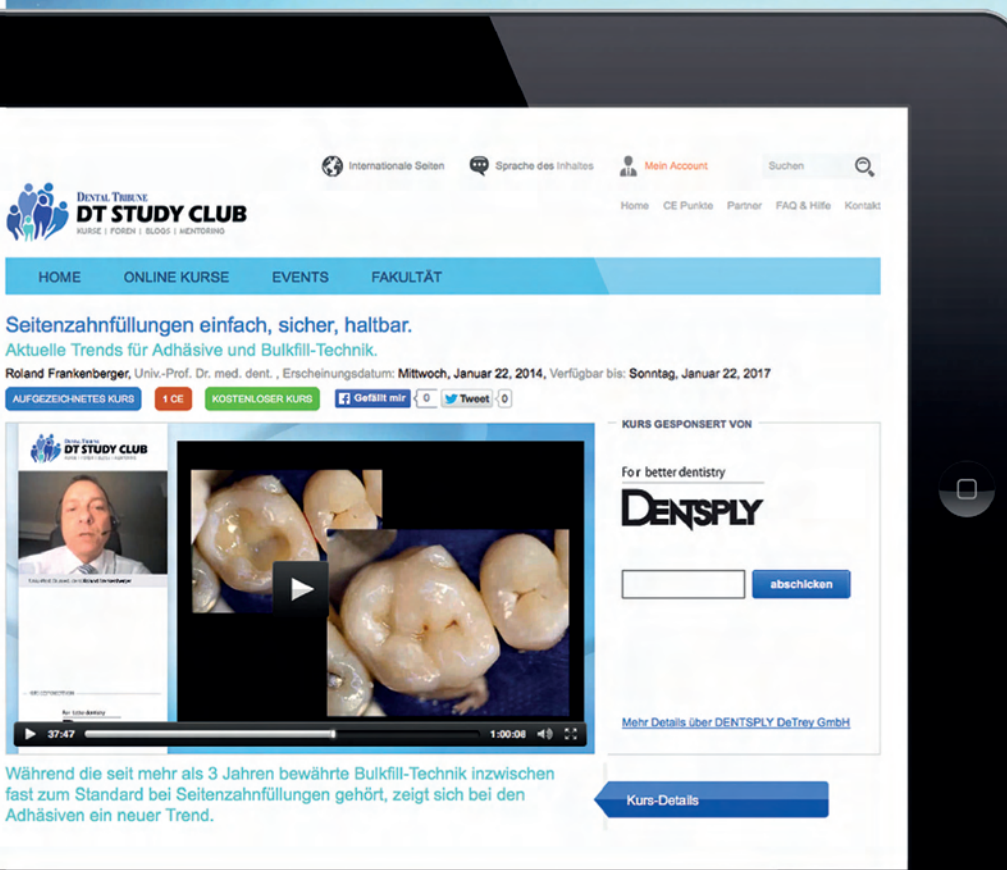


# Join the largest educational network in dentistry!



[www.DTStudyClub.com](http://www.DTStudyClub.com)

- education everywhere and anytime
- live and interactive webinars
- more than 500 archived courses
- a focused discussion forum
- free membership
- no travel costs
- no time away from the practice
- interaction with colleagues and experts across the globe
- a growing database of scientific articles and case reports
- ADA CERP-recognized credit administration



Register for  
**FREE!**

**ADA CERP**® | Continuing Education Recognition Program

ADA CERP is a service of the American Dental Association to assist dental professionals in identifying quality providers of continuing dental education. ADA CERP does not approve or endorse individual courses or instructors, nor does it imply acceptance of credit hours by boards of dentistry.

