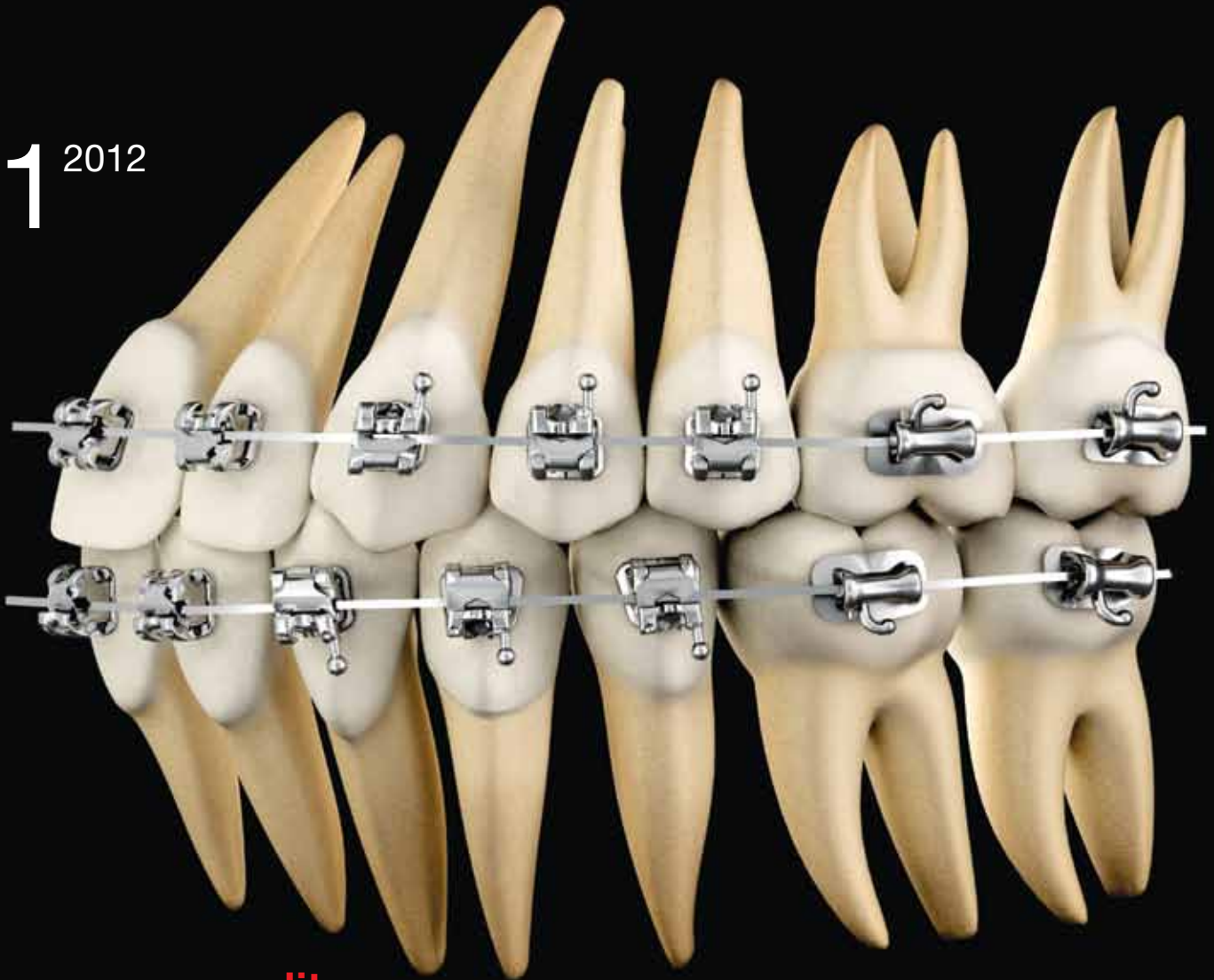

# ortho

the international C.E. magazine of orthodontics

1 2012



## **earn c.e. credit**

Clinical and diagnostic advantages of 3-D imaging systems in dental specialties

## **practice matters**

The business of private practice orthodontics in the United States

## **techniques**

Lingual you will love: Capturing the incremental patient with lingual orthodontics

# Welcome to *ortho*



**Torsten Oemus**  
Publisher  
Dental Tribune International

The goal of this quarterly magazine is twofold. First, it seeks to share practical orthodontic knowledge that can be put to use in your day-to-day practice. Second, it is a vehicle to help you chip away at your continuing education (C.E.) requirements.

The amount of new information available in the orthodontic field about new products, techniques and research data is astounding. Running a practice and seeing patients leaves little time for catching up on the latest clinical news and product information. Thus, we hope *ortho* will not only be a welcome respite for those rare chunks of time you can devote to leisurely reading, but one that provides a practical return on your investment by providing information that you can actually put to immediate use.

In addition, we know that taking time away from the practice to pursue C.E. credits is costly in terms of lost revenue and time. As a quarterly magazine, *ortho* is here to help you chisel at least four C.E. credits per year out of your already busy life without the lost revenue and time away from your practice. To that end, every edition of *ortho* will include at least one hour of ADA CERP-certified C.E. credit where readers can answer questions about the materials at [www.dtstudyclub.com](http://www.dtstudyclub.com) to earn this credit. Annual subscribers to the magazine (\$50) need only register at the Dental Tribune Study Club website to access these C.E. quizzes free of charge. In fact, even non-subscribers may take the C.E. quiz after registering on the DT Study Club website and paying a nominal fee.

If you are a practitioner with a penchant for words, it might also interest you to know that authors of the C.E.-accredited articles receive 15 percent of the fees collected from the non-subscribers who take the C.E. quiz online. The C.E. quiz for the articles in this edition will be available online on May 1.

Dental Tribune America is part of the largest dental publishing network in the world, Dental Tribune International (DTI), which consists of 23 license partners around the globe. The DTI network publishes a variety of dental publications that are distributed in more than 90 countries. Please visit us online at [www.dental-tribune.com](http://www.dental-tribune.com) to see the variety of publications we offer and at [www.dtstudyclub.com](http://www.dtstudyclub.com) to see the complete list of online and offline C.E. opportunities available. In the meantime, we hope you enjoy the first edition and welcome your feedback.

Sincerely,

Torsten Oemus  
Publisher

# Discover Your Practice for the First Time

Achieve Greater Efficiency,  
Profitability AND Satisfaction  
From Your Practice

## JUST SHORT OF PERFECT ORTHODONTICS



### THE JSOP COURSE

**J.S.O.P.®** – Just Short Of Perfect represents a system of orthodontic practice management and metrics developed by Dr. Ron Roncone. This system is practice-wide including clinical treatment, business management, marketing and sales, and is based on 40 years of practice, lecture and consulting experience. This 1/year personalized program consisting of (4), four-day group sessions is held at Dr. Roncone's meeting facility in Vista, CA providing the opportunity to implement new systems into your practice efficiently.

### JSOP COURSE FEE

**JSOP 16-Day Course Fee: \$20,000**

Register for JSOP XV and receive a reduced fee of \$10,000

### REGISTRATION INFORMATION

[http://www.ronconerol.com/registration/contact\\_us.html](http://www.ronconerol.com/registration/contact_us.html)

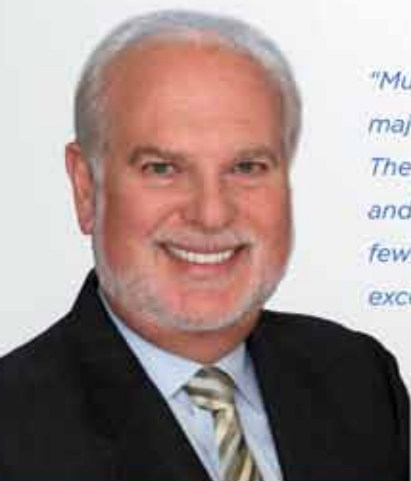### ADDITIONAL INFORMATION

#### Roncone Orthodontics International

221 Main Street, Suite 100 • Vista, California 92084

Ph: 800.758.5836 • Int'l Ph: 760.630.5914 • Fax: 760.758.7604

Visit: [www.ronconerol.com](http://www.ronconerol.com)



*"Much more is possible than the majority of orthodontists believe. The trick is achieving enjoyment and financial return while working fewer hours without compromising excellent treatment."*

- Dr. Ron Roncone

### JSOP SCHEDULE

#### JSOP XVII

7/19-7/22, 2012 Session 2: Clinical Systems I

11/15-11/18, 2012 Session 3: Clinical Systems II

2/21-2/24, 2013 Session 4: Orthodontic Practice  
Marketing, Enrollment & Communication

#### JSOP XVIII

9/6-9/9, 2012 Session 1: The Business of  
Orthodontics

### COURSE SUMMARY

#### SESSION 1: The Business of Orthodontics

- National Orthodontic Practice Statistics
- Integrated Systems Approach
- 17 Critical Factors
- Benchmarking
- Prioritizing System Corrections (Improvements)
- Strategic Planning
- Practice Monitors/Roncone Module

#### SESSION 2: Clinical Systems I

- Clinical Philosophy
- Brackets
- Wires
- Auxiliaries
- Bracket Placement
- Archform
- Stages of Treatment
- Finishing
- Orthodontic Results

#### SESSION 3: Clinical Systems II

- Diagnosis and Treatment Planning
- Phase I Treatment
- Treatment of the Adolescent and Adult Dentition
- Diseases of and Treatment of T.M.J.
- Hands-On

#### SESSION 4: Marketing, Enrollment & Communication

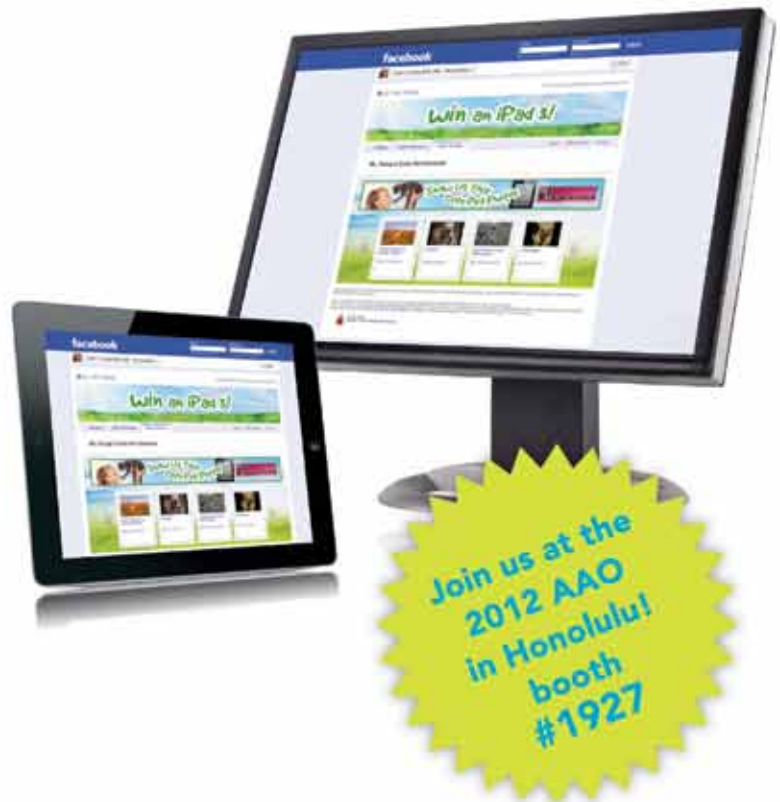- Marketing Basics
- Who and Where is the Market You Want?
- Positioning
- Marketing Director, The Plan, Teams, Internal & External
- Enrolling New Patients



# Unlock a wave of referrals and patient engagement from your social networks

Grow your social media base, engage your patients, and acquire new patients while tripling your Facebook Likes in as little as four weeks with Sesame Sweepstakes™.

- ✓ Choice of sweepstakes or contest promotions
  - Up to four promotions per year
- ✓ Duration of 4 – 8 weeks depending upon practice preference and type of promotion
- ✓ Full-service management of all aspects of the promotion including:
  - Design, administration and management of the contest or sweepstakes
  - Promotional emails, newsletters and outreach to the patient base\*
  - Google Places plugin on Facebook Timeline®
  - Facebook Recommendations plugin on Facebook Timeline
  - In-office promotional materials and QR codes
  - Legal compliance and adherence to Facebook promotion rules
  - Detailed reporting on all entrants
  - Daily reporting of call requests from entrants



Sesame Sweepstakes helps to grow your social media presence through word of mouth referrals and engage your patients to keep your practice top of mind. Better engagement translates into improved patient treatment compliance, and a strong social media presence extends your reach to your patients' social media circles.

*"We looked for a company to provide us with a strategic solution for maintaining our practice prominence in this new digital age, and Sesame proved to be the right partner for our practice."*

– Dr. Andrew Orchin

Sesame Sweepstakes requires Sesame Social™

\*Sesame Patient Login™ optional



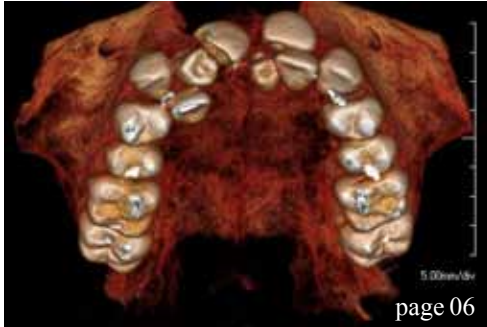Get started now!

866 • 530 • 7295

[solutions@sesamecommunications.com](mailto:solutions@sesamecommunications.com)  
[www.sesame24-7.com](http://www.sesame24-7.com)

Over 6 million people use Sesame to communicate with their dental providers.





## | c.e. article

- 06 Clinical and diagnostic advantages of **3-D imaging systems** in dental specialties  
\_Dan McEown, DDS

## | about the publisher

- 50 \_submissions  
55 \_imprint

## | practice matters

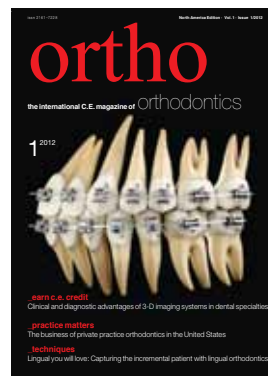- 11 The business of **private practice orthodontics** in the United States  
\_Chris Bentson, President, Bentson, Clarke & Copple
- 17 52 weeks of **social media posts** in less than five minutes  
\_Rachel Mele, Director of Business Development, Sesame Communications

## | technique

- 24 **Lingual** you will love: Capturing the incremental patient with invisible orthodontics  
\_Ronald Roncone, DDS, MS
- 30 SENTALLOY: The story of **superelasticity**  
\_Albert Teramoto, DDS

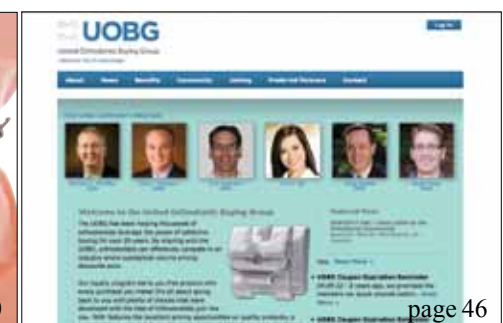
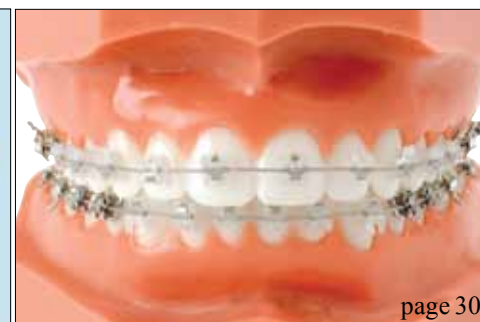## | UOBG

- 46 What is **UOBG** and why should **you** be a part of it?  
\_Lindsay Peach, UOBG Program Director
- 48 Sesame Communications appointed to **UOBG Preferred Partner Program**  
\_Gib Snow, DDS



## | on the cover

Cover image provided by DENTSPLY GAC



# Clinical and diagnostic advantages of 3-D imaging systems in dental specialties

Author\_Dan McEowen, DDS

## \_c.e. credit article

This article qualifies for C.E. credit. To take the C.E. quiz, please log on to [www.dtstudyclub.com](http://www.dtstudyclub.com). The quiz will be available on May 1.

**Fig. 1\_Saggital CBCT MPR showing bone defect at point of dehiscence of the implant coating.**  
(Photos/Provided by Dr. McEowen)

**Fig. 2\_Periapical does not show the sinus anatomy or the width of the bone.**

**Fig. 3\_MPR showing post-op of sinus graft and implant placement.**

\_For nearly 100 years, dentists have relied on 2-D radiographic imaging for diagnosis and treatment planning. With the 1999 introduction of cone-beam computed tomography (CBCT), all dentists now have tools available for more accurate diagnosis and treatment.<sup>1</sup> The ability to look at a tooth in any direction and orientation, as well as in 3-D, eliminates much of the guesswork commonly experienced with 2-D radiographs.

We have been limited in most cases to only a buccal-lingual view provided by periapicals, bite-wings and panoramic radiographs with the occasional axial view of an occlusal film. Medical CT scans and images began in the early 1970s and were sometimes used by dentists, offering our first multiplaner views.<sup>2</sup>

The adoption of 3-D cone-beam imaging is appropriate and has important advantages for all modalities of dentistry. From every specialist to the general dentist, the increased amount of radiographic information as well as increased accuracy will aid in the most sound diagnosis possible.

## \_CBCT description

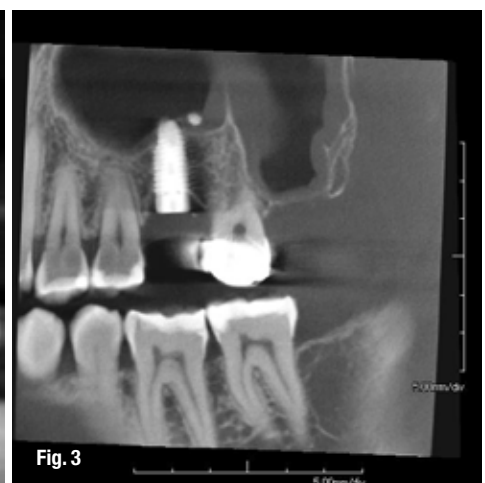
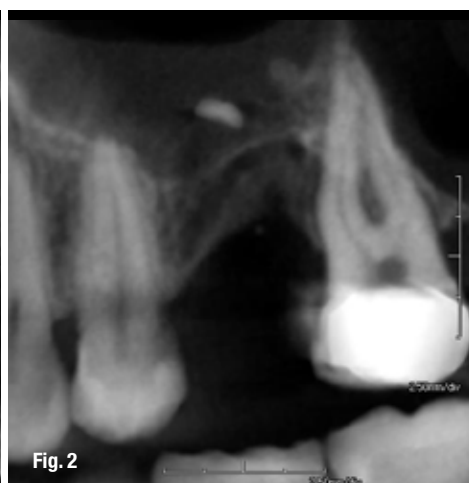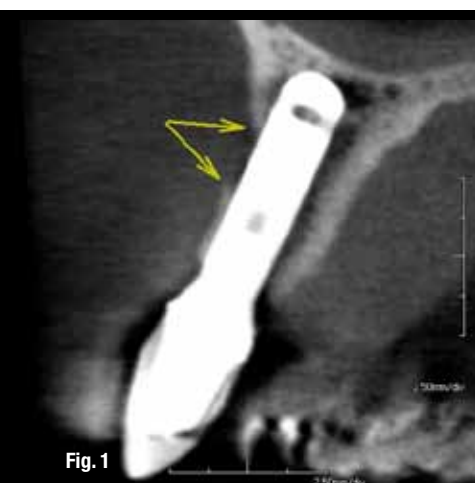CBCT is a single or partial rotation of an X-ray source around the head, capturing X-rays on various flat panel arrays and sensors. The information is converted to a series of axial slices by computed tomography and stored as virtual anatomy in the computer.

With the use of sophisticated software, the dentist is able to view information in several different views, including: axial slices (head-to-toe orientation), coronal slices (front-to-back orientation), saggital slices (side-to-side orientation) all known as multiplaner reconstructions (MPR). The thickness of each slice can be varied to include more or less information.

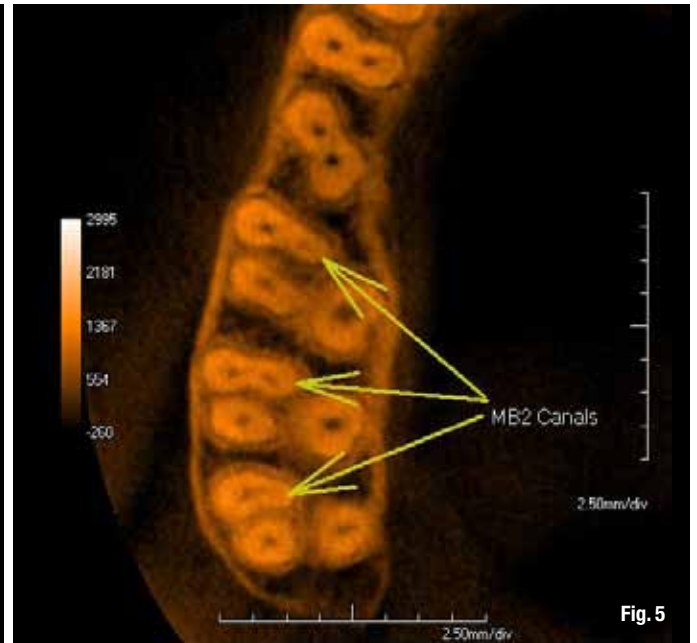
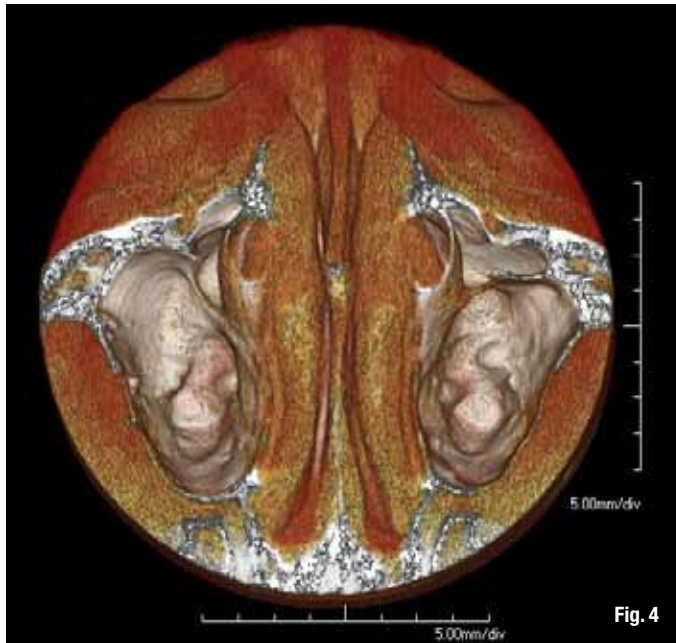
Because the voxels (volumetric pixels 3-D) are isotropic, other MPR images can be generated by slices drawn at any angle, curve or thickness through the scan to view areas critical to the final diagnosis.<sup>3,8</sup>

The final view offered by CBCT is a 3-D view that can be rotated and viewed in any direction.

Once again through software manipulation, 3-D







images can be viewed as conventional radiographs, maximum intensity projections (MIP), soft-tissue projections and a variety other views.

This nearly endless ability to manipulate the data aids in the diagnosis and identification of disease, nerve canals, sinus morphology, dental caries, bone density, fractures, endodontic pathology, implant placement criteria, periodontal defects, bone pathology, fractured teeth, iatrogenic trauma, TMJ morphology and disease, third-molar position and many more healthy or diseased conditions.

### Early CBCT adoption with implants

The first and primary use of CBCT for early adopters was implant placement. As the scope and the value of the information became better known, dentists of all branches began to see the value of MPRs and 3-D renderings including periodontics, endodontics, oral surgery, treatment of TMJ, orthodontics, implantology and general dentistry.<sup>1,7,8</sup>

Clinical periapical and panoramic radiographs for the placement of implants can be misleading with elongation, foreshortening, superimposition and geometrically incorrect data.<sup>7,8</sup> A look at the implant in the periapical shows no obvious disease to an existing integrated implant. Clinically, a buccal fistula was present with exudate and slight pain. The CBCT scan (Fig. 1) reveals a more accurate view showing a buccal defect on a sagittal MPR. A surgical flap revealed a dehiscence of the coating of the implant. Removal of the foreign body resulted in an asymptomatic and healthy patient.

The evaluation of the available bone for the initial

implant placement can be crucial for the long-term success of the case. If there is inadequate bone available, grafting may be a necessity. CBCT studies render the most accurate information available at a low radiation dose. The periapical shows an obvious lack of bone height, but does not show the buccal-lingual dimensions or an accurate view of the sinus morphology (Fig. 2).

The MPR view of the CBCT shows all necessary measurements to perform the sinus lift and grafting with the immediate placement of the implant fixture (Fig. 3). Three-dimensional views show the floor of the sinus and any soft-tissue pathology (Fig. 4). Having accurate measurements in all dimensions is an advantage of CBCT scanning.

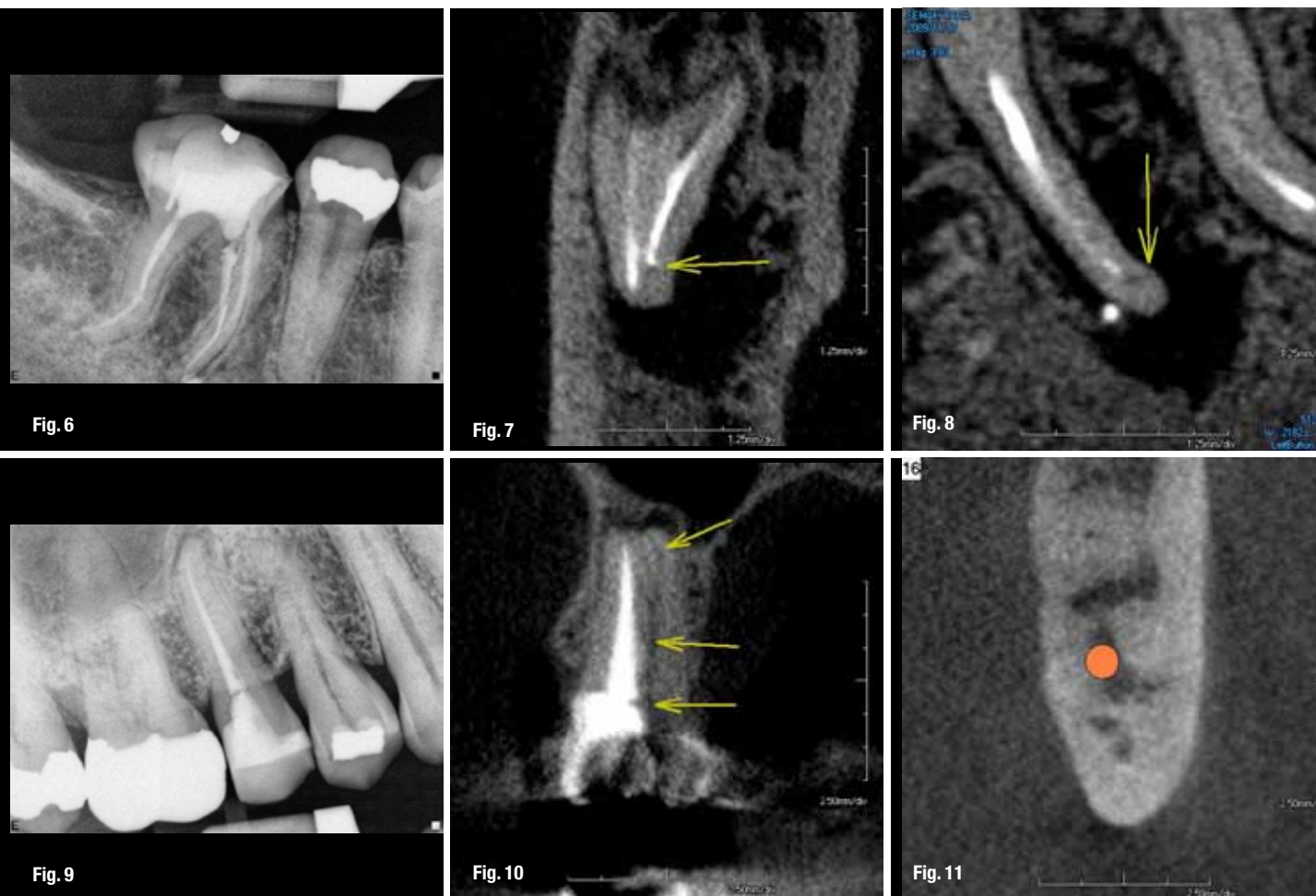
### CBCT and endodontics

Endodontics is a field that is rapidly adopting the use of CBCT and for good reason. The inherent geometric deficiencies of 2-D radiographs make the CBCT scan a valuable adjunct to investigate the root morphology in both 3-D and MPR. The typical periapical will show superimposed canals in the anteriors, bicusps and molars as well as unwanted bone densities both buccal and lingual to the affected tooth, making the image quality poor.

The ability to view MPR slices in cross-section, long axis and oblique directions gives the ability to follow all canals in any direction and show their relationship and measurements from other known structures. This virtual tour of the root morphology is a great benefit to the final treatment outcome (Fig. 5).<sup>3,4</sup>

**Fig. 4\_**The 3-D CBCT showing anatomy of the maxillary sinuses.

**Fig. 5\_**Axial MPR showing mesial buccal roots in first, second and third molars.



**Fig. 6**\_Periapical showing minimal pathology with no radiolucency.

**Fig. 7**\_Coronal MPR showing a short fill on the mesial lingual and radiolucency.

**Fig. 8**\_Sagittal MPR showing unfilled canal and radiolucency.

**Fig. 9**\_Periapical showing a normal fill with a radiolucency.

**Fig. 10**\_Coronal MPR showing the superimposed lingual root unfilled.

**Fig. 11**\_Coronal MPR showing nerve between roots of the third molar.

Post root-canal infection can be difficult to diagnose with the standard periapical. The endodontic fills may appear to be normal even though other clinical findings and symptoms are abnormal. The patient presents several months post root-canal treatment with pain on palpation and pressure and avoids this side of the mouth.

A periapical radiograph shows minimal pathology (Fig. 6). The roots appear to be filled and a small puff of sealer extends through the apex of the mesial roots. The distal root structure and fill appear normal. There is little indication of periapical radiolucency only a widening of the periodontal ligaments of the mesial roots.

A CBCT scan reveals a completely different picture. The coronal MPR reveals a short fill near the apex of the mesial lingual root and a large radiolucency (Figs. 7, 8) not visible on the periapical radiograph (Fig. 6).

Missed canals are difficult to see in a buccal-lingual projection of the periapical radiograph as one canal is superimposed on the other (Fig. 9). Often, as viewed in this radiograph, we see periapical pathology with an apparent normally filled canal. CBCT scans allow dentists to look for pathology in MPR planes to identify the actual problem before invasive

procedures are performed on the patient. The axial view shows a lingual canal exists and is untreated. The coronal view confirms the diagnosis and treatment can be completed (Fig. 10).

Today's endodontists, as well as general dentists, are benefiting from the diagnostic capabilities of the high-resolution CBCT scanners available over conventional 2-D periapical.<sup>5,6</sup>

### Oral surgery

Oral surgery, with its inherent invasive nature, can be better served using CBCT with MPR as well as 3-D images. The ability to perform virtual surgery is a benefit to both the doctor and the patient. Doctors have the advantage of seeing morphology and landmarks in real time and space with accurate measurements, and patients will gain a better understanding of the problems and the solutions their doctors are offering them.

Third-molar extractions can be risky based on 2-D and panoramic radiographs. These radiographs can often superimpose nerves and sinuses over root structures. Dentists using 2-D radiographs must often rely on experience to assess the risks of iatrogenic



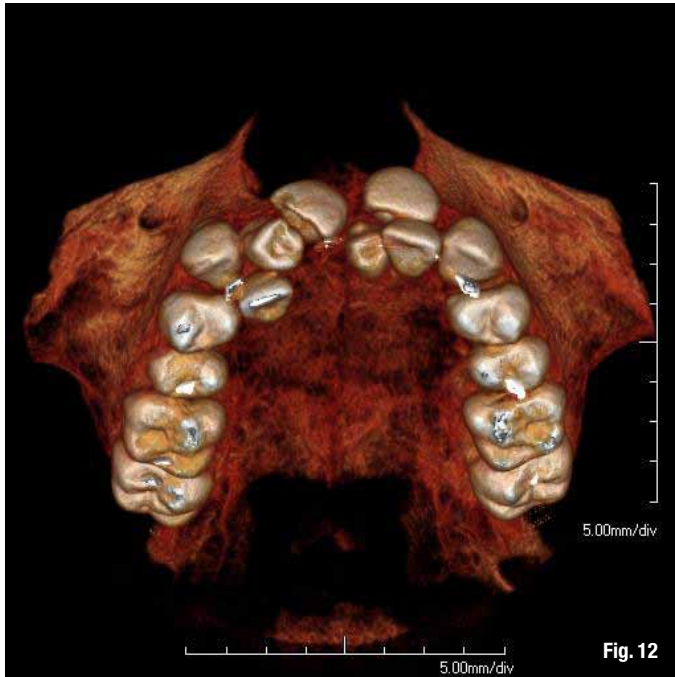


Fig. 12

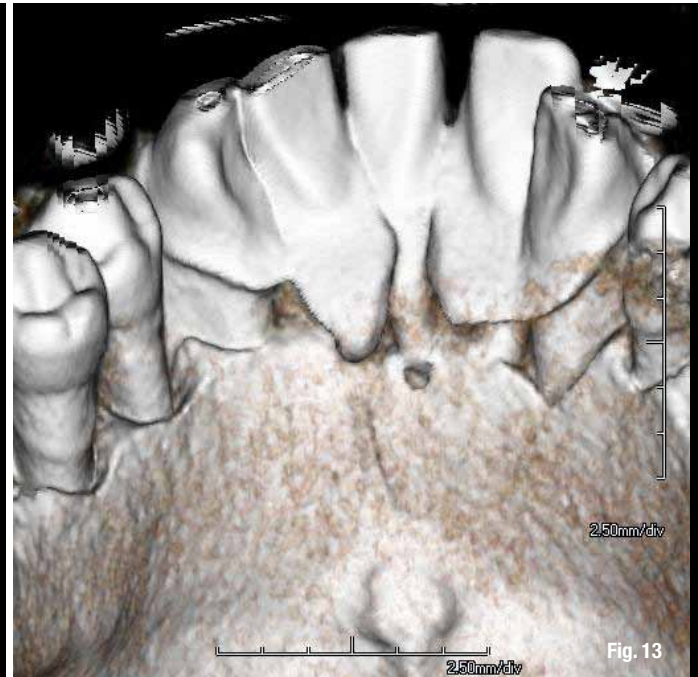


Fig. 13

trauma. The use of CBCT with MPRs and 3-D images reduces any guessing as well as the chance for any permanent damage to the patient. With the adoption of CBCT, the judgment is based on solid evidence and the risk will decrease.

A panorex of the superimposed third molars gave no solid evidence the canal lies between the roots. It is only with the use of CBCT and the MPRs that the nerve can accurately be seen traversing between the mesial buccal and mesial lingual root (Fig. 11).<sup>4,5</sup>

Other surgical advantages include the identification and the position of supernumerary or impacted teeth. The images show accurate positions and show definitive morphology that will aid in removal of the proper teeth (Fig. 12). Knowing the exact position of many of these teeth is a benefit to both the doctor and patient. It will lead to the most precise surgical path and the least invasive procedure.

### Periodontics

The explanation of periodontal problems are often misunderstood by the patient. As doctors, we talk about pockets, point to X-rays and propose treatment only to have patients refuse treatment because they do not understand what we are clinically describing. Using the 3-D portion of the CBCT scan can improve the understanding and acceptance of treatment plans.

The images are a picture of the problem that is owned by that patient and much easier to understand by the layperson. Illustrating periodontal defects and pockets allows the patient to better participate in the process (Fig. 13).

The MPRs and the 3-D projections aid in surgical planning for periodontists, allowing for accurate measurements and bone analysis prior to osseous surgery that doctors cannot get using the periapicals or panoramics.

Studies have shown that CBCT images are more accurate than panoramic radiographs. For the periodontist placing implants, the ability to measure bone density and avoid important anatomy is important.<sup>4,5</sup>

### Orthodontics

Orthodontists are beginning to adopt large field-of-view CBCT. Recent studies show that linear measurements of bony structures are more accurate using CBCT and have less distortion than current methods of measurement: lateral cephalometric, posteroanterior (PA) and submentovertex (SMVT).<sup>5</sup> Accurate measurements of tooth volume and tooth position can aid in accelerated treatment times and more precise treatment.

Along with tooth position, density of bone and size of arches, the orthodontist also has an accurate evaluation of the temporomandibular joint and position of the condyles. Impacted teeth are easily identified and position, either buccal or lingual can be confirmed prior to movement or removal.

Both MPRs and 3-D projections give the clinician a complete picture of the problems and the treatment course.

With a single CBCT scan, orthodontists can produce all of the information they need: panoramic, cephalometric, PA, SMVT, tooth size and volume, crowding evaluation in any plane, TMJ evaluation

**Fig. 12\_** The 3-D rendering showing supernumerary teeth and positions.

**Fig. 13\_** The 3-D rendering with periodontal defects and calculus bridge.