

roots

the international C.E. magazine of endodontics

3²⁰¹³

_C.E. article

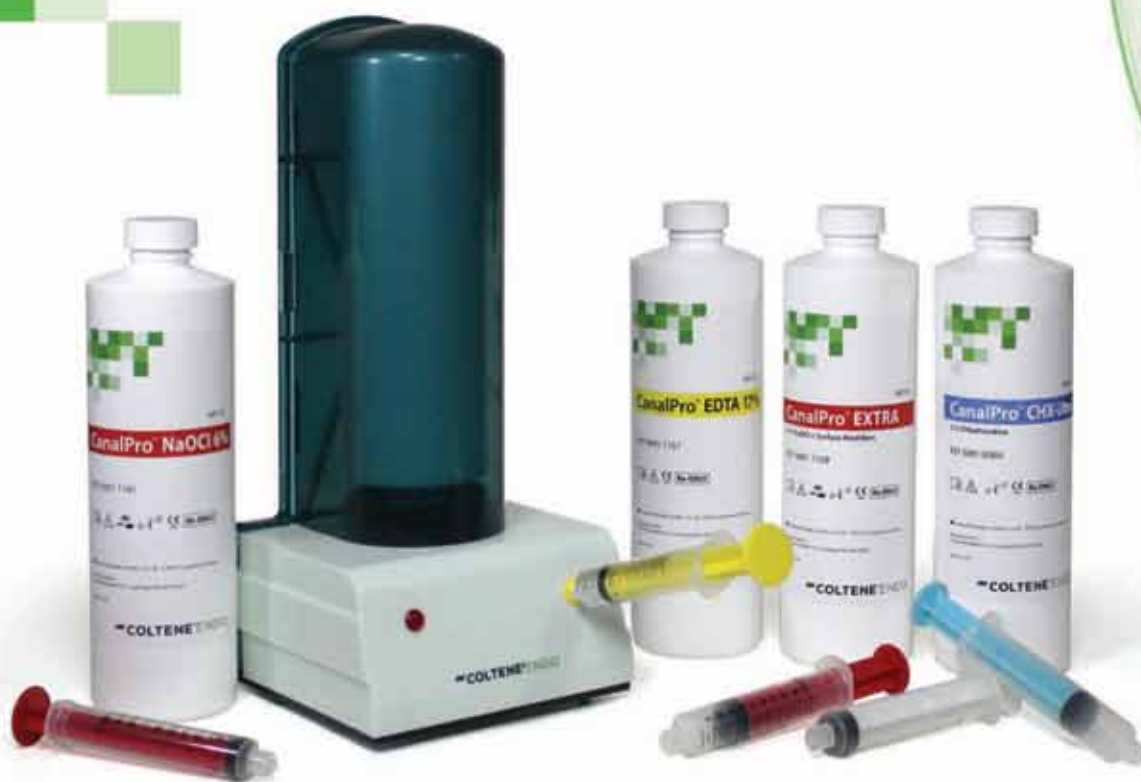Diagnosis 2013: The things you need to know for successful endodontic treatment

_technique

Bioactive endodontic obturation: Combining the new with the tried and true

_trends

PHAST PIPS: The photoacoustic wave of the future?



CanalPro™

Endodontic Irrigation System

More efficacious solutions

CanalPro NaOCl EXTRA

- 2x wetter: Proprietary surface modifiers enable penetration into hard-to-reach areas
- 2x more digestive than regular Sodium Hypochlorite cuts tissue dissolution time in half

Innovative delivery

Color-coded for safety and convenience

Visit **ColteneEndo.com** to get a **FREE** Sample.

While supplies last.



235 Ascot Parkway | Cuyahoga Falls, OH 44223
Tel, USA & Canada 800.221.3046 | 330.916.8800 | coltene.com

COLTENE® ENDO

ParaPost®

Alpen
ROTARY INSTRUMENTS

GuttaFlow® 2

ENDO
I • C • E

HyFlex® CM
controlled memory niti files

HYGENIC

Honoring those who **save teeth**



Fred Weinstein, DMD, MRCD(C),
FICD, FACD

There is perhaps nothing more satisfying than the ability to save a patient's tooth. I know this from decades of clinical experience. Probably most endodontists would agree with me on this — especially those who have devoted their careers to practicing and teaching.

I'm talking about people like my longtime friend Dr. Samuel O. Dorn, pictured with me at this year's AAE Annual Session in Honolulu. Dorn received the Edgar D. Coolidge Award, the AAE's highest honor. He was one of many endodontists who received awards at the meeting.

You can read my interview with Dorn by turning to page 24.

Also in this issue of **roots**, you will want to check out the article on bioactive obturation using MTA Fillapex and the Continuous Wave of Condensation technique, by Dr. Gary Glassman. There's also a report on photon induced photoacoustic streaming (PIPS) by Dr. Reid Pullen.

But that's not all. Every issue of **roots** also contains a C.E. component. By reading the article on diagnosis



by Dr. Thomas Jovicich, then taking a short online quiz about this article at www.DTStudyClub.com, you will gain one ADA CERP-certified C.E. credit. Keep in mind that because **roots** is a quarterly magazine, you can actually chisel four C.E. credits per year out of your already busy life without the lost revenue and time away from your practice.

To learn more about how you can take advantage of this C.E. opportunity, visit www.DTStudyClub.com. You need only register at the Dental Tribune Study Club

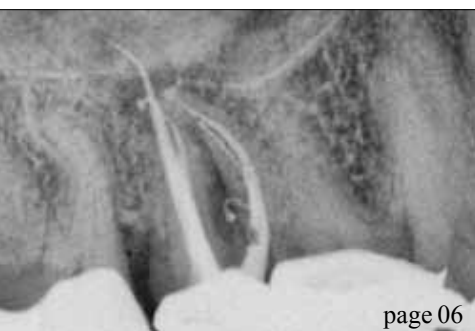website to access these C.E. materials free of charge. You may take the C.E. quiz after registering on the DT Study Club website.

I know that taking time away from your practice to pursue C.E. credits is costly in terms of lost revenue and time, and that is another reason **roots** is such a valuable publication.

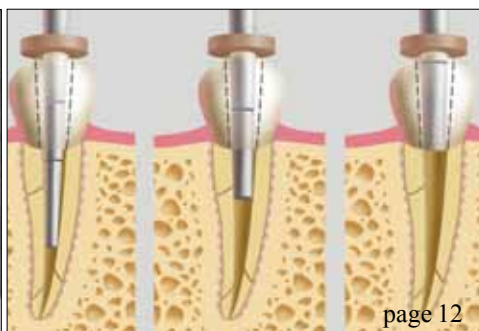
I hope you will enjoy this issue and that you will take advantage of the C.E. opportunity.

Sincerely,

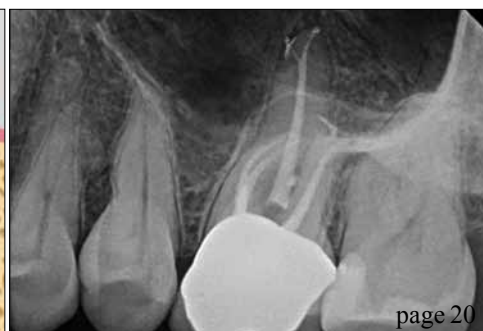Fred Weinstein, DMD, MRCD(C), FICD, FACD
Editor in Chief



page 06



page 12



page 20

| C.E. article

- 06 **Diagnosis 2013:** The things you need to know for successful endodontic treatment
_Thomas Jovicich, MS, DMD

| technique

- 12 **Bioactive endodontic obturation:** Combining the new with the tried and true
_Gary Glassman, DDS, FRCD(C)

| trends

- 20 **PHAST PIPS:** The photoacoustic wave of the future?
_Reid Pullen, DDS, FAGD

| interview

- 24 'The practice of **endodontics is exciting**'
_Fred Weinstein, Editor in Chief

| meetings

- 26 **AAE** holds its annual meeting in Honolulu
_Fred Michmershuizen, Managing Editor

| industry

- 28 Wykle Research expands its **Calasept Endo** line

| about the publisher

- 29 _submissions
30 _imprint



| on the cover

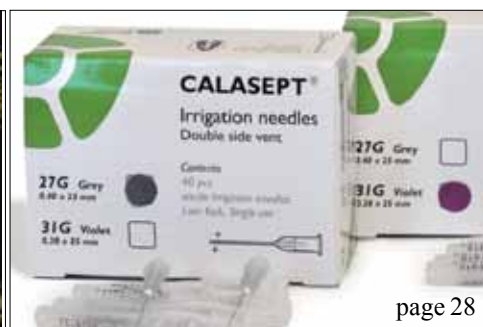Image by Reid Pullen, DDS, FAGD.



page 24



page 26



page 28

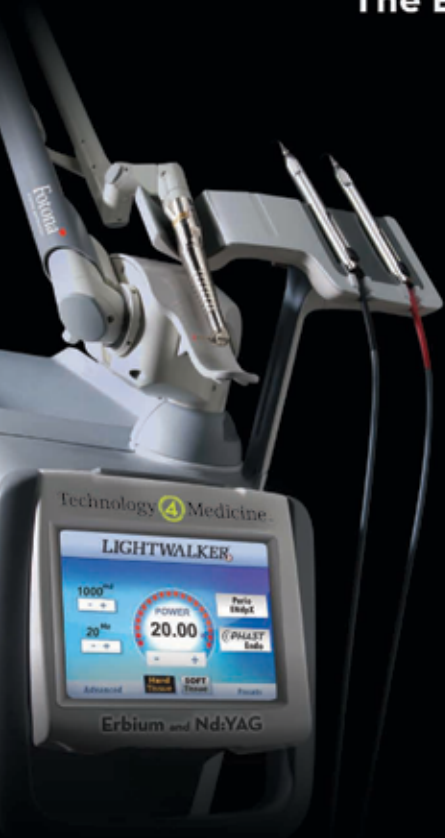Lasers Dentistry™

a division of Technology4Medicine, LLC

LIGHTWALKER AT™

Erbium & Nd:YAG | PHAST™ PIPS™ Laser Endo
Dual Wavelength Perio Protocol

The Endo, Perio, Soft & Hard Tissue Laser



**LIGHTWALKER AT, A CLASS OF ITS OWN,
NOTHING COMPARES:**

20 Watt Er:YAG Hard & Soft Tissue = Faster Cutting

15 Watt Nd:YAG = Proven Perio Wavelength

QSP & VSP Technology = Faster More Precise & Comfortable Procedures

50µs Er:YAG Pulse Duration = Fewer Shots & Less Anesthesia

OPTOflex Articulated Arm Delivery System = Enhanced Efficiency & Reliability

Xrunner™ Scanner Ready

Options for Snoring, Facial Aesthetics and Dermatological Procedures

Internal Air Compressor, Eliminating External Airlines

Optional Green High Visibility Aiming Beam

**The Lightwalker Will Change Your Practice,
Call Today**



See more at
T4Med.com

AGD - Nashville, 27-29 June, Booth #919

California Dental Association - San Francisco, 15-17 Aug

Ohio Dental Association - Columbus, 19-22 Sep, Booth #730

AAP Perio Meeting - Philadelphia, 28 Sept-Oct-1, Booth #110

ADA - New Orleans, 31 Oct -2 Nov

Greater New York Meeting, 1-4 Dec

Call us at
949-276-6650

Diagnosis 2013:

The things you need to know for successful endodontic treatment

Author_Thomas Jovicich, MS, DMD

c.e. credit

This article qualifies for C.E. credit. To take the C.E. quiz, log on to www.dtstudyclub.com. Click on 'C.E. articles' and search for this edition (Roots C.E. Magazine — 3/2013). If you are not registered with the site, you will be asked to do so before taking the quiz. You may also access the quiz by using the QR code below.



The goal of endodontic treatment is for the clinician to achieve an effective cleaning and debridement of the root canal system, including the smear layer and all of its mechanical and bacterial byproducts. Traditionally this is accomplished via mechanical instrumentation in conjunction with chemical irrigants together and actively engaged to completely debride and sterilize the root canal system.

The root canal system is a vast and complex three-dimensional structure comprising deltas and lateral canals, along with multiple branches off of the main root canal system (Figs. 1, 2, 9).

Before the clinician can begin to treat a patient in need of endodontic treatment, he or she first must come up with the proper diagnosis. Once the diagnosis has been made, it then must be integrated with the treatment plan. Taking that treatment plan and presenting it to the patient creates the next challenge: creating value for the patient. One of my most difficult challenges as a working endodontist is creating value for the patient in my chair who has no pain and is here because his or her dentist "saw

something" on the radiograph. Pain is the greatest patient motivator we have in dentistry today.

The focus of this article is on diagnosis, and it is my goal to provide the reader with a good grasp of diagnosis as it relates to endodontic treatment.

Endodontics is all about vision. You have it. I have it. The dentist down the street has it. Doing root canals today is all about having the confidence to make the proper diagnosis. This is achieved through repetition. The more you do it, the easier it becomes. In addition, you need consistency that is achieved through positive reinforcement. Once you believe you can do it and the results support that, you then develop competence. This allows you to retain the skills you have worked hard to hone. The most important trait to utilize in clinical practice today is common sense. This is what separates the true artisans from tooth mechanics.

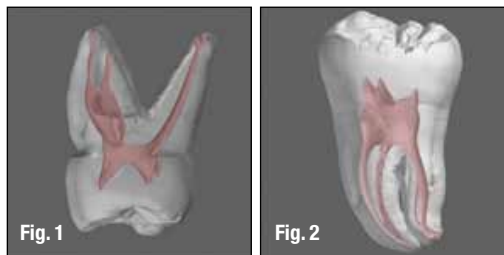
The key component to endodontic treatment is diagnosis. It is based upon using a multifocal approach that involves:

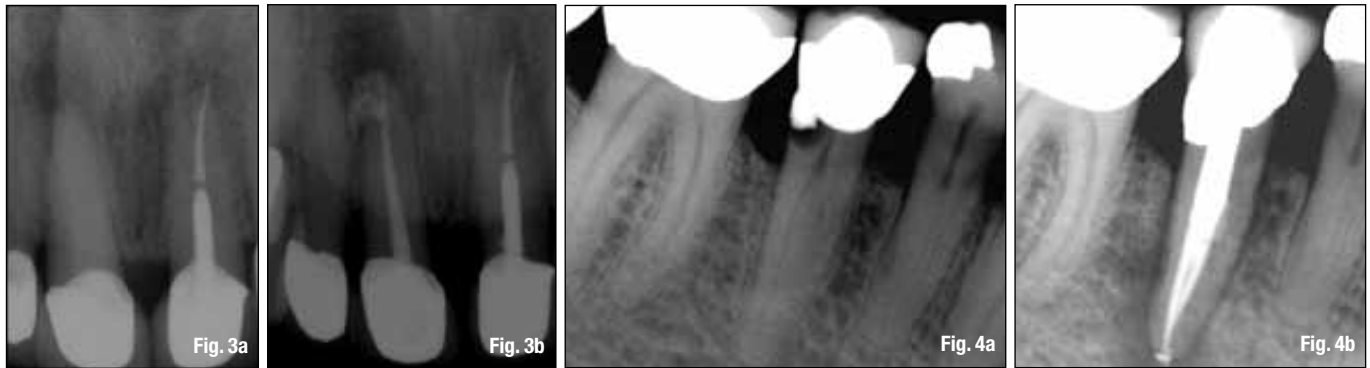- Patient report
- Medical and dental history
- Clinical signs and symptoms
- Diagnostic testing
- Radiographic findings
- Restorability

Taking and collating all of this information will allow the clinician to arrive at a proper and thorough diagnosis. Let's break these down and delve into what needs to be done.

Fig. 1 Maxillary molar. Note the complex anatomy and multiple portals of exit. (Photos/Provided by Thomas Jovicich, MS, DMD)

Fig. 2 Mandibular molar. Note the curvature along with the multiple portals of exit.





—Patient report

This is the first opportunity to create a road map to a diagnosis. The goal is to ascertain the nature of the problem. Step one: Ask the patient where the pain is located. Once you've localized the area, it's imperative to ask a few more questions. The next question should involve determining pulpal vitality through the use of an ice pencil.

Other times the patient will volunteer this information with a statement like: "The minute I put anything cold on this tooth, the pain is present and quite intense." This information suggests that the pain may be pulpal in origin. Because the trigeminal nerve is involved in endodontics, it is important to determine any type of radiating pain. It is not uncommon for maxillary pain to radiate from the mandibular area and vice versa. A final area of feedback I want from patients relates to biting and chewing.

The patient's report is the foundation upon which we begin the diagnostic procedure. Asking probing and leading questions in "plain English" will allow the patient to give you critical diagnostic information.

—Medical and dental history

Once you have the patient's report, probing his or her medical and dental history gives clarity to the background. What are the patient's medical allergies? What recent dental treatment has the patient had? Was there any mention of restorations placed that were near or at the pulp?

Many times a patient will mention having heard the dentist tell his assistant that they were close to the pulp during the excavation of decay. Asking detailed questions enables you to enrich the diagnostic canvas as to why the patient is sitting in your chair.

—Clinical signs and symptoms

By this point, you have listened to the patient's chief complaint and you have taken radiographs or digital images. It's time to "test" the patient. The "bite test" involves having the patient attempt to reproduce the pain through biting on an orangewood stick

or a cotton swab or a wet cotton roll. If there is pain to bite, you are dealing with some degree of pulpal inflammation with secondary involvement of the periodontal ligament. Once you have this information, the next step is to look at your digital imaging and analyze the relationship of the periodontal ligament (pdl) to the root. Is there a thickening? Is there a widening?

If the patient reports pain to bite upon release, this infers that there may be some structural root damage (Figs. 5a, b). At that point it is essential to look at the occlusal surface of the tooth, account for the type and age of any restoration and inquire if any recent dentistry has been done. In addition, it is imperative to probe the suspected tooth.

Probing from buccal to lingual with at least four measurements per side is the best barometer to assess periodontal health. If you find an isolated defect in any single probing, you are most likely dealing with a fracture of the root. Endodontic treatment to confirm or rule out a fracture is indicated in these clinical situations.

—Diagnostic testing

The percussion test involves using the blunt end of a mouth mirror or periodontal probe to assess for periodontal inflammation. It is imperative that the clinician gets a frame of reference. This is accomplished by testing the same tooth on the opposite side of the arch. In addition, it is prudent to test the suspected tooth as well as the teeth on either side. Testing should involve both the occlusal and facial surfaces.

Thermal tests utilizing hot or cold are the definitive modality to assess pulpal vitality. There are a myriad of ways to test with cold, including CO₂ systems, refrigerant sprays and ice cubes (pellets). I believe ice pellets are the best way to test for cold symptoms. In our practice, we use anesthetic carpules that are filled up with water and frozen.

This method is cheap, efficient and plentiful. The goal is to reproduce the patient's symptoms. Many patients who report pulpal hyperemia have managed this symptom by utilizing the opposite

Fig. 3a Maxillary central incisor with a periapical lesion. This is a markedly calcified canal.

Fig. 3b Maxillary central incisor with completed root canal using Sybron TFA rotary nickel titanium instruments, Sealapex sealer. Note the multiple portals of exit in the apical region.

Fig. 4a The presence of caries under the margin of a restoration. The caries extend to the pulp and will need endodontic treatment.

Fig. 4b The endodontic treatment is completed. In this case, the patient was lost to the practice for three years and came back when his face was swollen because of incomplete treatment.

Fig. 5a Cracked tooth syndrome.
Pre-treatment radiograph.

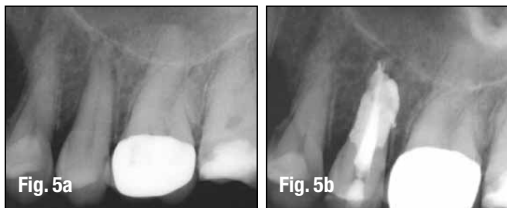

Fig. 5b What can happen in a cracked tooth when you obturate with warm, vertical condensation of gutta-percha.

Fig. 6 Well-done endodontic treatment of tooth #6. Notice the multiple portals of exit as they relate to the presence of lesions.

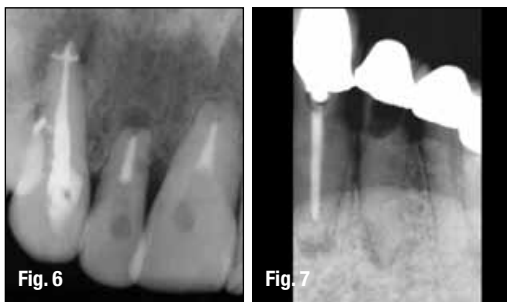


Fig. 7 Know when to say when. This dentist attempted to do an endodontic procedure that should not have been done.

side of their mouth. Temperature symptoms are a major motivator for patients to seek dental care.

Testing with ice involves establishing a baseline to cold. Typically, I chose to test the same tooth on the opposite side or the maxillary central incisor. I ask patients to tell me when they feel an "electrical shock or jolt" to the tooth. As soon as they do that, I remove the ice from the tooth. This is easily accomplished on the buccal surface of the tooth at the margin of the gingiva. When porcelain restorations are present, I strive to put the ice right at the margin on or above any metal margins.

Sometimes it is necessary to apply the ice on the lingual aspect of the tooth. As unresponsive as porcelain restorations can be, the clinician needs to be aware that pulp testing gold restorations can have the opposite effect. This is because of the metallurgical properties of gold. It is an amazing conductor of temperature. Always forewarn the patient when testing gold-restored teeth.

Ask the patient if the cold on the tooth reproduced his or her pain. Also, ask if the pain lingered after you removed the ice from the test site. If the pain it is lingering, it is a sign of irreversible pulpitis.

In some cases the pain can and does radiate along the pathway of the trigeminal nerve. Sometimes, especially in the maxilla, referred pain can be related to sinus issues, such as sinusitis, allergic rhinitis and rhinovirus.

If the patient does not respond to any thermal tests, both hot and cold, it is a sign that the pulp is necrotic, dying or infected. In this instance, studying the digital imaging may aid the diagnosis. One caveat: It is possible to have a necrotic pulp without being able to quantify it via digital images. In many incipient pathology issues, it takes approximately 90 to 120 days for breakdown to

manifest itself on imaging. Today's cone-beam imaging technology can shorten that process to 30 days. It is not uncommon to have a patient in the chair with symptoms that you cannot quantify radiographically.

Radiographic findings

Radiographic findings (Figs. 8a, b) are the road map for endodontics. Thorough study and evaluation of imaging allows the clinician to determine a multitude of facts about the tooth in question. What does the image reveal? Can you see if there is a widening of the pdl? If there is a widening of the pdl, it is essential to have the patient bite down on a bite stick.

Once he or she does that, you must ask if the pain, if present, is worse upon bite or upon release of bite. The latter is highly correlated with root fracture. Once that is confirmed, the next step is to prepare the patient for a root canal.

The dentist must convincingly explain the procedure's value as well as caution the patient about the possibility of losing the tooth due to the fracture extending apical from the cementoenamel junction (CEJ). Is there a lesion (Figs. 3a, 3b) present? This information allows me to frame my diagnostic questions to the patient. These include: Is the tooth sensitive to cold? I know from the lesion that the answer to that should be no. If, however, the answer is yes, it automatically triggers my mind to look for another tooth.

Generally, speaking teeth with lesions of endodontic origin (LEOs) test non-vital to thermal or electric pulp testing. In sequencing, I first ask for the patient's report, followed by radiographic findings, which I then augment with clinical testing to tie it all together and arrive at a diagnosis. Lastly, are caries present? The location of caries is a determining factor as to whether a root canal is needed (Figs. 4a, b).

Restorability

Restorability is an issue that has been a hot topic in dentistry for years. Its meaning has evolved as technology has become the backbone of modern dentistry. Prior to the incorporation of implant dentistry, restorability had a very different meaning. Dentists were much more motivated to save teeth. Options and creativity were necessary for clinical success, both in endodontics as well as in restorative dentistry.

Technology has taken away one form of resourcefulness and replaced it with the promise of a panacea. It has become far too easy for general dentists to recommend removal of a tooth to a

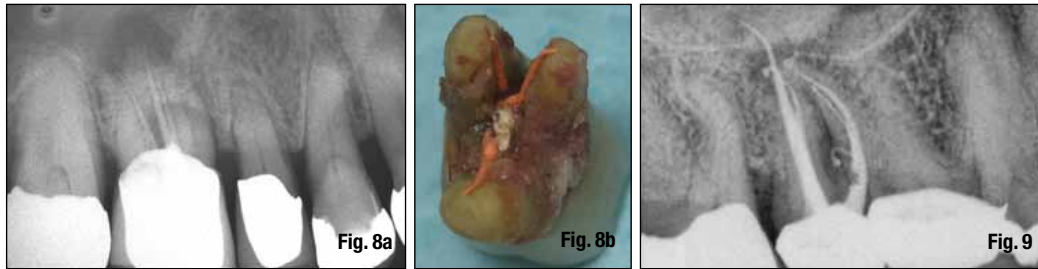


Fig. 8a Initial digital image with a patient whose chief complaint was mild pain to bite and chew.

Fig. 8b Digital photo of the tooth after I extracted it, showing a gross negligence. The tooth was perforated through the furcation, and gutta-percha was placed in what the dentist thought was the root canal system.

Fig. 9 The complexities of maxillary molar endodontics and multiple portals of exit. Of note, I was never able to shape the MB2 canal.

patient with the promise that an implant will save the day.

Historically speaking, the diagnosis of a tooth being non-restorable came after a myriad of attempts to save the tooth. Every aspect of dentistry came into play. Periodontists did osseous surgery and root amputations. Endodontists performed conventional endodontics and, if necessary, surgical intervention to do everything possible to save the tooth. Decisions involving the long-term prognosis of the tooth were relevant. Decisions about the type of restoration were discussed. Decisions about the osseous health of the roots and surrounding bone structures were relevant.

The goal of every specialist is to be an extension of the general dentist's practice. To that end, deciding whether a tooth was restorable or not was, at a minimum, a conversation to be had between the specialist and the general dentist.

Leap forward to the new millennium, and dentists no longer fight to save teeth. Dentists realize the financial windfall that implants offer their practices. Dentists can attend a myriad of continuing education courses over a weekend and on Monday become nascent implantologists. This fact makes diagnosis and saving a tooth the most important facet of restorative dentistry moving forward.

Treatment planning and restorability are integral to success both for the patient and the dentist. A patient in pain presents a unique opportunity for the dentist. Many questions need to be asked and answered. Among them: What can the dentist do to manage the pain? What is the cause of the pain? How long has the patient been in pain? Once the initial triage phase is complete, other factors must be addressed. These include: Is the tooth restorable? If endodontic treatment is indicated, what further treatment will be needed? Is there a need for periodontal intervention? If so, what type of treatment is it? Osseous surgery? Does the tooth need crown-lengthening surgery? How will these procedures affect the adjacent teeth?

The above paragraph speaks volumes as to the complexities of treatment planning in dentistry today. Every day in offices around the world, a patient visits his or her dentist in pain. How the dentist responds to this will go a long way in determining the

patient's dental well-being. A well-rounded practice with high moral fiber will enable the dentist and patient to work synergistically to develop a realistic treatment plan.

The last essential ingredient to success is that the dentist knows "when to say when" (Fig. 7). As a specialist and lecturer, I believe that if a general dentist does roughly 80 percent of the endodontic cases that walk in the door of his practice and refers out the remaining 20 percent, he or she will have a very busy endodontic practice. In the past five years, especially since the decline in the economy and busyness of practices, more than 50 percent of my practice consists of retreatment. The general dentist should have never attempted more than half of those cases. I can only speculate how much more there would be if dentists didn't have implants to fall back upon.

Implants vs. endodontic treatment

The next aspect of the diagnostic conundrum is the increasing role implants play in treatment planning. When I first began practicing endodontics in 1988, implants were in their nascent stages. If a patient had a root canal and continued to experience pain or discomfort, both the dentist and the endodontist had a myriad of choices, from retreatment to surgical correction. In 2013, the knee-jerk reaction to placing implants has never been greater. More and more general dentists go to weekend "seminars/courses," and on Monday morning they are placing implants. Much of this is based on the financially lucrative aspect of implant dentistry.

This has created polarizing arguments: save the tooth via endodontic treatment, or extract the tooth and place an implant. Too soon today, dentists will opt to extract a tooth that has a questionable prognosis in favor of placing an implant. It is my opinion that dentists should exhaust all possible options before opting to place an implant. Recently, I treated two of my colleagues with cracked teeth who wanted to exhaust every option (both were treated surgically). Ironically, they are two dentists who are heavy into implant dentistry. There has never been a better time to employ the "Golden Rule" for treatment planning.