

laser

international magazine of laser dentistry

3²⁰¹³

| **research**

Treatment of aphthous stomatitis using low-level laser therapy

| **overview**

Surgical management of peri-implantitis with laser

| **industry report**

Diode laser application optimises the clinical outcomes of digital workflow



BE AMAZED BY WATERLASE®

The WaterLase iPlus system is simply amazing. It is our most advanced, most powerful and simplest WaterLase yet. But don't take our word for it. See for yourself at

AMAZEDBYWATERLASE.COM!

+ BREAKS THE SPEED BARRIER

- Up to 100/pulses per second
- Patented tech delivers 600 mJ/pulse
- As fast as a high-speed drill

+ ILASE 940nm DIODE LASER DOCKING STATION

- Adds dual wavelength convenience
- First totally wireless diode laser
- Battery operated with finger operation

+ INTUITIVE USER INTERFACE

- 52 illustrated procedure pre-sets
- Touch-screen controls
- Greatly simplifies the learning curve

+ BIOLOGICALLY FRIENDLY DENTISTRY

- No micro-fractures or thermal damage
- More precise, minimally invasive
- Relies on water and light to cut

**CONTACT US TO LEARN MORE
ABOUT WATERLASE IPLUS!**

OR VISIT AMAZEDBYWATERLASE.COM TO VIEW
INSTANT REACTIONS FROM DOCTORS AND PATIENTS!

**GO TO BIOLASE.COM TO FIND
YOUR LOCAL DISTRIBUTOR.**



**THE ONLY LASER FOR:
SOFT TISSUE • WHITENING • PAIN THERAPY**

©BIOLASE, Inc. All rights reserved. For use by licensed professionals only. BIOLASE, WaterLase, iPlus, and Deep Pocket Therapy with New Attachment are trademarks of BIOLASE, registered in the U.S. and other countries.

FOLLOW US!

[f](#) [t](#) [in](#) [yt](#) [p](#) [g](#) | www.biolase.com | +1.949.361.1200

BIOLASE®

Minimally invasive? See for yourself!



Dr Georg Bach

Dear readers of **laser** international magazine of laser dentistry,

Minimally invasive – a buzzword! Overused? Trite? I don't think so.

The almost inflationary application of this term by one or the other dental publication can safely be countered by the honest quest of dentists around the world for new, improved or modified procedures, which are less stressful for the patient, can be performed fast and with good results.

Dental therapy supported by laser light—I hope you don't mind this connecting passage—usually fulfills these demands completely:

Minimal: As a general rule, laser therapy requires less time than conventional techniques which are not supported by laser.

In: Laser therapies are "in", they have an exceedingly positive image und the demand among our patients is high.

And yet, they sometimes are invasive, but thanks to the laser light they result in less pain, less intraoperative bleeding and they usually come with good recovery and healing.

Laser is minimally invasive. See for yourself if my depiction of laser technology holds true on the 23rd Annual DGL Congress! Renowned speakers will present an extensive overview on the state-of-the-art of laser dentistry as well as tips for laser application in the daily practice on 15 and 16 November at the Maritim Hotel Berlin, Germany.

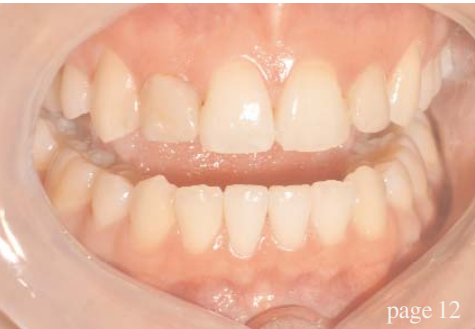I am glad to invite you to this "MUST" in the name of the German Society for Laser Dentistry, which has been the cooperation partner of laser for many years.

By the way, Berlin is always worth a trip!

With this in mind, enjoy reading this issue of **laser** international magazine of laser dentistry.

Warm regards,

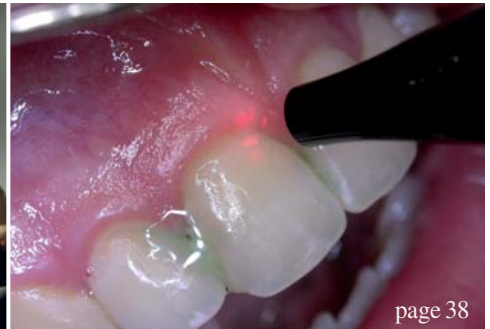Dr Georg Bach



page 12



page 26



page 38

| editorial

- 03 **Minimally invasive?** See for **yourself!**
| Dr Georg Bach

| research

- 06 **Incision and drainage** of a vestibular space **abscess** by **diode laser**
| Dr Wariya Panprasit *et al.*
- 12 **The diode laser** as an **electrosurgery replacement**
| Dr Glenn A. van As
- 18 **Treatment of aphthous stomatitis** using low-level laser therapy
| Pedro J. Muñoz Sánchez *et al.*

| overview

- 22 **Surgical management of peri-implantitis** with **laser**
| Prof. Dr Aslan Yar Gokbuget *et al.*

| industry report

- 26 **Diode laser** application **optimises** the clinical outcomes of **digital workflow**
| Prof. Dr Frank Liebaug *et al.*
- 30 **Lasers in periodontal therapy:** the TwinLight® approach
| Giovanni Olivi *et al.*
- 34 **Treatment of drug-induced gingival enlargement** with **Er:YAG laser**
| Dr Blagovesta Yaneva *et al.*
- 38 **The green power**
| Dr Darius Moghtader

| economy

- 40 **Gain power** at your **laser** clinics!
| Dr Anna Maria Yannikos

| interview

- 44 **Ultimately, I wish for laser education** to be completely integrated within the school of dentistry, everywhere.
| An interview with Macedonian Professor Ana Minovska

| meetings

- 46 **1st Meeting** of the **WFLD North American** Division
| Prof. Dr Georgios Romanos

| news

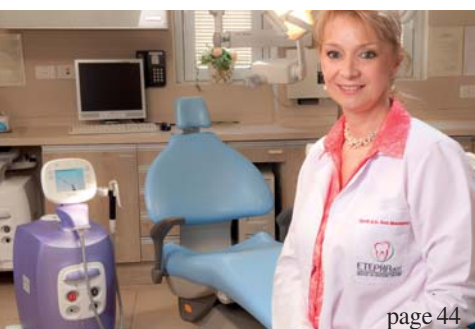- 42 **Manufacturer** News
- 48 **News**

| about the publisher

- 50 | imprint



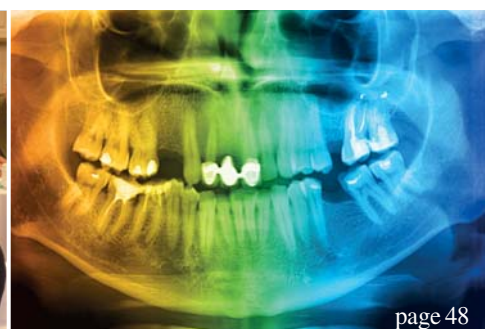
background image: ©Barbol



page 44



page 46



page 48



The first digitally controlled
dental laser handpiece

X-Runner

- instantly adjustable spot size and shape
- precise coverage of large areas
- lightweight, ergonomic design
- for Fotona LightWalker AT laser systems



Incision and drainage of a vestibular space abscess by diode laser

Authors_Drs Wariya Panprasit & Sajee Sattayut, Thailand

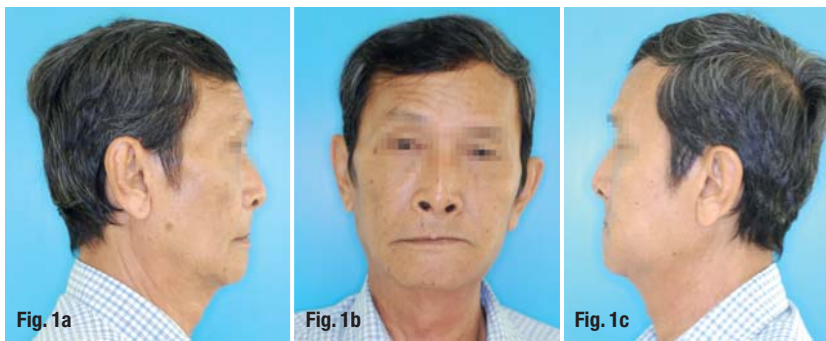

Fig. 1a-c Extra-oral swelling of the left cheek, right side (a); front view (b); and left side (c).

Introduction

Odontogenic infection in the orofacial regions causes tenderness, swelling, limited mouth opening and reduced function. In addition to this, the progressive infection may be life-threatening. The management of odontogenic infections entails rapidly eliminating the cause of infection; performing surgical drainage, which may be as simple as creating endodontic access for the removal of necrotic pulp or as complex as creating a wide incision for open drainage of accumulated pus and necrotic debris; administration of appropriate antibiotics; and supportive physical care. Typically, incision and drainage for the reduction of pus is performed using sharp dissection and retaining a Penrose or rubber tube drain until the

infection has subsided. This normally takes about two to five days, depending on the severity of the infection.^{1,2} There are some disadvantages of these procedures: bleeding during operation, the need for suturing, post-operative pain and oedema, early healing due to scar formation and discomfort from the inserted drain.

The properties of the diode laser provide advantages in soft-tissue surgery, such as producing precise surgical incisions with haemostasis, not requiring suturing, less post-operative swelling and pain, slower epithelial regeneration compared with traditional surgical wounds by producing necrotic tissue, and the promotion of good wound healing.³⁻⁸ Therefore, the diode laser can be used to simplify the surgical phase of odontogenic infection management considerably, as shown in this case report, illustrating the clinical use and efficacy of the diode laser for incision and drainage as a part of the management of intra-oral space abscesses.

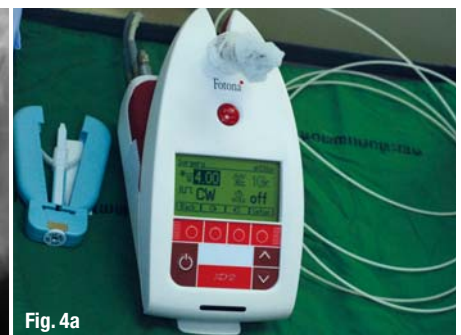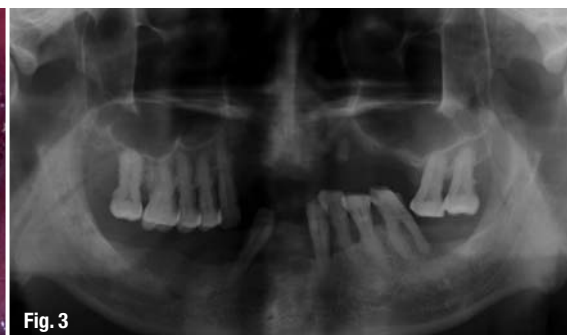
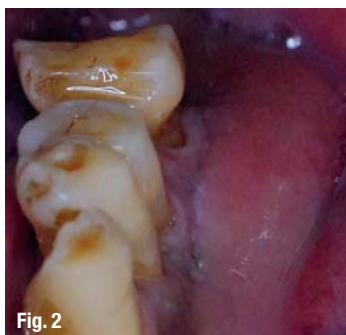Methods of laser incision and drainage

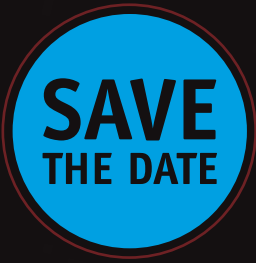The surgical procedure was performed under local anaesthesia, 2% mepivacaine with 1:100,000 epinephrine. An 810 nm diode laser (320 diameter fibre optic, 4 W, continuous wave) was used to ablate the

Fig. 2 Intra-oral swelling at the vestibular area of the mandibular left premolar and molar.

Fig. 3 Generalised horizontal bone loss, complicated crown fracture, exposed pulp of the mandibular left first molar.

Fig. 4a Diode laser incision and drainage. The diode laser (Fotona) with a wavelength of 810 nm.





NOVEMBER 15-16,
2013// BERLIN,
GERMANY//MARITIM HOTEL

LASER START UP 2013



22nd ANNUAL CONGRESS OF THE DGL e.V.



DOWNLOAD
PROGRAMME AND
REGISTRATION FORM

PLEASE FAX THIS FORM

+49 341 48474-390

Further information about:

LASER START UP 2013 22nd ANNUAL CONGRESS OF THE DGL e.V

November 15-16, 2013, Berlin, Germany

NAME/E-MAIL

OFFICE STAMP

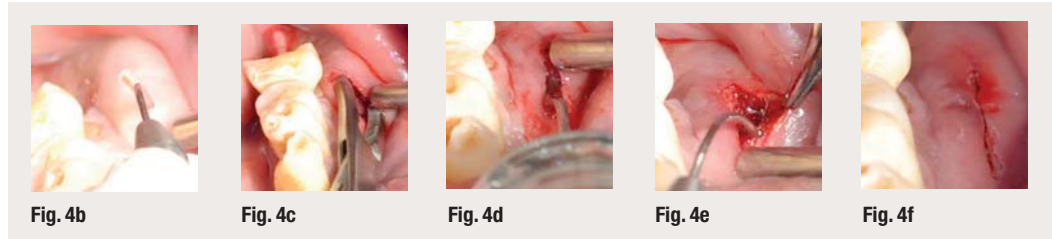
Fig. 4b Ablating mucosa with the diode laser; power setting at 4 W, continuous wave.

Fig. 4c Blunt dissection using curved artery forceps.

Fig. 4d Irrigation with a normal saline solution.

Fig. 4e Coagulating the incisional margin with the diode laser; power setting at 2 W, continuous wave.

Fig. 4f Finishing the surgical treatment without bleeding, suturing or a drain.



tissue from the most fluctuated oral mucosal area through the submucosal layer without perforating the periosteum, creating an incision of 1.5–2 cm in length.

Then, blunt dissection was performed. After irrigation with a normal saline solution, the incisional margins and submucosal layers were coagulated using the diode laser at 2 W, continuous wave. This aimed at maintaining soft-tissue tunnelling for pus drainage without placing sutures and inserting a drain. Amoxicillin, metronidazole, paracetamol and 0.12% chlorhexidine mouthwash were prescribed. Three cases of vestibular space abscess were treated.

Case 1

A 65-year-old male patient presented to the Department of Oral and Maxillofacial Surgery of the Faculty of Dentistry at Khon Kaen University in Thailand with swelling of and pain in the left cheek that had lasted for one day. The left submandibular lymph node was tender and movable with a diameter of 0.5 cm (Figs. 1a–c). The patient had normal mouth opening and the buccal vestibule of the mandibular left posterior teeth was swollen. It was soft in consistency, with normal mucosal colour and texture. There was a partial fracture of the mandibular left first molar, exposing pulp (Fig. 2). The tooth mobility was Grade I. In the radiographic examination, the panoramic radiograph (Fig. 3) showed that there was furcation involvement in the mandibular left first molar, with total bone loss of the distal root with a circumscribed periapical radiolucency of 2 x 4 mm in size, and 20% bone loss of the mesial root. Other significant findings from the radiographic examination included 50% horizontal bone loss of the mandibular left canine and premolars, extrusion of the maxil-

lary left second and third molars, generalised bone loss with subgingival calculus of the maxillary right canine and premolars, normal condylar shape and position, and normal density of the maxillary antrum. The case was diagnosed as a vestibular space abscess secondary to a complicated crown fracture of the mandibular left first molar. The treatment was a combination of diode laser incision and drainage under local anaesthesia (Figs. 4a–f), extraction of the mandibular left first molar and antibiotic administration.

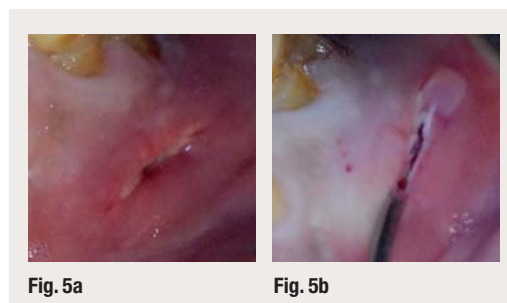
On day three after treatment, there was clinical improvement and the infection had subsided. The drainage via the laser incision remained intact. Irrigation with a 0.9% normal saline solution was carried out (Figs. 5a & b). Then, the mandibular left first molar was removed by a simple extraction technique under local anaesthesia.

Case 2

A 21-year-old female patient presented with swelling and pain in the region of the maxillary anterior teeth that had lasted for two days. She was undergoing orthodontic treatment. The extra-oral examination found a mild swelling of the philtrum. The intra-oral examination found a swelling of 1 x 2 cm in size at the labial gingiva, extending to the vestibule, that was soft in consistency, with tenderness on palpation. There were large tooth-coloured material fillings at the mesial surfaces of the maxillary left and right central incisors. The restorative filling of the maxillary right central incisor was significantly discoloured (Fig. 6a). The periapical film showed a well-circumscribed periapical radiolucency at the right central and lateral incisors of 1 x 1 cm in size and at the left central incisor of 0.3 x 0.3 cm in size (Fig. 6b). A vestibular space abscess was diagnosed. The treatment plan entailed root-canal treatment for the maxillary right incisors and the maxillary left central incisor, diode laser incision and drainage of the vestibular space abscess, and antibiotic administration. Diode laser incision and drainage (Fig. 6c) were performed at the first visit and antibiotics were administered. The patient presented again for follow-up visits one day and three days post-treatment. On day five after the operation, the incisional wound had almost completely healed and

Fig. 5a Laser incision with a thin coagulum three days post-treatment.

Fig. 5b Irrigation at the area of laser incision with a normal saline solution.



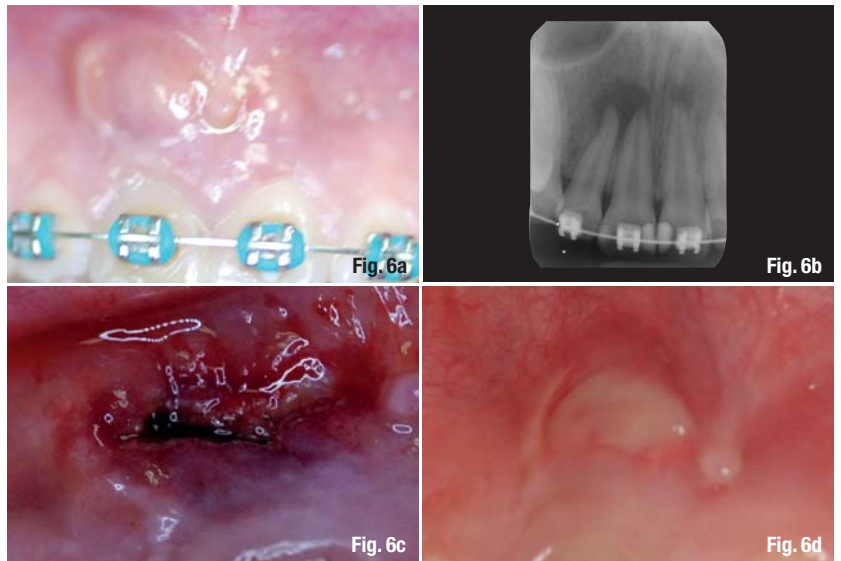
irrigation was not required (Fig. 6d). The clinical symptoms had resolved completely.

Case 3

A 27-year-old male patient presented with swelling and pain in the left cheek that had lasted for three days. The extra-oral examination findings were clinically within normal limits. The intra-oral examination found both swelling and shallowing of the vestibule of the mandibular left premolars and the first molar. There was an extensive carious lesion with pulpal exposure of the first molar (Fig. 7a).

The panoramic radiograph showed a well-circumscribed periapical radiolucency at the mandibular left first molar (Fig. 7b). The diagnosis was a vestibular space abscess. The treatment plan was the same as that of case 2. At the first visit, diode laser incision and drainage were performed (Fig. 7c) and antibiotics were prescribed. On day three after the operation, the laser wound was covered with a thin coagulum and irrigation could be performed (Figs. 7d & e).

Clinical symptoms, such as swelling and tenderness, had decreased. On day six after laser incision and drainage, all clinical symptoms had resolved



completely. A small opening remained in the laser wound for irrigation (Fig. 7f).

Discussion

When the blunt dissection was performed, the cases presented showed infection only in the superficial areas at a depth of less than 3 cm. In comparison with other types of lasers, such as the carbon dioxide,

Fig. 6a Vestibular space abscess of the maxillary incisors.

Fig. 6b Periapical film showing periapical radiolucencies of the maxillary incisors.

Fig. 6c Immediately post-treatment with diode laser incision and drainage.

Fig. 6d Laser wound on day five post-treatment.

AD

*become an author
for "laser"*

Please contact Claudia Jahn
✉ c.jahn@oemus-media.de