

roots

the international C.E. magazine of endodontics

3²⁰¹⁵

C.E. article

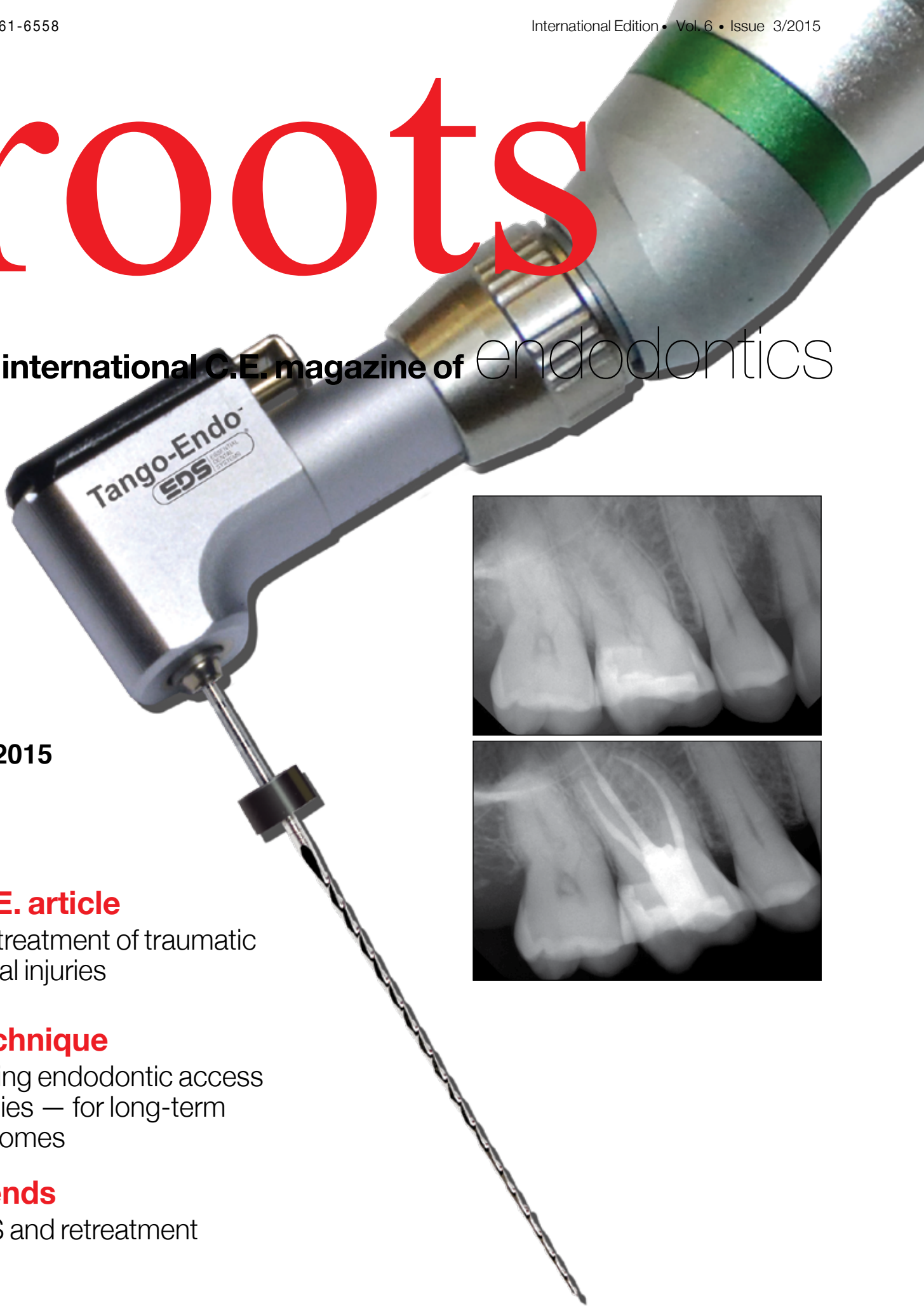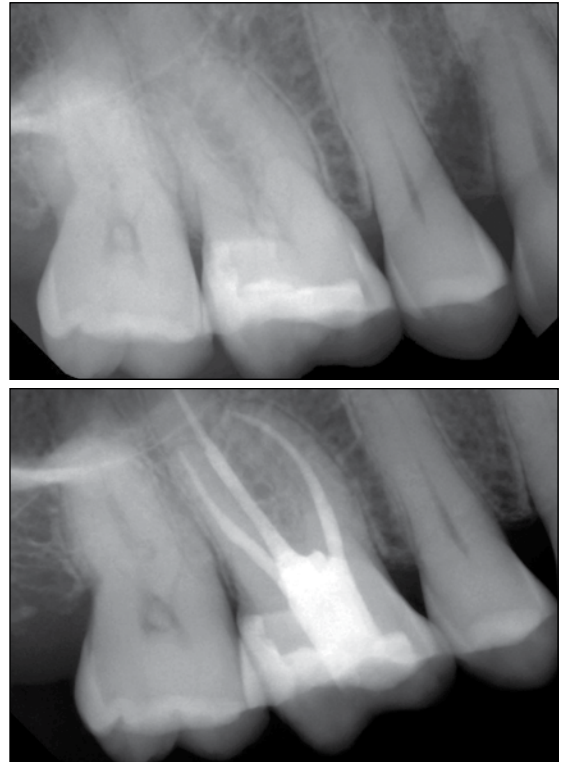
The treatment of traumatic dental injuries


technique

Cutting endodontic access cavities — for long-term outcomes

trends

PIPS and retreatment





VISION

Introducing the exciting new
A-Series™ Dental Microscope
from Global

GLOBAL
SURGICAL™ CORPORATION

We make it easier

Call today for a demonstration

1.800.767.8726 | www.globalsurgical.com

Inside baseball

We endodontists are a curious bunch. We are constantly honing our craft. We are always looking for ways to treat cases better and more predictably for our patients. But to stay on top of our game, we must always keep up to date on the latest technology and treatment options.

Much of this knowledge is esoteric — call it "inside baseball," if you will.

In this issue of *roots*, you can find many articles designed to enhance your specialized skill set. Dr. Asgeir Sigurdsson offers an article on the treatment of traumatic dental injuries. Dr. L. Stephen Buchanan presents a number of cases treated with smaller-than-average access cavities. Dr. Reid Pullen describes using laser technology in a retreatment case, and Dr. Tyler F. Baker shares his experience using new sound wave technology for endodontic disinfection.

The article by Dr. Sigurdsson, which originally appeared in *ENDODONTICS: Colleagues for Excellence*, the newsletter published by the American Association of Endodontists, is being made available in this issue of *roots* with the permission of the AAE. By reading this article, and then taking a short online quiz at www.DTStudyClub.com, you will gain one ADA CERP-certified C.E. credit. Keep in mind that because *roots* is a quarterly magazine, you can actually chisel four C.E. credits per year out of your already busy life without the lost revenue and time away from your practice.

To learn more about how you can take advantage of this C.E. opportunity, visit www.DTStudyClub.com. You need only register at the Dental Tribune Study Club website to access these C.E. materials free of charge. You may take the C.E. quiz after registering on the DT Study Club website.

I know that taking time away from your practice to pursue C.E. credits is costly in terms of lost revenue and time, and that is another reason *roots* is such a valuable publication. I hope you will enjoy this issue and that you will take advantage of the C.E. opportunity.

As always, I welcome your comments and feedback.

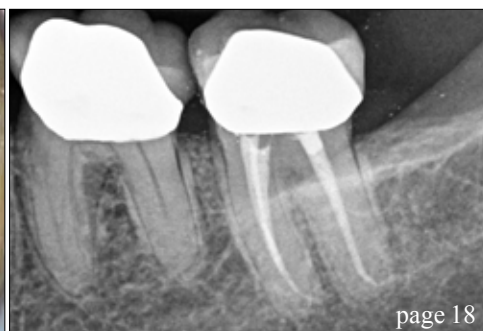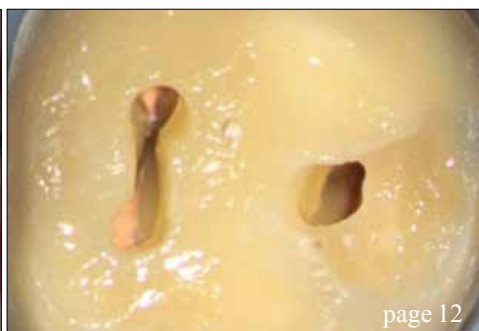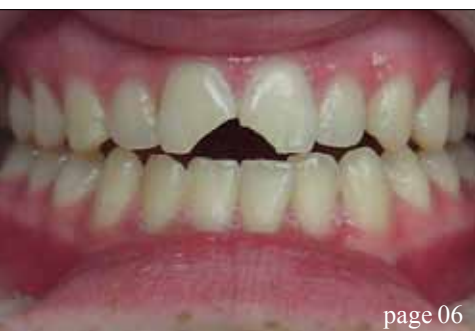Sincerely,



Fred Weinstein, DMD, MRCD(C), FICD, FACD
Editor in Chief



Fred Weinstein, DMD, MRCD(C),
FICD, FACD



| C.E. article

- 06 The treatment of **traumatic dental injuries**
_Asgeir Sigurdson, DDS, MS

| technique

- 12 Cutting **endodontic access** cavities — for long-term outcomes
_L. Stephen Buchanan, DDS, FACD, FICD

| trends

- 18 **PIPS** and retreatment
_Reid Pullen, DDS, FAGD
- 22 Sonendo: Challenging the standard of care with the **GentleWave System**
_Tyler F. Baker, DDS, MS

| industry news

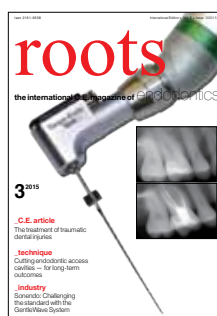- 25 FKG Denntaire in the 2015 ESE congress

| industry

- 26 Vista's **SmeaROFF**: One product, multiple benefits
- 28 Essential Dental Systems (EDS) introduces **Tango-Endo**

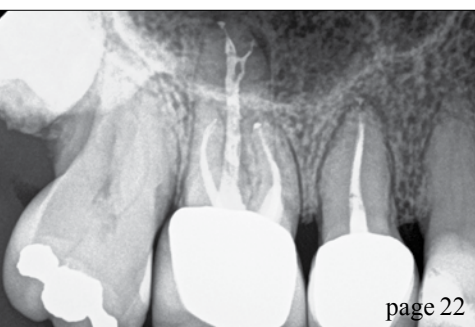
| about the publisher

- 30 _imprint



| on the cover

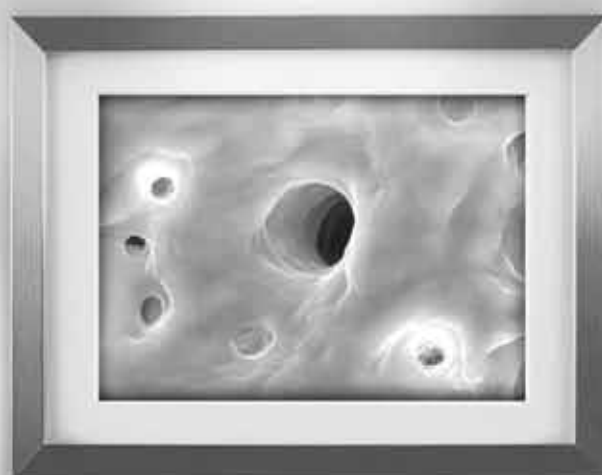The Tango-Endo reciprocating handpiece, available from Essential Dental Systems (EDS), allows for two-instrument shaping, shown with before-and-after images of an endodontic case treated with Tango-Endo. (Photos/Provided by EDS)





Is Your Practice

Surface of a root canal cleaned with conventional endodontic instruments (8000x magnification)



State of the Art?

Surface of a root canal cleaned with the GentleWave System (8000x magnification)

Not if you're using conventional therapies. Your instrumentation can leave up to 80% of canal space untouched¹—so tissue, bacteria and biofilm can remain. And if your therapy involves two treatment sessions, you could be missing out on new patients and referrals.

Art may be subjective, but State of the Art is about results. Once you see the results you get from the GentleWave™ System's patented, one-treatment Multisonic Ultracleaning™ technology, your perceptions about clean will be subject to change.

GENTLE WAVE™
ROOT CANAL THERAPY

Sonendo.com/Results

The treatment of traumatic dental injuries

Author_Asgeir Sigurdsson, DDS, MS

_c.e. credit

This article qualifies for C.E. credit. To take the C.E. quiz, log on to www.dtstudyclub.com. Click on 'C.E. articles' and search for this edition (Roots C.E. Magazine — 3/2015). If you are not registered with the site, you will be asked to do so before taking the quiz. You may also access the quiz by using the QR code below.



Fig. 1a Clinical case of two uncomplicated crown fractures in which the two broken pieces were located and reattached. (Photos/ Provided by American Association of Endodontists)

Figs. 1b, c After the two pieces had been attached, a chamfer was cut along the fracture line and additional composite cured in place. This will both increase the strength of the attachment and better hide the fracture line.

When treating dental trauma, the timeliness of care is key to saving the tooth in many cases. It is, therefore, important for all dentists to have an understanding of how to diagnose and treat the most common dental injuries. This is especially critical in the emergency phase of treatment.

Proper management of dental trauma is most often a team effort with general dentists, pediatric dentists or oral surgeons on the front line of the emergency service, and endodontic specialists joining the effort to preserve the tooth with respect to the pulp, pulpal space and root. An informed and coordinated effort from all team members ensures that the patient receives the most efficient and effective care.

Recently, a panel of expert members of the American Association of Endodontists prepared an updated version of Guidelines for the Treatment of Traumatic Dental Injuries.^{1,2} These guidelines were based, in part, on the current recommendations of the International Association of Dental Traumatology (see www.iadt-dentaltrauma.org for more information). This article provides an overview of the AAE guidelines; the complete guidelines are available for free download at www.aae.org/clinical-resources/trauma-resources.aspx.

The benefit of adhering to guidelines for treatment of dental trauma was recently shown in a study by Bucher et al.³ The study found that, compared with cases treated without compliance to guidelines, cases that adhered to guidelines produced more favorable outcomes, including significantly lower complication rates. The study also found that early follow-up visits were essential to ensure prompt treatment of complications when they arose.³

_Emergency care

Prior to any treatment, one must evaluate the

injury thoroughly by careful clinical and radiographic investigation. It is recommended to follow a checklist to ensure that all necessary information regarding the patient and the injury is gathered, including:

- 1) Patient's name, age, sex, address and contact numbers (include weight for young patients).
- 2) Central nervous system symptoms exhibited after the injury.
- 3) Patient's general health.
- 4) When, where and how the injury occurred.
- 5) Treatment the patient received elsewhere.
- 6) History of previous dental injuries.
- 7) Disturbances in the bite.
- 8) Tooth reactions to thermal changes or sensitivity to sweet/sour.
- 9) If the teeth are sore to touch or during eating.
- 10) If the patient is experiencing spontaneous pain in the teeth.

Once all of this information is gathered, a diagnosis can be made and appropriate treatment rendered. If the injured individual is not a patient of record, all necessary demographic information should be gathered as soon as the patient arrives and prior to any assessment. In the case of avulsion and the tooth being out of its socket, one should immediately place the tooth in a physiological solution of specialized media (such as Hank's Balanced Salt Solution™) or milk, or saline if those are not available. Only after the tooth is secured in solution should one obtain the patient's information. Once the patient is seated in the dental chair, it is necessary to do a quick central nervous system (CNS) evaluation before proceeding with further assessments.

Often, the dentist is the first health-care provider to see the patient after a head injury (any dental trauma is, by definition, a head injury) and must assess the risk

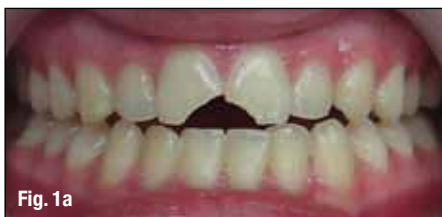

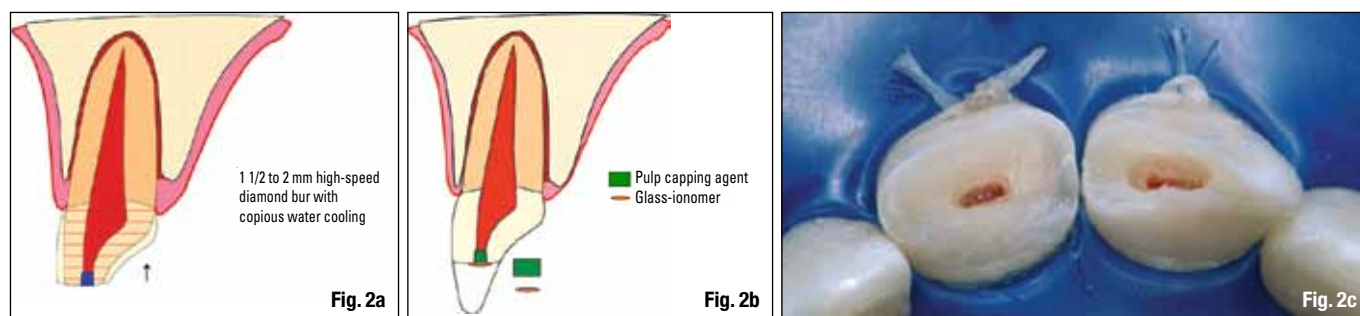
Fig. 1a

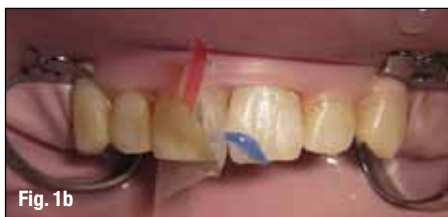

Fig. 1b

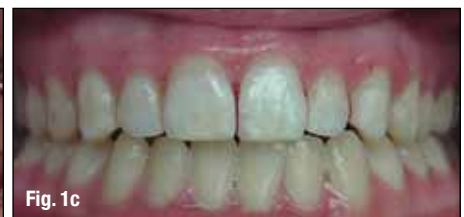

Fig. 1c



of concussion or hemorrhage. It has been estimated by a meta-analysis that the prevalence of intracranial hemorrhage after a mild head injury is 8 percent, and the onset of symptoms can be delayed for minutes to hours.⁴ The most common signs of serious cerebral concussion or hemorrhage are loss of consciousness or post-traumatic amnesia. Nausea/vomiting, fluids from the ear/nose, situational confusion, blurred vision or uneven pupils, and difficulty of speech and/or slurred speech may also indicate serious injury.⁵

Once the patient has been cleared of any CNS issues, the dental trauma should be assessed. The key is to obtain comprehensive information about the injury and, to do so, one must conduct thorough extraoral and intraoral clinical exams as well as appropriate radiographic evaluations.

The new AAE guidelines recommend taking one occlusal and two periapical radiographs with different lateral angulations for all dental injuries, including crown fractures. If cone-beam computed tomography is available, it should be considered for more serious injuries, such as crown/root, root and alveolar fractures, as well as all luxation injuries.

Additionally, sensibility tests should be conducted on all teeth involved as well as opposing teeth. Cold testing is recommended over electric pulp testing in young individuals.⁶ Both testing methods should be considered, however, especially when there is no response to one of the two. The pulp might be non-

responsive for several weeks after a traumatic injury, so a pulp test should be done at every follow-up appointment until a normal response is obtained.⁷

Once the diagnosis is confirmed and more serious complications such as CNS and jaw or other facial bone fractures have been ruled out, the emergency phase of the treatment needs to be initiated. The aim of treating dental trauma should be to either maintain or regain pulpal vitality in traumatized teeth. This is because dental trauma most frequently occurs in pre-teens or young teens in whom the teeth have not yet fully developed, and root development will cease without a vital pulp.

Clinical examples

Dental trauma can be roughly divided into two groups: fractures and luxation injuries. The fractures are then further divided by type: crown, crown-root and root fractures. If the pulp is exposed to the oral environment, it is called a complicated fracture; if not exposed, it is called an uncomplicated fracture.

Crown fractures: The first thing to do in any crown or crown-root fracture is to look for the broken-off tooth fragment. With modern bonding technology it is possible to rebond the fragment to the tooth, which is esthetically the best solution. Prior to reattaching the tooth fragment, the remaining dental thickness immediately covering the pulp

Fig. 2a Schematic diagram of minimal pulpotomy, where an approximately 2-mm reservoir is cut with a high-speed diamond bur and copious water cooling and calcium hydroxide mixed with sterile water placed. (Schematic drawings/ Provided by Dr. Sigurdsson)

Fig. 2b Glass ionomer or a protective liner is placed over the pulp capping agent to ensure it stays in place during etching and bonding.

Fig. 2c Clinical pictures of the minimal pulpotomy.

Table 1. Follow-Up Procedures for Fractured Permanent Teeth and Alveolar Fractures

TIME	Crown Fracture		Crown-Root Fracture		Root Fracture	Alveolar Fracture
	Uncomplicated	Complicated	Uncomplicated	Complicated		
4 Weeks					Splint removal*, clinical and radiographic control	Splint removal and clinical and radiographic controls
6-8 Weeks	Clinical and radiographic control	Clinical and radiographic control	Clinical and radiographic control	Clinical and radiographic control	Clinical and radiographic control	Clinical and radiographic control
4 Months					Splint removal**, clinical and radiographic control	Clinical and radiographic control
6 Months					Clinical and radiographic control	Clinical and radiographic control
1 Year	Clinical and radiographic control	Clinical and radiographic control	Clinical and radiographic control	Clinical and radiographic control	Clinical and radiographic control	Clinical and radiographic control
Yearly for 5 Years					Clinical and radiographic control	Clinical and radiographic control

*Splint removal in apical third and mid-root fractures; **Splint removal with a root fracture near the cervical area

(Tables/Provided by American Association of Endodontists)

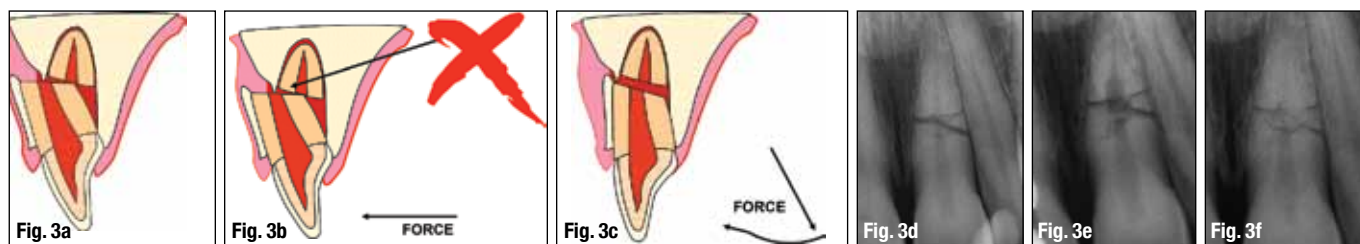


Fig. 3a Schematic drawing of a common situation after root fracture: The crown portion is displaced inward toward the palate and the fractured piece is stuck to the facial cortical plate.

Figs. 3b, c It is impossible to move the coronal portion back to its original location without releasing it from the cortical plate. This is accomplished by pulling the coronal portion down and then repositioning it.

Fig. 3d A periapical radiograph of a root fracture a few hours after the injury. It was established that both fragments were in good approximation of each other. Splinting was done for two weeks.

Fig. 3e At the nine-month recall, internal root resorption was noted, but no defect in the PDL or adjacent bone, indicating a 'normal' healing process.

Fig. 3f Five-year recall, no endodontic treatment was needed.

needs to be assessed radiographically and clinically. If there is at least 0.5 mm of the dentin remaining, there is no need to cover it with a protective liner. If it is estimated that the remaining dentin is less than 0.5 mm, it is advisable to cover the deepest part, closest to the pulp, with a cavity liner, and then dimple the fragment accordingly.^{8,9} If the tooth fragment was kept dry, it should be rehydrated in distilled water or saline for 30 minutes prior to reattachment. This process will increase its bonding strength¹⁰ (Figs. 1a-c).

In a complicated fracture, the goal is to create a bacteria-tight seal to protect the pulp, after ensuring that the pulpal wound is clean and all inflamed tissue removed.^{11,12} The two best capping materials available today are calcium hydroxide and mineral trioxide aggregate (MTA),^{13,14} but newer bioceramic materials are showing promise for this application. It is advisable to create a 1-2 mm reservoir into the pulp with a high-speed diamond bur and copious water cooling, place the capping material, and then either reattach the tooth fragment or restore the crown with a composite resin material (Figs. 2a-c).

Crown-root fractures: One of the more challenging types of fracture to treat is the crown-root fracture because the fracture margin has to be exposed around the tooth/crown to properly restore the tooth. This can be accomplished by gingivectomy if the fracture line is in the sulcus. In more extreme cases, the tooth will have to be extruded with orthodontic forces or surgically repositioned. In the emergency session, if the pulp is exposed, it needs to be protected in the same fashion as complicated crown fractures. If

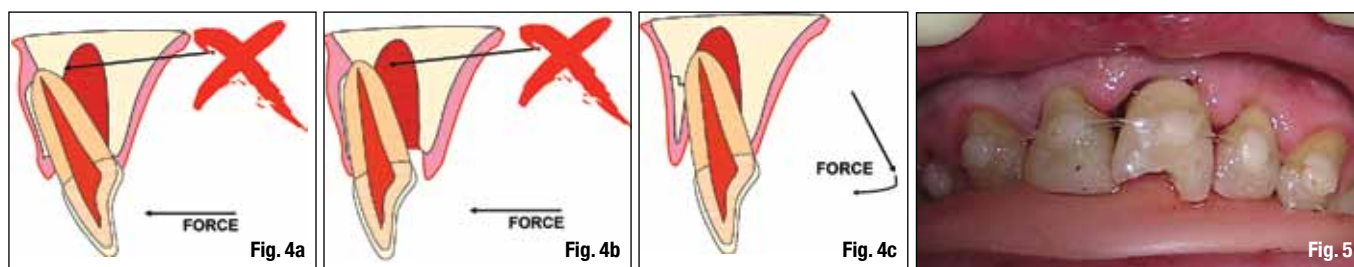
the pulp is not exposed, all accessible exposed dentin areas should be covered for the patient's comfort.

Pulpal survival for all these fracture types is generally good; however, endodontic treatment may be indicated later.^{15,16} Therefore, it is of utmost importance that a recall schedule is followed and that the teeth involved in the trauma are tested every time. Tables 1 and 2 outline the recommended recall rates for most common dental injuries. It is not uncommon for there to be no response to vitality tests for up to three months, and a lack of response to vitality tests does not always indicate that root canal treatment is needed – especially in young and immature teeth. Rather, it is advisable to look for at least one other sign of pulpal necrosis, such as vestibule swelling, periapical lesions and/or dramatic color change of the crown. If no signs exist, continue to monitor the patient at regular appointments every three months, for up to one year.

Root fractures: The pulp is affected in all root fractures. However, if the fragments are approximated soon after the fracture, there is a good chance that no endodontic treatment is necessary, just observation. With good approximation, it is likely that the pulp will revascularize across the fracture regardless of the age of the patient^{17,18} (Figs. 3a-f). A recent retrospective study included assessment of splinting type and time of root fracture. The study determined that, if the cervical portion of the tooth is stable once the two pieces have been approximated, no splint or a flexible splint for two weeks produces the best treatment outcome.^{2,18} Longer splinting time is recommended only when the fracture is close to the cervical area.

Table 2. Follow-Up Procedures for Luxated Permanent Teeth

TIME	Concussion/Subluxation	Extrusion	Lateral Luxation	Intrusion
2 Weeks	Splint removal (if applied for subluxation) Clinical and radiographic examination	Splint removal Clinical and radiographic examination	Clinical and radiographic examination	Clinical and radiographic examination
4 Weeks	Clinical and radiographic examination	Clinical and radiographic examination	Splint removal Clinical and radiographic examination	Splint removal Clinical and radiographic examination
6-8 Weeks	Clinical and radiographic examination	Clinical and radiographic examination	Clinical and radiographic examination	Clinical and radiographic control
6 Months	Clinical and radiographic examination	Clinical and radiographic examination	Clinical and radiographic examination	Clinical and radiographic examination
1 Year	Clinical and radiographic examination	Clinical and radiographic examination	Clinical and radiographic examination	Clinical and radiographic examination
2-5 Years	Yearly up to 5 years	Yearly up to 5 years	Yearly up to 5 years	Yearly up to 5 years



Luxation injuries: All luxation injuries will cause some damage to the periodontal ligament and, in some cases, the pulp as well. The immediate treatment is to limit further damage to the PDL and allow for the best possible healing. As with all dental injuries, follow-up is essential. Late complications, such as internal or external root resorptions, are relatively frequent and require endodontic treatment, especially in more severe injuries. In many of these cases, referral to an endodontist is advisable.

Luxation injuries are divided into subcategories, mainly by degree of severity. The two mildest are termed "concussion" and "subluxation." In those cases, the tooth is still in its original location, but is tender to percussion and/or, in the case of subluxation, has increased mobility. While no immediate treatment is needed for these injuries, follow-up is critical because the pulp may become necrotic, making endodontic intervention paramount.

When trauma has moved the tooth out of its normal position, it needs to be replaced gently as soon as possible. The only exceptions are cases of intrusion when it might not be possible or advisable to manipulate the tooth immediately. When an immature tooth is intruded up to 7 mm, it is recommended to wait three weeks and watch for signs of re-eruption. If no signs exist, one can initiate orthodontic repositioning. For intrusion of more than 7 mm, surgical or orthodontic repositioning should be performed within three weeks. In the case of an intruded tooth with a closed apex, there is a possibility of re-eruption if the tooth is slightly intruded (less than 3 mm) and the patient is younger than 17 years old. If the tooth is not moving after two to three weeks, however, orthodontic extrusion or extraction and reimplantation is recommended. If a tooth with a closed apex is intruded more than 3 mm, orthodontic or surgical repositioning should be performed within three weeks. The risk with all intrusions is that the intruded tooth may ankylose in the infraposition. Once that begins, the tooth may not be movable except possibly surgically. It is well to advise the patient and the parents/guardians that the long-term prognosis of an intruded tooth is unpredictable, as it is likely to eventually be lost due to ankylosis.¹⁹⁻²¹

Splinting of a luxated tooth is recommended only for teeth that are still mobile after repositioning. In all types of trauma cases, a splint must allow for physiological movement.^{22,23} (See Figs. 4a-c and 5, and Table 3, regarding splinting time.)

When assessing luxation trauma, it is important to consider the maturity of the apex. If it is still open, there is a chance that the pulp will survive the trauma or revascularize, allowing the growth of the tooth to continue (Figs. 6a-c).

If the apex is closed, endodontic treatment is likely needed. It is advisable to follow the patient closely (Table 1) or refer him or her to an endodontist for further evaluation. Because of the injury to the PDL, rapid inflammatory root resorption can occur (within days or a few weeks) if the necrotic pulpal tissue becomes infected. For mature teeth diagnosed with necrotic pulps, placing calcium hydroxide for two to four weeks prior to obturation is recommended; however, one should allow the PDL to heal for two weeks before placement (see treatment for avulsion, below). Apexification or revascularization is recommended for teeth with open apices.^{24,25}

It is important to remember that dental injuries do not always fall into one group or category, but often a combination of several categories. Injuries in multiple categories will impact the outcome. For example, it was recently demonstrated that the existence of a concurrent luxation injury with an uncomplicated crown fracture and complete root development are significant risk factors of pulp necrosis.²⁶

Avulsion: The time outside of the socket for an avulsed tooth is the most critical of its survival. If the tooth is replanted within 30 minutes, or alternatively kept in a physiological solution of specialized media or milk for a few hours, it has a fairly good prognosis.^{27,28} If the tooth has been dry for more than one hour, the periodontal ligament cannot be expected to survive and the tooth will likely become ankylosed (Fig. 7).

Fig. 4a In lateral luxation injuries of maxillary teeth, the apex is frequently pushed through the cortical plate facially.

Figs. 4b, c To reposition the tooth, it has to be released prior to moving the crown forward.

Fig. 5 Once the tooth has been repositioned, the patient bites into a softened pink wax plate that had been previously rolled one or two times. This will ensure that the luxated (or avulsed) tooth stays in place while being splinted. In this case, a 16-pound fishing line was used as the splint on the luxated tooth.

Table 3. Splinting Time for Various Types of Injuries

Type of Injury	Splinting Time
Subluxation	2 weeks
Extrusive luxation	2 weeks
Avulsion	2 weeks
Lateral luxation	2 weeks
Intrusion	4 weeks
Root fracture (middle 1/3)	4 weeks
Alveolar fracture	4 weeks
Root fracture (cervical 1/3)	4 months