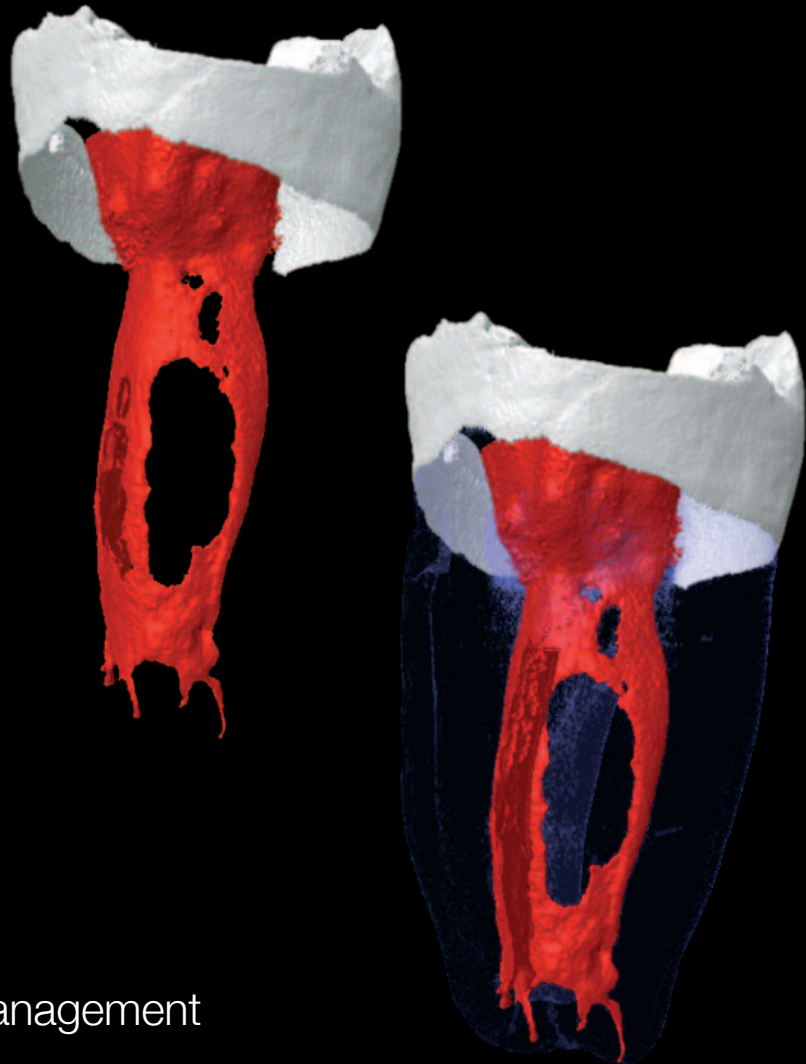


roots

international magazine of endodontology

1 2012



| **case report**

Large periapical lesion management

| **special**

The antibacterial effects of lasers in endodontics

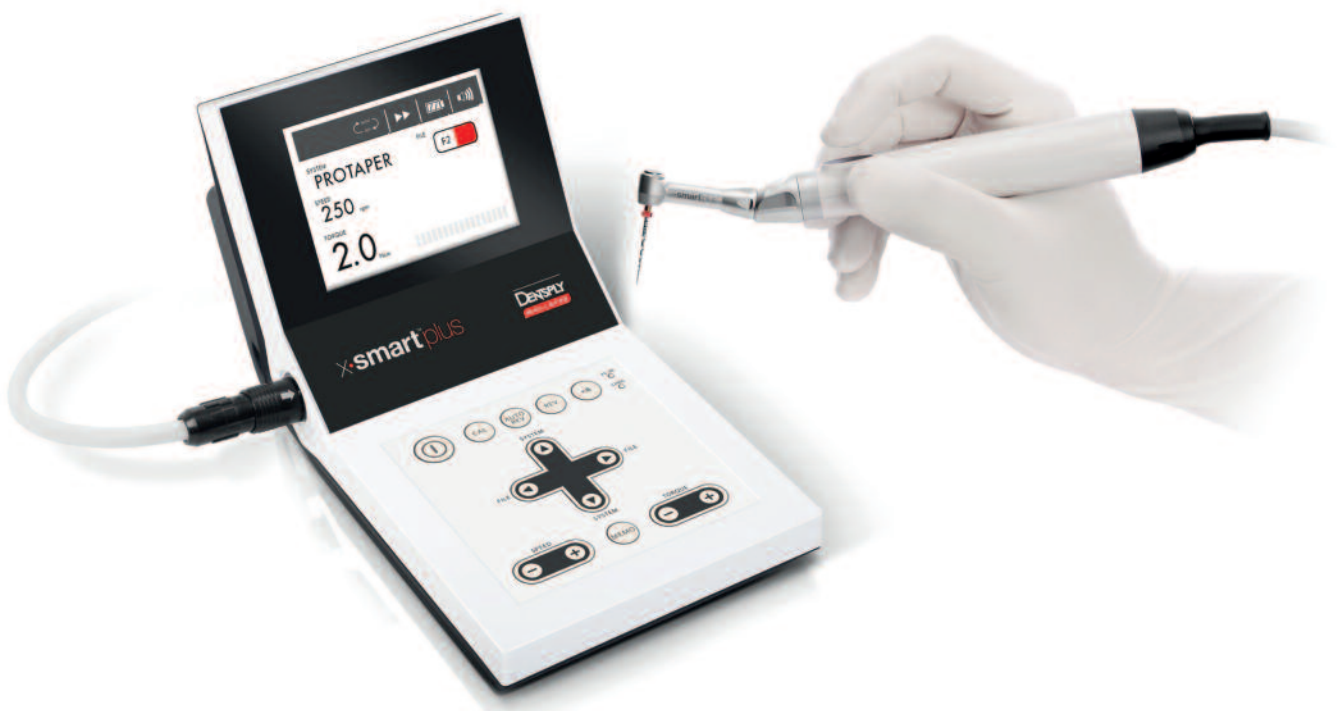| **research**

Ability of four irrigating solutions to remove debris after root-canal instrumentation

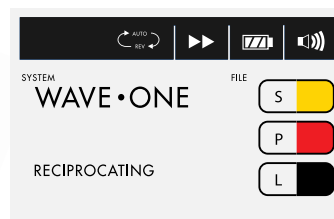


x•smartTMplus

everything you like about x•smartTM with a +



- wave•oneTM reciprocating motion as well as continuous rotation
- File selection at a single glance due to the ISO colour coded file library
- On / Off button on the motor handpiece
- Excellent visibility & access due to the miniature contra-angle head



Dear Reader,

Ten years ago, in January 2002, the German Society of Endodontology (DGEEndo) was founded. Full of enthusiasm, the 13 founding members pursued their goal of shaking up the endodontic world. In no time, a statute had been written, a home page and logo designed and the first annual meeting planned. Today, there are more than 1,000 registered members and the enthusiasm is still tangible. In light of this development, the German Society for Conservative Dentistry (DGZ) and the DGEEndo decided to join forces and formed the German Society of Endodontology and Traumatology (DGET). The first annual meeting was held in Bonn last year – a great start for a successful merger.

What began ten years ago with the use of modern technology has rapidly developed in recent years. Literature research on iPads during a presentation, lectures on mobile phones, apps and videos on YouTube are now available to many. This globalisation is also reflected in the representation of nationalities from all over the world amongst speakers at conferences and in the instant availability of the latest information and news.

Last year, a child born in Manila was symbolically named the world's seven billionth baby by the UN. Never before had that many people simultaneously lived on earth. According to the BBC, about 77 billion people have lived on our planet since the beginning of human history.¹ Thanks to the Internet, social networks and search engines, we now have virtually unlimited and rapid access to the knowledge mankind has accumulated thus far. In this context, endodontics has also experienced an explosion of factual knowledge and technological development in recent years. Furthermore, medicine, biology, chemistry, physics and engineering have become intermeshed in technology that offers never-before-seen speed and perfection. Today, in addition to the more technically oriented innovations, such as NiTi, reciprocating one-file systems or the technologically fascinating self-adjusting file, as well as an immense variety of new irrigation concepts, more biologically oriented ideas are taking shape.

In the April 2007 issue of the *Journal of Endodontics*, Kenneth M. Hargreaves called on researchers around the world to combine the available knowledge and to join efforts in the field of tissue regeneration in endodontics.² The collected ideas ranged from the revascularisation of the root canal to stem-cell therapy, pulp implants, 3-D polymer scaffolds, injectable 3-D cell printing and gene therapy. Today, some of these ideas have already found their way into our practices, such as triple antibiotic paste (metronidazole, ciprofloxacin, minocycline). Teeth with incomplete root growth and necrosis of the pulp treated with this paste show good development of the dentine–pulp complex in the form of good root development.³

Back in 2005, we succeeded in creating artificial dental and bone tissue in the laboratory.⁴ Researchers^{5–8} have been working on creating human teeth in test tubes for many years. Today, the daily press even reports about such news and, thus, endodontic topics have been made available to the whole world. Even though we only cover one of many sectors, these prospects hold significant implications for both specialists and patients, and keep us moving forward with enthusiasm and scientific curiosity.

Yours faithfully,

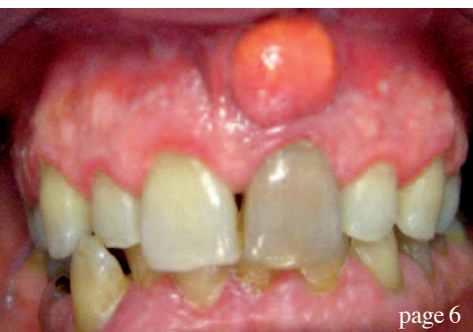

Prof Michael A. Baumann
University of Cologne, Germany

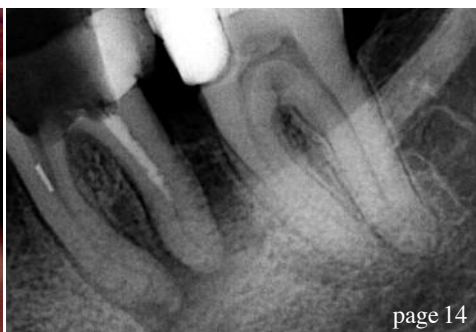

Prof Michael A. Baumann

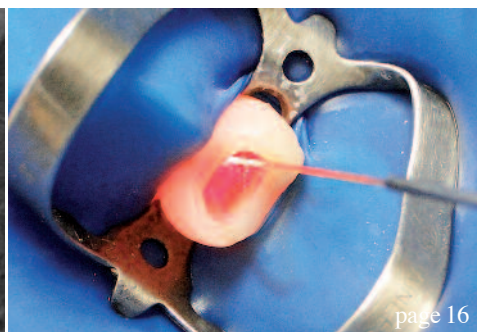
Editorial note: A complete list of references is available from the publisher.



page 6



page 14



page 16

| editorial

- 03 **Dear Reader**
| Prof Michael A. Baumann, Guest Editor

| case report

- 06 **Large periapical lesion management**
Decompression combined with root-canal treatment
| Dr Nuria Campo
- 10 **Intentional replantation: A viable treatment option for specific endodontic conditions**
| Prof Naseem Shah et al.
- 14 **When flexibility and strength are key**
| Dr Philippe Sleiman

| special

- 16 **The antibacterial effects of lasers in endodontics**
| Dr Selma Cristina Cury Camargo

| feature

- 22 An interview with **Dr Maria Emanuel Ryan**

| research

- 26 **Ability of four irrigating solutions to remove debris after root-canal instrumentation**
| Dr Jorge Paredes-Vieyra et al.

| The Endospot

- 30 **The lazy man's guide to persistent apical periodontitis**
| Dr Patrick Caldwell

| industry news

- 34 **New A-dec LED offers brilliant simplicity**
| A-dec
- 35 **G-Files—Rotary NiTi instruments for glide path enlargement**
| MICRO-MEGA

| meetings

- 36 **The 20th annual SSE conference** left nothing to be desired
| Dr Philipp Kujumdshiev

40 **International Events**

| about the publisher

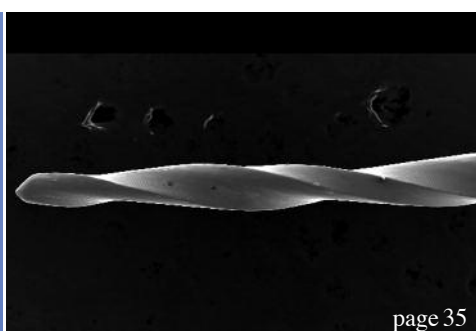
- 41 | submission guidelines
- 42 | imprint



Cover image courtesy of Prof Marco Versiani and Prof Manoel D. Sousa Neto, Ribeirão Preto Dental School, University of São Paulo.



page 34



page 35

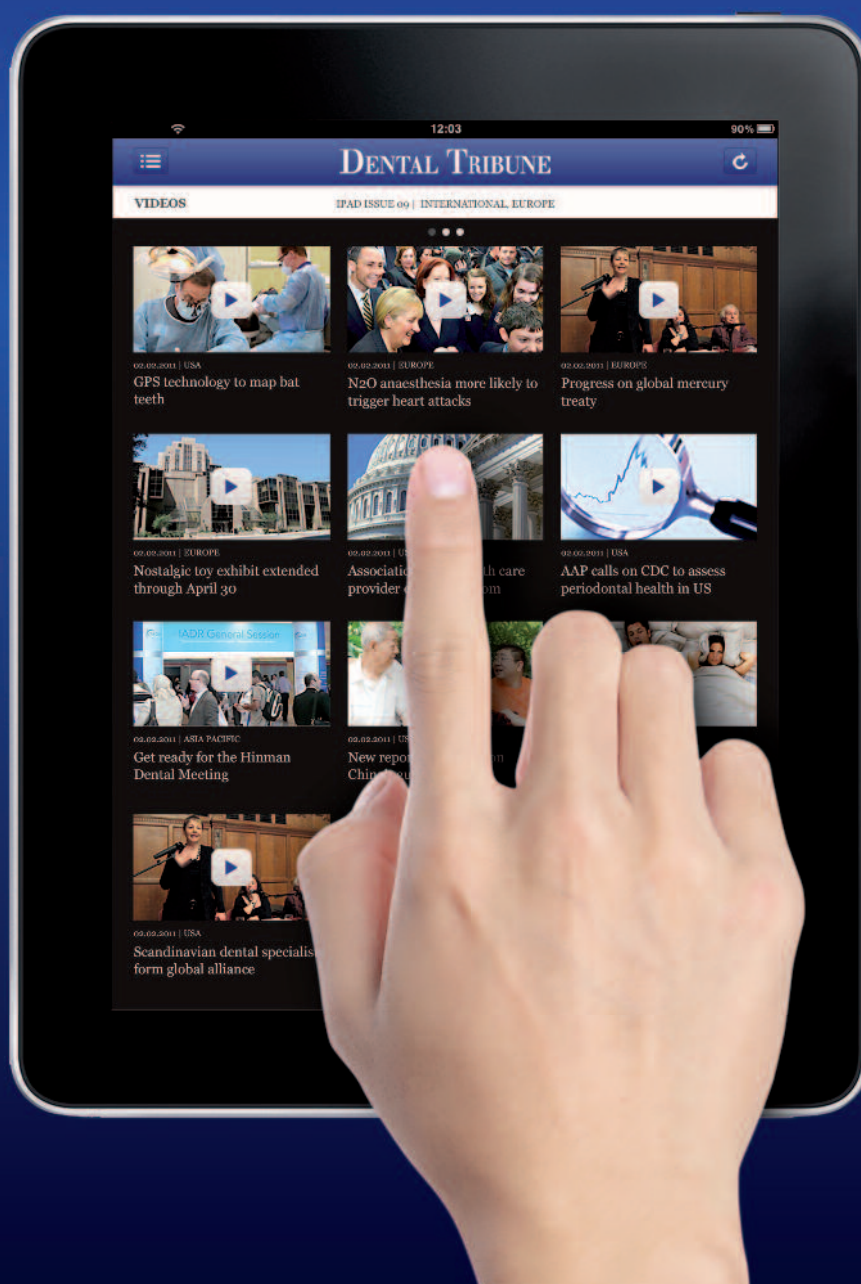

page 36

Dental Tribune for iPad – Your weekly news selection

Our editors select the best articles and videos from around the world for you every week. Create your personal edition in your preferred language.

ipad.dental-tribune.com



Large periapical lesion management

Decompression combined with root-canal treatment

Author_ Dr Nuria Campo, Spain

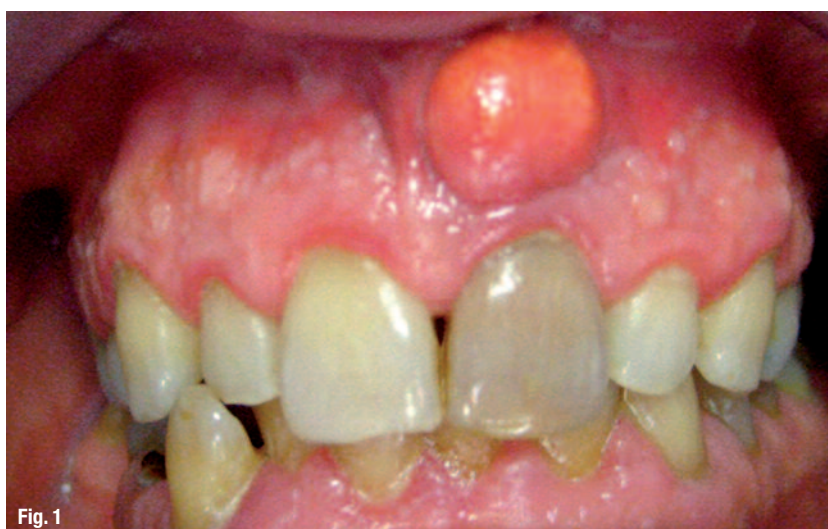

Fig. 1

Fig. 1_Buccal abscess.

Most periapical lesions occur as direct sequelae of chronic apical periodontitis, usually after pulpal necrosis of a tooth. The affected tooth is non-responsive to thermal and electrical pulp tests.

Periapical lesions often develop slowly and do not become very large. Patients do not experience pain unless there is acute inflammatory exacerbation. These lesions are often diagnosed during routine radiographic exams. Some periapical lesions become large and, in cases of large radiolucencies, they may be diagnosed in the absence of any patient complaint. Sometimes, symptoms such as mild sensitivity, swelling, tooth mobility and displacement may be observed in these cases.

Large periapical lesions are often associated with anterior maxillary teeth, probably due to traumatic injuries. These lesions could be classified as granulomas, pocket cysts (also called bay cysts) and true cysts. Granulomas are usually composed of solid soft tissue, while cysts have a semi-solid or liquefied central area usually surrounded by epithelium.¹ Pocket cysts have an epithelial lining that is connected with the root canal, and true cysts are completely lined with epithelium and not connected with the root canal.²

Fig. 2a_Mesio-radial periapical radiograph.

Fig. 2b_Ortho-radial periapical radiograph.

Fig. 2c_Disto-radial periapical radiograph.

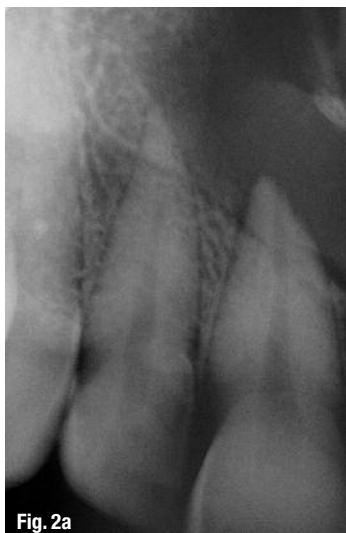

Fig. 2a

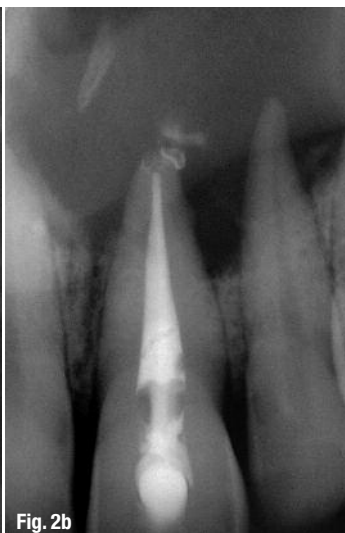

Fig. 2b

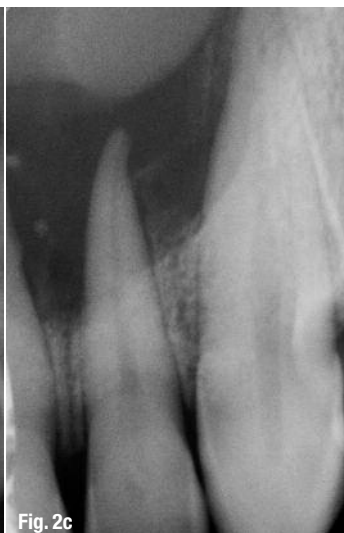

Fig. 2c

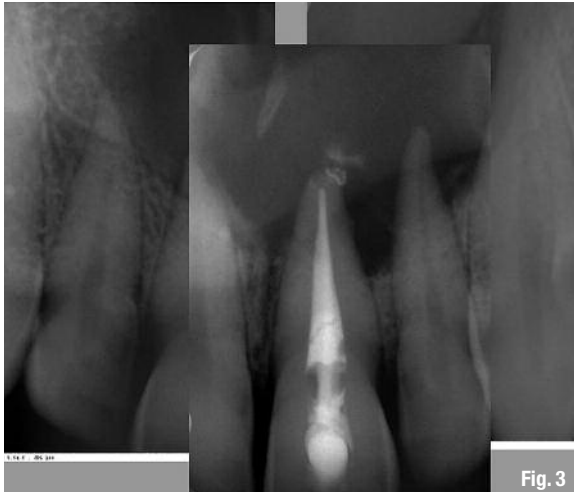


Fig. 3

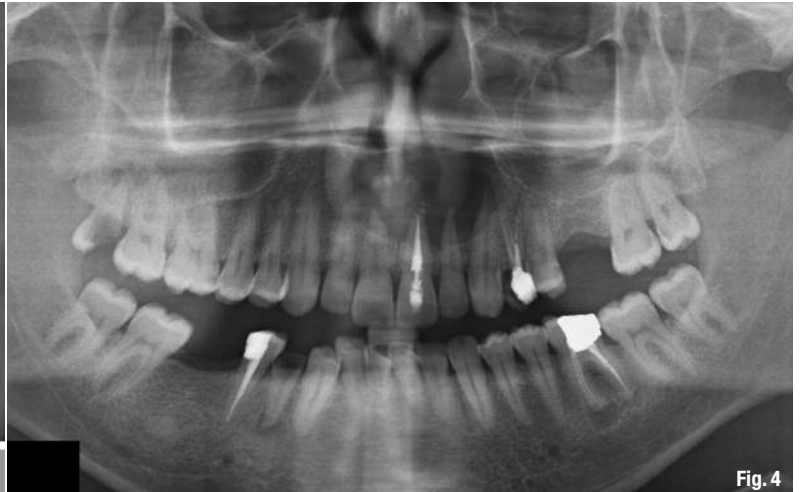

Fig. 4

According to Nair's³ research, based on serial sectioning and strict histopathological criteria, the prevalence of pocket cysts to be 6%, whereas that of true cysts is 9%. Previous studies without serial sectioning that reported ranges from 6 to 55% are proven to contain a great margin of error.

The differential diagnosis of large periapical lesions is still a controversial topic. Periapical radiographs, contrast media, Papanicolaou smears and albumin tests have proven to be inaccurate in establishing a preoperative diagnosis. Only once the post-operative biopsy has been taken, can a diagnosis be established. There is evidence¹ that CBCT scans may provide a more accurate diagnosis than biopsy.

To obtain an accurate reading, the entire lucency must be scanned for the most lucent or least dense areas. If the least dense area of the CBCT scan shows positive grey-scale values identified as solid tissues, diagnosis will be consistent with granuloma. If it shows negative grey-scale values identifying a semi-solid or fluid-filled central area, diagnosis will be con-

sistent with a pocket or a true cyst. Real-time ultrasound imaging and ultrasound recently demonstrated that they are capable of establishing differential diagnosis as well.⁴

There is widespread agreement that most granulomas heal after non-surgical root-canal treatment (NSRCT), but there is no consent regarding this in the case of periapical cysts. In Nair's opinion, based on indirect clinical evidence, it appears that pocket cysts may heal after non-surgical endodontics. He asserts that a pocket cyst is sustained by the microbes within the canal system, but that a true cyst is self-sustaining and will remain after the micro-organisms have been removed from the root-canal system. The new preoperative diagnostic techniques will be helpful in the treatment decision process.

The following case report describes the management of a particularly large maxillary periapical lesion (involving four anterior teeth) by decompression with tubing, followed by NSRCT using interim long-term calcium hydroxide (Ca(OH)₂).

Fig. 3 Periapical's composition showing the full extension of the lesion.

Fig. 4 Initial panoramic radiograph.

Fig. 5 Previous root-canal filling (gutta-percha with a plastic carrier).

Fig. 6 Ca(OH)₂ root dressing.

Fig. 7 Remains of buccal encapsulated tissue.



Fig. 5

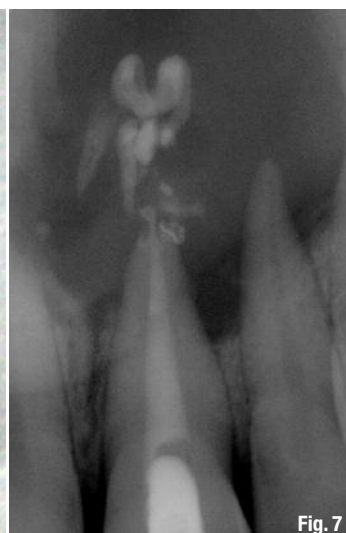

Fig. 7

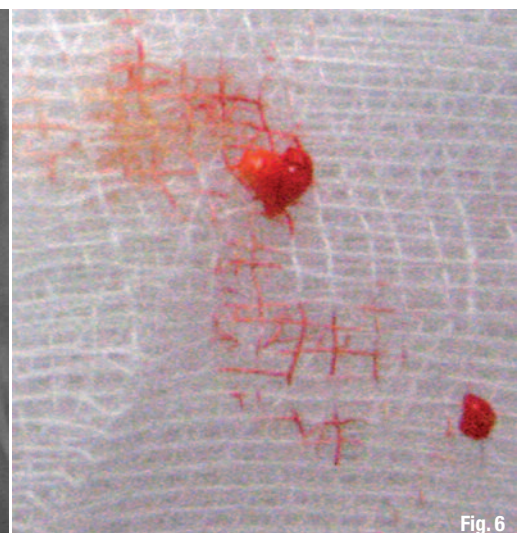

Fig. 6

_Case report




Fig. 8

Fig. 8 Modified print tip used as cannula.

A healthy 39-year-old male patient with recurrent palatal swelling and buccal abscesses was referred to our practice (Fig. 1). He had had these symptoms for the last two to three years owing to trauma sustained while working with machinery. An RCT on tooth #9 had been performed following the incident. One year later, the tooth presented with apparent brown discoloration according to the patient.

At the initial examination, tooth #9 was found to be non-vital (non-responsive to cold or electrical stimuli), and teeth #7, 8, 10 and 11 had a cold pulpal response within normal limits. Radiographs revealed a large cyst-like periapical lesion that appeared to be centred above the left upper central incisor (Figs. 2 & 3). A panoramic radiograph (Fig. 4) confirmed the full extent of the lesion, which appeared to involve the floor of the nasal sinus. The history of repeated palatal and buccal abscesses suggested a through-and-through osseous defect. The diagnosis was apical periodontitis in tooth #9.

The following treatment options were considered:

- _decompression combined with RCT; and
- _surgical removal of the lesion with RCT on tooth #9 and possibly teeth #8, 10 and even 7 and 11 owing to the great risk of damaging nervous and vascular supply during surgery.

The patient preferred the most conservative approach and treatment was performed in four appointments over five months.

_Management sequence

1. During the first visit, the previous root-canal filling (gutta-percha with a plastic carrier) was removed (Fig. 5). There was a lot of gutta-percha in the pulpal camera. This and remains of necrotic pulpal tissue could have been the cause of the brown stain-

ing of the tooth. Persistent purulent content from the canal was noted. A Ca(OH)_2 paste (Ultradent XS, Ultradent) was placed in the root canal as interim medication (Fig. 6). Once the buccal encapsulated tissue was removed (Fig. 7), copious drainage was also obtained from the buccal abscess.

2. After one month, Ca(OH)_2 was replaced because the canal could not be dried even after shaping and cleaning with copious amounts of 5.25% sodium hypochlorite. A vestibular incision was made and a plastic cannula was inserted into the lesion, obtaining purulent drainage. Thereafter, the cannula was prepared and sutured to the mucosa (Figs. 8 & 9), and the patient was instructed to irrigate through the lumen of the cannula with 3ml of 0.12% chlorhexidine on a daily basis for four weeks (Fig. 10), consistent with the protocol described by Brøndum and Jensen.⁵
3. Two months after the last visit, complete drying of the canal space was achieved but, owing to the extent of the lesion, it was decided to replace and maintain the Ca(OH)_2 for two months in order to determine whether this would effect healing as evidenced in the pattern of the lesion.
4. Two months later, healing appeared to be underway (Fig. 11a) and the canal was dry. The root-canal filling was performed with gutta-percha and AH Plus (DENTSPLY DeTrey) and composite were placed to seal the access (Fig. 11b).

The patient was recalled at eight months and was asymptomatic and there was no swelling or abscess at either the palatal or buccal surfaces. Normal pulpal responses have been maintained in teeth #7 to 11 since.

Healing of the lesion still appeared to be in progress, owing to the reduction in the size of the lesion. The trabecular pattern at the borders of the lesion had been restored (Fig. 11c) and the periodontal ligament around tooth #9 was almost fully recovered (Fig. 12). We plan to recall this patient on a yearly basis until the lesion is fully healed.

Fig. 9 Sutured plastic cannula.

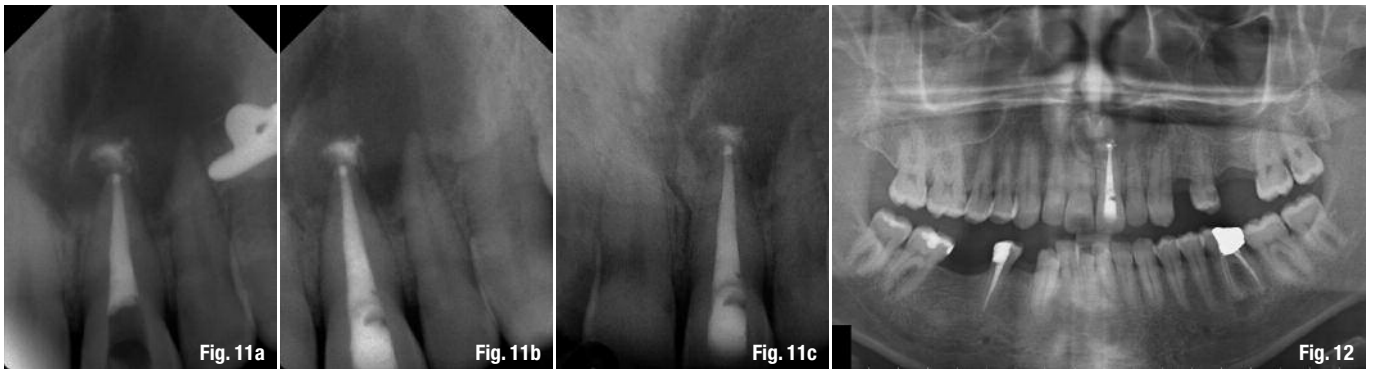
Fig. 10 Flat-tipped needle with Luer-Lok syringe for irrigation.

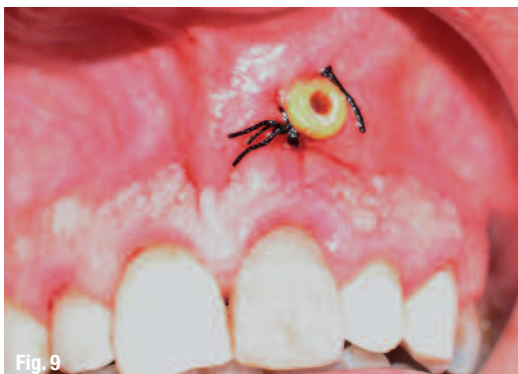

Fig. 9



Fig. 10



Discussion

The management of large periapical lesions is the subject of prolonged debate. The treatment options range from RCT or NSRCT with long-term $\text{Ca}(\text{OH})_2$ therapy to various surgical interventions, including marsupialisation, decompression with a tube and surgical removal of the lesion. These treatment options can also be combined.

Long-term drainage is important in the conservative management of these large lesions. One method is to drain through the canal on a daily basis until the canal becomes dry. This could last for between 15 days and one month. At each visit, debridement, drying and closing of the access cavity are mandatory. Another method of drainage is decompression with a tube from the apical focus. There is no standard protocol for the length of time for which the tube should be left in. Some clinical cases, however, have reported five-week to 14-month-periods, with periodical reshaping if necessary.

The literature offers evidence that the majority of these cyst-like lesions heal after conventional RCT over multiple appointments. Çaliskan⁶ reported 74% complete healing and 9.5% incomplete healing in an *in vivo* study of anterior teeth with large periapical lesions ranging from 7 to 18 mm. The treatment combined long-term canal drainage with $\text{Ca}(\text{OH})_2$ dressing and non-surgical RCT. Several case reports⁷⁻⁹ have demonstrated that long-term decompression involving a tube combined with interim $\text{Ca}(\text{OH})_2$ dressing and RCT is also successful.

Decompression is favoured because fewer visits are necessary compared with root-canal drainage. Furthermore, it is much more conservative, especially in comparison with surgical removal of the lesion with the risk of damaging the nervous and vascular supply of adjacent teeth and other anatomical structures, such as the nose and maxillary sinus floor. Even if surgical removal is still necessary later, the lesion will predictably have shrunk in size by

such time and present less difficulty and less risk of damage to other teeth or vital structures.

With complete informed consent, the patient may prefer more immediate therapy and select surgical enucleation without delay in conjunction with the conventional endodontic therapy of the responsible tooth and usually the adjacent ones involved in the lesion. It is important to remember that microbes initially caused the lesion and continue to maintain the immune response and thus the apical periodontitis. The length of time required for healing in these cases ranges from eight to 14 months.⁶ Follow-up on the process of healing should be done every six months for four years.

There are also large periapical lesions of non-dental origin, such as non-dental cysts (e.g. nasopalatal cyst) and neoplastic entities. If there are doubts regarding the dental origin of the periapical lesion, the first choice of treatment is the surgical approach.

This case has illustrated the healing of a large periapical lesion with a minimally invasive approach. However, every case requires an individual approach depending on the patient's cooperation, preferences, availability and proximity to the surgery, as well as the dentist's professional training and technical skills.

Editorial note: A complete list of references is available from the publisher.

_about the author

roots

Dr Nuria Campo received her degree from the University of Barcelona in 1997. She is a self-trained endodontist. Dr Campo co-organised the Roots Summit IX in Barcelona.

ncampob@gmail.com
www.microendodencia.wordpress.com
es-es.facebook.com/microendodencia

Fig. 11a After five months of interim medication, healing appeared to be underway.

Fig. 11b Root-canal filling and coronal sealing.

Fig. 11c Eight-month recall periapical radiograph.

Fig. 12 Eight-month recall panoramic radiograph.