

roots

the international C.E. magazine of endodontics

1 2014

_C.E. article

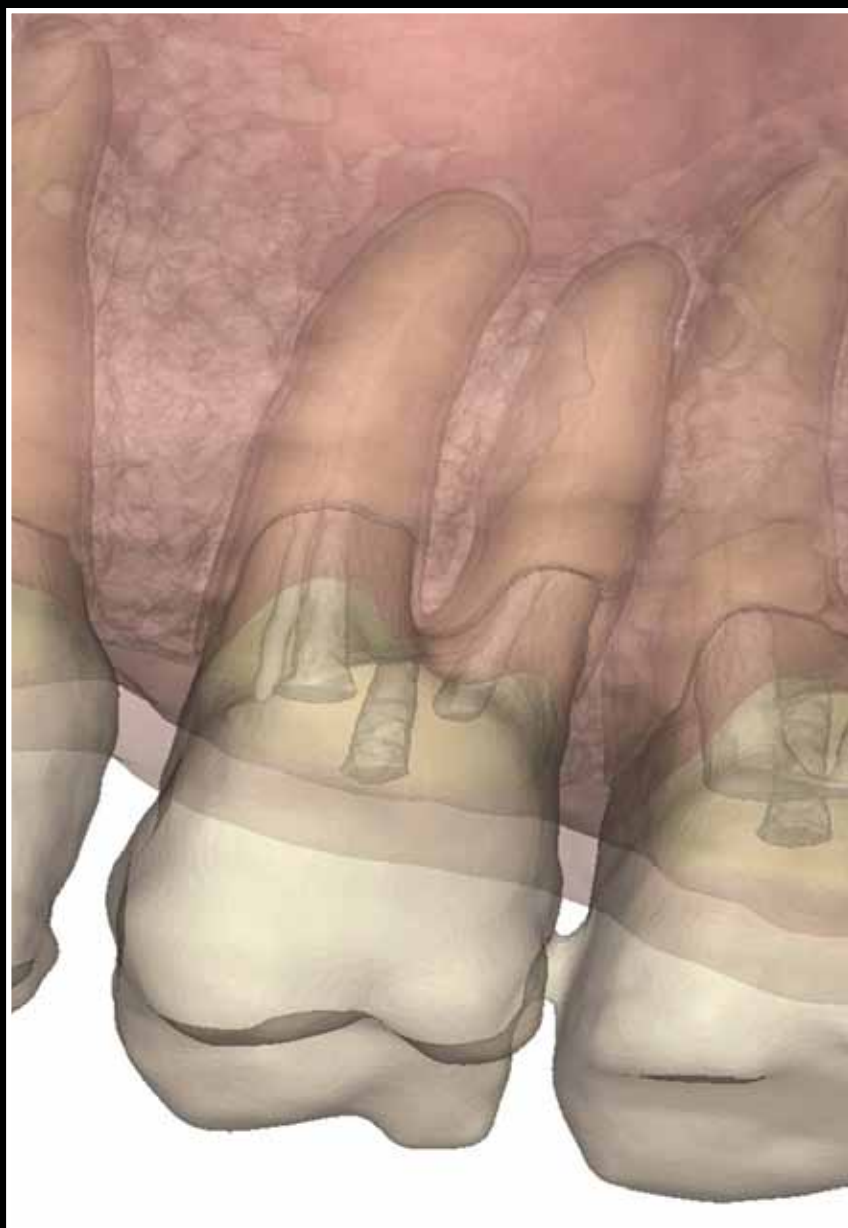
Passive micro-volume management of sodium hypochlorite in endodontic treatment

_education

A new paradigm in surgical training

_industry

Endodontics made more efficient with the ScanX Swift





CanalPro™

Endodontic Irrigation System

More efficacious solutions

CanalPro NaOCl EXTRA

- 2x wetter: Proprietary surface modifiers enable penetration into hard-to-reach areas
- 2x more digestive than regular Sodium Hypochlorite cuts tissue dissolution time in half

Innovative delivery

Color-coded for safety and convenience

SEE US AT:

CDS Booth #3600 | AAE Annual Session

Call **1.800.221.3046**
to get a **FREE** Sample.

While supplies last.

COLTENE® ENDO

The Brands You Trust

Call Us: 800.221.3046 | Fax: 330.916.7077 | coltene.com



Alpen
RODNEY INSTRUMENTS

BioSonic

COMPONEER

HYGENIC

SPEC

HyFlex

ParaPost

CanalPro

SYNERGY

AFFINIS

Expanding our horizons



Fred Weinstein, DMD, MRCD(C),
FICD, FACD

How is your new year shaping up so far? If you are like me, you have been traveling to some of the major dental industry meetings, including the Yankee Dental Congress in Boston and the Midwinter Meeting in Chicago. Perhaps you picked up this copy of *roots* at one of these meetings.

This issue contains some interesting articles, including a study by Dr. Les Kalman on the use of sodium hypochlorite in endodontic irrigation and a report by Dr. L. Stephen Buchanan on some new technology that enhances the educational experience for those who are learning about endodontic surgery. You can also read about tools that Dr. Howard Golan uses to make digital imaging in his practice more efficient.

Every issue of *roots* also contains a C.E. component. By reading the article by Dr. Kalman, then taking a short online quiz about this article at www.DTStudyClub.com, you will gain one ADA CERP-certified C.E. credit. Keep in mind that because *roots* is a quarterly magazine, you can actually chisel four C.E. credits per year out of your already busy life without the lost revenue and time away from your practice.

To learn more about how you can take advantage of this C.E. opportunity, visit www.DTStudyClub.com. You need only register at the Dental Tribune Study Club website to access these C.E. materials free of charge. You may take the C.E. quiz after registering on the DT Study Club website.

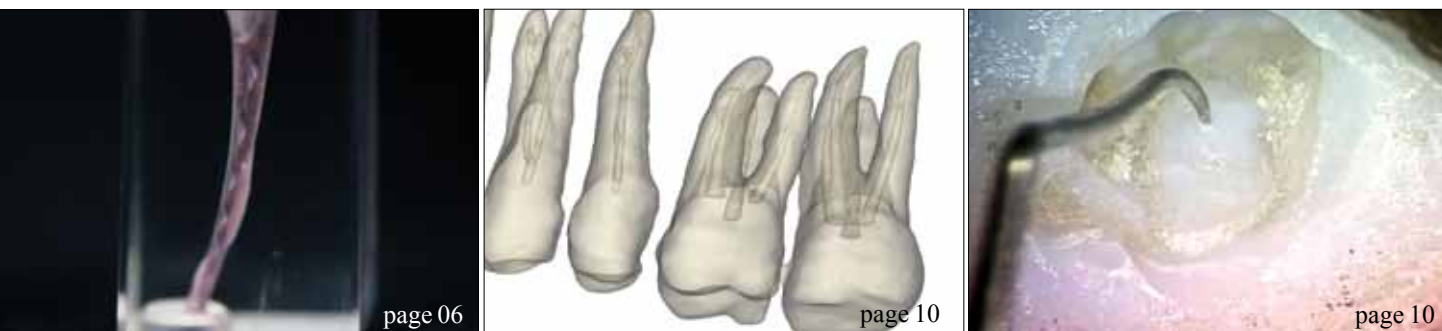
I know that taking time away from your practice to pursue C.E. credits is costly in terms of lost revenue and time, and that is another reason *roots* is such a valuable publication. I hope you will enjoy this issue and that you will take advantage of the C.E. opportunity.

For those of you attending the late winter and spring meetings in Chicago, Atlanta and other places, be sure to say hello to me in person. As always, I welcome your comments and feedback.

Sincerely,

A handwritten signature in grey ink that reads "Fred".

Fred Weinstein, DMD, MRCD(C), FICD, FACD
Editor in Chief



| C.E. article

- 06 Passive micro-volume management of **sodium hypochlorite** in endodontic treatment
_Les Kalman, B.Sc (Hon), DDS

| education

- 10 A **new paradigm** in surgical training
_L Stephen Buchanan, DDS, FICD, FACD

| industry

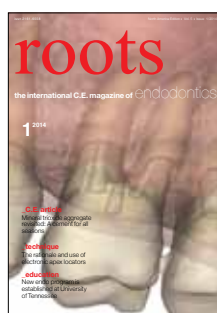- 15 Endodontics made more efficient with the **ScanX Swift**
_Howard Golan, DDS
- 18 **X-Runner** all-tissue ablative laser scanning handpiece

| industry education

- 20 Three-day course is designed for doctors and their teams to learn together

| about the publisher

- 21 _submissions
22 _imprint



| on the cover

A fully segmented CT volume in preparation for 3-D printing. (Image/Provided by L. Stephen Buchanan, DDS, FICD, FACD)



Lasers **4** Dentistry

Technology **4** Medicine

LIGHTWALKER ATS™

A CLASS OF ITS OWN, NOTHING COMPARES!

The PIPS Endo, WPT Perio, Hard & Soft Tissue Laser

Erbium & Nd:YAG LASER Dual Wave Length

20 Watt Er:YAG Hard & Soft Tissue = **Ultra Fast** Cutting

15 Watt Nd:YAG = Proven Perio Wavelength

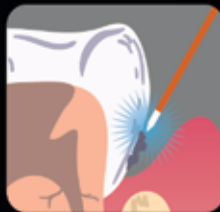
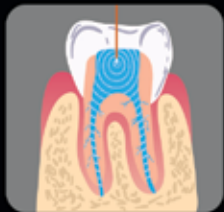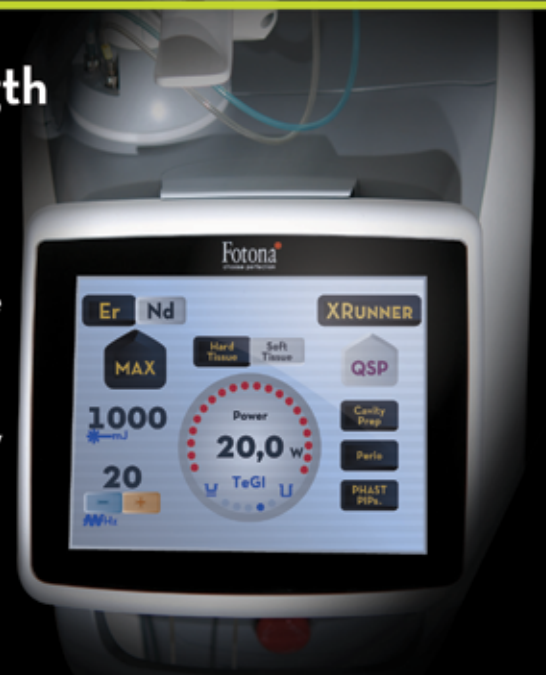QSP & VSP Technology = Faster, More Precise & Comfortable

50µs Er:YAG Pulse Duration = Fewer Shots & Less Anesthesia

OPTOflex Delivery System = Enhanced Efficiency & Reliability

PHAST PIPS = Fast, Effective Laser Endo

Dual Wavelength = Advanced Laser Perio



**Superior
Predictable
Consistent**

"First week using my new Lightwalker ATS laser. This is the 4th hard tissue laser in my practice over the last 12 years that included 2 Waterlase systems and also using the Lightwalker DT since July 2011. The new ATS is by far superior! The QSP pulse mode allows me to ablate enamel on par with my highspeed handpiece (1st time ever!!) and I have yet to use any anesthetic this week on any laser patient. Class 1, 2, 3, 4, and 5's!! In addition, the new green aiming beams lights up the target creating a great contrast to the colors of natural tissue. I foresee a paradigm shift in my laser practice!!"

-Rick Cardoza, DDS, El Cajon, CA

For an in-office presentation, call 949.276.6650 T4MED.com

Passive micro-volume management of sodium hypochlorite in endodontic treatment

Author_Les Kalman, B.Sc (Hon), DDS

_c.e. credit

This article qualifies for C.E. credit. To take the C.E. quiz, log on to www.dtstudiesclub.com. Click on 'C.E. articles' and search for this edition (Roots C.E. Magazine — 1/2014). If you are not registered with the site, you will be asked to do so before taking the quiz. You may also access the quiz by using the QR code below.



_Abstract

The passive utilization and micro-volume management of sodium hypochlorite as an endodontic irrigant has been illustrated with a laboratory demonstration and several clinical cases. By limiting the volume and pressure of sodium hypochlorite, the injurious effects can be minimized while still benefiting from the ideal disinfecting characteristics. Further studies are required to understand the behavior of fluids, especially sodium hypochlorite, within the context of permeability, fluid mechanics and multiphase fluid flow through porous media.

_Introduction

Endodontic treatment addresses the re-

moval of the tooth's internal pulp and micro-organisms,¹ primarily due to infection and necrosis. Once proper diagnosis and prognosis has been established, the patient has the option of maintaining the tooth's form and function while the vitality becomes lost. Current endodontic treatment consists of utilizing rotary files to remove the pulpal tissue and shape the internal dentin chamber of the tooth. Chemicals, in the form of gels and liquids, are then implemented to disinfect the canal(s) and eliminate bacteria.² The chemicals are then dried and the canal space filled with either gutta-percha or resin to create a hermetic seal.

The chemicals employed to clean and disinfect the intracanal space are vast and include file lubricants such as Prolube (DENTSPLY) and irrigants such as

Fig. 1_DENTSPLY Vortex rotary file with sodium hypochlorite.
(Photos/Provided by Les Kalman, B.Sc (Hon), DDS)



Fig. 1

Fig. 2_DENTSPLY Profile rotary file with dyed sodium hypochlorite.



Fig. 2

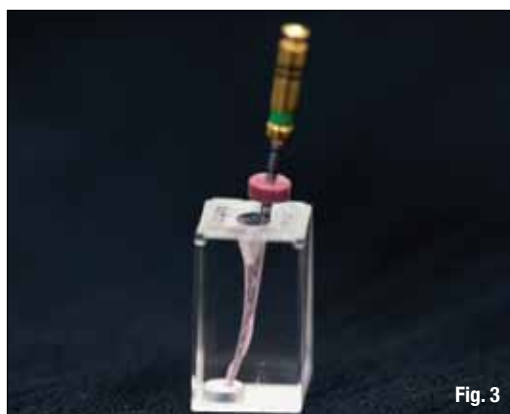

Fig. 3



Fig. 4

Fig. 3_Micro-volume delivery of sodium hypochlorite with rotary file.

Fig. 4_Sodium hypochlorite in block with rotary file.

QMix (DENTSPLY). During clinical endodontics, the canal is filled with a cocktail of chemicals, as file lubricants and irrigants become a mixture.

Chlorhexidine gluconate (CHX) is an uncommonly used irrigant³ with several desirable properties. It provides antimicrobial activity against certain aerobic and anaerobic bacteria, exhibits no significant changes in bacterial resistance in the oral microbial environment and has no injurious effect to the skin or mucosa.⁴ In fact, CHX has a role as an oral rinse at the 0.12 percent concentration.⁴

Sodium hypochlorite (NaOCl) still remains the most commonly used chemical,^{2,3} because of its availability, cost and effectiveness.^{2,5} Sodium hypochlorite is effective against broad-spectrum bacteria and has the ability to dissolve both vital and necrotic tissue.⁶ However, this irrigant is equally damaging to the patient and has a history of injurious effects.⁵ Typically the NaOCl is delivered into the canal space with a syringe dose of 2–10 ml that is expelled under pressure. The ability of NaOCl to escape either through poorly sealed isolation or other means can cause serious injury to the patient.⁵

Injury from NaOCl is well established in the literature^{3,5,6} and has been attributed to three main errors: poor handling, injection beyond the apical foramen and allergy.⁶ Poor handling injury can result in operator and/or patient injury to the eye and/or skin.⁶ Injection beyond the apical foramen can result in the following:⁶

- immediate and severe pain
- edema to adjacent tissue
- edema to the lip, infraorbital region and side of face
- intense bleeding from within the canal space
- skin and mucosa bleeding
- intestinal bleeding
- paraesthesia
- secondary infection.

Allergy from NaOCl is rare but has been reported and may result in severe pain, a burning sensation, edema and transient paraesthesia.⁶

Methodology

Although there is no universally accepted irrigation protocol regarding endodontic treatment,³ it is the duty of clinicians to apply evidence-based dentistry within clinical parameters to provide their patients with the highest standard of care with minimal morbidity. The use of NaOCl has numerous beneficial factors that maximize treatment success; however, it is the application of the liquid that can cause injury.

Micro-volume management of NaOCl has been proposed. The concept is based on the premise that endodontic instruments have irregular surfaces, crucial for dentinal preparation, and that liquids exhibit surface tension characteristics.⁷ By placing an instrument into a suitable container, the NaOCl will be carried within the surface texture of the instrument (Figs. 1, 2). As the operator inserts the instrument into the canal (Fig. 3), the NaOCl is carried with it. Upon instrument movement, the NaOCl is released into the canal space (Fig. 4). Surface tension and permeability of porous media (dentin) will also increase the ability of the liquid to percolate into the canal.⁷ This approach is radically different than current philosophies, as the NaOCl is introduced into the canal space in a micro-volume amount without any pressure. The operator has control of the minimized liquid while benefitting from its effectiveness.

The micro-volume management of sodium hypochlorite has been applied to numerous clinical cases. Post-operative obturation radiographs of completed clinical cases have been presented (Figs. 5–9).

Discussion

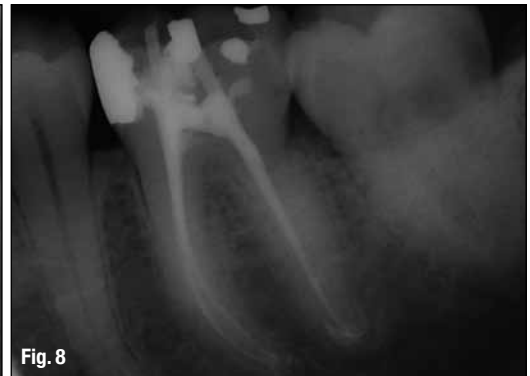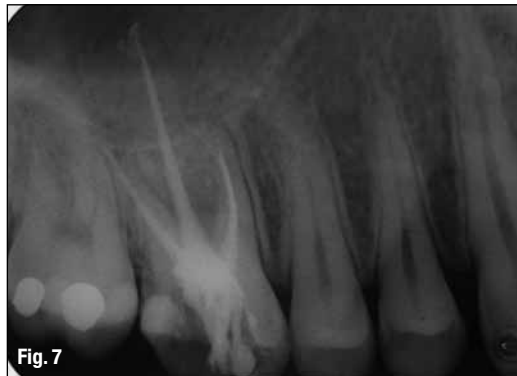
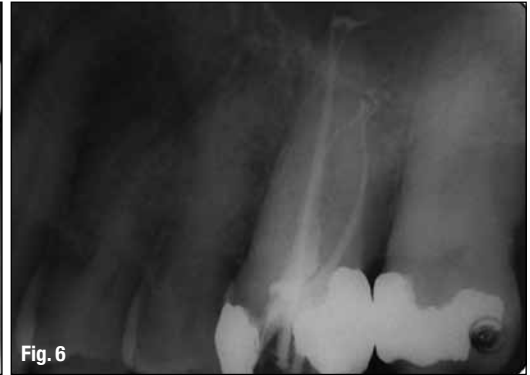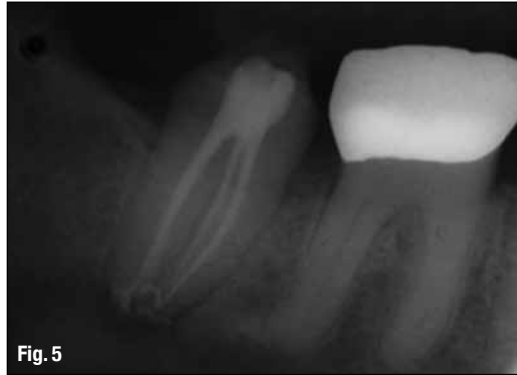The canal system inside a tooth is very complex. Although there is the presence of one or more canals, there also exist numerous micro tunnels, ribbons and sheets throughout the canal network.⁸ The canals are also housed within a porous

Fig. 5_Radiograph of endodontic treatment on #47.

Fig. 6_Radiograph of endodontic treatment on #26.

Fig. 7_Radiograph of endodontic treatment on #16.

Fig. 8_Radiograph of endodontic treatment on #36.



dentinal structure, for which the permeability has been distinguished.⁹ Although the elimination of the pulp is a relatively predictable clinical procedure, the introduction of liquids into this complex micro-network porous development further complicates matters. If the clinician introduces liquids, then the successful removal of those liquids is key to clinical success. Concepts of multiphase fluid flow through porous media, and capillaries,¹⁰ permeability of porous media¹¹ and surface tension fluid mechanics⁷ must be recognized to validate and further advance canal irrigation.

Micro-volume management of NaOCl has been suggested as a delivery modality to maximize its bactericidal effects yet minimize its injurious effects. Surface tension fluid mechanics and permeability^{7,10,11} suggest that the NaOCl can be carried within the surface irregularities of endodontic in-

strumentation and deposited into the canal space and percolate within the complex network of the canal. The passive management of the irrigant in micro-volume would greatly reduce complications due to poor handling. CHX has been suggested as the larger volume, positive pressure irrigant that may be delivered into the canal space. CHX has favorable antibacterial characteristics but minimal injurious effects, if mismanagement of the irrigant has occurred. If positive pressure delivery of CHX is required, the operator should regulate the pressure and avoid the risk of injection beyond the apex. The use of EDTA (ethylenediaminetetraacetic acid) could be employed after NaOCl, to minimize the formation of precipitates.²

The application of micro-volume management of NaOCl suggests that the canal space can be effectively cleaned in a conservative manner. Application

‘NaOCl has several advantages for its role as an endodontic irrigant, but its use must be exercised with caution in order to prevent injury.’

of this principle has been applied to clinical cases with little to no post-endodontic sensitivity. Obturation has been completed with ThermoSeal and ThermoFil (DENTSPLY). Even though there is evidence of sealer extrusion, the absence of post-operative symptoms and pathology suggests adequate volume for sufficient disinfection.

Further laboratory studies are required to understand permeability, fluid mechanics and multiphase fluid flow through porous media and their relation to the micro-management of NaOCl. Additional clinical investigations should be implemented to assess and validate the efficiency and efficacy of micro-volume management of sodium hypochlorite on endodontic therapy.

Conclusions

Introduction of lubricants and irrigants into the canal complex is crucial for endodontic success. The action of fluids in the canal complex must be understood within the context of permeability, fluid mechanics and multiphase fluid flow through porous media.

NaOCl has several advantages for its role as an endodontic irrigant, but its use must be exercised with caution in order to prevent injury. Application of NaOCl as a passive, micro-volume liquid has been illustrated.

Further consideration is required to validate the theory. The potential to minimize morbidity while maximizing clinical endodontic success seems promising for both clinician and patient.

References

1. Dang E. Comparison of sodium hypochlorite and chlorhexidine gluconate: quality of current evidence. *The Journal of Young Investigators: An Undergraduate, Peer-Reviewed Science Journal* 2008;23(1):1–9.
2. Basrani BR, Manek S, Rana SNS, Fillery E. and Manzur A. Interaction between sodium hypochlorite and chlorhexidine gluconate. *J Endod* 2007;33: 966–969.
3. Dutner J, Mines P, and Anderson A. Irrigation trends among American Association of Endodontists members: a web-based survey. *J Endod* 2011;:- 1–4.
4. 3M ESPE: Peridex™ Chlorhexidine Gluconate (0.12%) Oral Rinse Fact Sheet: 2009.
5. Clarkson RM, and Moule AJ. Sodium hypochlorite and its use as an endodontic irrigant. *Australian Dental Journal* 1998;43(4).
6. Hülsmann H. & Hahn W. Complications during root canal irrigation-literature review and case reports. *International Endodontic Journal*: 2000;33:186–193.
7. Trefethen L. Surface tension in fluid mechanics. *Encyclopaedia Britannica*. (12ed.) Wiley:Chicago, 1969;1–7.

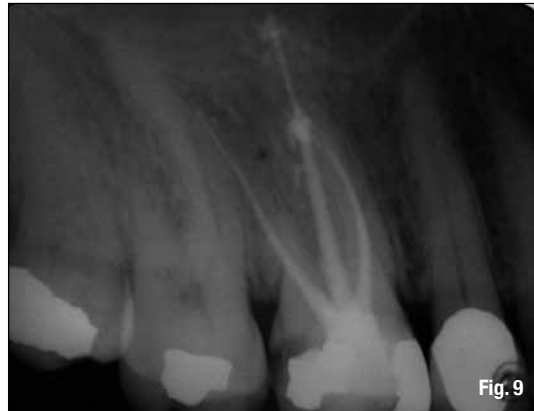

Fig. 9 Radiograph of endodontic treatment on #16.

8. West JD, Roane JB and Goering AC. Cleaning & shaping of the root canal system. In Cohen S. and Burns RC. *Pathways of the Pulp*. (6th ed.) Mosby:St. Louis, 1994;179–218.
9. Trowbridge HO. and Kim S. Pulp development, structure & function. In Cohen S. and Burns RC. *Pathways of the Pulp*. (6th ed.) Mosby:St. Louis, 1994;296–336.
10. Templeton CC. and Rushing SS. Jr. Oil-water displacements in microscopic capillaries. *Journal of Petroleum Technology*. 1956;8(9):211–214.
11. Crotti MA. Motion of Fluids in Oil and Gas Reservoirs. Mosby:New York, 1978;8–14.

about the author

roots

Les Kalman, B.Sc (Hon), DDS, graduated from the University of Western Ontario with a doctor of dental surgery degree in 1999. He then completed a GPR at the London Health Sciences Centre. He has been involved in general dentistry within private practice since 2000. He has served as the chief of dentistry at the Strathroy-Middlesex General hospital. In 2011, he transitioned to full-time academics as an assistant professor at the Schulich School of Medicine and Dentistry. Kalman's research focuses on clinical innovations, including the Virtual Facebow app. Kalman is also the director of the Dental Outreach Community Services (DOCS) program, which provides free dentistry within the community. Kalman has authored articles ranging from pediatric impression to immediate implant surgery in both Canadian and American journals. He has been a product evaluator for several companies, including GC America and Clinician's Choice. Kalman is the co-owner of Research Driven, a company that deals with intellectual property development. Kalman is a member of the American Society for Forensic Odontology, International Team for Implantology, Academy of Osseointegration, American Academy of Implant Dentistry and the International Congress of Oral Implantology. He has been recognized as an academic associate fellow (AAID) and diplomate (ICOI). He can be contacted at lkalman@uwo.ca.

