

# roots



the international C.E. magazine of endodontics

1 2013

## **C.E. article**

Endodontic retreatment and adhesive restoration of structurally compromised second premolar

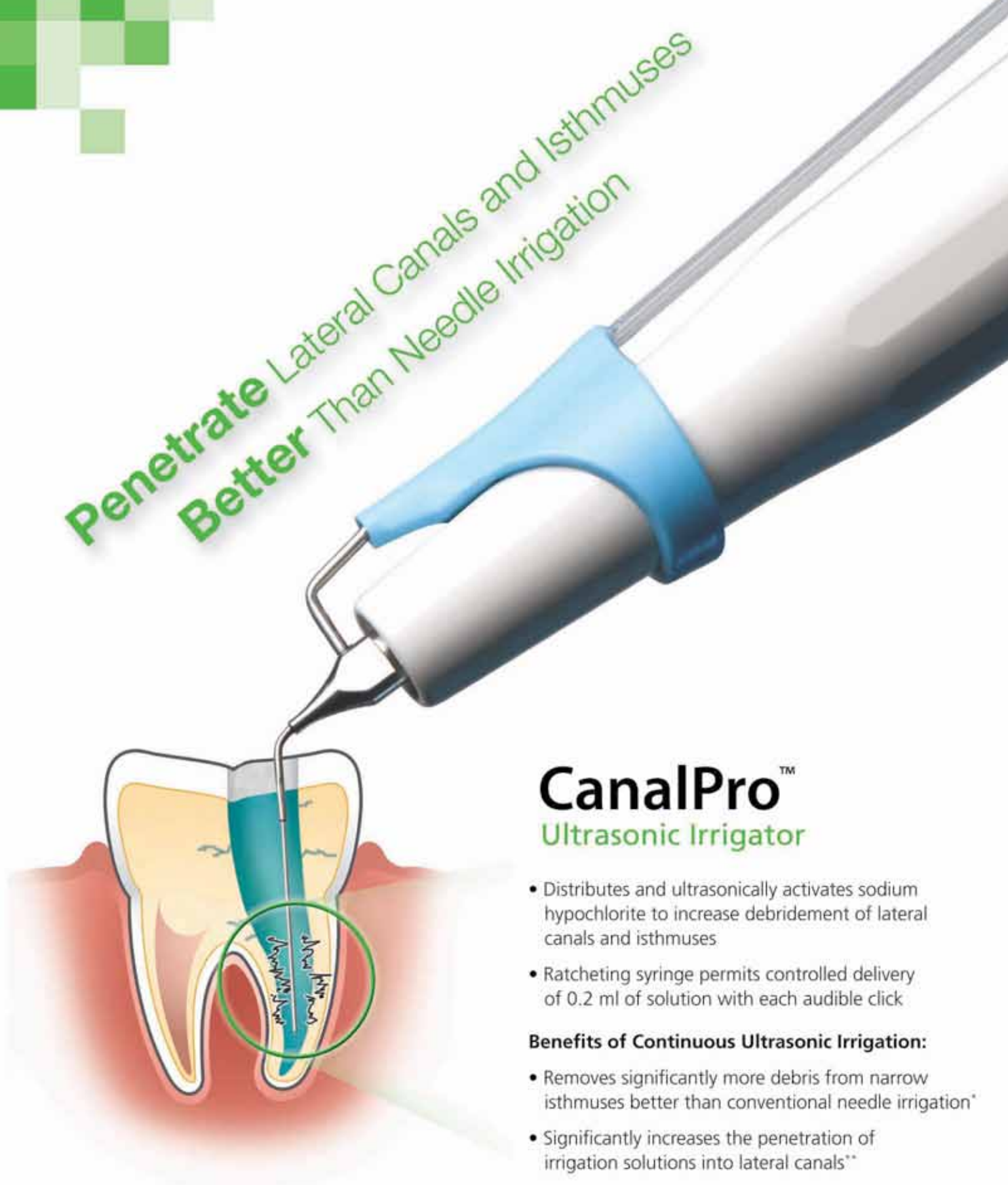
## **events**

Greater N.Y. Dental Meeting offers lots of resources for endodontists

## **events**

AAE brings annual meeting to Hawaii

Penetrate Lateral Canals and Isthmuses  
Better Than Needle Irrigation



## CanalPro™ Ultrasonic Irrigator

- Distributes and ultrasonically activates sodium hypochlorite to increase debridement of lateral canals and isthmuses
- Ratcheting syringe permits controlled delivery of 0.2 ml of solution with each audible click

### Benefits of Continuous Ultrasonic Irrigation:

- Removes significantly more debris from narrow isthmuses better than conventional needle irrigation\*
- Significantly increases the penetration of irrigation solutions into lateral canals\*\*

\*Adcock et al, J.Endod. 2011; 37 (4) \*\*Castelo-Baz et al, J. Endod. 2012; 38 (5)

**COLTENE® ENDO**

235 Ascot Parkway | Cuyahoga Falls, OH 44223  
Tel. USA & Canada 800.221.3046 | 330.916.8800 | coltene.com

**See us at AAE booth # 711**

PATENT PENDING

# There is always more to learn



Fred Weinstein, DMD, MRCD(C),  
FICD, FACD

I always enjoy myself at dental meetings. It sure is great to connect with compatriots, and there is undoubtedly something different to experience, a novel approach or technique to explore, or new technology to learn about. There is also plenty of printed material available to take home. Perhaps you picked up this very magazine at a dental meeting and are reading it on the plane or train trip home.

Welcome.

For this issue of *roots*, you can read a report on an endodontic retreatment and adhesive restoration of a structurally compromised second premolar by Dr. Stela Nicheva, Dr. Lyubomir St. Vangelov and Dr. Ivan Filipov of Bulgaria. And speaking of meetings, Managing Editor Fred Michmershuizen has written a report on the many offerings for endodontists that were available at the recent Greater New York Dental Meeting.

You can also read a preview of the American Association of Endodontists Annual Session, which is planned for April 17-20 in Honolulu.

But there's even more.

Every issue of *roots* magazine also contains a C.E. component. By reading the article on endodontic retreatment and adhesive restoration, then taking a short online quiz about this article at [www.DTStudyClub.com](http://www.DTStudyClub.com), you will gain one ADA CERP-certified C.E. credit. Keep in mind that since *roots* is a quarterly magazine, you can actually chisel four C.E. credits per year out of your already busy life without the lost revenue and time away from your practice.

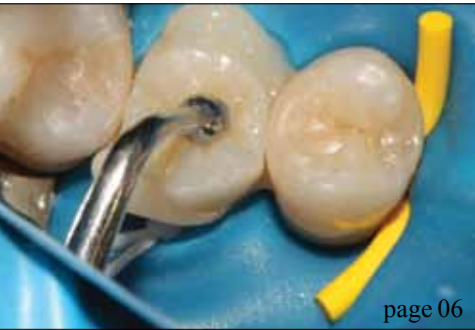To learn more about how you can take advantage of this C.E. opportunity, visit [www.DTStudyClub.com](http://www.DTStudyClub.com). Annual subscribers to the magazine (\$50) need only register at the Dental Tribune Study Club website to access these C.E. materials free of charge. Non-subscribers may take the C.E. quiz after registering on the DT Study Club website and paying a nominal fee.

I know that taking time away from your practice to pursue C.E. credits is costly in terms of lost revenue and time, and that is another reason *roots* is such a valuable publication.

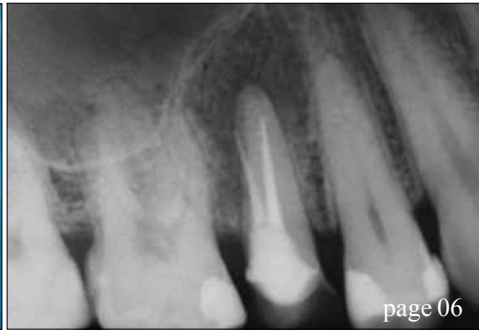For those of you who will be attending the upcoming AAE meeting in Hawaii, I will see you there. Meanwhile, I hope you will enjoy this issue of *roots* and that you will take advantage of the C.E. opportunity.

Sincerely,

Fred Weinstein, DMD, MRCD(C), FICD, FACD  
Editor in Chief



page 06



page 06



page 13

### | C.E. article

- 06 Endodontic **retreatment and adhesive restoration** of structurally compromised second premolar  
\_Stela Nicheva, DMD; Lyubomir St. Vangelov DMD; and Ivan Filipov, DMD, PhD

### | about the publisher

- 21 \_submissions
- 22 \_imprint

### | events

- 13 **Greater N.Y. Dental Meeting** offers lots of resources for endodontists  
\_Fred Michmershuizen, Managing Editor
- 16 **AAE** brings its annual meeting to Hawaii

### | industry

- 18 COLTENE ENDO launches **CanalPro Ultrasonic Irrigator**
- 20 Wykle Research expands its **Calasept Endo** line

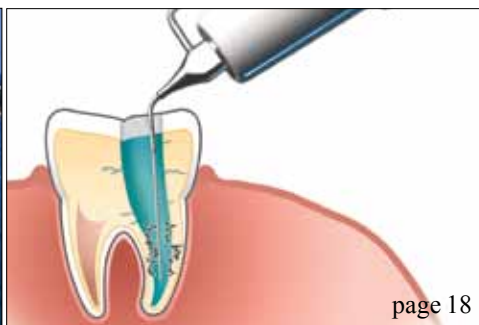

### | on the cover

*Image courtesy of Barry Lee Musikant, DMD, FICD*



page 16



page 18



page 20


# LASER ENDODONTICS WITH WATERLASE

It's a little-known fact, but WaterLase YSGG dental laser technology is ideal for root canal therapy. Studies show effective lateral penetration into canal walls, removal of smear layer, and wide-open dentinal tubules after treatment – WaterLase technology can elevate your endodontic treatment!

## waterlase *iPlus*™

WaterLase iPlus Laser System available starting at \$17,500

- + Addresses E.faecalis present in the canal system
- + Patented 'Radial Firing Tip' effective on smear layer removal
- + Studies show open dentinal tubules and lateral penetration of laser energy up to 1,000 microns
- + Minimizes the risk of cross contamination in the dental clinic
- + The leading all tissue laser system worldwide



The smear layer remaining after rotary or hand instrumentation not only contains infected tissue, but can seal infection within dentinal tubules. Scanning Electron Microscopy shows how treatment with WaterLase Radial Firing Tips can leave canal walls free of smear layer, allowing YSGG laser energy to penetrate and weak toxic bacteria.



**VISIT [BIOLASE.COM/ENDO](http://BIOLASE.COM/ENDO)**

**OR CALL 888.424.6527 TO LEARN MORE ABOUT THE  
ENDODONTIC APPLICATIONS OF WATERLASE**

FOLLOW US:

[f](#) [t](#) [in](#) [v](#) [p](#) [g](#) | [www.biolase.com](http://www.biolase.com) | 888.424.6527

**BIOLASE™**

# Endodontic **retreatment** and **adhesive restoration** of structurally compromised second premolar

**Authors**\_Stela Nicheva, DMD; Lyubomir St. Vangelov, DMD; and Ivan Filipov, DMD, PhD

## \_c.e. credit

This article qualifies for C.E. credit. To take the C.E. quiz, log on to [www.dtstudyclub.com](http://www.dtstudyclub.com). Subscribers to the magazine can take this quiz for free and will be emailed an access code after the magazine's release. If you do not receive the code, please write to [support@dtstudyclub.com](mailto:support@dtstudyclub.com). Non-subscribers may take the quiz for \$20. You can access the quiz by using the QR code below. The quiz will be available on Feb. 18.



**\_In light of the scientific literature concerning the outcome of the endodontic treatment,** it doesn't sound inappropriate that the restoration of the endo-coronal complex has to be completed by the endodontist<sup>1</sup>. In this context the following report presents a complete rehabilitation of a second premolar, including retreatment and definitive restoration.

Teeth that need retreatment are most often grossly decayed due to caries, fracture and/or previous restoration. The endodontic retreatment in such cases is a challenge concerning the isolation, overcoming different obstructions, perforation management (if they exist) and final restoration. The success rate for teeth that exhibit one or more technical problems, such as transportation, strip-

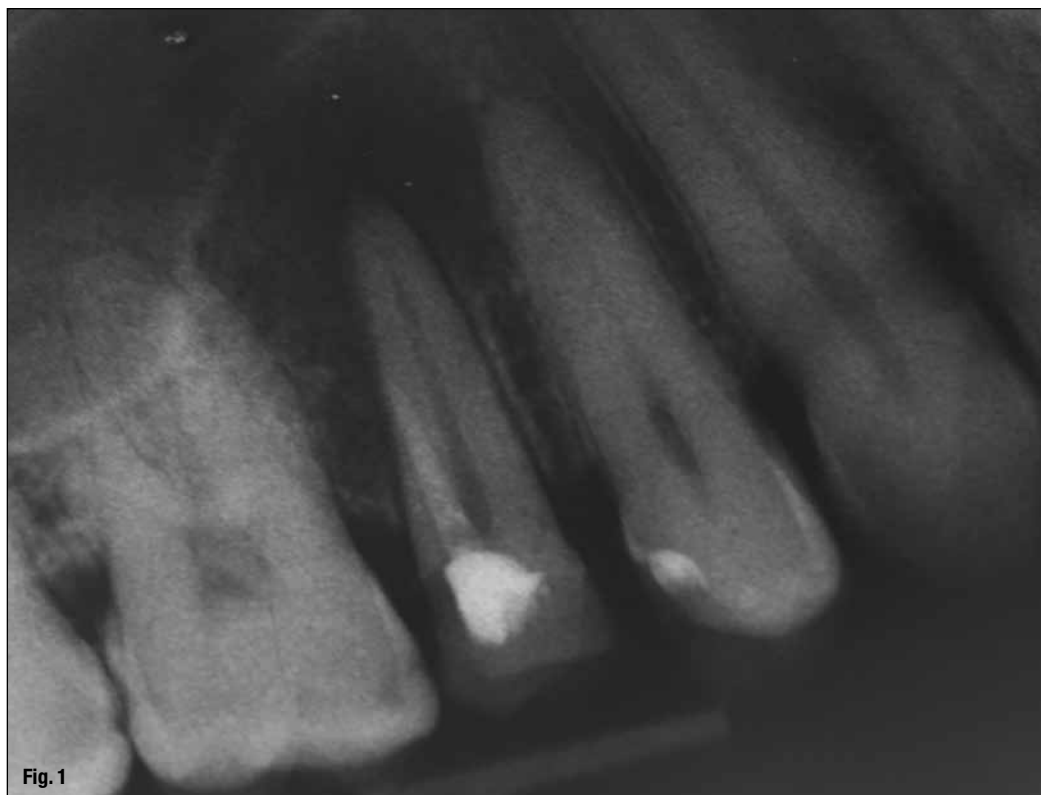


Fig. 1

(Photos/Provided by  
Dr. Stela Nicheva)

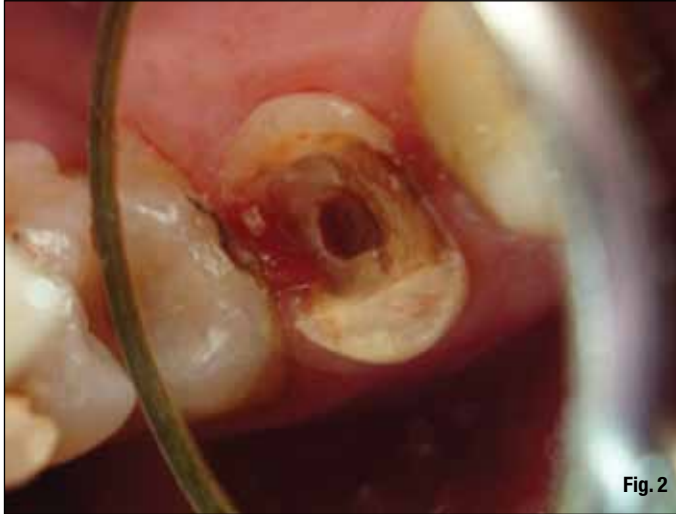

Fig. 2

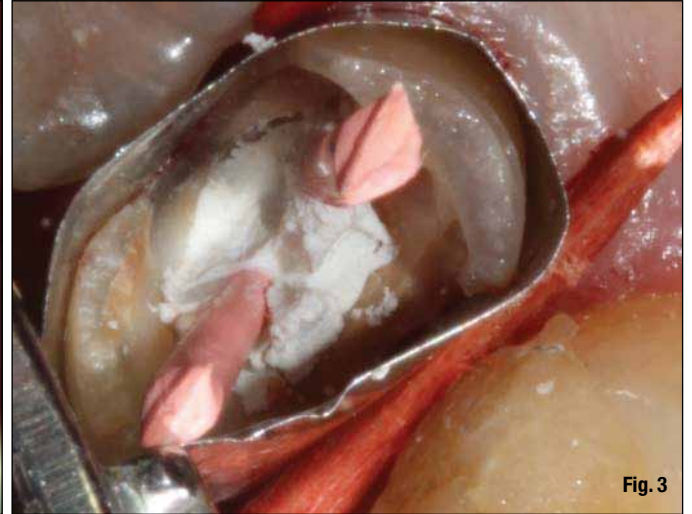


Fig. 3

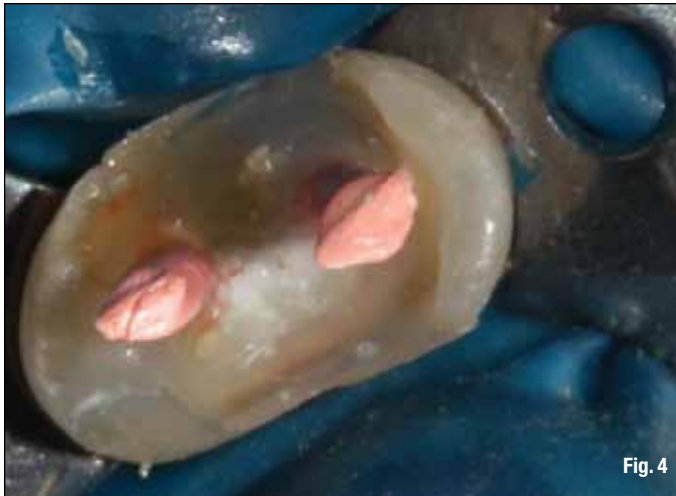

Fig. 4

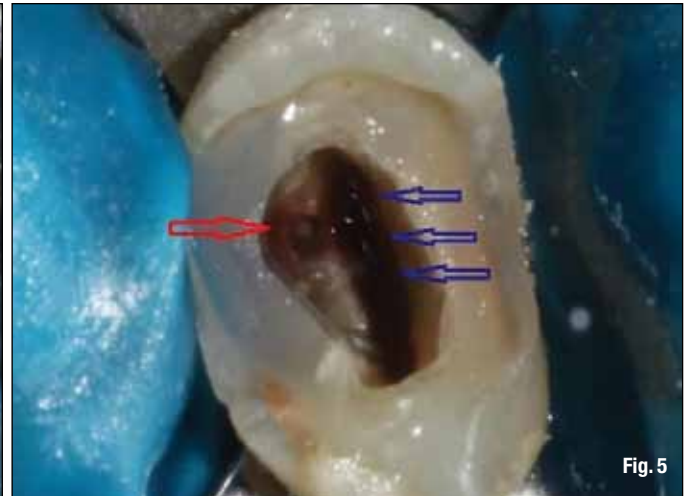

Fig. 5

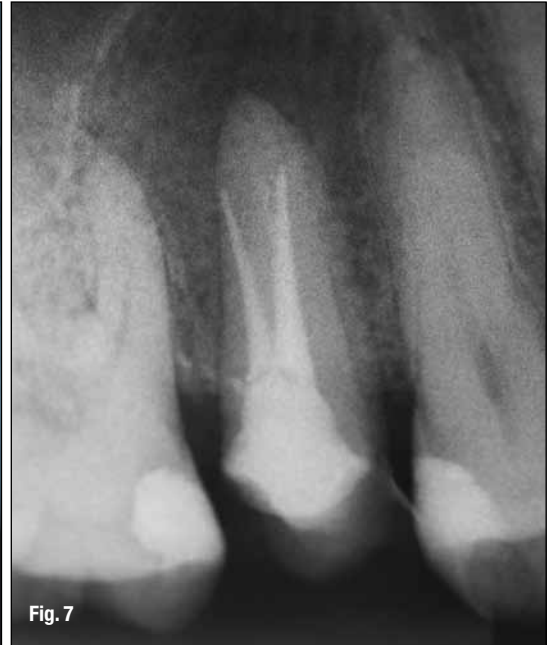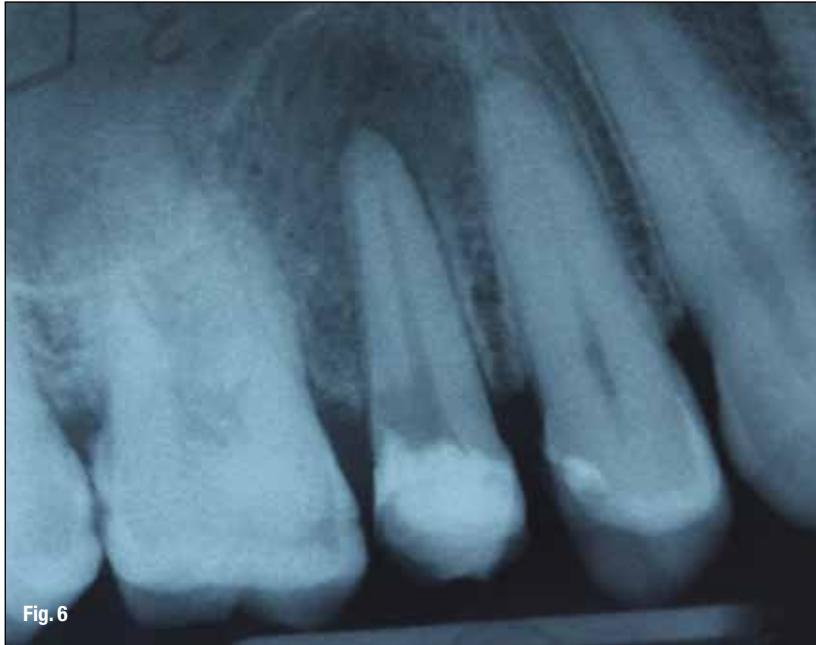ping, perforation or internal resorption, is reported to be 47 percent.<sup>2</sup> Perforations have the most negative influence.<sup>3</sup>

One of the factors that influence the outcome following non-surgical retreatment is the final restoration. Though some authors question the importance of the coronal restoration for the longevity of endodontically treated teeth,<sup>4,5</sup> it is well accepted that the final restoration is as important for the outcome of the endodontic treatment as the quality of the treatment itself.<sup>6</sup> Still, restoration of endodontically treated teeth remains a controversial issue. In the context of the increasing relevance of biomimetics,<sup>7,8</sup> adhesively inserted indirect partial tooth-colored restorations are gaining more and more attention. The restoration or mimicking of the biomechanical, structural and esthetic integrity of the teeth in a conservative manner is an advantage that must be used and preferred whenever possible. Still, these types of restorations are an underutilized restorative modality, particularly on endodontically treated teeth compared to crowns.<sup>9</sup> This may be because clinicians and

dental technicians are more familiar with crown restorations, the results of which are predictable, and insecure about the adhesive protocol for bonded partial restorations.

Once the decision for tooth-colored partial restoration is made, the operator must choose between two materials – composite or ceramics. The benefits of the former (less abrasiveness and brittleness, lower costs, easy to polish and repair, user friendly) encounter the strength, inertness and biocompatibility of the latter. While some studies indicate that ceramic and composite inlays provide similar fracture resistance on endodontically treated premolars,<sup>10</sup> other suggest that when cuspal coverage is required composite resin may be more beneficial in endodontically treated posterior teeth compared to ceramics pertaining to its greater survival rate, fatigue resistance and more favorable failures.<sup>11</sup> This can be explained with the more friendly stress distribution of composite resin onlays, confined above the cemento-enamel junction.<sup>12</sup>

The present report describes the microscopic retreatment and the definitive restoration of a



grossly decayed perforated maxillary premolar. The reasons for the applied treatment are discussed.

### Case report

A 34-year-old male patient reported to the department of Operative Dentistry and Endodontics, complaining of symptoms from another tooth. The radiographic examination (Fig. 1) revealed inadequate endodontic treatment and perforation with radiolucent area at the apex of tooth 15. The tooth was endodontically treated four years ago.

Medical history was non-contributory. Probing was within normal limits. Local anesthesia with Ubistesine DS was administered. After the removal of the old restoration (Fig. 2) and cleaning up the decay, a pre-endodontic buildup was accomplished. Undercuts were not removed but were blocked out with the composite resin. The operative field was isolated with retraction cord immersed in AICI3 and Matrix band (Fig. 3). While keeping the orifice and perforation open with gutta-percha points and Cavit, a total etch technique was performed. Enamel and dentin were covered with adhesive (Prime Et Bond NT, Dentsply) and polymerized for 10 seconds. Bulk-fill flowable composite was applied (SDR, Dentsply) and polymerized for 40 seconds in order to create a reservoir for the irrigants during endodontic retreatment (Fig. 4). After the removal of gutta-percha points and Cavit, the real canal (blue arrows) and the perforation (red arrow) were easily accessible (Fig. 5).

Since the artificial canal was previously obturated with a paste, cleaning with a combination

of hand files, ultrasonics (Pro Ultra 5 and 6) and irrigation with citric acid was used. To confirm the effectiveness of the cleaning procedure, an intra-operative X-ray was done (Fig. 6). Because of the different angulation of the beam, it seems as if the perforation is on the level of the crestal bone, which is not the real case.

For cleaning and shaping of the real root canal, the following protocol was used:

- 1) Glide path was established using SS K-files 08, 10, and Path Files 013, 016, 019, (Dentsply Maillefer).
- 2) The upper two-thirds was prepared using S1 and S2 files from Pro Taper system (Dentsply Maillefer).
- 3) The apical third used a 20 (04) GTX file (Dentsply Maillefer).

Throughout the whole procedure, irrigation with Citric acid (40 percent, Cerkamed, Poland) and NaOCl (2 percent, Cerkamed, Poland) was used.

We preferred S1 and S2 files because of their ability to brush against the canal wall, which is very useful in cases with oval cross sections, where it is of paramount importance to clean all aspects of the root canal spaces. For the apical one third we choose a landed GTX file, because the canal was very narrow and we wanted to eliminate the possibility to transport the apical foramen. Both artificial and true canal were obturated using warm vertical compaction of gutta-percha and MTA-based sealer (FillApex, Angelus, Brazil). On the post-op radiograph, the preparation and obturation seem short, but this was the reading we repeatedly got with our apex locator (RayPex5, WDV, Germany) (Fig. 7).



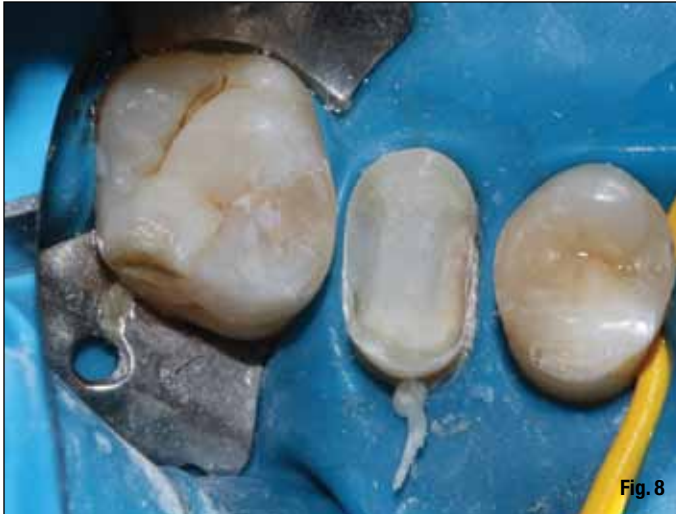

Fig. 8

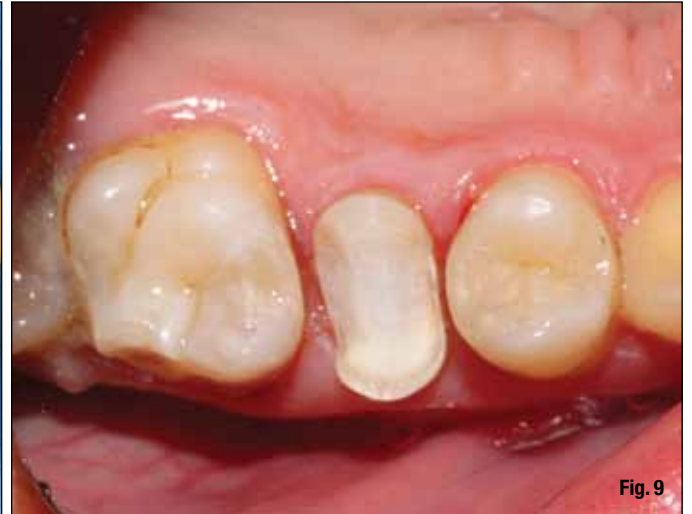

Fig. 9

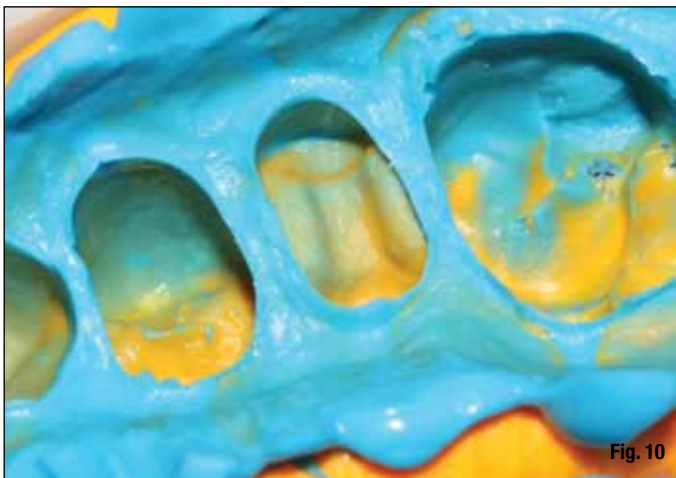

Fig. 10

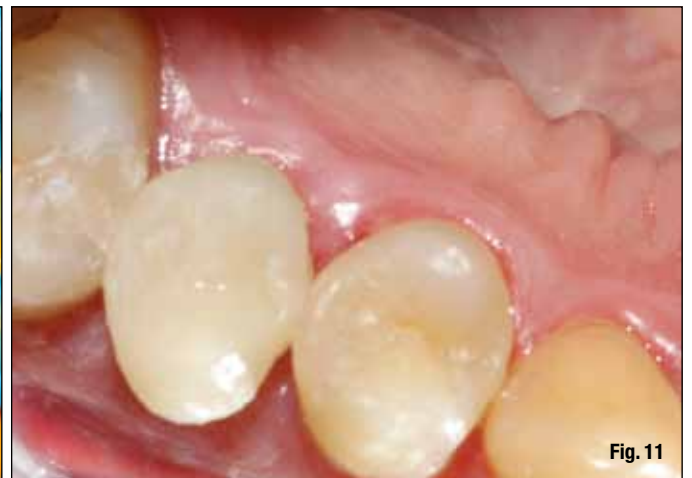

Fig. 11

After the completion of the endodontic retreatment, the pre-endodontic buildup was left at place and the endodontic access was restored again with SDR, creating a core, on which an onlay preparation with diamond burs (Mani Inc.) was performed (Figs. 8,9). The enamel margins were exposed and unsupported enamel prisms were removed using fine-grit diamond points. The remaining tooth structure was prepared to create a butt-joint with the restoration margins. Internal line angles were rounded and the walls provided 5- to 15-degree path of divergence. The proximal boxes preparations extended to the existing composite, since they were located in the dentin.

The dimensions of the preparation provided at least 2 mm interocclusal clearance, which could be verified on the impression. A condensable silicone impression was taken (Fig. 10). A custom-made provisional restoration was created using direct technique and temporarily cemented with a non-eugenol luting agent (TempBond NE) (Fig. 11). The fitting aspect of the restoration was sandblasted by the dental technician.

At the second appointment after assessment of the prepared restoration, removal of the

provisional and cleaning of the preparation the fit and aesthetics of the onlay were evaluated. Rubber dam was placed and the preparation was cleaned with acetone, etched with 37 percent phosphoric acid for 15 seconds, rinsed and dried.

The fitting aspect of the restoration was also cleaned with acetone prior to cementation. A dual-cure self-adhesive luting resin (SmartCem2, Dentsply) was applied to the walls of the preparation and the restoration was placed with firm pressure until fully seated. The excess cement was removed with an explorer, a #12 scalpel blade and dental floss in the interproximal area after five-second polymerization that brought the cement to a "rubbery" stage (Figs. 12,13). The restoration was covered with glycerin and finally cured for 60 seconds from each side (Figs. 14,15). The minimal occlusal adjustments were done with fine diamond burs under water coolant. Finishing and polishing were accomplished with the Enhance system (Dentsply) (Fig. 16).

Once finishing and polishing was done, a 37 percent phosphoric acid gel was applied for 15 seconds to clean the surface of the restoration and to acid etch the marginal enamel. After