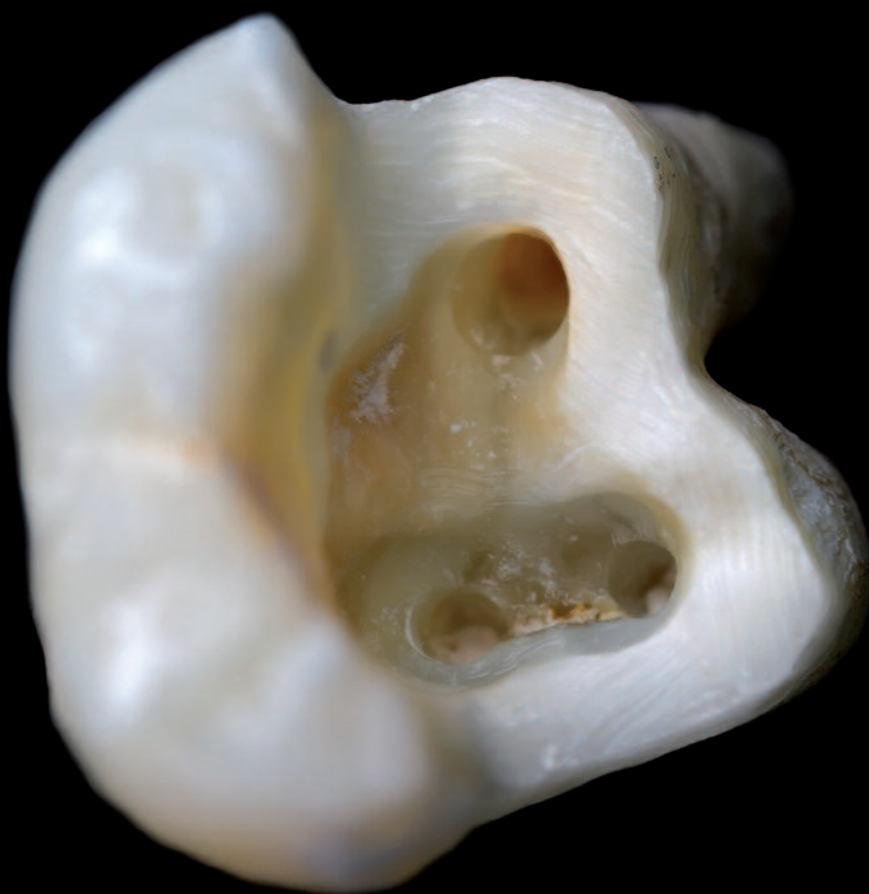

roots

international magazine of endodontology

3²⁰¹⁴



| CE article

Restoration of endodontic teeth:
An engineering perspective

| trends

PIPS and retreatment

| special

Daktari for Maasai –
Mobile Dental Care in the Serengeti



Dental Tribune International

The World's Largest News and Educational Network in Dentistry

dti] Dental Tribune International

www.dental-tribune.com



Dear Reader,



Dr Sekar Mahalaxmi

I have great pleasure in welcoming you to the first Roots Summit in India. After the stupendous success of the Roots Summit in Brazil in 2012, it is time for roots to travel all the way east to the beautiful country of India, with its rich culture, flora and fauna; where loads of enthusiastic rooters are eagerly awaiting this endodontic clinical and academic extravaganza.

This year's Roots Summit is held in Mahabalipuram, a peaceful beach town near the southern city of Chennai. An array of national and international speakers will share their experiences on the complexities of the root canal, the management of separated instruments, and regenerative endodontics, which are critical areas in today's clinical scenario in endodontics. To add to this, there are more than a dozen pre-summit workshops to choose from for those who wish to gain first-hand experience. This is a golden opportunity for all dentists from Asian countries and from afar to meet in India to further enhance their knowledge and skills in a positive way.

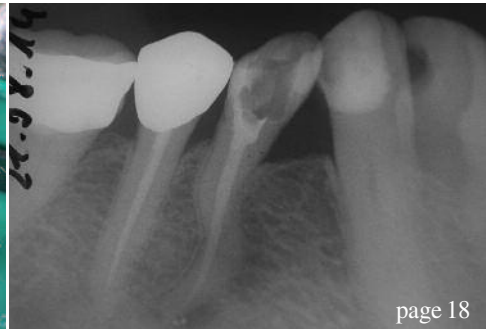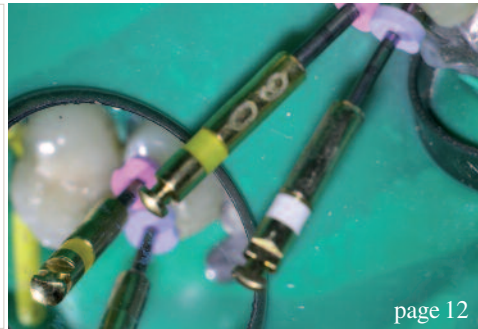
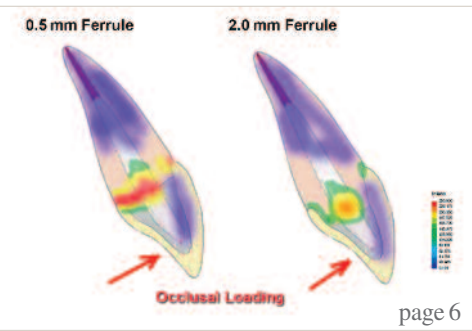
Together with other members of the organising team, I invite you to your lifetime experience with stalwarts in the field of endodontics. The organising team will leave no stone unturned to make this Summit an event to remember by one and all. We look forward to three full days of pure knowledge, clinical skills and academic excellence that will keep the delegates glued to their seats.

Stay with us and enjoy the warm and vibrant Indian hospitality.

Yours faithfully,

Mahalaxmi

Dr Sekar Mahalaxmi
Head of the Department of Conservative Dentistry and Endodontics
SRM University, College of Dentistry, Chennai, India



editorial

- 03 Dear **Reader**
| Dr Sekar Mahalaxmi

CE article

- 06 **Restoration of endodontic teeth:**
An engineering perspective
| Dr Gregori M. Kurtzman

industry report

- 14 **Pressing** endodontic issues
| Dr Antonis Chaniotis

case report

- 18 **S-shaped root**—risks of a master challenge
in endodontology
| Dr Friedrich Müller

trends

- 20 **PIPS** and retreatment
| Dr Reid Pullen

feature

- 24 **“Continuous Education is a top priority for us,
first proof is our new Training Centers”**
| Interview with Alexandre Mulhauser, FKG Dentaire Middle East
& Africa Director

research

- 26 **Diclofenac**, dexamethasone or **laser** phototherapy? Part II
| Jan Tunér

special

- 30 **Daktari for Maasai—**
Mobile Dental Care in the Serengeti
| Prof. Martin Jörgens

industry news


- 38 **Planmeca and the University of Turku**
found Nordic Institute of Dental Education
| Planmeca

events

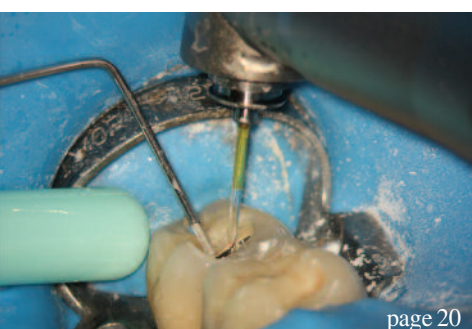- 40 International **Events**

about the publisher

- 41 | submission guidelines
42 | imprint



Cover image courtesy: Ocskay Bence/shutterstock.com





CROIXTURE

PROFESSIONAL MEDICAL COUTURE



THE NEW 2014-2015 COLLECTION

EXPERIENCE OUR ENTIRE COLLECTION ON WWW.CROIXTURE.COM

Restoration of endodontic teeth: An engineering perspective

Author_ Dr Gregori M. Kurtzman, USA

_ce credit

roots



This article qualifies for CE credit. To take the CE quiz, log on to www.dtstudyclub.com. Click on 'CE articles' and search for this edition of the magazine. If you are not registered with the site, you will be asked to do so before taking the quiz. You may also access the quiz by using the QR code.

_Introduction

Identifying the canals and negotiating them to be able to instrument and obturate the tooth is necessary to clinical success. But restoration of the endodontically treated tooth is critical to long-term success. It does not matter if we can complete the endodontic portion of treatment if the tooth cannot be restored. With this in mind, we need to look at the restoration phase from an engineering perspective. What is needed to reinforce the remaining tooth so that it can manage the repetitive loading that occurs during mastication? This article will discuss the importance of ferrule in adhesive dentistry as well as when to use posts and what materials are best.

_Ferrule: How important is it today?

Ferrule was an important concept in dentistry but has been de-emphasized with the bonding evolution. Yet this concept is as important today as it was prior to dental bonding. But what is a ferrule? A ferrule is a band that encircles the external dimension of residual tooth structure, not unlike the metal bands that exist around a barrel to hold the slats together. Sufficient vertical height of tooth structure that will be grasped by the future crown is necessary to allow for a ferrule effect of the future prosthetic crown; it has been

shown to significantly reduce the incidence of fracture in the endodontically treated tooth.^{1,2}

Important to this concept is the margin design of the crown preparation, which may include a chamfer or a shoulder preparation. Because a chamfer margin has a bevelled area that is not parallel to the vertical axis of the tooth, it does not properly contribute to ferrule height. Therefore, when a chamfer is utilized it would require an additional 1 mm of height between the edge of the margin and the top aspect of the coronal portion of remaining tooth structure. Thus, use of a chamfer may not be the best margin design when restoring endodontically treated teeth or those teeth with significant portions of missing tooth structure. With today's movement toward scanning and milling for fixed prosthetics, whether done in the practitioner's office or at the laboratory, it should be noted that it is difficult to scan the internal aspect of a shoulder preparation and it has been uniformly recommended that a rounded shoulder be used. The rounded shoulder preparation provides the maximum vertical wall at the margin, with the internal aspect being slightly rounded versus at a 90-degree angle. This ensures better replication of the margins when scanned and milled.

Some studies suggest that while ferrule is certainly desirable, it should not be provided at the expense of the remaining tooth/root structure.³

Alternatively, it has also been shown that the difference between an effective, long-term restoration and restorative failure can be as small as 1 mm of additional tooth structure that, when encased by a ferrule, provides greater protection. When such a long-lasting, functional restoration cannot be predictably created, osseous crown lengthening should be considered to increase what tooth structure is available to achieve a ferrule, but this is also dependent on the periodontal status of the tooth, and

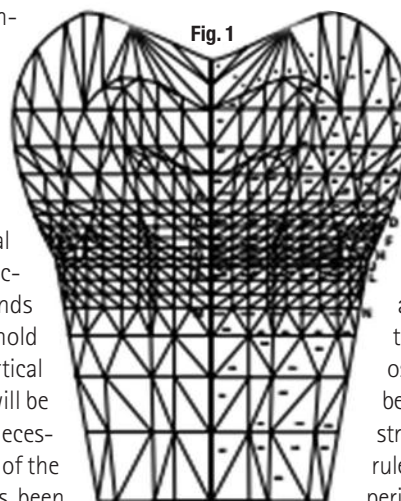


Fig. 1 Strain analysis of a posterior tooth demonstrating concentration of strain on loading at the cervical. (Image/Dr Gene McCoy)

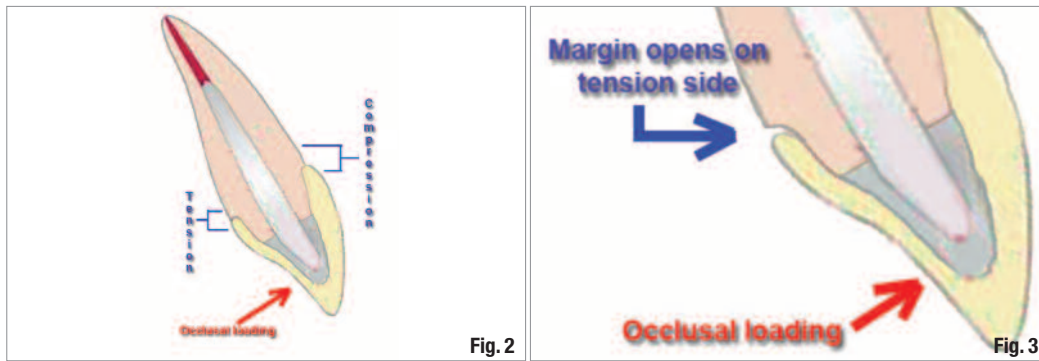


Fig. 2 As a maxillary anterior tooth is loaded during mastication, tension and compression occur at the crown's margins.

(Images/Dr Gregori M. Kurtzman)

Fig. 3 Opening of the margin on the tension side may lead in time to recurrent decay or restoration and endodontic failure.

when ferrule cannot be achieved then extraction should be considered.⁴ Ichim, et al, stated succinctly, "The study confirms that a ferrule increases the mechanical resistance of a post/core/crown restoration."⁵

How much ferrule is required?

When rebuilding an endodontically treated tooth, it is best to maintain all dentin that is available, even thin slivers. These thin slivers of dentin provide a strong connecting link between the core and tooth's root and between the crown and root.⁶ It is important to attempt to retain as much tooth structure as possible, and this aids in achieving ferrule as well as maintaining cervical strength of the tooth where loading concentrates. Under masticatory loading, strain concentrates at the cervical portion of teeth, thus it is important to avoid over-preparation of this portion of the tooth during endodontic treatment and preserve this area during restoration of the tooth (Fig. 1).

Multiple studies discussing how much ferrule is required have found that teeth with at least 2 mm of ferrule have significantly greater long-term prognosis from a restorative standpoint than those with less or no ferrule. Libman, et al, reported, "Fatigue loading of

cast post and cores with complete crowns of different ferrule designs provide evidence to support the need for at least a 1.5-mm to 2.0-mm ferrule length of a crown preparation. Crown preparation with a 0.5-mm and 1.0-mm ferrule failed at a significantly lower number of cycles than the 1.5-mm and 2.0-mm ferrules and control teeth."⁷ Libman further demonstrated when loading at an off-axis direction, which occurs in the maxillary anterior, at the restoration's margin the side where the load is originating is under tension, whereas the opposing side is under compression (Fig. 2). This repetitive loading and micro strain due to tension at the lingual margin leads to the margin opening, which may lead to recurrent decay and/or failure of the endodontic seal or restoration (Fig. 3).

Additionally, if we look at strain studies by Libman and others comparing ferrule of different heights, we observe that in a ferrule of 0.5 mm there is greater strain at the margin under tension and concentrates at mid tooth where the core or post is situated. Teeth with 2.0 mm of ferrule demonstrated significantly less strain loading at the margins or centre of the cervical aspect of the tooth. The lower the strain at the cervical midpoint, the less chance of overload and failure restoratively (Fig. 4).

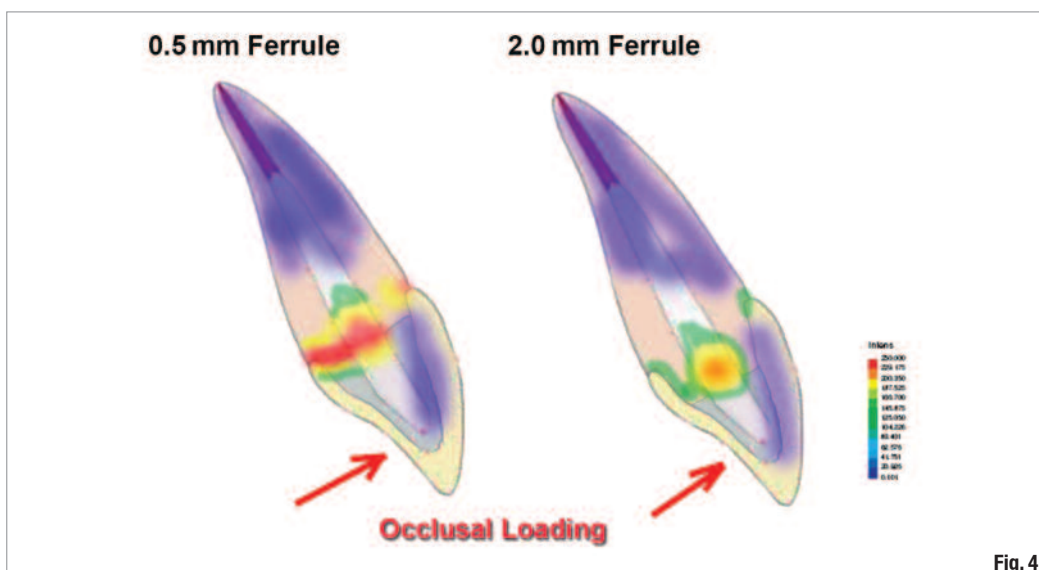


Fig. 4 Difference of intensity of strain and location related to ferrule height during occlusal loading (Libman).

Fig. 5_ Comparison of load distribution of fiber posts compared to a cast post and prefabricated metal post.

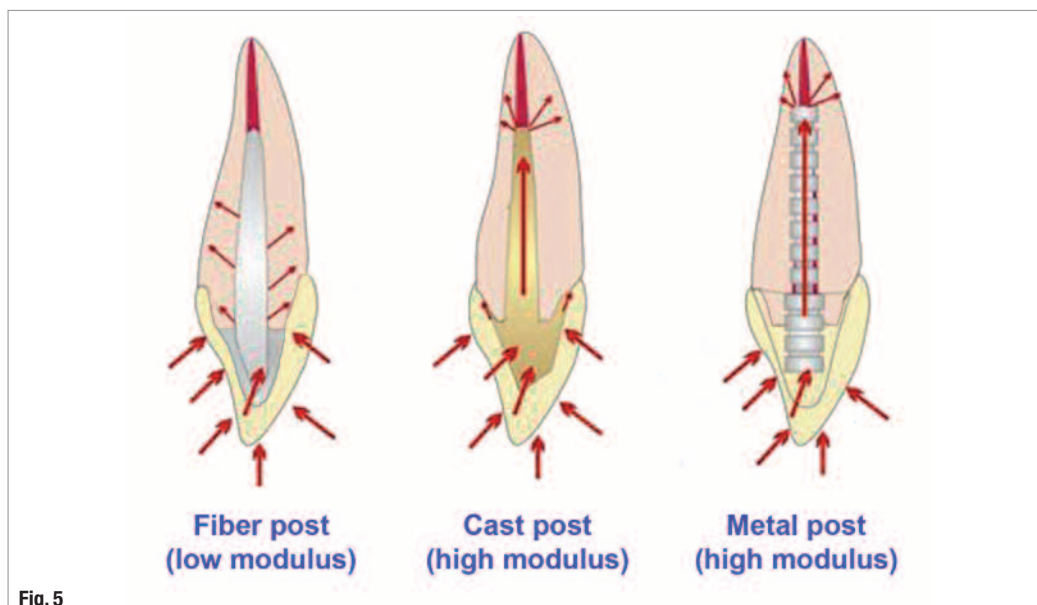


Fig. 5

Detecting failure at the coronal seal

It is not unusual to have a patient present for a routine recall appointment and the clinician or hygienist note recurrent decay at a crown margin with the patient unaware of the issue. This becomes more complicated with teeth that have previously undergone endodontic treatment, as there is no pulp present that could warn the patient an issue is present until often extensive decay occurs or the crown dislodges from the remaining tooth. Freeman, et al, in their published study, stated, "Fatigue loading of three different post and core designs with the presence of a full cast crown leads to preliminary failure of leakage between the restoration and tooth that is clinically undetectable."⁸

The literature supports that coronal leakage may be a major factor in failure of endodontic treatment.⁹⁻¹¹ As previously discussed, when loaded during mastication, margins with inadequate ferrule may demonstrate micro opening on the tension side, leading to leakage over time. This initially may be observed as recurrent decay, but as it deepens and exposure of the obturation material results, failure of the endodontics may result due to apical migration of oral bacteria. This is minimized when a bonded core or post/core is present, but given sufficient time when a ferrule of sufficient height is not present the endodontics or the restoration will fail.

Do all posts function the same?

Teeth function differently, depending on the material that the post is fabricated from, with loads distributed within the root relative to the modulus of elasticity of the post compared to the dentin of the root (Fig. 5).

When a tooth restored with a fiber post does fail due to overload, the mode of failure is coronal, protecting remaining root and tooth structure.¹² This mode of failure with fiber-post-restored teeth typically allows the tooth to be restored, as vertical root fracture is a rare occurrence. Bitter reported, "Compared to metal posts, FRC posts revealed reduced fracture resistance in vitro, along with a usually restorable failure mode"¹³ (Fig. 6). Whereas, with metal posts either prefabricated or cast, failure was at a higher value for cast post and core 91 per cent of the specimens had fractured roots, none of the specimens with a fiber post demonstrated root fracture; the post and core usually fractured at the tooth composite core interface.¹⁴ As stress concentrates at the apical tip of the metal post due to its higher modulus of elas-

Fig. 6_ Tooth restored with a fiber post demonstrating coronal horizontal fracture supracrestally typically seen with teeth restored with fiber posts when overloaded.

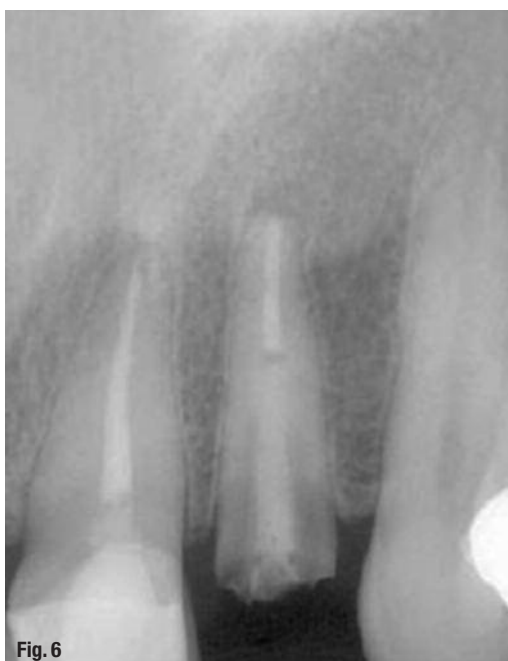

Fig. 6

ticity than the surrounding root, vertical root fracture is a frequent occurrence (Fig. 7). This may result also from breakdown of the cement luting the post to the root, allowing slippage microscopically of the post in the tooth under load, leading to torque at the cervical area and the resulting vertical root fracture.

As metal posts are stiffer (higher modulus of elasticity) than the dentin of the root, with metal posts stress concentrated at the posts apical leading to vertical root fracture and catastrophic loss of the tooth. Ansari reported, "The risk of failure was greater with metal-cast posts (nine out of 98 metal posts failed) than with carbon fiber posts (using which, none out of 97 failed) risk ratio."¹⁵ But with fiber posts having a flexibility equal or greater than the root (lower modulus of elasticity) stress concentrated at the cervical region leading to horizontal fracture of the post and core and typically the tooth can be salvaged.

The elastic modulus refers to the relative rigidity of the material. The stiffer the material, the higher its relative modulus. When two different materials are placed together, as an example, a post is placed into a tooth's root the elastic modulus is influenced by whichever of the materials is stiffest. Dentin averages a modulus of elasticity of 17.5 (+/- 3.8) GPa, with glass fiber posts at 24.4 (+/- 3.4) GPa, titanium prefabricated posts at 66.1 (+/- 9.6) GPa, prefabricated stainless steel at 108.6 (+/- 10.7) GPa and cast high noble gold posts at 53.4 (+/- 4.5) GPa. Cast posts fabricated from noble or base metals have higher modulus than high noble alloys and approach stainless-steel prefabricated posts in their relative stiffness. Fiber posts have an elastic modulus that more closely approaches that of dentin (Fig. 8). The flexural strength of fiber and metal posts was respectively four and seven times higher than root dentin, and there is still debate on whether a post strengthens the tooth.^{16,17} The basic purpose of a post is to aid in retention of the core.

The absence of a cervical ferrule has been found to be a determining negative factor, giving rise to considerably higher stress levels within the root. When no ferrule was present, the prefabricated metal post/composite combination generated greater cervical stress than cast post and cores. Yet, the ferrule seemed to cancel the mechanical effect of the reconstruction material on the intensity of the stresses. With a ferrule, the choice of reconstruction material had no impact on the level of cervical stress. The root canal post, the purpose of which is to protect the cervical region, was also shown to be beneficial even with sufficient residual coronal dentin. In the presence of a root canal post, cervical stress levels were lower than when no root canal post was present. Pierrisnard concluded that the higher the elasticity modulus, the lower the stress levels.¹⁸

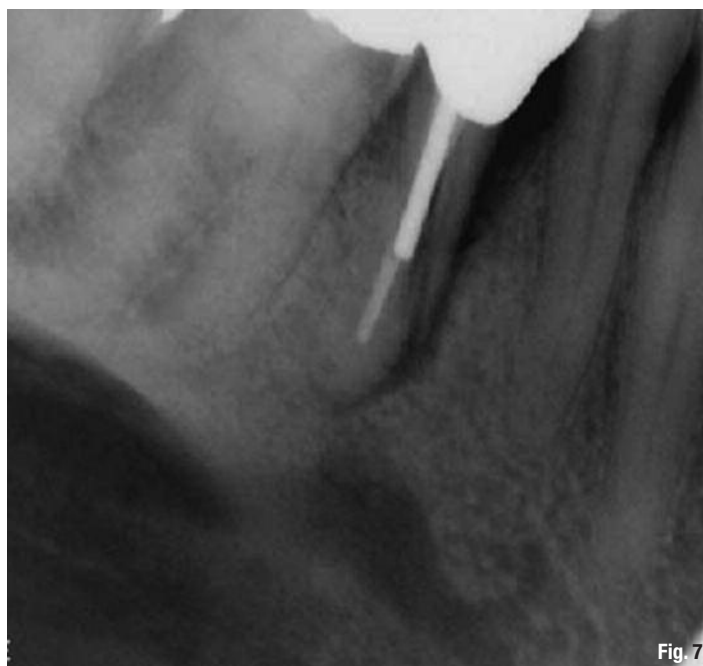


Fig. 7 _Vertical root fracture of a tooth restored with a metal post.

The material the post is fabricated from should have the same modulus of elasticity as the root dentin to distribute the applied forces along the length of the post and the root and not concentrate them at the apical tip of the post. Studies have shown that when components of different rigidity are loaded, the more rigid component is capable of resisting forces without distortion. This stress is concentrated when the post is the stiffer material at the posts apical tip. The less-rigid component fails invariably when a post is used that is stiffer than the root's dentin.¹⁹ Posts with modulus of elasticity significantly greater than that of dentin create stresses at the tooth/cement/post interface, with the possibility of post separation and failure. As repetitive loading occurs on the endodontically restored tooth, the cement eventually fails at the interface between the metal post and root dentin, allowing microslippage of the post. This allows higher stresses to be exerted on the root, leading to vertical root fracture and catastrophic loss of the tooth. The higher modulus (rigidity) of the metallic posts makes it stiff and unable to absorb stresses. In addition, transmission of occlusal and lateral forces through a metallic core and post can concentrate stresses, resulting in the possibility of unfavorable fracture of the root.²⁰ Dentin's modulus of elasticity is approximately 14 to 18 GPa. Fiber posts have modulus that is approximately 9 to 50 GPa, depending on the manufacturer of the post. This provides a similarity in elasticity between the fiber post and dentin of the root, allowing post flexion to mimic tooth flexion. The fiber post absorbs and distributes the stresses and thus shows reduced stress transmission to the root.²¹ The longitudinal arrange-