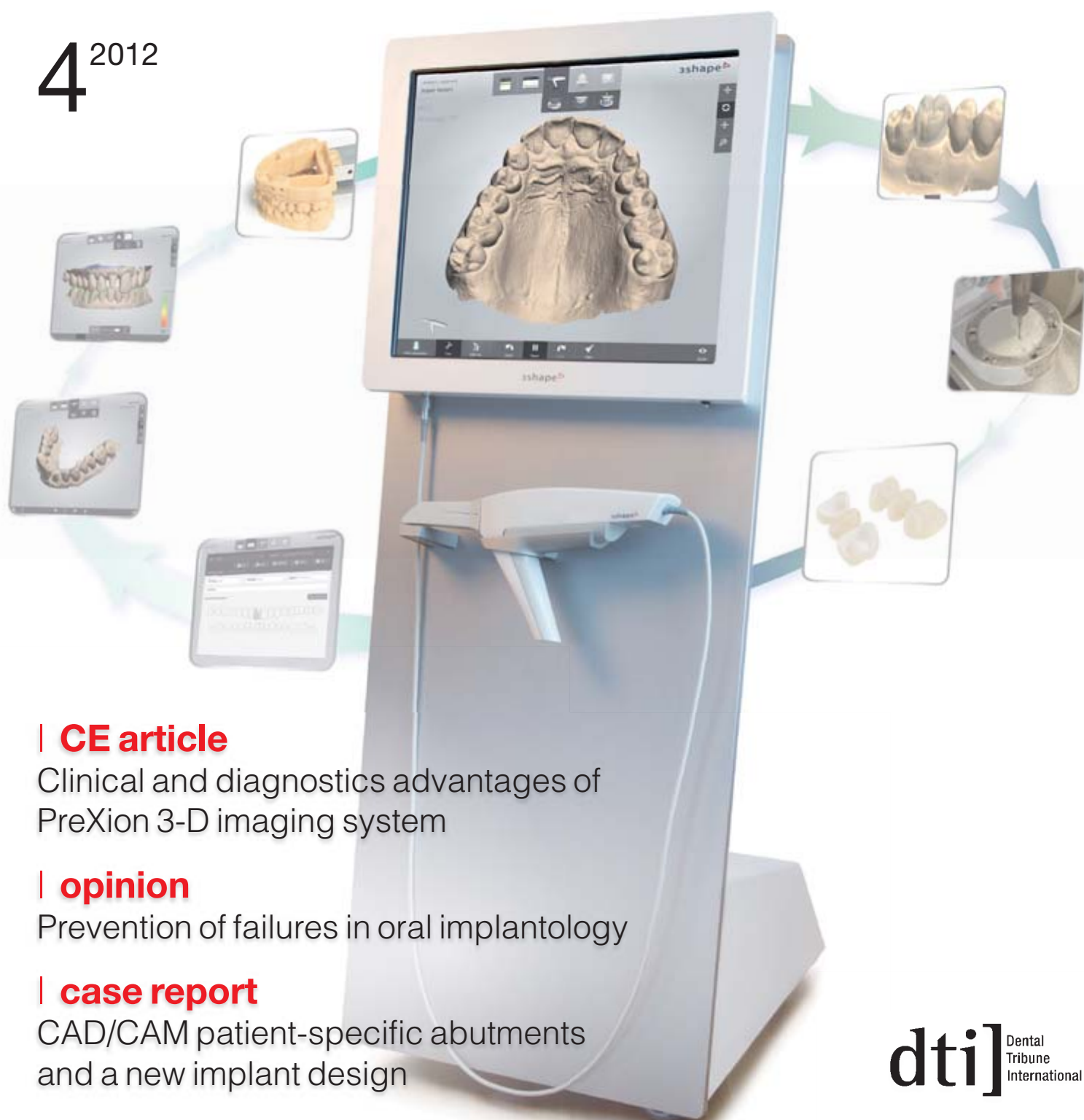

CAD/CAM

international magazine of digital dentistry

4²⁰¹²



| CE article

Clinical and diagnostics advantages of PreXion 3-D imaging system

| opinion

Prevention of failures in oral implantology

| case report

CAD/CAM patient-specific abutments and a new implant design

Nobel Biocare Global Symposium 2013 – New York

JUNE 20–23, WALDORF ASTORIA NEW YORK



Gain insight how to treat
more patients better

Experience the best in
implant dentistry

Learn from over 100 world-
renowned leaders

Enjoy the fascinating
city of New York



Designing for Life: Today and in the future. Join the leading experts in implant dentistry at the event not to be missed in 2013. This exciting four-day Nobel Biocare Global Symposium 2013 in New York is your number one opportunity to gain the full 360-degree perspective on how you can treat more patients better. Benefit from an innovative and insightful program format designed to maximize your learning experience. Update yourself on the key factors for successful oral rehabilitation such as diagnostics

and treatment planning, surgical and restorative treatments and patient follow-up. Understand how to effectively restore missing single teeth, multiple teeth and edentulous jaws. Learn more about important clinical themes such as minimally invasive, graftless solutions, immediate replacement and function, soft tissue health and esthetics. Find out how you can utilize this knowledge to achieve even better results. **Register now!**



nobelbiocare.com/newyork2013



Dear Reader,

_With 2012 drawing to a close, I would like to take a brief look back at the past and share some thoughts with you.


While it sometimes appears that time flies by at a rapid pace, advancements in dentistry have truly been rapid. Presumably, the extraordinary progress may not be felt as strongly by dentists in the former Eastern Bloc countries, such as the Czech Republic, as it is by dentists in Western Europe or the USA. However, nearly 20 years ago, most of our dental units worked with pulleys and cables, while the offices were equipped with chairs that did not allow treatment of a patient in a horizontal position.

From a global perspective, dentistry has undergone a series of significant changes. Not long ago, there was only one company involved in CAD/CAM technology—intra-oral scanning and milling of dental restorations in particular. Currently, there are nearly 10 intra-oral scanners and at least 20 extra-oral laboratory scanners from which to choose. Today's dentists can obtain intra-oral images from CBCT devices and we can manufacture implant guides in-office while the patients wait—all of which was the realm of science fiction until recently. I am grateful to be experiencing this exciting development.

Therefore, I am not sure that today we can still refer to 3-D technologies in dentistry as "revolutionary". In some areas of dentistry, these technologies have already become a diagnostic tool, or have even established themselves as a standard operating procedure. That is one of the reasons we decided to build, and in May 2012 opened, the Czech Society of CAD/CAM Dentistry (CSCD) Training Center. The centre is focused primarily on the practical education of dentists and dental technicians in the use of CAD/CAM technologies and CBCT. Inspired by the old Chinese proverb "It's better to see once than to hear a hundred times", we equipped the centre and the operating room with high-definition cameras and audio-visual data channels. This allows the participants to view the live procedures in the classroom (in the case of large audiences, the entire process can be shown in a nearby 3-D cinema). In the centre's training laboratories, every course participant is equipped with his or her own ready-to-use intra-oral scanner and a phantom head connected to the dental units—because as dental professionals we all realise that without training and hands-on practice in proper preparation all advantages of CAD/CAM technologies are meaningless.

I wish you not only a perfect fit for your scans and millings, but also a fulfilling personal and professional life in the upcoming year. I also sincerely hope to see you at some of the practical courses in the Czech Republic soon!

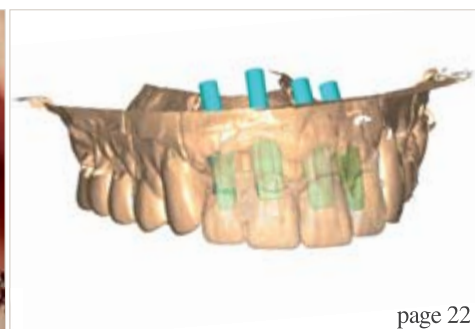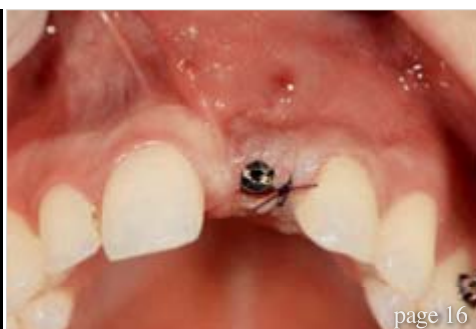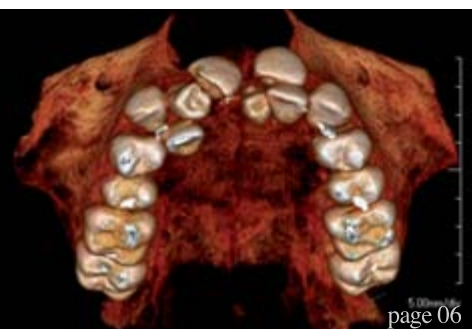
With kind regards and best wishes,



Dr Josef Kunkela
President of the Czech Society of CAD/CAM Dentistry



Dr Josef Kunkela
President of the Czech Society
of CAD/CAM Dentistry



editorial

03 Dear Reader

I Dr Josef Kunkela, President of the Czech Society of CAD/CAM Dentistry

CE article

06 Clinical and diagnostics advantages of PreXion 3-D imaging system

I Dr Dan McEowen

opinion

10 Prevention of failures in oral implantology

I Dr Dov M. Almog

12 Use of CBCT in implant dentistry should follow justification and optimisation

I A commentary by Prof. Keith Horner, University of Manchester

feature

14 Traditional imaging will not disappear with CBCT

I An interview with Prof. Stefan Häßfeld

case report

16 Early childhood anterior tooth trauma

I Dr Fred Bergmann

22 CAD/CAM patient-specific abutments and a new implant design

I Prof. Frank Liebaug & Dr Ning Wu

special

26 The importance of occlusion

I Dr Peter Bausch

industry report

30 Computer-aided crown design—Fabrication of CAD/CAM crowns chairside

I Dr Andreas Bindl

industry news

34 Planmeca ProMax 3D Mid—An optimal volume size for every 3-D imaging application

I Planmeca

35 CEREC Omnicam: Powder-free 3-D scanning in full colour

I Sirona Dental GmbH

36 3Shape introduces CAD Points—A unique pay-per-design service that opens up new opportunities for dental labs

I 3Shape

38 Straumann and Align discontinue distribution agreements for iTero intra-oral scanner

I Institut Straumann

40 CAMLOG Foundation calls for entries for its 2012/2013 research award

I CAMLOG

digital platforms

41 Course calendar

meetings

42 Digital dentistry conference draws over 500 to Singapore

44 EAO celebrates successful anniversary event in Copenhagen

46 Digital developments on show at IDS 2013—CAD/CAM technology in the spotlight

48 International Events

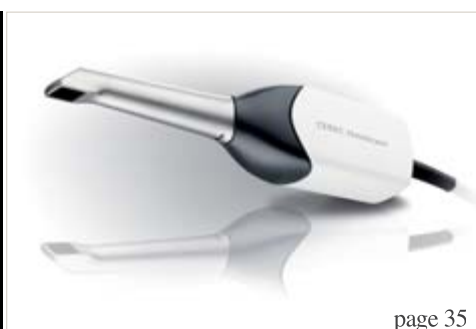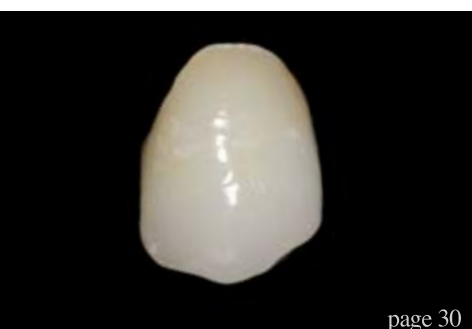about the publisher

49 I submission guidelines

50 I imprint



Cover image courtesy of crowncceram – www.crowncceram.com.



**IPS[®]
e.max[®]**

THE WORLD SPEAKS e.max.



SO DOES THE SCIENCE.*

UP TO 10 YEARS¹ OF CLINICAL EVIDENCE.
98.2%² CROWN SURVIVAL RATE.
40 MILLION RESTORATIONS.³
1 PROVEN SYSTEM:
IPS e.max

**all ceramic
all you need**

* The IPS e.max Scientific Report Vol. 01 (2001–2011) is now available at:
www.ivoclarvivadent.com/science_e

¹ M. Kern et al. "Ten-year results of three-unit bridges made of monolithic lithium disilicate ceramic";
Journal of the American Dental Association; March 2012; 143(3):234-240.

² Mean observation period 4 years IPS e.max Press, 2.5 years IPS e.max CAD.
See the IPS e.max Scientific Report Vol. 01 (2001–2011).

³ Based on sales.



www.ivoclarvivadent.com

Ivoclar Vivadent AG

Bendererstr. 2 | FL-9494 Schaan | Liechtenstein | Tel.: +423 / 235 35 35 | Fax: +423 / 235 33 60

**ivoclar[®]
vivadent[®]**
passion vision innovation

From left: G. Ubassy, Dental Technician, France | M. Roberts, Dental Technician, USA | M. Temperani, Dental Technician, Italy | D. Hornbrook, Dentist, USA |
O. Brix, Dental Technician, Germany | U. Brodbeck, Dentist, Switzerland | G. Gürel, Dentist, Turkey | C. Coshman, Dentist, Croatia | Brazil |
A. Shepperson, Dentist, New Zealand | A. Bruguera, Dental Technician, Spain | S. Kataoka, Dental Technician, Japan | S. Kna, Dentist, Brazil

Clinical and diagnostics advantages of PreXion 3-D imaging system

Author_ Dr Dan McEowen, USA

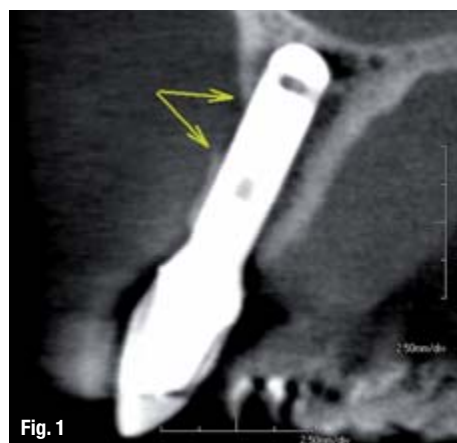


Fig. 1 _Saggital CBCT MPR showing bone defect at point of dehiscence of the implant coating.

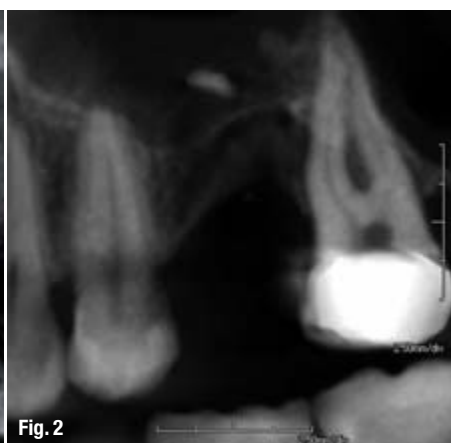

Fig. 2

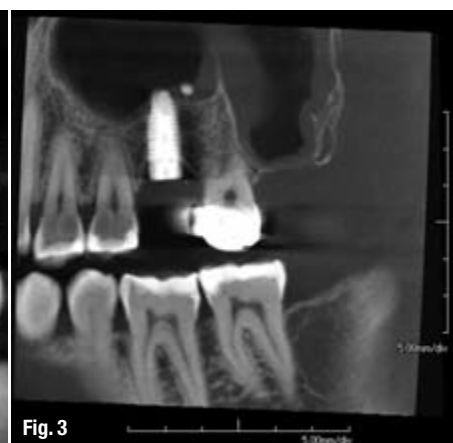

Fig. 3

Fig. 2 _Periapical does not show the sinus anatomy or the width of the bone.

Fig. 3 _MPR showing post-op of sinus graft and implant placement.

_For nearly 100 years, dentists have relied on 2-D radiographic imaging for diagnosis and treatment planning. With the 1999 introduction of cone-beam computed tomography (CBCT), all dentists now have tools available for more accurate diagnosis and treatment.¹

The ability to look at a tooth in any direction and orientation, as well as in 3-D, eliminates much of the guesswork commonly experienced with 2-D radiographs.

We have been limited in most cases to only a buccal-lingual view provided by periapicals, bitewings and panoramic radiographs with the occasional axial view of an occlusal film. Medical CT scans and images began in the early 1970s and were sometimes used by dentists, offering our first multiplaner views.²

The adoption of 3-D cone-beam imaging is appropriate and has important advantages for all modalities of dentistry. From every specialist to the general dentist, the increased amount of radiographic information as well as increased accuracy will aid in the most sound diagnosis possible.

_CBCT description

CBCT is a single or partial rotation of an X-ray source around the head, capturing X-rays on various flat panel arrays and sensors. The information is converted to a series of axial slices by computed tomography and stored as virtual anatomy in the computer.

With the use of sophisticated software, the dentist is able to view information in several different views, including: axial slices (head-to-toe orientation), coronal slices (front-to-back orientation), sagittal slices (side-to-side orientation) all known as multiplaner reconstructions (MPR). The thickness of each slice can be varied to include more or less information.

Because the voxels (volumetric pixels 3-D) are isotropic, other MPR images can be generated by slices drawn at any angle, curve or thickness through the scan to view areas critical to the final diagnosis.^{3,8}

The final view offered by CBCT is a 3-D view that can be rotated and viewed in any direction.

_ce credit CAD/CAM

By reading this article and then taking a short online quiz, you will gain one ADA CERP CE credit. To take the CE quiz, visit www.dtstudyclub.com. The quiz is free for subscribers, who will be sent an access code. Please write support@dtstudyclub.com if you don't receive it. Non sub-



scribers may take the quiz for a \$20 fee.

Once again through software manipulation, 3-D images can be viewed as conventional radiographs, maximum intensity projections (MIP), soft-tissue projections and a variety other views.

This nearly endless ability to manipulate the data aids in the diagnosis and identification of disease, nerve canals, sinus morphology, dental caries, bone density, fractures, endodontic pathology, implant placement criteria, periodontal defects, bone pathology, fractured teeth, iatrogenic trauma, TMJ morphology and disease, third-molar position and many more healthy or diseased conditions.

_Early CBCT adoption with implants

The first and primary use of CBCT for early adopters was implant placement. As the scope and the value of the information became better known, dentists of all branches began to see the value of MPRs and 3-D renderings including periodontics, endodontics, oral surgery, treatment of TMJ, orthodontics, implantology and general dentistry.^{1,7,8}

Clinical periapical and panoramic radiographs for the placement of implants can be misleading with elongation, foreshortening, superimposition and geometrically incorrect data.^{7,8} A look at the implant in the periapical shows no obvious disease to an existing integrated implant. Clinically, a buccal fistula was present with exudate and slight pain. The CBCT scan (Fig. 1) reveals a more accurate view showing a buccal defect on a sagittal MPR. A surgical flap revealed a dehiscence of the coating of the implant. Removal of the foreign body resulted in an asymptomatic and healthy patient.

The evaluation of the available bone for the initial implant placement can be crucial for the long-

term success of the case. If there is inadequate bone available, grafting may be a necessity. CBCT studies render the most accurate information available at a low radiation dose. The periapical shows an obvious lack of bone height, but does not show the buccal-lingual dimensions or an accurate view of the sinus morphology (Fig. 2).

The MPR view of the CBCT shows all necessary measurements to perform the sinus lift and grafting with the immediate placement of the implant fixture (Fig. 3). Three-dimensional views show the floor of the sinus and any soft-tissue pathology (Fig. 4). Having accurate measurements in all dimensions is an advantage of CBCT scanning.

_CBCT and endodontics

Endodontics is a field that is rapidly adopting the use of CBCT and for good reason. The inherent geometric deficiencies of 2-D radiographs make the CBCT scan a valuable adjunct to investigate the root morphology in both 3-D and MPR. The typical periapical will show superimposed canals in the anteriors, bicusps and molars as well as unwanted bone densities both buccal and lingual to the affected tooth making the image quality poor.

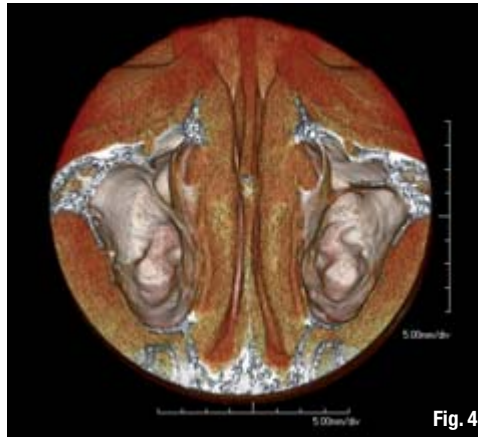


Fig. 4

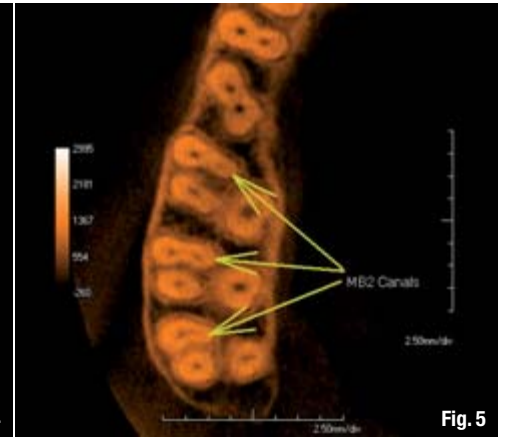


Fig. 5

Fig. 4 _ The 3-D CBCT showing anatomy of the maxillary sinuses.
Fig. 5 _ Axial MPR showing mesial buccal roots in first, second and third molars.

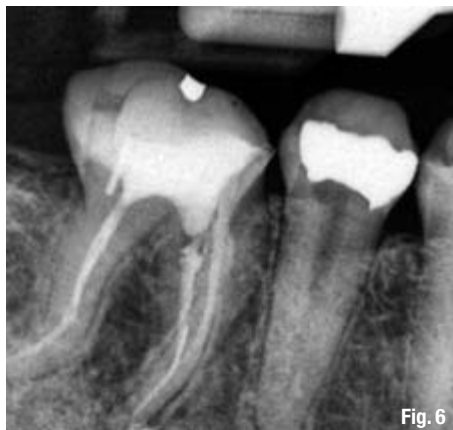

Fig. 6

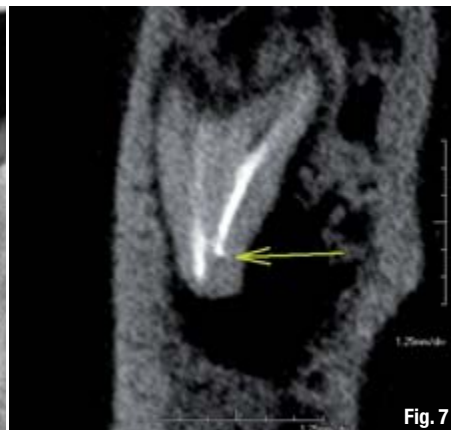

Fig. 7

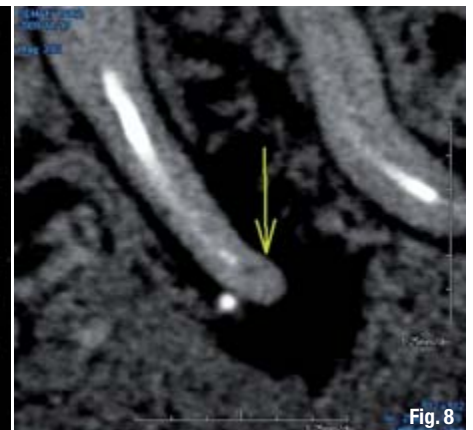

Fig. 8

Fig. 6 _ Periapical showing minimal pathology with no radiolucency.
Fig. 7 _ Coronal MPR showing a short fill on the mesial lingual and radiolucency.
Fig. 8 _ Sagittal MPR showing unfilled canal and radiolucency.

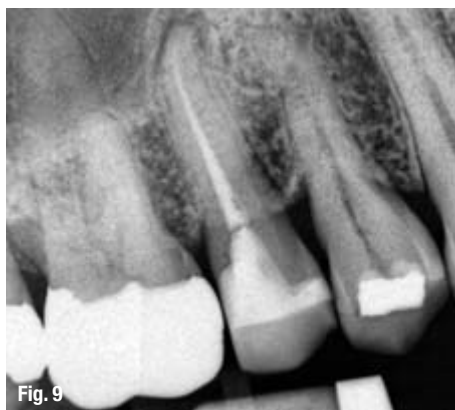

Fig. 9

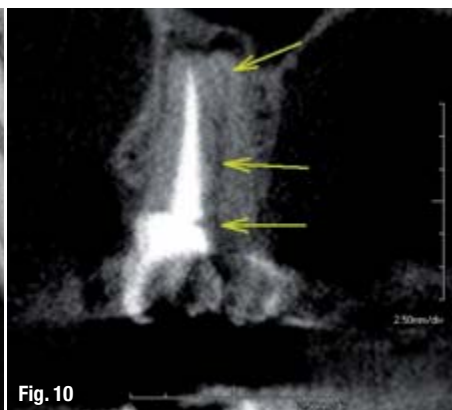

Fig. 10

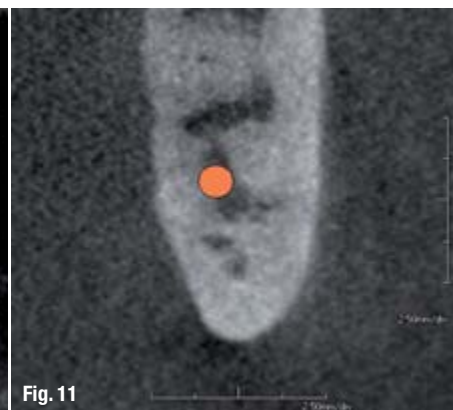


Fig. 11

Fig. 9 Periapical showing a normal fill with a radiolucency.

Fig. 10 Coronal MPR showing the superimposed lingual root unfilled.

Fig. 11 Coronal MPR showing nerve between roots of the third molar.

The ability to view MPR slices in cross-section, long axis and oblique directions gives the ability to follow all canals in any direction and show their relationship and measurements from other known structures. This virtual tour of the root morphology is a great benefit to the final treatment outcome (Fig. 5).^{3,4}

Post root-canal infection can be difficult to diagnose with the standard periapical. The endodontic fills may appear to be normal even though other clinical findings and symptoms are abnormal. The patient presents several months post root-canal treatment with pain on palpation and pressure and avoids this side of the mouth.

A periapical radiograph shows minimal pathology (Fig. 6). The roots appear to be filled and a small puff of sealer extends through the apex of the mesial roots. The distal root structure and fill appear normal. There is little indication of periapical radiolucency only a widening of the periodontal ligaments of the mesial roots.

A CBCT scan reveals a completely different picture. The coronal MPR reveals a short fill near the apex of the mesial lingual root and a large radiolucency (Figs. 7 & 8) not visible on the periapical radiograph (Fig. 6).

Missed canals are difficult to see in a buccal-lingual projection of the periapical radiograph as one canal is superimposed on the other (Fig. 9). Often, as viewed in this radiograph, we see periapical pathology with an apparent normally filled canal. CBCT scans allow dentists to look for pathology in MPR planes to identify the actual problem before invasive procedures are performed on the patient. The axial view shows a lingual canal exists and is untreated. The coronal view confirms the diagnosis and treatment can be completed (Fig. 10).

Today's endodontists, as well as general dentists, are benefiting from the diagnostic capabilities of

the high-resolution CBCT scanners available over conventional 2-D periapical.^{5,6}

Oral surgery

Oral surgery, with its inherent invasive nature, can be better served using CBCT with MPR as well as 3-D images. The ability to perform virtual surgery is a benefit to both the doctor and the patient. Doctors have the advantage of seeing morphology and landmarks in real time and space with accurate measurements, and patients will gain a better understanding of the problems and the solutions their doctors are offering them.

Third-molar extractions can be risky based on 2-D and panoramic radiographs. These radiographs can often superimpose nerves and sinuses over root structures. Dentists using 2-D radiographs must often rely on experience to assess the risks of iatrogenic trauma. The use of CBCT with MPRs and 3-D images reduces any guessing as well as the chance for any permanent damage to the patient. With the adoption of CBCT, the judgment is based on solid evidence and the risk will decrease.

A panorex of the superimposed third molars gave no solid evidence the canal lies between the roots. It is only with the use of CBCT and the MPRs that the nerve can accurately be seen traversing between the mesial buccal and mesial lingual root (Fig. 11).^{4,5}

Other surgical advantages include the identification and the position of supernumerary or impacted teeth. The images show accurate positions and show definitive morphology that will aid in removal of the proper teeth (Fig. 12). Knowing the exact position of many of these teeth is a benefit to both the doctor and patient. It will lead to the most precise surgical path and the least invasive procedure.

Periodontics

The explanation of periodontal problems are often misunderstood by the patient. As doctors we talk about

pockets, point to X-rays and propose treatment only to have patients refuse treatment because they do not understand what we are clinically describing. Using the 3-D portion of the CBCT scan can improve the understanding and acceptance of treatment plans. The images are a picture of the problem that is owned by that patient and much easier to understand by the layperson. Illustrating periodontal defects and pockets allows the patient to better participate in the process (Fig. 13).

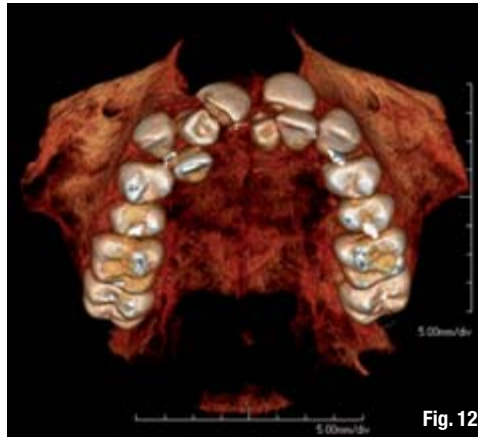

Fig. 12

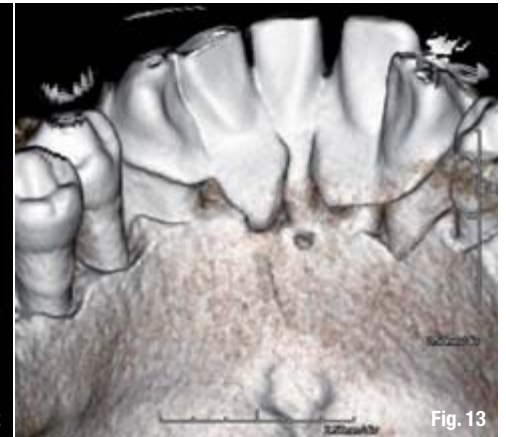


Fig. 13

The MPRs and the 3-D projections aid in surgical planning for periodontists, allowing for accurate measurements and bone analysis prior to osseous surgery that doctors cannot get using the periapicals or panoramics. Studies have shown that CBCT images are more accurate than panoramic radiographs. For the periodontist placing implants, the ability to measure bone density and avoid important anatomy is important.^{4,5}

_Orthodontics

Orthodontists are beginning to adopt large field-of-view CBCT. Recent studies show that linear measurements of bony structures are more accurate using CBCT and have less distortion than currently used methods of measurement: lateral cephalometric, posteroanterior (PA) and submentovertex (SMVT).⁵ Accurate measurements of tooth volume and tooth position can aid in accelerated treatment times and more precise treatment.

Along with tooth position, density of bone and size of arches, the orthodontist also has an accurate evaluation of the temporomandibular joint and position of the condyles. Impacted teeth are easily identified and position either buccal or lingual can be confirmed prior to movement or removal. Both MPRs and 3-D projections give the clinician a complete picture of the problems and the treatment course.

With a single CBCT scan, orthodontists can produce all of the information they need: panoramic, cephalometric, PA, SMVT, tooth size and volume, crowding evaluation in any plane, TMJ evaluation and airway analysis, all with both soft-tissue and skeletal information.^{5,7}

_Conclusion

We treat our patients in 3-D, and now, with cone beam computed tomography, we are changing the way we diagnose from 2-D to 3-D. The addition of this technology will increase your diagnostic

skills with better and more complete information at your disposal. As with any type of invasive diagnostic tool, clinicians should weigh the risk to benefit in using CBCT scans.

Judicious use of CBCT and knowledge of patient's lifetime doses should always be a consideration as well as the availability of other diagnostic tests appropriate for the problems of the patient. When adopting new technology, training is paramount. Along with training comes the responsibility of the doctor to read and diagnose information from CBCT scans.

Do not avoid CBCT from lack of knowledge; instead, take this opportunity to become a better diagnostician and radiologist. As you review radiology and pathology, your use of CBCT will aid in making the most accurate diagnosis and the most complete treatment plans.

Editorial Note: A complete list of references is available from the publisher.

_about the author

CAD/CAM



Dr Dan McEowen

is a 1982 graduate of Loma Linda School of Dentistry and has been in private practice for 26 years. He is a founding member of the World Clinical Laser Institute, achieving a mastership level of proficiency.

He has been active in FDA approval of oral surgery techniques using Erbium lasers. McEowen has lectured and trained internationally in techniques using lasers in general and specialty dental fields. He is a member of the ICOI and is active in implantology. McEowen has been involved in cone-beam technology for more than five years and owns 3D Imaging Center in Maryland.