

DENTAL TRIBUNE

The World's Dental Newspaper • Asia Pacific Edition

PUBLISHED IN HONG KONG

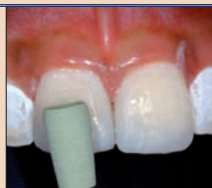www.dental-tribune.asia

No. 5 VOL. 9



Facial birth defects
Origins to be uncovered
by Nepalese teeth

▶ Page 3



Class IV restorations
Improved longevity
and aesthetics

▶ Page 10



Dental stem cells
An interview with
researcher Dr Mao

▶ Page 14

India to get stand-alone dental insurance

New oral health care scheme expected to be launched in June

Daniel Zimmermann
DTI

NEW DEHLI, India/HONG KONG/LEIPZIG, Germany: The Insurance Regulatory and Development Authority in India has approved a stand-alone insurance scheme that could help millions of patients throughout the country gain access to much-needed dental care, Indian newspapers have reported. The scheme, which is said to be implemented in June, will cover basic dental procedures, such as check-ups, fillings and extractions, as well as treatment for oral cancer.

Proposed by the Indian Dental Association in 2003, the plan has been under review since then. It has been announced that the General Insurance Corporation, an insurance company owned by the government, and three other public insurance companies will form part of the scheme. Two insurance options will be offered for a premium of Rs 1,000 (US\$22) and Rs 2,000 (US\$44) per year.

Currently, most dental fees in India are paid out of pocket and in-



An Indian girl smiling. Like millions of her countrymen she could soon benefit from a new dental scheme. (DTI/Photo Kailash K Soni)

urance is mainly offered through general health insurance, which often stipulates certain requirements, such as hospitalisation. Stand-alone dental schemes exist, for example, through private companies like Unilever but they are not utilised by the masses.

Dr Ravi Sher Singh Toor, a senior lecturer in the Depart-

ment of Pedodontics & Preventive Dentistry at Luxmi Bai Dental College & Hospital in Punjab, said that a good dental insurance scheme should include preventative services and give patients the freedom to choose their own dentist. They should also allow the option to refer the patient to a specialist, he added.

While the costs for basic dental procedures in India start from as low as US\$10, complex treatments like bridgework or implants can add up to US\$500. The average annual income in India dropped to approximately US\$1,200 last year, according to a recent study by the ET Intelligence Group consulting group. [DTI](#)

Geistlich takes over Korean distributor

The Swiss dental manufacturer Geistlich Pharma has announced that it has acquired 100 % of the shares of Jungsan Biomed, its current distribution partner in South Korea. The new company will be based in the capital Seoul and focus exclusively on the distribution of Geistlich's biomaterials for bone replacement and tissue regeneration in dental and cranio-facial surgery. Financial details were not disclosed.

According to a Geistlich representative, the Jungsan acquisition is one of the most recent steps in the company's long-term strategy for international expansion. It is also intended to strengthen the market presence in one of the most dynamic and competitive dental markets in Asia. The company will retain the staff and facilities of Jungsan Biomed in Seoul, the representative said.

GeistlichPharma is part of the larger Geistlich Group conglomerate, which includes activities in the production of adhesives, fat for animal feeds and real estate. Besides South Korea, the company also has a subsidiary in Beijing in China. [DTI](#)



In a study on animal teeth, Prof. Paul Sharpe (picture) and colleagues found that blood cells can trigger cell growth in teeth. (DTI/Photo KCL, UK) • WORLD NEWS, page 5

New hope for facial rehabilitation

An exercise programme involving devices used by dentists has shown prospects for the rehabilitation of facial nerve damage. The treatment uses an instrument associated with measuring tongue strength and the so-called Perry appliance to increase the strength of impaired facial muscle regions. [DTI](#)

Unilever to expand China business

Owing to its growth in emerging markets, Unilever, the Anglo-Dutch manufacturer of toothpaste and other consumer products, has announced to expand its business in China with a new production site. The plant will be located in Tianjin and have an annual production output of 100,000 tons. [DTI](#)

Bank report predicts new "Asian Century"

A new report released at the Annual Meeting of the Asian Development Bank in Vietnam has forecast that the region could account for half of the world's economic output by 2050, provided that it sustains growth and overcomes challenges like urbanisation and social well-being.

Under these assumptions, more than 3 million people could enjoy living standards comparable with those enjoyed by most Western countries today. Prospects are high for countries such as Vietnam, Thailand and Malaysia, according to the report.

Currently, the continent, led by high-income developed economies like China, Korea and Japan, accounts for 27 % of the world's economic output. [DTI](#)



Distinguished by innovation

We shape the future of dentistry with our innovative products and systems. They distinguish us – in the field of restoratives, all-ceramics and esthetic prosthetic solutions. A wealth of experience, great commitment and innovative ideas help us to always find the optimum solution for high-quality products that allow you to make people smile.

www.ivoclarvivadent.com

Ivoclar Vivadent AG
Benderstr. 2 | FL-9494 Schaan | Principality of Liechtenstein
Tel. +423 / 235 35 35 | Fax +423 / 235 33 60

ivoclar vivadent
passion vision innovation

AD

UPCOMING
WEBINARS



ADAC CERP
CONTINUING EDUCATION RECOGNITION PROGRAM

DENTAL TRIBUNE AMERICA IS AN ADA CERP RECOGNIZED PROVIDER

17 MAY
7 p.m. EST
CARIES MANAGEMENT USING S-PRG TECHNOLOGY

Dr. John Comisi

Participants will come to understand the pathologic process of caries, how bioactive materials help reduce the caries process and how S-PRG technology, a bioactive material, promotes oral health.

Gd 1h FREE Made available by: Shofu



REGISTER ON WWW.DTSTUDYCLUB.COM

14 JUNE
7 p.m. EST
ADVANCED SYNCHRONIZED ESTHETICS/PROSTHETICS IN CT GUIDED SURGERY

Daniel Llop, CDT

Digital sequential collaboration: It starts with the tooth and ends with the tooth. Participants will learn how to digitally plan, predict and maximize hard- and soft-tissue augmentation and esthetic and prosthetic consequence.

Gd 1h 95.00 USD



REGISTER ON WWW.DTSTUDYCLUB.COM

ON DEMAND
FEATURED ARCHIVE: BRILLIANT IMPLANT AESTHETICS

Dr. Paul Weigl

Participants will learn about innovative soft-tissue shaping and prosthetic socket preservation.

Im 1h 95.00 USD



REGISTER ON WWW.DTSTUDYCLUB.COM

BECOME A FREE MEMBER

WWW.DTSTUDYCLUB.COM

Australia commmits to dental health care reform, sets up taskforce

Daniel Zimmermann
DTI

HONG KONG/LEIPZIG, Germany: In a last minute effort to commit to dental health care reform, the Australian government has decided to provide additional funding of AU\$53 (US\$56 million) to public dental services over the next four years. The funding will be used to establish more dental internship programmes in order to reduce waiting times for dental treatment, government officials said in May. They also announced to set up a National Advisory Council on Dental Health to plan further steps to reform the inadequate public dentistry system.

The Greens have welcomed the commitment, which they see as a first step in long-term dental care reform. They reminded Labor that dental care also has to remain top priority in next year's budget. The coalition between both parties has struggled politically over the last two months regarding how much money should be spent to improve the country's poor public dental health care system. The Greens' promotion of a universal dental care scheme for all Australians was a key factor for forming a coalition with Labor in last year's federal elections.

In March, Labor Minister of Health Nicole Roxon announced that dental care funding would



Australia's Prime Minister Julia Gillard (second from left) inspecting damage during a recent visit to Japan. Australia's inadequate public dental health care system also needs her attention, dentists say. (DTI/Photo courtesy of ALP, Australia)

be scrapped altogether from this year's budget.

Dentistry representatives said that although the funding will help patients nationwide to access delayed dental treatment, it will probably not be enough to cut down waiting times, particularly in rural areas. In addition, the government should be focusing on ways to entice dentists to work in underserved areas like the South.

"Things like scholarships for dental graduates so that they're paid during dentistry and when they graduate they commit them-

selves to rural areas or relocation payments like the government has done for general practitioners," Dr Angela Pierce, President of the Australian Dental Association told the ABC News network.

Waiting times for public dental services in Australia have remained high over the last few years owing to the shortage of dental staff. According to a 2008 report by the Australian Institute of Health and Welfare, patients relying on public dental services are three times more likely to suffer from dental diseases such as caries or periodontal disease.

International Imprint

Licensing by Dental Tribune International		Publisher Torsten Oemus	
Group Editor/Managing Editor DT Asia Pacific	Daniel Zimmermann newsroom@dental-tribune.com Tel.: +49 341 48474-107	Copy Editors	Sabrina Raaff Hans Motschmann
Editors	Claudia Salwiczek Anja Worm	President/CEO	Torsten Oemus
Editorial Assistant	Yvonne Bachmann	Marketing & Sales	Peter Witteczek
International Editorial Board		Director of Finance & Controlling	Dan Wunderlich
Dr Nasser Barghi, Ceramics, USA Dr Karl Behr, Endodontics, Germany Dr George Freedman, Esthetics, Canada Dr Howard Glazer, Cariology, USA Prof. Dr I. Krejci, Conservative Dentistry, Switzerland Dr Edward Lynch, Restorative, Ireland Dr Ziv Mazor, Implantology, Israel Prof. Dr Georg Meyer, Restorative, Germany Prof. Dr Rudolph Slavicek, Function, Austria Dr Marius Steigmann, Implantology, Germany		Marketing & Sales Services	Nadine Parczyk
		License Inquiries	Jörg Warschat
		Accounting	Manuela Hunger
		Product Manager	Bernhard Moldenhauer
		Executive Producer	Gernot Meyer
		Ad Production	Marius Mezger
		Designer	Franziska Dachsel
Dental Tribune International Holbeinstr. 29, 04229, Leipzig, Germany Tel.: +49 341 48474-302 · Fax: +49 341 48474-175 Internet: www.dental-tribune.com E-mail: info@dental-tribune.com			

DENTAL TRIBUNE

The World's Dental Newspaper - Asia Pacific Edition

Published by Dental Tribune Asia Pacific Ltd.

© 2011, Dental Tribune International GmbH. All rights reserved.

Dental Tribune makes every effort to report clinical information and manufacturer's product news accurately, but cannot assume responsibility for the validity of product claims, or for typographical errors. The publishers also do not assume responsibility for product names or claims, or statements made by advertisers. Opinions expressed by authors are their own and may not reflect those of Dental Tribune International.

Regional Offices

Asia Pacific
DT Asia Pacific Ltd.
c/o Yonto Risio Communications Ltd, 20A, Harvard Commercial Building, 105-111 Thomson Road, Wanchai, Hong Kong
Tel.: +852 3115 6177 · Fax: +852 3115 6199

The Americas
Dental Tribune America, LLC
116 West 25th Street, Suite 500, New York, NY 10001, USA
Tel.: +1 212 244 7181 · Fax: +1 212 224 7185

Nepalese teeth to uncover origins of birth defects

Daniel Zimmermann
DTI

HONG KONG/LEIPZIG, Germany: The remote village of Jiri in Nepal is just a regular stop-over for trekkers on their way to Mount Everest. For Prof. Richard J. Sherwood from Dayton in the US, however, the small group of natives living there could hold the key to understanding the origin of common birth defects such as cleft lip or palate. In a field study, the anthropologist and biomedical expert is currently examining the teeth of hundreds of villagers, which, according to him, could explain why the early development of facial features can go seriously wrong.

The reason Prof. Sherwood chose such a remote place for his study was pragmatic. The population of Jiri has been part of several biomedical studies since the 1980s and, therefore, much of the groundwork, including genotyping by blood sampling, has already been done. In addition, the local ethnic group in Jiri, the Jirels, have a homogeneous diet and have never received orthodontic care, which are two factors important for studying natural variations in the craniofacial apparatus, Prof. Sherwood says.



Prof. Richard J. Sherwood examining a dental cast in the Jiri Dental Study lab.

In order to obtain data quickly, he set up a small dental clinic in the village in January last year, where local staff takes traditional dental casts and sends them to the US regularly. At Wright State University in Dayton, they are digitally scanned and examined further. Prof. Sherwood visits the site himself two or three times a year. According to him, there are over 15 people working on the project including a dentist, dental assistant and physician in Nepal. "Before we established the dental clinic, there was no local dentist and most people had never seen a dentist in their life," he says. "Participants are given a tooth cleaning and general oral exam as part of our study. We also provide some services, such as fillings, free of charge."

A pilot study back in 2005 produced 200 impressions, however, Prof. Sherwood told *Dental Tribune Asia Pacific* that he is aiming to take samples from at least one-fifth of Jiri's current population—about 1,500 people—until funding runs out in 2012. His study has received more than US\$2 million from the National Institute of Dental and Craniofacial Research, a US federal agency based near Washington, DC, and part of the National Institutes of Health, which supports research with the potential to improve oral, dental or cranio-facial health.

Prof. Sherwood intends to publish preliminary results next year. Through the study of normal variation, he hopes to determine the chromosomal regions that could explain why cleft palates develop differently, as well as gain new insights into other dental conditions, such as crowding.

According to the American Speech-Language-Hearing Association, one out of every 700 new-

borns (more than 6,000) in the US is affected by cleft lip and/or palate each year. In less developed countries like China, reports suggest that tens of thousands are affected, most of which are left untreated, leading to death or, in the majority of cases, lifelong impairments. Besides genetics, the condition has also been linked to the mother's poor health habits, such as smoking, or environmental factors, including exposure of

the foetus to drugs, pesticides or radioactivity.

"Abnormalities can be thought of as the extreme ends of the normal distribution in a trait but even relatively minor conditions, for example malocclusions, may have a significant impact on the psychological well-being of individuals if they feel self-conscious about how they look," Prof. Sherwood concludes. "If we are able to identify the genetic



Jiri is located in the Himalayas.

influences on normal variation it will, of course, have implications on the study of facial abnormalities." ■

AD

straumann

ROXOLID™

THE NEW "DNA" OF IMPLANT MATERIALS

ROXOLID™ – Exclusively designed to meet the needs of dental implantologists.

Roxolid™ offers ■ Confidence when placing small diameter implants ■ Flexibility of having more treatment options ■ Designed to increase patients' acceptance of implant treatment



VISIT STRAUMANN BOOTH AT A11 AND A13, HALL 3E AT HKIDEAS

9a.m.: "Surgical Site Assessment for Optimal Outcomes with Implant Therapy" &
2p.m.: "Bone Augmentation in Implant Therapy - Staged vs. Simultaneous Approaches"
By Dr Stephen Chen • 4 June 2011

www.straumann.sg

COMMITTED TO
SIMPLY DOING MORE
FOR DENTAL PROFESSIONALS

Dear reader,



Daniel Zimmermann
DTI


In contrast to their medical colleagues, dental stem cell researchers have been working 'under the radar' for quite some time. The recent conference on dental and craniofacial stem cells in New York could be the first sign that experts in this field have become fully aware of the potential regenerative technologies can hold for the future of dentistry and oral health.

With the current state of research, however, it will still take years, probably decades, before even first human trials will receive approval by regulatory agencies but help could come from the fact that dental stem cells hardly raise any ethical outrage, a discussion that commonly restricts research with stem cells derived from other sources like human embryos. So ironically, we might be able to see clinical applications in dentistry first before they are even introduced to general medicine.

Much will depend on the cooperation between the medical and dental field, as non-dental cells have been proven to be able to re-build tooth cells and vice versa. With the recent conference and another already on the horizon, dentists have definitely taken a giant leap. DTI

Yours sincerely,

Daniel Zimmermann
Group Editor
Dental Tribune International



A dental insurance for India



Dr Ravi Sher Singh Toor
India

Considering the growth of the Indian economy, prospects for dental insurance remain unexplored. Unlike most Western countries, specific dental insurance plans are not common and oral health insurance is usually integrated within general health insurance schemes. This type is provided by insurance companies as part of their own general health insurance schemes, such as a health advantage policy or student medical policy.

In a comprehensive survey of 3,120 people from all parts of Indian society, our department found that none of those sur-

veyed had any kind of dental insurance. This indicates the urgent need for such a scheme. Over three-quarters (78%) said that they would make use of dental insurance if offered, if the plan was suited to their needs. None of the respondents knew of a dental insurance company.

The Indian Dental Association has been trying to establish an all-inclusive dental health-care insurance scheme since 2005. Until now, however, the organisation had been unable to achieve anything substantial in this regard. Once introduced in June, the policy may not be well received, as there has been no advertisement campaign or press coverage of the scheme and no public announcements have been made.

If well received, the scheme may offer many benefits, such as

oral health-care workers being able to reach every class and village across the country. In addition, the scheme would serve as a good motivation to visit a dentist regularly and to complete their treatment, as they will not need to pay for further treatment.

If the government creates awareness of the benefits of dentistry for longevity of teeth across society, insurance policymakers should support it by offering beneficial dental insurance schemes for the masses. DTI

Contact Info

Dr Ravi Sher Singh Toor is Senior lecturer in the Department of Pedodontics and Preventive Dentistry at Laxmi Bai Dental College and Hospital, Patiala, India. He can be contacted at toor2k@gmail.com.

To the Editor

Re: "No-drill restorations and amalgam equally successful" (*Dental Tribune Asia Pacific*, Vol. 9, No. 1+2, page 5)

Mercury is toxic to poor and rich alike. The mercury in "silver" fillings is the largest contributor to the human body burden of this highly toxic heavy metal.

Dr Harold Loe, then Director of the National Institute of Dental Research in the US, stated in the 2003 September edition of the *Dental Products Report* that: "first filling is a critical step in the life of a tooth. Using amalgam for the first filling requires removing a lot of the tooth substance, not only diseased tooth substance but healthy tooth substance as well."

So, in making the undercut you sacrifice a lot, and this results in a weakened tooth. The next thing you know the tooth breaks off, and you need a crown. Then you need to repair the crown ... and so it continues to the stage where there is no more to repair and you pull the tooth.

With the first filling you should do something that can either restore the tooth or retain more healthy tooth substance. Use new materials-composites or materials you can bond to the surface without undercuts. You can do this with little removal of the tooth substance so that the core of the tooth is still there."

ART has been tested for years with excellent results. It is the answer to getting rid of amalgam even for the poor, despite the FDI and ADA claim that poor children will not have their cavities filled if mercury fillings are banned. ■

Bob Reeves, USA

AD

PROMEDICA

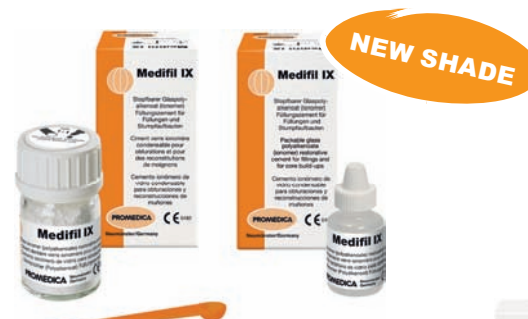Highest quality made in Germany

- ▶ high quality glass ionomer cements
- ▶ first class composites
- ▶ innovative compomers
- ▶ modern bonding systems
- ▶ materials for long-term prophylaxis
- ▶ temporary solutions
- ▶ bleaching products...

All our products convince by

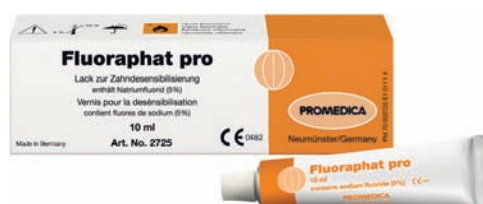- ▶ excellent physical properties
- ▶ perfect aesthetical results

Visit us at
SINO DENTAL 2011
Beijing
Booth G25
German Pavilion



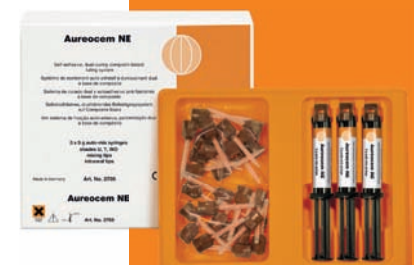Glass ionomer filling cement

- perfect packable consistency
- excellent durable aesthetics
- also available as application capsules
- now available in shade A2



Dental desensitizing varnish

- treatment of hypersensitive dentine
- fast desensitization
- fluoride release
- easy and fast application



Innovative luting system

- suitable for all material classes
- no etching and no bonding
- fast and easy cementation of endodontic posts
- dual-curing for flexibility and safety

PROMEDICA Dental Material GmbH
Tel. +49 43 21 / 5 41 73 · Fax +49 43 21 / 5 19 08
Internet: <http://www.promedica.de> · eMail: info@promedica.de

PROMEDICA

Blood vessel cells aid tissue repair in teeth

Daniel Zimmermann
DTI

NEWYORK, USA/LEIPZIG, Germany: New research presented at the recently held first International Conference on Dental and Craniofacial Stem Cells in New York in the US could mean a breakthrough in future tissue and organ repair. In an experiment involving incisors from rodents, a mammal species that includes mice

and squirrels, researchers from the UK, Brazil and the US found that connective tissue cells can transform into specialised cells to repair damaged tissue in teeth.

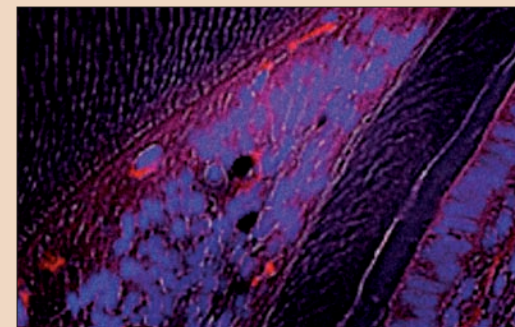
Their results have been published in the latest issue of *Proceedings of the National Academy of Sciences of the USA*.

Previous research suggested that so-called pericytes, usually

found in small blood vessels, have the potential to transform into different cells. This new study is the first claiming to have found genetic evidence that they can also act as stem cells to regenerate lost or damaged tissue. In the experiment, they were transplanted into the tooth, where they transformed into dental pulp cells.

“This is the first time perivascular cells have been shown to

differentiate into specialised cells during a natural repair process,” says Prof. Paul Sharpe from the Department of Craniofacial Development at the Dental Institute at King’s College London, who led the study. “In addition to the obvious significance for understanding the cellular mechanisms of tissue repair, it also has wider implications for areas of regenerative medicine/dentistry directed towards stimulat-



Blood vessel cells inside a tooth. (DTI/Photo Kings College London, UK)

ing natural repair following tissue damage or disease.” [DTI](#)

AD

US public dental care in poor state

From news reports

PENNSYLVANIA & CHICAGO, USA: US dentists are more likely to offer emergency dental care to children enrolled in private insurance schemes than those with Medicaid, the country’s health programme for the poor. These alarming findings are the result of an undercover study of 85 dental practices in the state of Illinois. Researchers at the University of Pennsylvania posed as mother of a fictional 10-year-old boy with an acute oral injury.

According to the study, only six dentists offered an appointment to children with public health insurance. All dentists offered an appointment to privately insured children. However, chances increased significantly when dentists were enrolled in Medicaid.

The findings confirm earlier studies that have painted a sad picture of the country’s dental health-care system for disadvantaged children. According to a 2010 study by the Pew Research Center, one in five children in the US lack access to dental care owing to low income and poor resources.

“Lack of funding is among the greatest barriers to better oral health in America. But funding alone will not ‘fix’ Medicaid. Patients need help navigating an often complicated bureaucracy and overcoming other barriers,” said Raymond F. Gist, President of the American Dental Association (ADA), commenting on the results of the study. “These programmes cannot reach their potential without other significant reforms. These include reducing unnecessary red tape for dentists and patients, and helping patients overcome such related barriers as the needs for transportation, child care or permission to take time off from school or work to receive treatment.”

The ADA has been lobbying for increased Medicare funding for years. The association recently launched a pilot programme to train health workers to provide treatment to people experiencing barriers to access of oral health-care services. [DTI](#)

new

Welcome to a new layer of expertise in dentine hypersensitivity

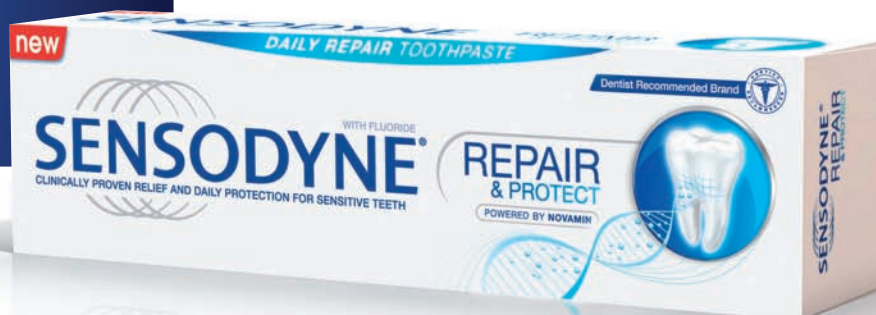Today you can go further than treating the pain of dentine hypersensitivity. Today you have new Sensodyne® Repair & Protect containing NovaMin® calcium phosphate technology. NovaMin® builds a reparative hydroxyapatite-like layer over exposed dentine and within the tubules¹⁻⁵

Starting to form from the first use,⁵ this reparative layer creates an effective and lasting barrier to the pain of dentine hypersensitivity⁶⁻⁸

Explore the new layer of opportunity with Sensodyne Repair & Protect



Visual representation of dentine cross-section and dynamic reparative layer



Specialist in dentine hypersensitivity management

References: 1. Burwell A et al. J Clin Dent 2010; 21(Spec Iss): 66-71. 2. LaTorre G, Greenspan DC. J Clin Dent 2010; in press. 3. Efflant SE et al. J Mater Sci Mater Med 2002; 26(6):557-565. 4. Clark AE et al. J Dent Res 2002; 81 (Spec Iss A): 2182. 5. GSK data on file. 6. Du MQ et al. Am J Dent 2008; 21(4): 210-214. 7. Pradeep AR et al. J Periodontol 2010; 81(8): 1167-1113. 8. Sallan S et al. J Clin Dent 2010; in press. SENSODYNE® and the rings device are registered trademarks of the GlaxoSmithKline group of companies. Prepared November 2010. Z-10-175.

Ortho-specialist appoints former J&J exec as CEO

Daniel Zimmermann
DTI

HONG KONG/LEIPZIG, Germany: Former Johnson & Johnson executive David N. Edwards will replace Dr Mervyn Fathianathan as CEO of BioMers, a Singapore-based company specialising in orthodontic appliances. Edwards, who has also worked for Bausch & Lomb and Nestlé, will take over the responsibilities

for the company's global business, starting immediately. Dr Fathianathan will remain Chief Technical Officer and oversee future development and research activities, the company said.

Founded in 2005, BioMers is a National



David N. Edwards (DTI/
Photo courtesy of Nano-start, Germany)

University of Singapore spin-off focusing on products based on polymer composite for biomedical applications. Their core products include the recently launched SimpliClear, a highly translucent customisable braces system, and an ortho-

dontic retention solution called ASTICS.

According to Dr Fathianathan, Edwards is expected to help the company expand into new markets. In his previous position as President of Bausch & Lomb's Asia-Pacific division, he managed several successful product launches in the ophthalmic market, Dr Fathianathan said.

BioMers currently distributes its products in Singapore and the US only. The company is partially owned by Nanostart, a German-based venture fund with representation in Singapore. [D](#)

New standard launched by ISO

From news reports

GENEVA, Switzerland: Around 1.5 million different medical devices are available worldwide. Every year, thousands of new products are launched. The International Organization for Standardization (ISO) has introduced a new International Standard that aims to assess the safety and performance of such devices and to improve patient safety.

ISO is a global network that identifies international standards that are required by businesses, governments and society. The non-governmental organisation develops these standards in partnership with the sectors that will put them to use, adopts them by transparent procedures based on national input and delivers them to be implemented worldwide.

According to ISO, the new standard ISO 14155:2011 will provide a technical basis for regulation and minimise technical barriers to trade. It was developed to encourage medical manufacturers to guarantee that their products do not compromise patient safety.

In 2007, the World Health Organization reported that more than one million accidents attributable to medical devices occur annually in the US. Furthermore, in some developing countries, half of the medical equipment was found to be unusable or only partly usable.

The new standard addresses good clinical practice for the design, conduct, recording and reporting of clinical investigations carried out on humans to assess the safety or performance of medical devices for regulatory and other purposes. This International Standard specifies general requirements intended to protect the rights, safety and well-being of humans and to ensure the scientific conduct of the clinical investigation and the credibility of the clinical investigation results.

The requirements are also intended to define the responsibilities of the sponsor and principal investigator, as well as assist sponsors, investigators, ethics committees, regulatory authorities and other bodies involved in the conformity assessment of medical devices. [D](#)

Experience peace of mind.

Rely on quality-assured and long-lasting restorations.

Select from a full range of high-quality biocompatible solutions.

Access tools for effective patient communication.



NobelProcera Implant Bridge

It's called NobelProcera. A single system that lets you provide your patients with individualized prosthetic solutions for every indication. Gain the peace of mind that comes with complete coverage including extensive warranty, quality assurance and material certification. Prescribe a wide selection of individualized restorations, all in biocompatible materials, that yield a consistent fit

and natural-looking esthetics. As a pioneer in CAD/CAM dentistry, NobelProcera uses innovative digital technology and centralized precision milling for tooth- and implant-based copings to full-arch bridges and implant bars. Partner with Nobel Biocare and make a real and lasting difference to the well-being of your patients. **Their smile, your skill, our solutions.**

nobelbiocare.com/digital



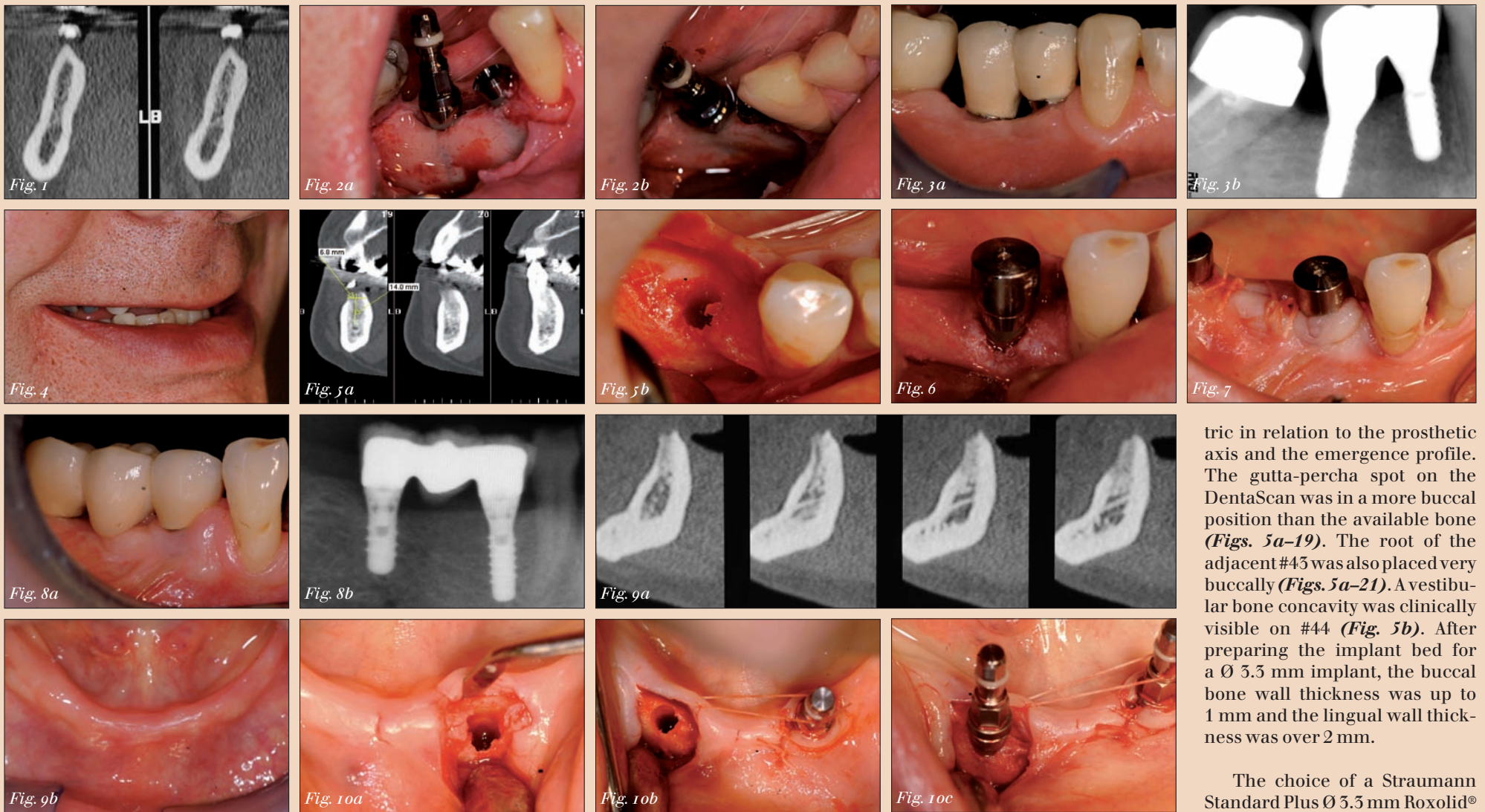
Nobel Biocare Asia Ltd. 14/F, Cambridge House, Taikoo Place, 979 King's Road, Quarry Bay, Hong Kong; Phone +852 2845 1266; Fax +852 2537 6604 3

© Nobel Biocare Services AG, 2011. All rights reserved. Nobel Biocare, the Nobel Biocare logotype and all other trademarks are, if nothing else is stated or is evident from the context in a certain case, trademarks of Nobel Biocare. Disclaimer: Some products may not be regulatory cleared/released for sale in all markets. Please contact the local Nobel Biocare sales office for current product assortment and availability.

AD

More flexibility and treatment options with Roxolid®

Straumann's small-diameter implants in clinical use



Dr Didier Blasé
Belgium

Narrow implants are very beneficial in reduced width crests, as they may avoid systematic horizontal bone augmentation if the remaining bone is in the correct prosthetic axis. Roxolid® small-diameter implants from Straumann also offer more flexibility and can provide dentists with new treatment options. Depending on the specific case, they can be placed more lingually or buccally than a regular implant which helps to adjust possible eccentricity of the remaining bone (see Case 2).

Originally, I did not use small-diameter implants frequently because I did not feel confident doing so, owing to the higher risk of fracture reported for narrow implants in the literature. Another concern was the reduced surface for osseointegration compared with regular-diameter implants.

The combination of higher strength and excellent osseointegration properties of Roxolid compared with the features of commercially available pure titanium implants gave me new confidence. Roxolid implants allow me to benefit from all the specific advantages of small-diameter implants but with the necessary degree of predictabil-

ity. In non-aesthetic regions, it may allow avoidance of GBR procedures and less time-consuming treatment.

Another reason was Straumann's approach in launching the product. I saw a slow and safe product introduction, based on extensive testing and clinical data. The strength of the material was proven by laboratory tests. Various clinical and pre-clinical studies ultimately convinced me. It will be interesting to observe the long-term behaviour of this new material and the clinical data it generates. We have to remain cautious, however, even if the results of the mechanical testing are very promising.

Case 1: Partially edentulous patient with a narrow bone ridge in a non-aesthetic zone (premolar)

Two implants had to be placed in positions #44 and #45. In the region of #45 there was sufficient bone height over the VIII canal. By contrast, the ridge width was very narrow (Fig. 1). An augmentation procedure was needed as a prerequisite for the placement of a regular-diameter implant (e.g. Ø 4.1 mm). In this case, the Ø 3.5 mm Roxolid® implants were a valuable alternative in order to use the existing bone substance better—particularly as the remaining bone

was in the right prosthetic axis. As there was not much space, the drilling had to be precise. The bone walls were very thin and the implant shimmered through slightly. A small dehiscence of 1 mm was visible at the buccal plate of #45 and #44, but it did not need any augmentation (Figs. 2a & b), as there was no aesthetic issue (Fig. 4).

The polished implant neck was intentionally placed above the crest in order to avoid bone loss around the neck. A two-element bridge was placed on the implants (Figs. 3a & b). The implant neck was slightly visible clinically on the vestibular side. The inter-implant papilla was absent. Even when the patient smiled broadly (Fig. 4), the border of the implant neck was not visible, as this region was hidden. It is very important to analyse the smile line of the patient before placing implants in this way.

In this case, Roxolid® allowed less complicated surgery to be performed by avoiding a larger augmentation in a non-aesthetic zone. The patient benefited from a shorter treatment time.

Case 2: Partially edentulous patient with eccentric bone

The X-ray measurement in region #44 showed a crestal width of over 7 mm. Therefore,

there was sufficient bone to place a Ø 4.1 mm implant. However, the bony substance was eccen-

tric in relation to the prosthetic axis and the emergence profile. The gutta-percha spot on the DentaScan was in a more buccal position than the available bone (Figs. 5a–19). The root of the adjacent #45 was also placed very buccally (Figs. 5a–21). A vestibular bone concavity was clinically visible on #44 (Fig. 5b). After preparing the implant bed for a Ø 3.5 mm implant, the buccal bone wall thickness was up to 1 mm and the lingual wall thickness was over 2 mm.

The choice of a Straumann Standard Plus Ø 3.5 mm Roxolid® implant instead of a regular-diameter implant allowed place-

→ DT page 9

AD

SIDEX 2011
Seoul International
Dental Exhibition
& Scientific Congress 2011

coex SEUL
JUNE 24-26, 2011

www.sidex.or.kr

81-7 Songjung-dong Sungdong-gu, Seoul 133-837, Korea
Tel : +82-2-498-9146 Fax : +82-2-498-9147
E-mail : sda@sda.or.kr URL : www.sidex.or.kr



W&H sterilizers created
for you!

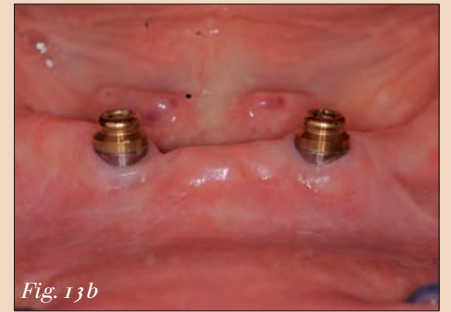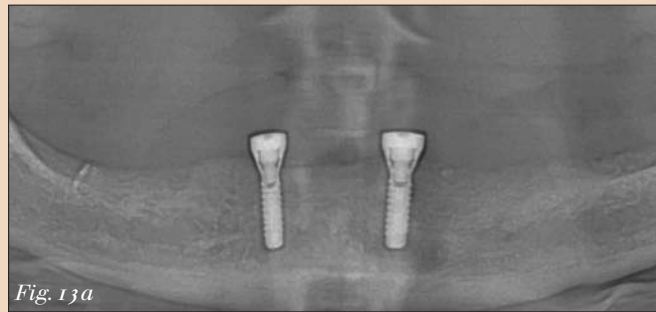
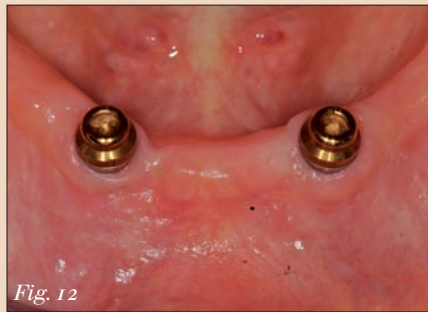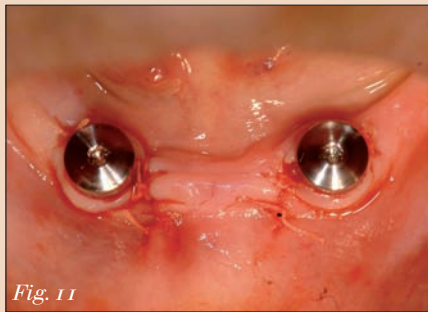


Lisa and Lina, two type-B sterilizers with one single aim:

to meet your needs and adapt to your practice requirements through Lisa's automatic traceability system and made-to-measure cycles, and the essentials of sterilization with Lina.

wh.com

Totally type B



← **DT** page 7

ment of the implant in an ideal position, particularly when anticipating the future prosthetic restoration and avoiding vestibular bone augmentation (Fig. 6). The small dehiscence of 2 mm was not compensated for. Thanks to an initial lingually displaced incision, a large and thick band of keratinised gingiva was preserved buccally (Fig. 7) at the end of the surgery to prevent further buccal recession of the gingiva. Prior buccal gingival recession on #45 could be observed. The preoperative scan (Figs. 5a-21) offered an explanation in form of a large bony dehiscence of the buccal plate on this tooth. The patient did not want any muco-lingival surgery for root coverage. Eight weeks after surgery, a three-unit premolar bridge was seated on implants at teeth #44 and #46.

A Roxolid® Ø 3.5 mm implant, in this case, made it possible to place an implant in an ideal position without performing an augmentation procedure, allowing for a less complicated surgical procedure. The patient received an aesthetic solution that would not have been recommended in the anterior aesthetic zone (teeth #15 to #25), where a bone augmentation procedure would have been a prerequisite.

Case 5: A bone-preserving solution for an elderly, fully edentulous patient

A fully edentulous 85-year-old patient was to be given an implant-retained removable denture. Two implants were to be placed inter-foraminally in the #43/42 and #33/32 regions. There was sufficient bone height, but the crest was very thin, which would have required a larger augmentation (bone block) or major grinding of the ridge (Figs. 9a & b).

The placement of Ø 3.5 mm implants allowed the vestibular dehiscence defect in region #33 to be limited to 3 mm (Fig. 10a) and to 1 mm in region #45 (Fig. 10b). Two small flaps were elevated in order to minimise the surgical trauma. Two Straumann Standard Plus Roxolid® implants (L 12 mm) were placed.

The initial lingually displaced incision preserved a nice amount of keratinised gingiva that was repositioned buccally around the polished implant necks and the healing screws (Fig. 11). After a six-week healing period, two LOCATOR® abutments were placed. The clinical check at three months showed good healing of the soft tissues,

with a thick and wide band of keratinised gingiva around the implants. The panoramic X-ray (Fig. 13a) demonstrated that

there was enough bony substance around the implants to prevent the risk of a mandibular fracture.

Even though there was sufficient bone height, the ridge was very thin in this case. Therefore, Roxolid® small-diameter

implants were a valuable solution in order to avoid a more traumatic and more invasive solution. **DT**

AD

POWERFUL BONDS

POWERFUL OPTIONS





VARIOLINK® N
The **ESTHETIC** dual-/light-curing luting composite system



MULTILINK® N
The **UNIVERSAL** self-curing luting composite with light-curing option



MULTILINK® SPEED
The **FAST** self-adhesive, self-curing resin cement with light-curing option



passion vision innovation

www.ivoclarvivadent.com

Ivoclar Vivadent AG Clinical
Bendererstr. 2 | FL 9494 Schaan | Liechtenstein | Tel.: +423 / 235 35 35 | Fax: +423 / 235 33 60

Ivoclar Vivadent Marketing (India) Pvt. Ltd.
503/504 Raheja Plaza | 15 B Shah Industrial Estate | Veera Desai Road, Andheri (West) | Mumbai 400 053 | India
Tel.: +91 (22) 2673 0302 | Fax: +91 (22) 2673 0301 | E-mail: india@ivoclarvivadent.com

Ivoclar Vivadent Marketing Ltd. Singapore
171 Chin Swee Road | #02-01 San Centre | Singapore 169877 | Tel.: +65 6535 6775 | Fax: +65 6535 4991