

# DENTAL TRIBUNE

—The World's Dental Newspaper • Middle East & Africa Edition—

PUBLISHED IN DUBAI

OCTOBER 2009

No. 4-5 Vol. 7




**Media CME**  
Peri-implant soft tissue  
recessions

► Page 6



**Middle East**  
2nd Qatar International  
Medical and Hospital Show

► Page 11



**News & Opinions**  
1 In 5 Kids Lack Vitamin D,  
Study Says

► Page 12

## India plans to overhaul dental education system



Dental graduates in India have trouble to find a career in dentistry. (DTI/Photo Michael Jung)

HONG KONG/LEIPZIG, Germany: The Dental Council of India has recently announced to introduce changes in the country's lacking dental education system. According to president Dr Anil Kohli who spoke to dental graduates of

the Sri Ramakrishna Dental College and Hospital in Coimbatore in September, the Council will look into the accreditation standards for graduate and postgraduate dental courses, as well as continuing dental education and clinical fellowship

programmes. Other issues including CE recognition in India and abroad will also be reviewed.

India has the largest number of dental schools and students in the world but the quality of den-

### Announcement

Dental Tribune Middle East & Africa (DTME) is moving into new office, please note our new telephone, facsimile and PO Box numbers:

Education Zone  
Knowledge village, Dubai  
Tel: + 971 4 391 0257  
Fax: + 971 4 3664512  
PO Box: 214592  
Dubai, UAE

tal education has gone down recently, especially in economically underdeveloped areas. In addition, a large number of graduates have to quit dentistry due to limited career options.

Dr Kohli said that the implementation of the changes will take several years to complete but they are needed to improve the quality of dentistry in the country and to attract more students from foreign countries. He also stressed the need for a national oral health policy.

"Our own figures show that only four to five per cent of the population visit a dentist. We'll have to look at this aspect as the next frontier of dental care in India if we are going to provide fruitful employment to our fresh graduates," he added. [DTI](#)

## Low doses of radiation can cause heart disease and stroke

A mathematical model constructed by researchers at Imperial College London predicts the risk of cardiovascular disease (heart attacks, stroke) associated with low background levels of radiation. The model shows that the risk would vary almost in proportion with dose. Results, published October 23 in the open-access journal PLoS Computational Biology, are consistent with risk levels reported in previous studies involving nuclear workers.

Cardiovascular disease is the leading cause of death and one of the leading causes of disability in developed countries, as reported in the paper and also by the World Health Organization (<http://www.who.int/whosis/en/>). For some time, scientists have understood how high-dose radiotherapy (RT) causes inflammation in the heart and large ar-

→ [DTI](#) page 3

AD

DTMEA 4+5/09

# PROMEDICA

Highest quality made in Germany

- high quality glass ionomer cements
- first class composites
- innovative compomers
- modern bonding systems
- materials for long-term prophylaxis
- temporary solutions
- bleaching products...

All our products convince by

- excellent physical properties
- perfect aesthetical results

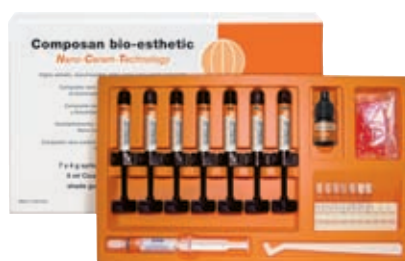**NEW at PROMEDICA**

New: Bleach Shade!



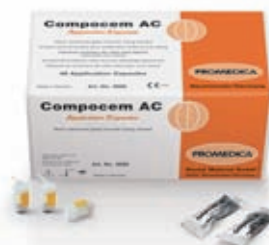**Temporary crown and bridge material**

- particular fracture and wear resistance
- now available in 6 attractive shades



**Light-curing nano-ceram composite**

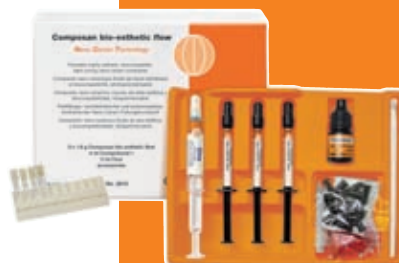- universal for all cavity classes
- comfortable handling, easy modellation
- highly esthetic and biocompatible



**Resin-reinforced glass ionomer luting cement**

- strong adhesion, very low film thickness
- especially suited for zirconia-based pieces

**Nano-Ceram-Technology**



• exact match of translucency and shade to the packable Composan bio-esthetic

**PROMEDICA**

**PROMEDICA Dental Material GmbH**

Tel. + 49 43 21 / 5 41 73 • Fax + 49 43 21 / 5 19 08

Internet: <http://www.promedica.de> • eMail: [info@promedica.de](mailto:info@promedica.de)



# Samsung Medical Center Signs agreement with INDEX Holding to open its first MENA Medical Center in Dubai

Dubai Health Authority – Government of Dubai Support the Agreement and Endorse the initiative

Dubai, UAE, 18 October 2009: INDEX Holding announced, during a press conference held today in Dubai Health Authority Head Quarter, signing an agreement with Samsung Medical Center with the support of Dubai Health Authority – Government of Dubai.

“We are delighted that Samsung Medical Center considers Dubai to be their first residence in MENA region and we welcome their presence in UAE. We extend our support to the agreement signed today between INDEX Holding and Samsung Medical Center and we consider this step as an addition to Dubai’s unremitting achievements in the medical sector. We highly appreciate the constant contribution of INDEX Holding in attracting foreign investment to UAE through the organization of prominent medical exhibitions and conferences such as FDI and IHF World Congress 2011 in addition to more than 12 annual leading conferences in cooperation with Dubai Health Authority. Dubai government highly encourages the private sector to invest in the medical sector, and Dubai Health Authority also considers the private sector to be its strategic partner in providing the best health services in UAE” said Qadi Saeed Al Murroshid, Director General of Dubai Health Authority.



Since initiating Korea’s first medical referral system in 1995, Samsung Medical Center currently maintains Korea’s largest medical cooperative network that includes some 70 cooperative hospitals and 700 member clinics. With more than 10,000 personnel including 5,000 medical professionals, Samsung Medical Center is one of the largest advanced medical complexes. Also as a designated teaching hospital for Sungkyunkwan University School of Medicine, Samsung Medical Center produces outstanding future leaders in healthcare.

“We would like to thank the government of Dubai, Dubai Health Authority and Index Holding for giving us the opportunity to introduce and promote the

high state of our healthcare services to the region in Dubai, the city that represents quality of life. The agreement is a culmination of the forward-thinking leadership of Dubai government, a determination by INDEX Holding, and world class medical capabilities of the Samsung Medical Center, and will provide a new ground not only for strengthening healthcare status of both countries, but also for enhancing health and welfare of the Middle East and North Africa. We will also welcome the patients to be treated in our advanced medical centers in Korea. In addition to Dubai’s strategic position in the region, we will also benefit from the integrated infrastructure of its medical sector and the facilities provided by the government”

said Jong-Chul Rhee, President & CEO, Samsung Medical Center

Since Samsung Medical Center opened its Comprehensive Cancer Center with 700 beds, Asia’s largest in size, in 2008, it has performed some 1,900 gastric cancer and 1,600 colorectal cancer operations. This year, Samsung Cardiovascular Imaging Center in Collaboration with Mayo Clinic began its operation, introducing a new concept in providing healthcare services to patients with complex cardiovascular diseases. Also, the quality of care in liver transplant and extremely low birth weight infant patients, along with others, well exceeds those in developed countries.

“During our last visit to Seoul, we have initially signed the MOU

with Samsung Medical Center to be the sole representative of Samsung Medical Center in the region and we are pleased to sign the agreement today with the support of Dubai Health Authority as a strategic partner. “Index and Samsung Medical Center agreement” will not only provide unique and active services to UAE citizens and residents but will also be of great benefit to the MENA region at large. We at Index Holding consider our growth as a part of UAE’s national economic growth and feel responsible of being pioneers in the health sector. This was not to happen without the constant support of Dubai Health Authority and other governmental sectors in the UAE” said Abdul Salam Al Madani, President of Index Holding. [DI](#)

## Root Canal Treatment Made Easy

Region’s dentists to learn new techniques from international experts at Dentistry 2009

Dubai, According to a recent survey by the American Association of Endodontists (AAE), fear of dentists plagues more than 80 per cent of us. Root canal procedure is the most feared treatment with 54 per cent of adults as afraid of getting a root canal as they are of flying during a storm.

Any procedure that can make root canal treatment quicker or less painful has to be good news for everyone. At Dentistry 2009, a multi-track conference and exhibition, the region’s dentists will be learning how to perform a successful root canal treatment in less than 45 minutes, saving patients time, stress and discomfort.

The new treatment will be presented by Dr Ahmet Utkut Ozan, Executive Director of Maxim Dental Institution in the USA and key speaker at the conference. Dr Ozan has been selected as one of the ‘Top Hundred Clinicians’ in the USA for the past three years and his popular ‘proven methods’ in Endodontics have been presented within the

USA and internationally. At Dentistry 2009 he will be running the workshop “A Recipe for Successful Molar Endo in under 45 minutes”, a technique many dentists will be keen to learn in order to offer their patients the most up-to-date care techniques.

“The best part of my lecture series is the workshops,” says Dr Ozan. “My focus is to teach attending dentists completely new techniques, utilising proven older technology covering topics such as activated irrigation, intra canal aspiration and troubleshooting in endodontics.”

Dr Ozan is honoured to be elected as a top hundred clinician in the USA, especially since he originally trained in his home country of Turkey. “I believe that the Western dental world has a lot to learn from Eastern dental professionals,” he explains. “As a Middle Eastern dentist I love visiting the region, particularly the UAE, and enjoy the scientific sessions which are well organised and up-to-date.”

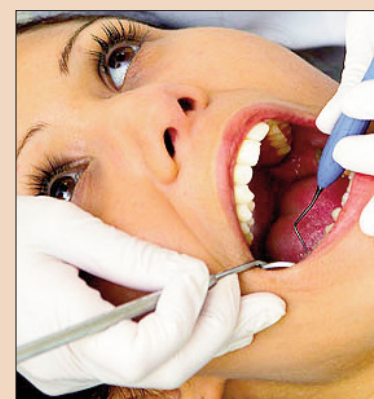
In addition to Dr Ozan’s lecture series, the list of speakers at Dentistry 2009 includes over 30

of the leading experts in the field of dentistry. Attendance at a lecture or workshop will carry CME (Continuing Medical Education) credits highlighting the educational significance of the event.

“With five IDR award winning presenters amongst others, top notch leaders in each discipline of dentistry and world renowned speakers all under one roof, Dentistry 2009 is a gathering you

wouldn’t want to miss,” emphasised Raza Chevel, Conference Producer - Exhibitions, IIR Middle East, UAE.

Crafted by IIR Middle East Life Sciences, the organisers of the annual Arab Health Exhibition & Congress, Dr Ozan’s lecture series will be running at Dentistry 2009 from 10 to 12 November at the Abu Dhabi National Exhibition Centre, UAE. [DI](#)



<b>DENTAL TRIBUNE</b> <small>The World's Dental Newspaper - Middle East &amp; Africa Edition</small>		<b>President/CEO</b> Yasir Allawi <a href="mailto:y.allawi@dental-tribune.ae">y.allawi@dental-tribune.ae</a>
<b>Published by Venus Advertising</b> <small>in licence of Dental Tribune International GmbH</small> © 2009, Dental Tribune International GmbH. All rights reserved. <small>Dental Tribune makes every effort to report clinical information and manufacturer's product news accurately, but cannot assume responsibility for the validity of product claims, or for typographical errors. The publishers also do not assume responsibility for product names or claims, or statements made by advertisers. Opinions expressed by authors are their own and may not reflect those of Dental Tribune International.</small>		<b>Director mCME:</b> Dr. D. Mollova <a href="mailto:info@cappmea.com">info@cappmea.com</a>
		<b>Marketing manager</b> Sawzan Alhalwachi <a href="mailto:info@dental-tribune.ae">info@dental-tribune.ae</a>
		<b>Production manager</b> Hussain Alvi <a href="mailto:hussain.alvi@dental-tribune.ae">hussain.alvi@dental-tribune.ae</a>
		<b>Postal Address:</b> P.O. Box 214592, Dubai, UAE Tel- 009714 5910258 Fax- 009714 5664512
<b>Editorial Board</b>		
Dr. Abdel Salam Al Askary, Implantology, Egypt Dr. Talal Al-Harbi, Orthodontist, Qatar Dr. Mohammed H. Al Jishi, Bahrain Dr. Lara Bakaeen, Prosthodontist, Jordan Dr. Abdullah Al-Shammari, Restorative Dentistry, KSA Dr. Aisha Sultan, Periodontist, UAE Dr. Kamal Balaghi Mobin Aesthetics, Iran Prof. Hussain F. Al Huwaizi, Endodontics, Iraq		



# Sharjah Women's College Mobile Health Clinic is ready to roll again

Sharjah, (WAM)--The Mobile Health Van will be launched again in the academic year 2009-2010, starting from October 16th, following success and warm welcome by all schools it visited in Sharjah and Ajman over the academic year 2008-2009.

Scoring tremendous success in this unique experiment, the mobile health van, w which was started by a team of dedicated health sciences students, is ready once more to reach as far as it can into the community.

The month of November will also see the mobile clinic coordinate its activities with Dubai Health Festival, which is being organized by Dubai Healthcare City to maximize their outreach and provide the students an opportunity to learn from the expertise offered by the DHCC staff.

The health awareness campaign has been a useful experiment in getting senior health sciences students to step out into the community and share their knowledge and polish their newly learnt medical skills The

→ [DT](#) Page 1

teries and how this results in the increased levels of cardiovascular disease observed in many groups of patients who receive RT. However, in the last few years, studies have shown that there may also be cardiovascular risks associated with the much lower fractionated doses of radiation received by groups such as nuclear workers, but it is not clear what biological mechanisms are responsible.

The Imperial College London team, led by Dr. Mark Little, has explored a novel mechanism that suggests that radiation kills monocytes (a type of white blood cell) in the arterial wall, which would otherwise bind to monocyte chemo-attractant protein 1 (MCP-1). The resultant higher levels of MCP-1 cause inflammation which leads to cardiovascular disease. As well as being consistent with what is seen in nuclear workers, the changes in MCP-1 caused by dietary cholesterol that are predicted by the model are also consistent with experimental and epidemiologic data.

If the mechanism is valid it implies that risks from low dose radiation exposures (e.g., medical and dental X-rays), which until now have been assumed to result only from cancer, may have been substantially underestimated, say the authors.

The biological mechanism has yet to be experimentally tested. Further research is planned to investigate this. [DT](#)

team has planned a detailed program of workshops and lessons on personal hygiene, dental health, H1N1 awareness, anemia, diabetes, good nutrition; these workshops will be supplemented with basic testing that in-

cludes blood glucose, hemoglobin, BMI measurements.

The eager students have thoroughly enjoyed learning the basics of good health and hygiene in a fun way from their equally ea-

ger to impart elder national sisters. An activity that generated much enthusiasm in the previous run was the 'Glo germs', a fluorescent dye that makes the germs on the hands glow under the UV light. The young faces

were horrified to see the bugs on their hands and the message of hand washing' surely hit the mark. With the world battling the H1N1 pandemic this activity will surely help the efforts of the Ministry of health to contain this [DT](#)

AD

NEW

iso-active

FOAMING GEL

EXPERIENCE NEXT GENERATION TOOTHPASTES

ALL-ROUND PROTECTION AND SENSITIVITY RELIEF

iso-active™  
FOAMING GEL

Patented breakthrough iso-active gel to foam technology

Thoroughly cleans hard to reach areas while protecting teeth and providing all-round sensitivity relief

Multi Action

SENSODYNE®  
DAILY TOOTHPASTE FOR SENSITIVE TEETH

Whitening

SENSODYNE®  
DAILY TOOTHPASTE FOR SENSITIVE TEETH

SENSODYNE®

DAILY TOOTHPASTE FOR SENSITIVE TEETH





# Implanted eye tooth helps blind patient see again

## First osteo-odonto-keratoprosthesis procedure performed in the US

MIAMI, FL, USA: A 60-year-old patient from the US has recovered her sight after surgeons in Miami implanted one of her teeth in her eye. This surgical procedure was a first in the US and undertaken at the Bascom Palmer Eye Institute at the University of Miami's Miller School

of Medicine, where the patient's eye tooth was implanted as a base to hold a prosthetic lens. The patient was blinded in 2000 by the effects of Stevens-Johnson syndrome, a severe adverse reaction to common drugs, causing burning, blistering and sloughing of skin and involved

tissue. It also frequently causes blindness, and results in 100,000 deaths per year worldwide.

Dr Victor L. Perez, Associate Professor of Ophthalmology at the Bascom Palmer Eye Institute, and his interdisciplinary team performed a modified osteo-odonto-keratoprosthesis

(MOOKP) procedure, a complex surgery that had until now been available only in a limited number of eye centres in Europe and Asia. Developed by the Italian ophthalmologist Prof. Benedetto Strampelli in the 1960s, MOOKP has proven effective as a solution to end-stage

corneal disease, in which severe corneal scarring blocks vision and corneal transplants are no longer an option but the eye's internal structures and optic nerve remain healthy.

"For certain patients whose bodies reject a transplanted or artificial cornea, this procedure 'of last resort' implants the patient's tooth in the eye to anchor a prosthetic lens and restore vision," explained Dr Perez.

In MOOKP, an extracted tooth and surrounding bone are shaved and sculpted, and a hole is drilled to insert an optical cylinder lens. In order to bond the tooth and lens as a bio-integrated unit, they are implanted under the patient's skin in the cheek or shoulder. The eye specialist then prepares the surface of the eye for implantation of the prosthesis, by removing scar tissue surrounding the damaged cornea.

About one month later, mucous material is collected from the inside of the patient's cheek and used to cover and rehabilitate the surface of the damaged eye. In the final phase, the prosthesis is removed from the cheek or shoulder and implanted in the eye. The prosthesis is aligned with the centre of the eye, and a hole is made in the mucosa for the prosthetic lens, which protrudes slightly from the eye and enables light to enter the eye, allowing the patient to see again.

"The procedure will help countless of people in the US to regain sight," said Dr Eduardo C. Alfonso, chairperson of the Bascom Palmer Eye Institute. "Thanks to the work of Dr Perez's team, patients in the US now have access to this complex surgical technique." [\[1\]](#)

## Laser dentistry gets boost in India

The local government of Gujarat, a federal state in Western India, has announced a new initiative to incorporate laser dentistry into the dental curriculum of all governmental dental colleges. The move comes after a clinical guide for oral laser applications was released at the 3<sup>rd</sup> National Conference on Oral Laser Applications held in Ahmedabad earlier this month.

According to Gujarat Health Minister Jaynarayan Vyas, the project will be supported by the Society for Oral Laser Applications, an affiliate organisation of the International Society for Oral Laser Applications in Vienna (Austria). If the initiative succeeds, government authorities expect to appoint dental laser specialists in each of the state's districts soon. [\[2\]](#)

AD

## Europe/Mediterranean Master Program in Implantology

gIDE / UCLA

1 year Master Program 2009/10

Course Director  
Dr. Sascha Jovanovic  
Los Angeles, California  
Periodontist



214 hours/ 17 days of clinical training in 4 sessions.

60 hours/ 4 modules of e-learning curriculum from world renowned clinicians and scientists.

3 hands on workshops and 14 Live Surgery demonstrations.

8 exam assessments.

12 Hours of video surgery on iPod touch 32GB (Apple).

2 case presentation, 5 reviewed by faculty

### Session I

2009, November 18-21  
Days 1, 2, 3 and 4  
in Athens, Greece

### Session II

2010, February 17-20  
Day 5, 6, 7 and 8  
in Athens, Greece

### Session III

2010, May 19-22  
Day 9, 10, 11 and 12  
in Athens, Greece

### Session IV

2010, Aug 30 - Sep 3  
Day 13-17  
in Los Angeles, USA

There is no training similar to this 1 – year Certificate Program in Implant Dentistry with a didactic, a hands – on program and live surgery from the worlds leading clinicians and educators.

- Between session 1 and 2 e-learning (A-Z in Implant Dentistry / 24 hours course followed by exams)
- Between session 2 and 3 e-learning (Advanced Implant Therapy / 24 hours course followed by exams)
- Between session 3 and 4 e-learning program (Esthetic Implant Dentistry and New Advances / 12 Hours course followed by exams)

#### SPONSORS



#### ORGANIZED BY



Course fee: 11.900 €

Initial deposit payable upon registration EUR 1.000

1st payment EUR 4.900, before 3rd Oct '09

2nd payment EUR 3.000, before 3rd Jan '10

3rd payment EUR 3.000, before 4th Apr '10

For More Information and To Register Contact:

Lito Christophilopoulou

+30 210-21 32 084 & +30 210-22 22 637,

Fax: +30 210-22 22 785

e-mail: mp-mediterranean@gidedental.com

website: www.omnipress.gr

website: www.gidedental.com



2010

4-6 May

YOUR HOSPITAL SHOW REFERENCE



2<sup>nd</sup> Qatar International Medical & Hospital Show

Qmedic

Qhealth

Qpharma

Qlab

Qdental

Qhospi

Qophthal

[www.qmedic.net](http://www.qmedic.net)


For further information & sponsorship opportunities please contact the organizer

P.O.Box 22679 , Doha-Qatar  
Tel. +974 444 22 70/71, Fax. +974 442 28 38  
E-mail: [qmedic@conexqatar.com](mailto:qmedic@conexqatar.com) [www.conexqatar.com](http://www.conexqatar.com)



كونيक्स لتنظيم وخدمات المعارض والمؤتمرات  
Expos, Conferences, Organizing & Services





# Peri-implant soft tissue recessions

By Dr. André P. Saadoun, D.D.S., M.S.

The article has been accredited by Health Authority - Abu Dhabi as having educational content and is acceptable for up to 2 (Category 1) credit hours. Credit may be claimed for one year from the date of subscription.

## Introduction

A beautiful aesthetic result is difficult to obtain with implants in the anterior areas. Both the alignment of the gingival margin and the presence of papillae are essential elements in resolving aesthetic implant problems to achieve an harmonious smile. These two soft tissue entities, however, are closely related to the patient's biotype and to the quality/quantity of underlying structural alveolar bone.

The peri-implant gingiva, particularly if it is narrow, with a thin-scalloped biotype, inevitably retracts six months after the abutment connection and restoration, owing to the reformation of the biologic space (Small and Tarnow, 2000).

The process of soft and hard tissue healing must be understood and incorporated into a carefully coordinated sequence of therapy. It is also important to identify complications and clinical mistakes and their implications on the final aesthetic outcome (Saadoun et al, 1999).

How, then, should soft tissue recession (bone and gingiva) around an implant be prevented or treated?

## Prevention of peri-implant recession

Marginal bone loss of 1 mm in the first year following the abutment connection, followed by loss of 0.2 mm per year, were among the criteria

defined for implant success (Albrektsson et al, 1986). Saving a few tenths of a millimetre of bone around an implant does not increase the longevity of the implant, and should be done only for aesthetic reasons. To prevent or to decrease peri-implant bone resorption and consequent gingival recession following implant restorations in the anterior zone, several strategies have been suggested, which are explained in detail in the following points.

### 1) Implant design and diameter

The design of the collar of the implant should stabilize the crestal bone by bringing the roughened surface right up to the platform, and the threads/microgrooves as close as possible to the platform, with no divergence of the collar walls.

The thread position of the implant determines the effective level of remodelling after loading, and this is perhaps even more important than the position of the implant abutment microgap. (Rompen et al., 2003).

Placement of the implant platform 1.5 mm above the bone, helps to minimize bone loss as the biological space around the implants is established on the collar (Lezly Miller, 2005).

### 2) Implant placement and extraction timing

To make the best choice between

different alternatives of implant placement, a precise pre-surgical diagnosis is necessary in order to evaluate the gingivo-osseous parameters, to determine the optimal moment to extract the tooth and place the implant, and to decide whether implant placement and loading should be immediate, early or delayed (Saadoun and Landsberg, 1997).

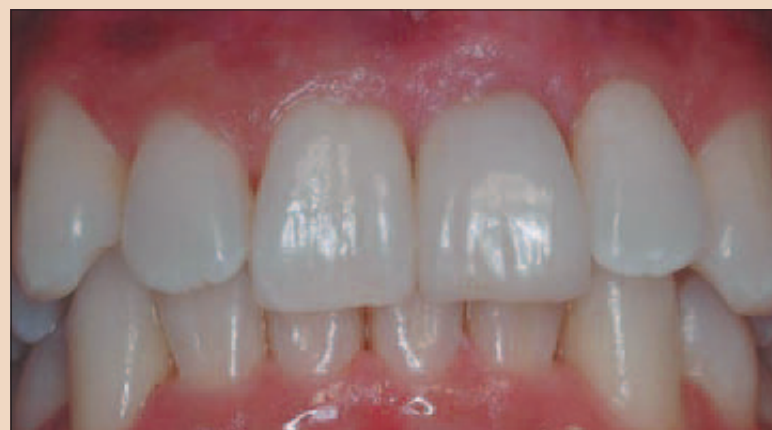Orthodontic treatment is the best solution for patients who wish to limit the surgery required for the placement of implants to a single session, and to enhance the hard and soft tissue profile prior to extraction and implant placement (Salama et al, 1993).

### 3) Flap design

On healed site the limited flap design minimizes inter proximal bone and papillae loss. Many flap design have been described for healed sites, some raising the total inter proximal papillae with sulcular incision around adjacent teeth, others using mid-crest/palatal crest incision with sulcular envelope flap and, finally, tissue punch flap recommended in large amount of keratinized gingiva.

Flapless approach using tissue punch procedure has many advantages: less trauma to the bone and disturbances to the soft tissue stability, reduction of pain and oedema, and less post surgical information.

Immediate implant place-



Smile aspect 6 months later

ment after extraction is usually a flapless surgical procedure, the extraction being done using a periosteal elevator to minimize traumatic damage to the hard and soft tissues.

### 4) Tridimensional implant placement

Satisfactory morphology of the papilla and of the gingival margin after anterior implant restoration depends ultimately on two factors: implant placement (Esposito et al, 1993, Saadoun et al, 1998, Jovanovic, 1999, Grunder et al, 2005) and implant restoration.

The tridimensional criteria for implant placement in the aesthetic zone are:

- **Mesio-Distal:** 1.5-2mm between implant and adjacent tooth 3.5-4mm between implant and adjacent implant
- **Bucco-Lingual:** 2.5-3mm from the cervical height of contour of the adjacent teeth to the buccal surface of the implant platform.
- **Corono-Apical:** 2.5-3mm apical to the bucco gingival margin depending on the biotype

Therefore, if immediately post extraction implant placement is indicated, the osteotomy must be performed

against the palatal wall to prevent any damage to the remaining (and usually thin) buccal cortical bone (Testori, 2003).

### 5) Connective osseous grafts

An autogenous bone and xenograft with a membrane is used to gain buccal thickness knowing that bone resorption/gingival recession always occurs after extraction/implant placement.

Gingival biotype plays an important role in determining tissue levels achieved around implants. A thin biotype is generally more susceptible to peri-implant recession, induced by the resorption of a thin labial cortical plate. The use of osseous and connective grafts converts a thin gingival biotype into a thick gingiva (Mathews, 2000), which can enhance gingival marginal stability and simplify tissue management during the restorative treatment phase.

### 6) Abutment and restoration

Optimal aesthetics will be promoted if the final abutment is installed at the time of implant placement, and left in place undisturbed, throughout the final restoration phase, avoiding disturbance of bone and soft tissue architecture.

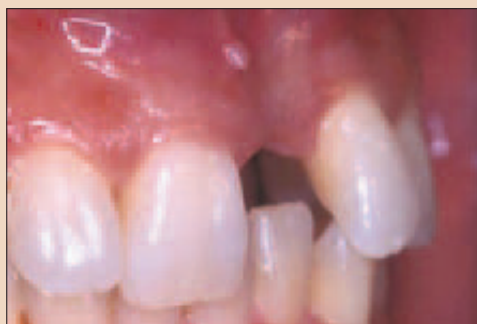

Fig. 1: Deformed ridge following traumatic extraction (right view)

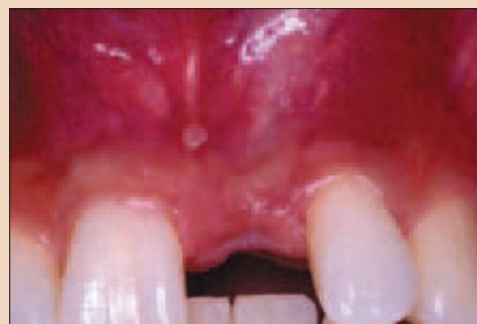

Fig. 2: Deformed ridge following traumatic extraction (central view)

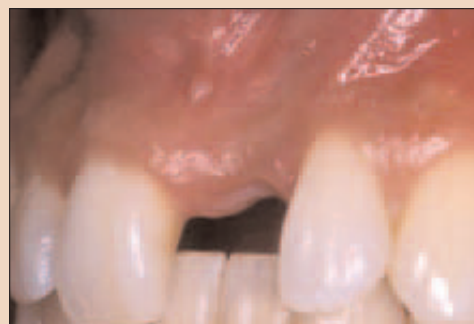

Fig. 3: Deformed ridge following traumatic extraction (left view)

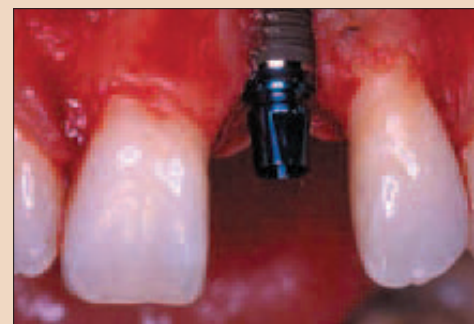

Fig. 4: Implant insertion after flap elevation

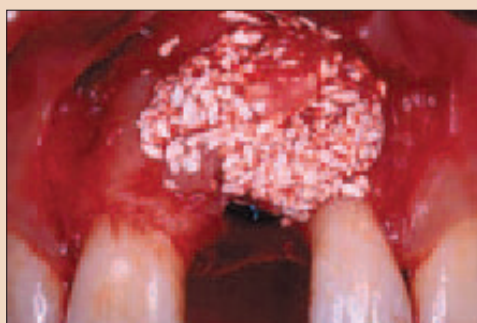

Fig. 5: Bio-Oss graft combined with PRF particulates

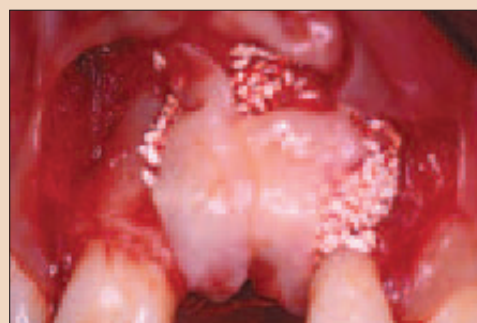


Fig. 6: Implant and graft covered with PRF membrane

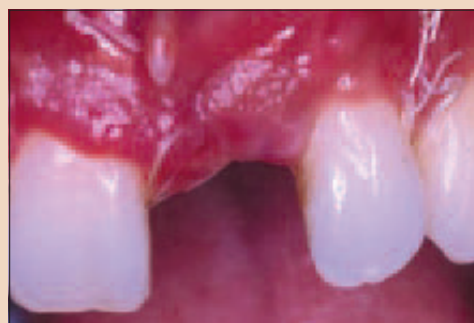

Fig. 7: Coronally advanced flap (frontal view)

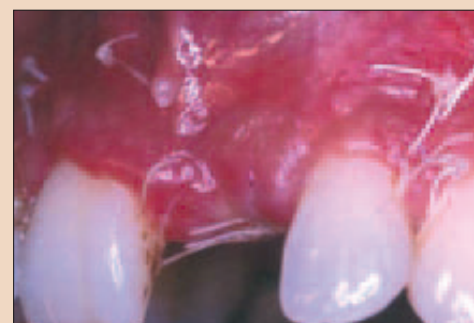

Fig. 8: Coronally advanced flap (left view)



(Rompen *et al*, 2003). Disconnection and reconnection of the abutment disrupts the biologic zone, inducing the junctional epithelium to migrate apically beyond the implant-abutment junction until it can adhere again. This often results in marginal bone loss, particularly in cases of thin gingival biotype.

It is important to minimize the bacterial contamination in and around the implant-abutment junction. The seal provided by an abutment of locking-tapered design has been demonstrated to be optimal in this respect, in vitro (Dibart *et al*, 2005).

Implant abutments of gold or glazed ceramic should be avoided. Only titanium or zirconium abutments are recommended because hemidesmosomes have been shown to attach to them (Touati and Guez, 2002).

In order to retain soft and hard tissue around the implant/-abutment connection, the transmucosal aspect of the implant abutment should not be oversized and divergent, but rather narrow and concave in order to induce thickening and immobilization of the peri-implant tissues, thus increasing the interface between the implant and the soft tissue, and creating an "O-ring connective tissue". This will ensure the long-term stability of the biological width (Rompen *et al*, 2007).

Beneath the restoration, the concave abutment should provide maximum space to the soft tissue and clearly avoid a flared geometry. Its submerged profile should be negative to avoid compression of and to allow maximum thickness and stability of the soft tissue, as well as more room for the biologic width (Touati 2004). On the buccal aspect, the emergence profile of both the provisional and the final restorations should be flat or concave (under-contoured), to minimise pressure-induced apical migration of the gingival margin.

Design of final crowns to comply with the following "norms" will go a long way toward optimising papillary form (Salama *et al*, 1999; Elian *et al*, 2002):

- Distance from interdental bony crest to contact point between natural crown and implant-borne crown: 4.5 mm
- Distance from inter-implant bony crest to contact point between two implant-borne crowns: 3.4 mm
- Distance between bony crest and connection point between an implant-borne crown and a pontic: 5.5 mm

#### 7) Occlusal trauma

It has been proven that an excessive occlusal load during

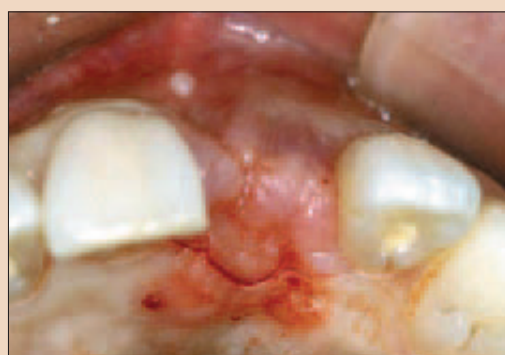

Fig. 9: Flap design before implant exposition

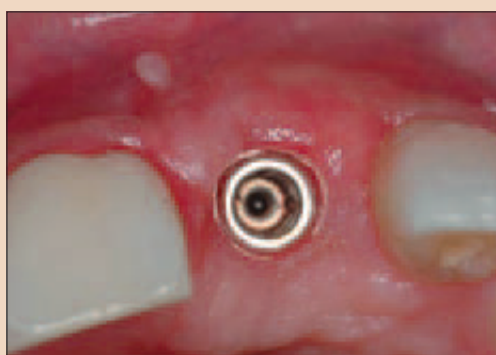


Fig. 10: Soft tissue aspect 4 weeks after implant exposition (occlusal view)

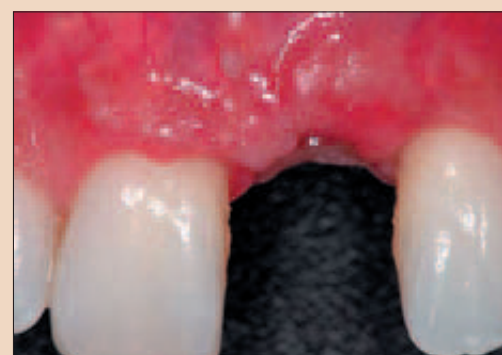

Fig. 11: Soft tissue aspect 4 weeks after implant exposition (frontal view)

## 4<sup>th</sup> CAD/CAM & Computerized Dentistry International Conference

13-14 May 2010, Dubai  
The Westin Hotel

*The new era in Dentistry*



- \* CAD/CAM in Aesthetic and Prosthetic Dentistry
- \* CAD/CAM Dental Laboratories
- \* CAD/CAM Materials
- \* Computerized Scanning and Imaging
- \* Implantation Navigation Systems
- \* Computerized Orthodontic Planning and Design
- \* Computerized Management and Planning
- \* Computerized Informational and Educational Software

Organized by:



CAPP Tel: +971 4 3616174; Fax: +971 4 3686883  
Mob: +971 50 2793711; info@cappmea.com

[www.cappmea.com/cadcam4](http://www.cappmea.com/cadcam4)

Gold Sponsor  
**Sirona**  
The Dental Company

Official Sponsors  
**3M ESPE**



**DeguDent**  
A Denegry International Company



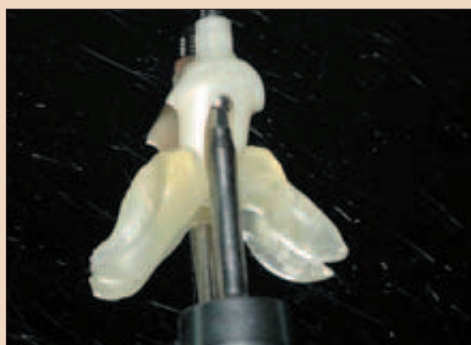

Fig. 12: Zirconium abutment with its guide and screw driver

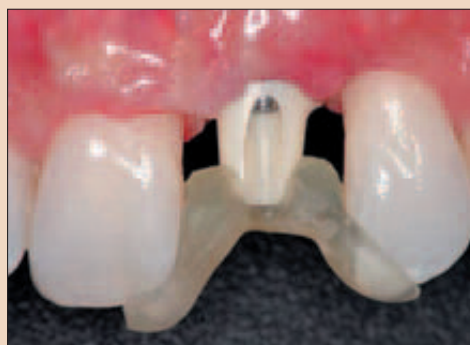

Fig. 13: Zirconium abutment in place using the guide

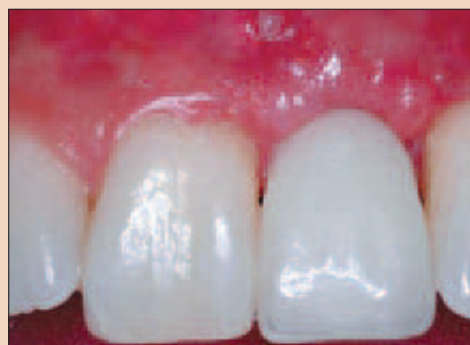

Fig. 14: Temporary crown 6 weeks later

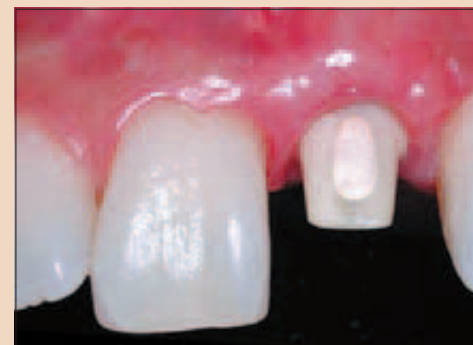

Fig. 15: Soft tissue aspect after removal of the temporary crown

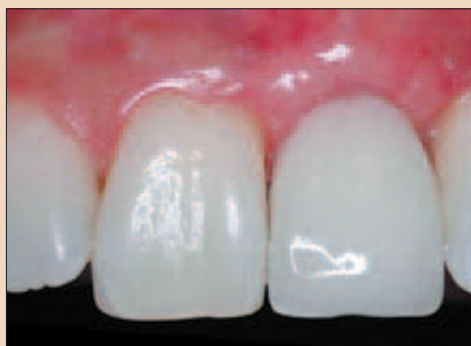

Fig. 16: Temporary crown 6 months later

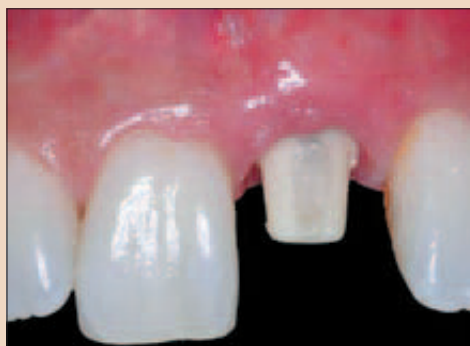

Fig. 17: Soft tissue aspect around the abutment 6 months later

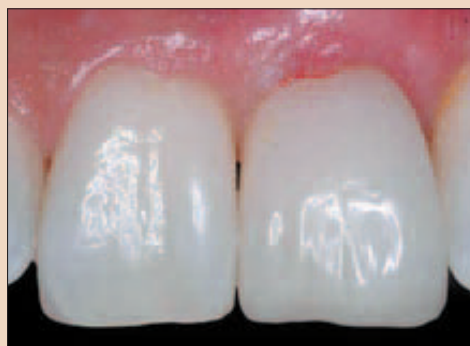

Fig. 18: Procera restoration on the day of cementation

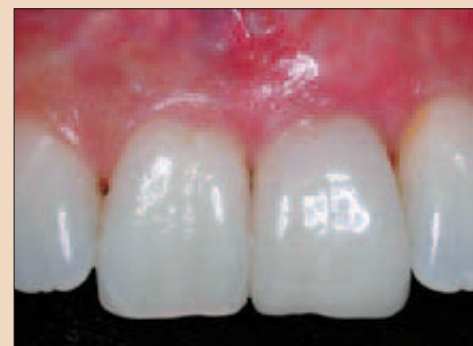

Fig. 19: Restoration 3 months later

#### → DT Page 7

function can cause the loss of peri-implant bone (Misch *et al*, 2005). The control of horizontal, trans-axial forces on an implant during the first months of function is a determining factor in reducing stress in the crestal zone, in enabling bone adaptation, and in minimizing crestal bone loss (Legall *et Saadoun*, 2002).

#### Conclusion

The essential prerequisites for an optimally aesthetic implant restoration should always remain a careful, precise, comprehensive, biologically- and prosthetically-based diagnosis, as well as the choice of the most appropriate implant materials, most conservative, and least traumatic treatment techniques, aimed at conserving, and where necessary augmenting gingival and bone to achieve a successful outcome. ■

#### References

- Albrektsson T *et al*. The long-term efficacy of currently used dental implants. A review and proposed criteria of success. *Int J Oral Maxillofac Impl*, 1986; 1:11-25.
- Dibart S, Warbington M, Su MF, Skobe Z. In vitro evaluation of the implant-abutment bacterial seal: the locking taper system-*Int J Oral Maxillofac Implants*, 2005; 20:732-737.
- Elian N, Jalbout ZN, Cho SC. *et al*. Realities and limitations in the management of the interdental papilla between implants: three case reports. *Pract Proced Aesthet Dent* 2003;15(10):737/744.
- Esposito M, Ekstrubbe A, Grondahl K. Radiological evaluation of marginal bone loss at tooth surfaces facing single Brånemark implants. *Clin Oral Imp Res*, 1993;4(3):151-157.
- Grunder U, Gracis S, Capelli M. Implantation in the tridimensional space: Aesthetic consequences. *Int J Perio Rest Dent*, 2005; 25(2), 72-83.
- Jovanovic SA, Paul SJ, Nishimura RE. Anterior implant-supported reconstruction: a surgical challenge. *Pract Periodontics Aesthet Dent*, 1999; 11(5):551-558.
- Legall MG, Lauret JF, Saadoun AP. Occlusion fonctionnelle en implantologie. *Occlusion et Fonction. JPIO*, 2002 : 97-120.
- Lezly S, Miller, B. Replacement of adjacent missing anterior teeth with scalloped implants: a case report. *Pract. Proc. Aesthet. Dent*. 2005, 17(5):331-338.
- Mathews DP. Soft tissue management around implants in the esthetic zone. *Int J Periodont Rest Dent* 2000;20:141-149.
- Misch C, Suzuki J, Misch-Mietsh F, Bidez M. A positive correlation between occlusal trauma and peri-implant bone loss: literature support. *Implant Dent*, 2005, 14:108-116.
- Rompen E, Touati B, Van Dooren E. Factors influencing marginal tissue remodelling around implants. *Pract Proved Aesthet Dent* 2003;15(10):754--761.
- Rompen E, Raepsaetn N, Dompkaen O, Touati B, Van Dooren E. Soft tissue stability at the facial aspect of gingivally converging abutment in the aesthetic zone: a pilot clinical study. *J. Prost Dent*, 2007; sup 97(6):119-125.
- Saadoun AP, Le Gall MG. Periodontal implications in implant treatment planning for aesthetic results. *Pract Periodont Aesthet Dent*, 1998;10(5):655-664.
- Saadoun AP, Le Gall MG, Touati B. Selection and ideal tridimensional implant position for soft tissue aesthetics. *Pract Periodont Aesthet Dent*. 1999;11(9):1063-1072
- Saadoun AP, Le Gall MG, Touati B. Current trends in implantology: Part 1-Biological response, implant stability, and implant design. *Pract Proved Aesthet Dent*, 2004;16(7):529-535.
- Salama H, Salama MA. The role of orthodontic extrusive remodelling in the enhancement of soft and hard tissue profiles prior to implant placement. *Int J Periodontics Restorative Dent*, 1995;13(4):312-333.
- Small PN, Tarnow DP. Gingival recession around implants: a 1-year longitudinal prospective study. *Int J Oral Maxillofac Implants*, 2000; 15(4).527-532.
- Small PN, Tarnow DP, Cho SC. Gingival recession around wide-diameter versus standard-diameter implants: A 5- to 5-year longitudinal prospective study. *Pract Proved Aesthet Dent* 2001;13(2):143-146.
- Testori T. Ideal implant positioning in maxillary anterior extraction sockets. *Acad News*, 2003;1-13.
- Touati B, Guez G. Immediate implantation with provisionalization: from literature to clinical implications. *Pract Proved Aesthet Dent*. 2002;14(9):699-707.
- Touati B. Biologically driven prosthetic options in implant dentistry. *Pract Proved Aesthet Dent*, 2004;16(7):517-520.

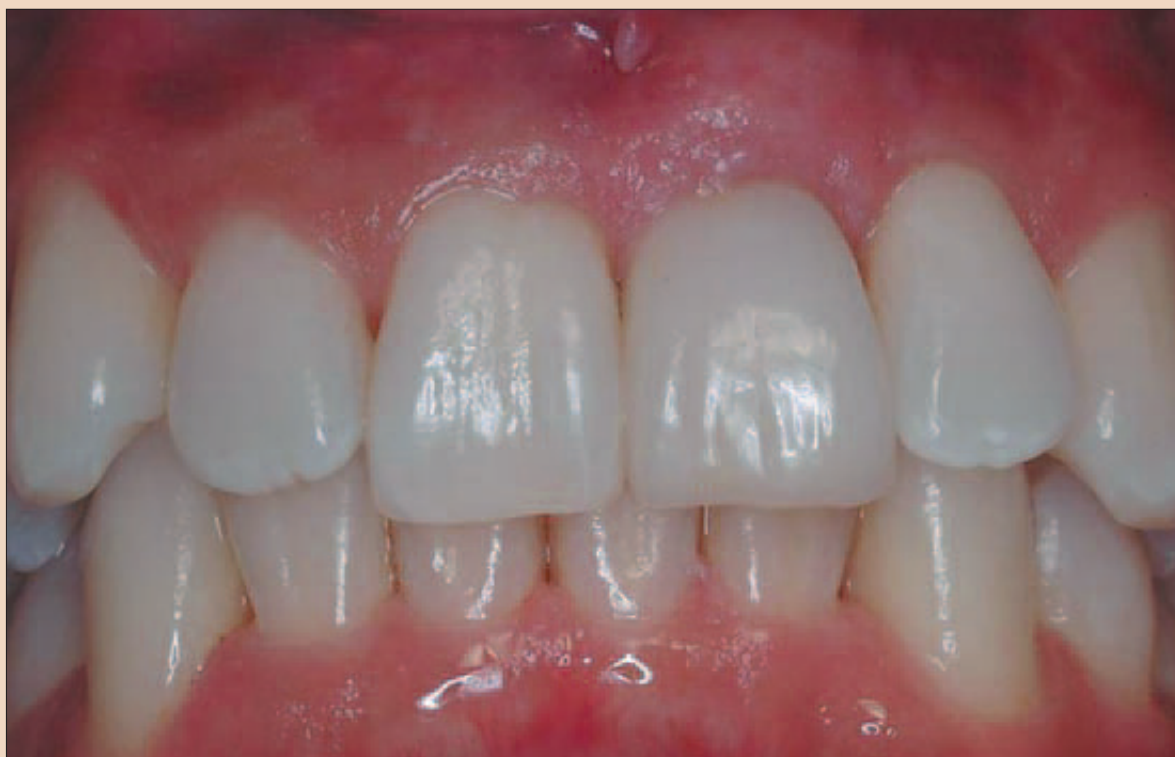

Fig. 20: Smile aspect 6 months later

## MEDIA CME Self-Instruction Program

Dental Tribune Middle East & Africa in collaboration with CAPP introduce to the market the new project mCME-SelfInstruction Program.

mCME gives you the opportunity to have a quick and easy way to meet your continuing education needs.

mCME offers you the flexibility to work at your own pace through the material from any location at any time. The content is international, drawn from the upper echelon of dental medicine, but also presents a regional outlook in terms of perspective and subject matter.

How can professionals enroll? They can either sign up for a one-year (10 exercises) by subscription for the magazine for one year (\$65) or pay (\$20) per article. After the payment, participants will receive their **membership number** and will be able to attend to the program.

**How to earn CME credits?** Once the reader attends the distance-learning program, he/she can earn credits in three easy steps:

1. Read the articles.
2. Take the exercises
3. Fill in the Questionnaire

and Submit the answers by Fax (+971 4 36868885) or

Email : [info@cappmea.com](mailto:info@cappmea.com)

After submission of the answers, (name and membership number must be included for processing) they will receive the Certificate with unique ID Number within 48 to 72 hours.

Articles and Questionnaires will be available in the website after the publication.

[www.cappmea.com](http://www.cappmea.com)





## Message from the president

The 2009 FDI Annual World Dental Congress (AWDC) in Singapore has come to a close for another year. This year's event ran seamlessly thanks to the tireless efforts of the Local Organising Committee (LOC) and volunteers. I would like to make a special mention of the FDI staff, which has been working in collaboration with the Singapore LOC in addition to relocating the FDI head office from Ferney-Voltaire, France, to Geneva, Switzerland.

The AWDC brought together 107 speakers from many disciplines of the dental profession to share knowledge and best practices on treatment advances with colleagues from around the world. Congress participants were dazzled with the latest developments in products and equipment at the Exhibition, which featured more than 150 international vendors. During the week, important business meetings designed to set the agenda for global health advocacy took place, as well as the 2009 FDI Elections. Congratulations to Council and Committee members who were appointed during the General Assembly B and Council C meetings (see 2009 FDI Elections). And thank you to outgoing representatives who have dedicated their time and expertise to the organisation: Dr William O'Reilly, Dr Neil Campbell, Dr Mark Goodhew, Dr Claus Munck, Dr Howard Jones, Prof. Martin Tyas, Prof. Reiner Biffar, Mr George Weber and Prof. Martin Hobdell.

The congress provided an ideal forum to further strengthen FDI's relationships with member associations, corporate partners and contributing specialists. During the National Liaison Officer (NLO) Lunch on 2 September, three of our contributing authors to "The Oral Health Atlas" made a brief presentation about the research involved



Dr Burton Conrod passes the presidential chain to incoming FDI President Dr Roberto Vianna. (DTI/FDI)

in compiling this new FDI advocacy tool, which was officially released later that day. I was delighted to learn as well about the Unilever announcement: Unilever has renewed its partnership with FDI on the Live.Learn.Laugh. programme for another three years, to continue developing oral health projects for communities in need.

The Welcome Ceremony this year was a special evening for me. Singapore's Health Minister, Mr Khaw Boon Wan, delivered an inspiring account of the positive improvements to oral health in his country, emphasising as well the need to continue working in collaboration across the region. I will

forever cherish the moment I received the presidential chain from my distinguished colleague, Past-President, Dr Burton Conrod, in a symbolic change of FDI presidency. During his term as president, Dr Conrod has supported important FDI initiatives to increase global awareness about oral health issues, including Live.Learn.Laugh., the publication of 'The Oral Health Atlas' and the Global Caries Initiative. In my Welcome Ceremony speech, I affirmed my commitment to the continuation of these and other FDI activities. Later we enjoyed a colourful performance that took the audience through Singapore's history, represented through dance and music.

Looking at the year ahead we have many exciting projects on the horizon, including

upcoming events for the Global Caries Initiative and the FDI Regional Continuing Education Programme. I feel proud to have been given this opportunity to serve as FDI President, particularly at a time when next year's AWDC will be in my home country. The 2010 AWDC Local Organising Committee has been working steadily towards welcoming us all in Salvador da Bahia next year and I look forward to seeing you there!

Dr Roberto Vianna  
FDI President

## 2009 FDI elections

There were two seats open for election on the FDI Council, including President-Elect, and ten seats open for election on the Committees at the 2009 FDI Annual World Dental Congress. In total, 26 nominations were received for the available positions, with

four nominations for Council positions and 22 nominations for Committee positions.

Congratulations and welcome to the following FDI Council and Committee members who were elected in Singapore.

<b>FDI President-Elect</b>	Dr Orlando Monteiro da Silva (Portugal)
<b>FDI Council</b>	
Councillors	Dr Norberto Lubiana (Brazil)
<b>FDI Committees</b>	
Communications & Member Support Committee	Dr Jun-Sik Moon (Korea) Asst Prof. Dr Nikolai Sharkov (Bulgaria) Prof. Dr S.M. Balaji (India) Prof. Dr Vladimer Margvelashvili (Georgia)
Dental Practice Committee	Dr Ward van Dijk (The Netherlands) Dr Armando Hernandez Ramirez (Mexico)
Science Committee	Prof. Dr Georg B. Meyer (Germany) Dr Claudio Pinheiro Fernandes (Brazil)
World Dental Development & Health Promotion Committee	Dr Jo E. Frencken (The Netherlands) Dr Kevin S. Hardwick (United States) <a href="#">FDI</a>

## FDI Policy Statements

The FDI General Assembly adopted three new and nine revised FDI Policy Statements at the 2009 Annual World Dental Congress.

### New Policy Statements

- Dentin Hypersensitivity
- Edentulism and General Health Problems of the Elderly
- The Use of Academic, Professional and Honorary Titles

### Revised Policy Statements

- The Association between Oral Health and General Health
- Dental Bleaching Materials

- Effect of Masticatory Efficiency on General Health
- Fluoride in Restorative Materials
- Infection Control in Dental Practice
- Post-Exposure Prophylaxis for HBV, HCV and HIV
- Research

The FDI Policy Statements on Dental Unit Water Lines and Tuberculosis and the Practice of Dentistry were withdrawn at General Assembly B and Open Forum 1, respectively. [FDI](#)

## FDI launches new Oral Health sourcebook

Participants and delegates of the 2009 congress joined incoming FDI President, Dr Roberto Vianna, FDI Executive Director, Dr David Alexander, and authors Roby Beaglehole, Habib Benzian and Jon Crail, at the FDI Pavillion for the official release of FDI's new 'Oral Health Atlas', in commemoration of World Oral Health Day (WOHD) on 12 September, 2009.

The annual WOHD is an opportunity for diverse segments of the population to reflect upon

their own situations when it comes to managing oral health and 'The Oral Health Atlas' is designed to illustrate oral health globally. Using short texts, colourful maps, graphics and images, along with statistics and facts, the atlas presents a global picture of oral health in a visually intuitive and easy-to-understand format.

Following the official release at congress, the Singapore Dental Association announced it would purchase copies of 'The Oral Health Atlas' for dis-



Dr David Alexander and Dr Roberto Vianna with authors of 'The Oral Health Atlas' at the FDI Pavillion in Singapore. (DTI/FDI)

tribution to public libraries across the city-state. Other member associations have demonstrated interest in translating the atlas for readers within their regions.

'The Oral Health Atlas' is published by Myriad Editions ([www.myriadeditions.com](http://www.myriadeditions.com)), which is known for its award-winning State of the World Atlas series. More information about the atlas, including how to purchase a copy, is available at the official website: [www.oralhealthatlas.org](http://www.oralhealthatlas.org) [FDI](#)