


DENTAL TRIBUNE

— The World's Dental Newspaper • Middle East & Africa Edition —

PUBLISHED IN DUBAI

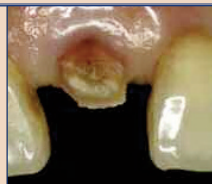FEBRUARY 2010

No. 1+2 Vol. 8



Media CME
Oral cancer: Early detection saves lives

▶ Page 6



Trends & Applications
Emergency dental implant procedures

▶ Page 8



News & Opinions
FDI, FOLA and DTI launch campaign for Haitian dentists

▶ Page 10

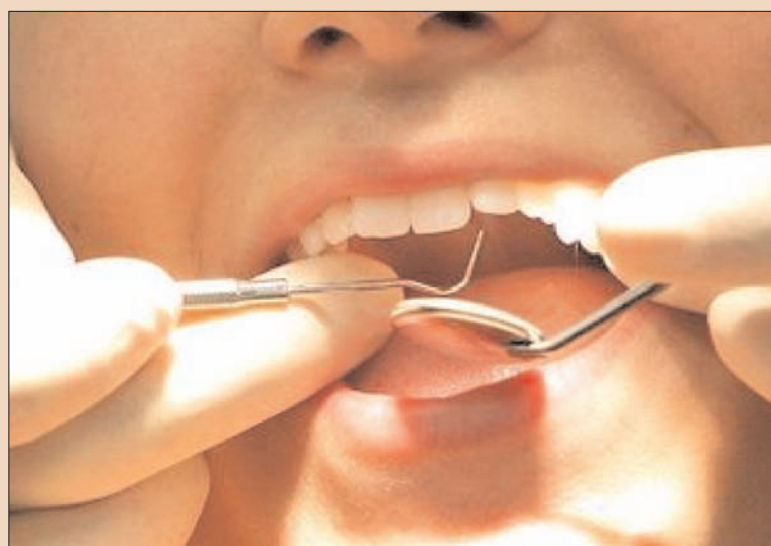
Jet 'to replace dentist's drill'

A futuristic "plasma jet" that eradicates tooth decay without fillings could be replacing the hated dentist's drill in as little as three years, it was claimed.

The space-age device fires a beam of electrically-charged oxygen atoms into tooth cavities to obliterate decay-causing bacteria. Traditionally, the same job is done by drilling holes into the tooth that has to be filled.

Unlike the dentist's drill, the plasma jet is non-invasive and

→ DT page 2



Baby death linked to mum's gum disease

The first-ever documented link between foetal death and a mother's pregnancy-related gum disease has been reported.

A 35-year-old woman delivered a full-term stillborn baby who, during pregnancy, experienced severe gum bleeding, a symptom of pregnancy-related gingivitis.

Approximately 75% of pregnant women experience gum bleeding due to the hormonal changes during pregnancy.

These findings – by Yiping Han, a researcher from Department of Periodontics at Case Western Reserve University School of Dental Medicine – are discussed in an article in the February issue of *Obstetrics & Gynecology*.

The article explains that bleeding in the gums allows bacteria in the mouth to enter the bloodstream and potentially infect a foetus – but can be stopped by the immune system.

However, in this case, the mother also experienced an upper respiratory infection like a cold and low-grade fever just a few days before the stillbirth.

Lead author, Yiping Han, said: 'There is an old wives' tale that you lose a tooth for each baby, and this is due to the underlying changes during pregnancy.'

'But if there is another underlying condition in the background, then you may lose more than a tooth.'

Even though the amniotic fluid was not available for testing, Han suspects from work with animal models that the bacteria entered the immune-free amniotic fluid and eventually ingested by the baby.

'The timing is important here because it fits the timeframe of haematogenous (through the blood) spreading we observed in animals,' Han said.

Post-mortem microbial studies of the baby found the presence of *F. nucleatum* in the lungs and stomach. The baby had died from a septic infection and inflammation caused by bacteria.

After questioning the mother about her health during the pregnancy, Han arranged for her to visit a periodontist, who col-

→ DT page 2

First Emirati professor joins Masdar

ABU DHABI // An academic who has received numerous awards for her scholastic achievements has become the first Emirati faculty member at Masdar Institute of Science and Technology.

Dr Amal al Ghaferi will be an assistant professor at the institute, which is the research arm of

the US\$22 billion (Dh80.8bn) carbon-neutral Masdar City project. She will teach materials science and engineering and carry out research in nanotechnology and energy.

"I believe my position at Masdar Institute will open doors to pursuing my research in nanotechnology and related fields," said Dr al Ghaferi. "I am looking

forward to this challenging mission and hope to become a role model for all UAE nationals."

She graduated in physics from UAE University, where her grade-point average was 3.98 on a 4.0 scale. She later earned a PhD in materials science and en-

→ DT page 2

AD

DTMEA 1+2/10

PROMEDICA

Highest quality made in Germany

- ▶ high quality glass ionomer cements
- ▶ first class composites
- ▶ innovative compomers
- ▶ modern bonding systems
- ▶ materials for long-term prophylaxis
- ▶ temporary solutions
- ▶ bleaching products...

All our products convince by

- ▶ excellent physical properties
- ▶ perfect aesthetical results

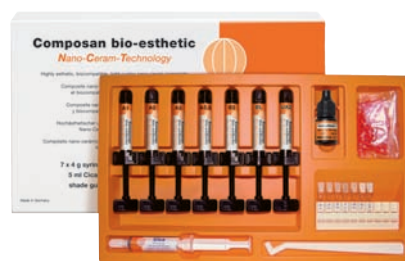Visit us at
AEEDC 2010
Dubai
Booth 457
German Pavilion

New:
Bleach Shade!



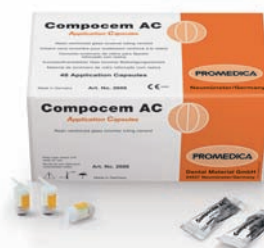Temporary crown and bridge material

- particular fracture and wear resistance
- now available in 6 attractive shades



Light-curing nano-ceram composite

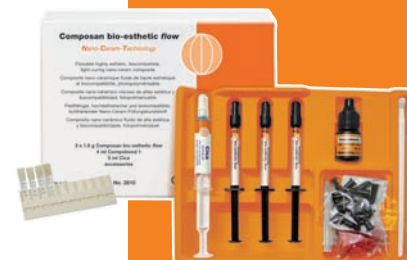- universal for all cavity classes
- comfortable handling, easy modellation
- highly esthetic and biocompatible



Resin-reinforced glass ionomer luting cement

- strong adhesion, very low film thickness
- especially suited for zirconia-based pieces

Nano-Ceram-Technology



• exact match of translucency and shade to the packable Composan bio-esthetic

PROMEDICA

PROMEDICA Dental Material GmbH

Tel. + 49 43 21 / 5 41 73 · Fax + 49 43 21 / 5 19 08

Internet: <http://www.promedica.de> · eMail: info@promedica.de

Countries in Asia less than average in health care spending

Daniel Zimmermann
DTI

LEIPZIG, Germany: Asian countries have been found to spend less of their GDP's for health care than most other countries in Europe and the US. According to a new health care report by the Organisation for Economic Co-operation and Development

(OECD) in Paris, only New Zealand provided more money for health care than the average of all observed countries. Japan, Korea and Australia, however, spent less than the OECD average of 8.9 per cent of GDP.

The US currently spends more on health care than any other

country—almost two and a half times greater than the OECD average of US\$2,984, adjusted for purchasing power parity. Luxembourg, France and Switzerland also spend far more than the OECD average. At the other end of

the scale, health-care expenditure in Turkey and Mexico is less than one-third of the OECD average.

The latest edition of *Health at a Glance* demonstrates that all the countries observed could do better in providing good quality health care. Key indicators presented in the report provide information on health status and the determinants of health, in-

cluding the growing rates of child and adult obesity, which are likely to drive higher health spending in the coming decades.

Based on new data on access to care, the report demonstrates that all OECD countries provide universal or near-universal coverage for a core set of health services, except the US, Mexico and Turkey. [DTI](#)

Jet 'to replace dentist's drill'

← [DTI](#) Page 1

pain-free. Fear of fillings is a genuine phobia for some people, causing them to avoid visits to the dentist.

A new study has shown that firing low-temperature plasma beams at dentine - the fibrous tooth structure below the enamel - can reduce bacteria levels by up to 10,000 times.

Researchers in Germany tested the effectiveness of the plasma jet against common dental bugs including *Streptococcus mutans* and *Lactobacillus casei*.

Both form films on the surface of teeth and are responsible for the erosion of tooth enamel and dentine that causes cavities.

The scientists infected dentine from extracted human molars with four strains of bacteria and exposed it to plasma for between six and 18 seconds. The longer the treatment continued, the greater the amount of bacteria that was eliminated.

Lead researcher Dr Stefan Rupf, from Saarland University in Homburg, said: "The low temperature means they can kill the microbes while preserving the tooth. The dental pulp at the centre of the tooth, underneath the dentine, is linked to the blood supply and nerves and heat damage to it must be avoided at all costs." [DTI](#)

Baby death linked to mum's gum disease

← [DTI](#) Page 1

lected plaque samples from her teeth.

Using DNA cloning technologies, Han found a match in the bacterium in the mother's mouth with the bacterium in the baby's infected lungs and stomach.

"The testing strongly suggested the bacteria were delivered through the blood," Han said. With preventive periodontal treatment and oral health

care, the mother has since given birth to a healthy baby.

Han says this points again to the growing importance of good oral health care. Collaborating with Han on the case study were Yann Fardini, Casey Chen, Karla G. Iacampo, Victoria A. Peraino, Jaime Shamonki and Raymond W. Redline.

The study had support from the National Institute of Dental and Craniofacial Research in the US [DTI](#)

First Emirati professor joins Masdar

← [DTI](#) Page 1

gineering from the University of Pittsburgh.

Dr al Ghaferi has won two Sheikh Rashid Awards for Academic Excellence for her undergraduate and postgraduate work. The prize is typically conferred upon several hundred Emiratis per year who have excelled in their studies.

She has also received a fellowship from the US State Department and earned one of six British government research

grants from a Dh1.1 million fund while she was employed at UAE University.

Dr John Perkins, the institute's provost, said Dr al Ghaferi would make "a significant contribution" in both her research and teaching.

"She is also an excellent role model for young people interested in pursuing a career in science and technology," he said.

There are now 22 faculty members at the institute recruited from universities around the world. [DTI](#)

Editorial Board

Prof. Abdullah Al-Shammary, Restorative Dentistry, KSA
Prof. Hussain F. Al Huwaizi, Endodontics, Iraq
Prof. Samar Burgan, Oral Medicine, Jordan
Dr. Abdel Salam Al Askary, Implantology, Egypt

Dr. Talal Al-Harbi, Orthodontist, Qatar
Dr. Mohammed H. Al Jishi, Bahrain
Dr. Lara Bakaen, Prosthodontist, Jordan
Dr. Aisha Sultan, Periodontist, UAE
Dr. Kamal Balaghi Mobin Aesthetics, Iran

DENTAL TRIBUNE

The World's Dental Newspaper - Middle East & Africa Edition

Published by Education Zone

in licence of Dental Tribune International GmbH

© 2010, Dental Tribune International GmbH. All rights reserved.

Dental Tribune makes every effort to report clinical information and manufacturer's product news accurately, but cannot assume responsibility for the validity of product claims, or for typographical errors. The publishers also do not assume responsibility for product names or claims, or statements made by advertisers. Opinions expressed by authors are their own and may not reflect those of Dental Tribune International.

President/CEO Yasir Allawi
y.allawi@dental-tribune.ae

Director mCME: Dr. D. Mollova
info@cappmea.com

Marketing manager Khawla Najib
khawla@dental-tribune.ae

Production manager Hussain Alvi
dentalme@dental-tribune.ae

PO Box 214592, Dubai, UAE, Tel + 971 4 391 0257
Fax + 971 4 366 4512 www.dental-tribune.com

AD

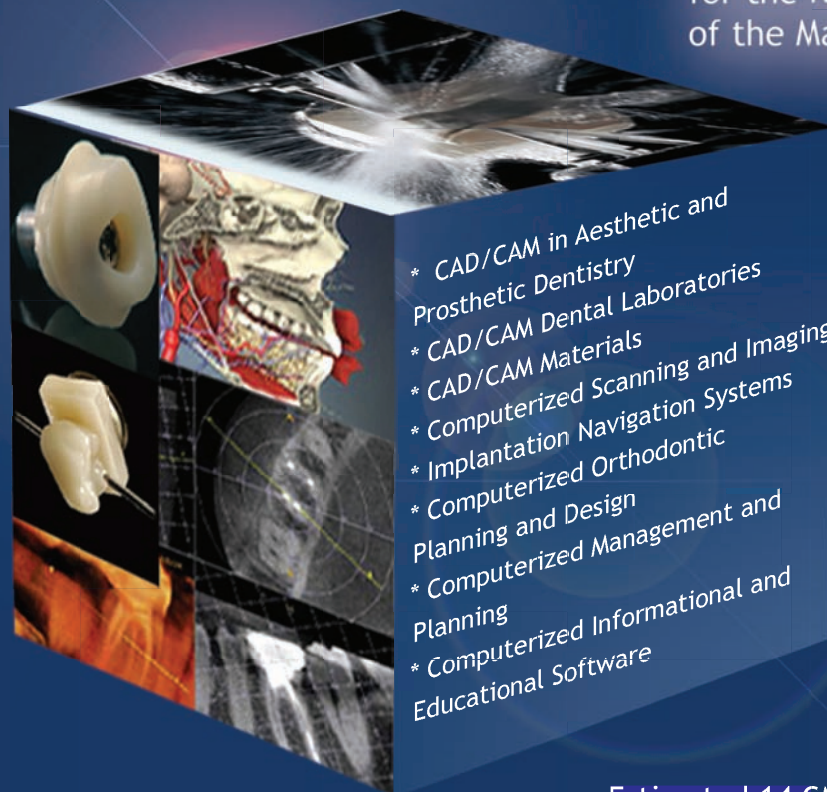
The new era in Aesthetic Dentistry

4th CAD/CAM Computerized Dentistry International Conference

13-14 May 2010, Dubai
The Address Dubai Marina

20% Discount
for the Readers
of the Magazine

www.cappmea.com/cadcam4



- * CAD/CAM in Aesthetic and Prosthetic Dentistry
- * CAD/CAM Dental Laboratories
- * CAD/CAM Materials
- * Computerized Scanning and Imaging
- * Implantation Navigation Systems
- * Computerized Orthodontic Planning and Design
- * Computerized Management and Planning
- * Computerized Informational and Educational Software

Estimated 14 CME Hours

Platinum Sponsor

sirona
The Dental Company

Gold Sponsors

3M ESPE

Nobel Biocare

Official Sponsors

DeguDent
A Denary International Company

ivoclar vivadent

Hint-ELs
DentaCAD System

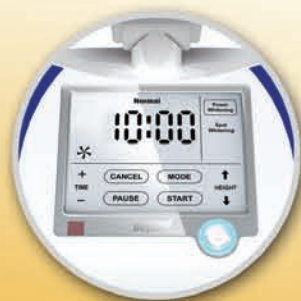AMANN GIRRBACH

Other Industry Players

VITA

beyond™

Innovation and Excellence
in Aesthetic Dentistry



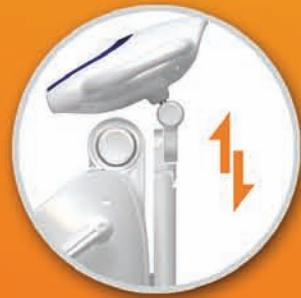←
Touch User
Interface
(TUI) control
panel



←
Built-in LED
curing light for
single-tooth
whitening and
dual-wavelength
curing power



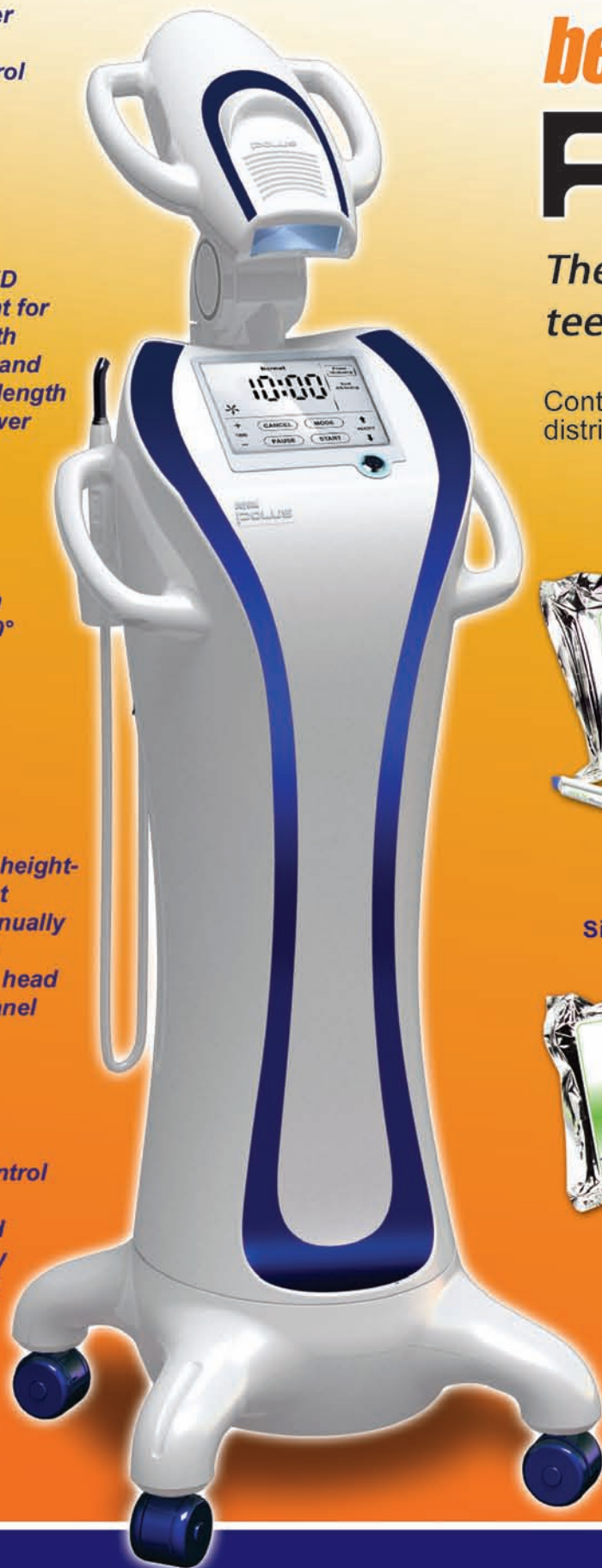←
Radial arm
boasts 360°
range of motion



←
Motorized height-
adjustment
can be manually
controlled
from lamp head
and TUI panel



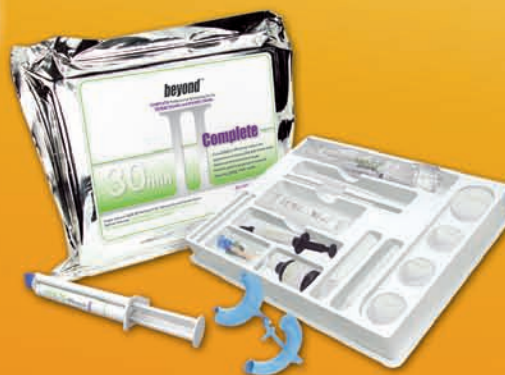←
Wireless
remote control
with call
button and
emergency
pause and
resume
buttons



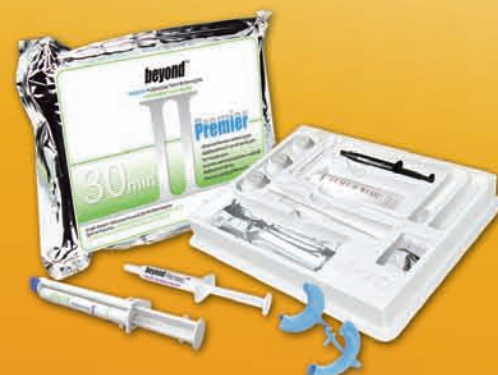beyond™ POLUS™

The future of chair-side power
teeth whitening has arrived.

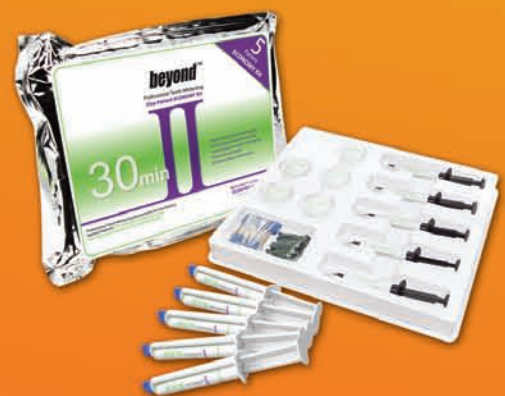Contact us today to learn more about BEYOND™ products and
distribution opportunities in your area!



BEYOND™ Complete®
Single-Patient Treatment Kit



BEYOND™ Premier™
Single-Patient Treatment Kit



BEYOND™ Five-Patient
Economy Kit



BEYOND™ Max5™ and Max10™
Treatment Kits

beyond™ Dental & Health

BEYOND™ USA HEADQUARTERS
12503 Exchange Dr. Suite 558
Stafford, TX 77477 USA
Tel: +1-281-277-4352
Fax: +1-281-277-4350
Email: beyondusa@beyonddent.com

Algeria: DENT CO LTD, Tel: +213-31-90-00-89
Egypt: Arabian Doctor Trading EST.,
Tel: +201-01-462-338 / +201-07-043-734
Iraq: NAKHLAT SHATT ALARAB - MEDICAL COMPANY,
Tel: +963-93-251-1258
Jordan: Osama Fadel Al-Deen Est, Tel: +962-6-5333115
KSA: Medical Vision Est., Tel: +966-1-405-7275
Kuwait: SAFWAN TRADING & CONTRACTING COMPANY,
Tel: +965-484-8952

Lebanon: RICHA DENTAL STORE, Tel: +961-5-452-555 /
PearlSmile sarl, Tel: +961-1-495-111
Oman: Sala Medical Complex "Sala Medical, Tel: +968-24-485-159
Palestine: High Professional Co., Tel: +972-59-967-0780
Qatar: Ebn Sina Medical, Tel: +974-4417953
Syria: Koucheh Trading Co., Tel: +963-41-450749
UAE: National Medical Supplies, Tel: +971-4-2857578
Yemen: Alasser Group, Tel: +967-73-379-7927

www.beyonddent.com

YOUR HOSPITAL SHOW REFERENCE



2nd Qatar International Medical & Hospital Show

Qmedic

Qhealth

Qpharma

Qlab

Qdental

Qhospi

Qophthal

www.qmedic.net

For further information & sponsorship opportunities please contact the organizer

P.O.Box 22679 , Doha-Qatar
Tel. +974 444 22 70/71, Fax. +974 442 28 38
E-mail: qmedic@conexqatar.com www.conexqatar.com



كونيكس لتنظيم وخدمات المعارض و المؤتمرات
Expos, Conferences, Organizing & Services

New health initiatives for Dubai

Representatives of Dubai Healthcare City (DHCC) have announced the launch of new initiatives to address a number of issues in the Middle East's growing health-care sector. Speaking at a press conference at Arab

professionals further, the Dubai Harvard Foundation for Medical Research is offering a Science Writers and Journalists Fellowship Program in 2009 for the second consecutive year and post-doctoral research fellowships to train scientists and researchers. The foundation is also offering annual grants for two research

teams under the Collaborative Research Center Programme.

Dr Ayesha added that one of DHCC's many achievements in the last two years has been the region's first health-care licensing examination centre, established to help develop and administer comprehensive examinations

for health-care professionals. Doctors in Dubai and other countries in the Middle East usually choose to advance their specialist training credentials through the postgraduate examinations of the British Royal Colleges, such as the Membership of the Royal College of Physicians, which is hosted in Dubai, or the

Membership of the Royal College of Surgeons.

Postgraduate programmes in dentistry are offered by the DHCC's Boston University Institute for Dental Research and Education. The only private postgraduate dental institute in the Middle East received accreditation by the UAE government last year. Its programmes include endodontics, orthodontics, paediatrics, periodontology, and prosthodontics. [D](#)



Health, an annual event for the health-care industry in Dubai in the UAE, senior vice-president Dr Ayesha Abdullah said that the DHCC's programmes in 2009 will include a CME session on diabetes by the Harvard Medical School Dubai Center, as well as a variety of mobile, simulation-based courses for various levels of health-care professionals including dentists.

To support the training of regional and local health-care pro-

Fizzy Phone: Mobile Runs On Coca-Cola

Bulky mobile phone chargers could soon be a thing of the past with handsets running on soft drinks instead

Daizi Zheng designed the 'greenphone', which is powered by Coca-Cola, as part of her final university project. The Central Saint Martins graduate came up with the concept for Finnish mobile phone manufacturer Nokia.

Ms Zheng said the prototype could run up to four times longer than a traditional lithium ion battery and has the potential to be fully biodegradable.


The greenphone's bio battery generates electricity using enzymes to catalyse sugar in the drink. As the battery dies out, only water and oxygen are left behind.

Unfortunately, Nokia will not be developing the greenphone prototype further in the near future. Ms Zheng told Sky News: "At the time they wanted something to bring out within the next two years and thought my design was too futuristic."

But she added that bio batteries are being developed by large electronics companies and may be on the market in the next five years

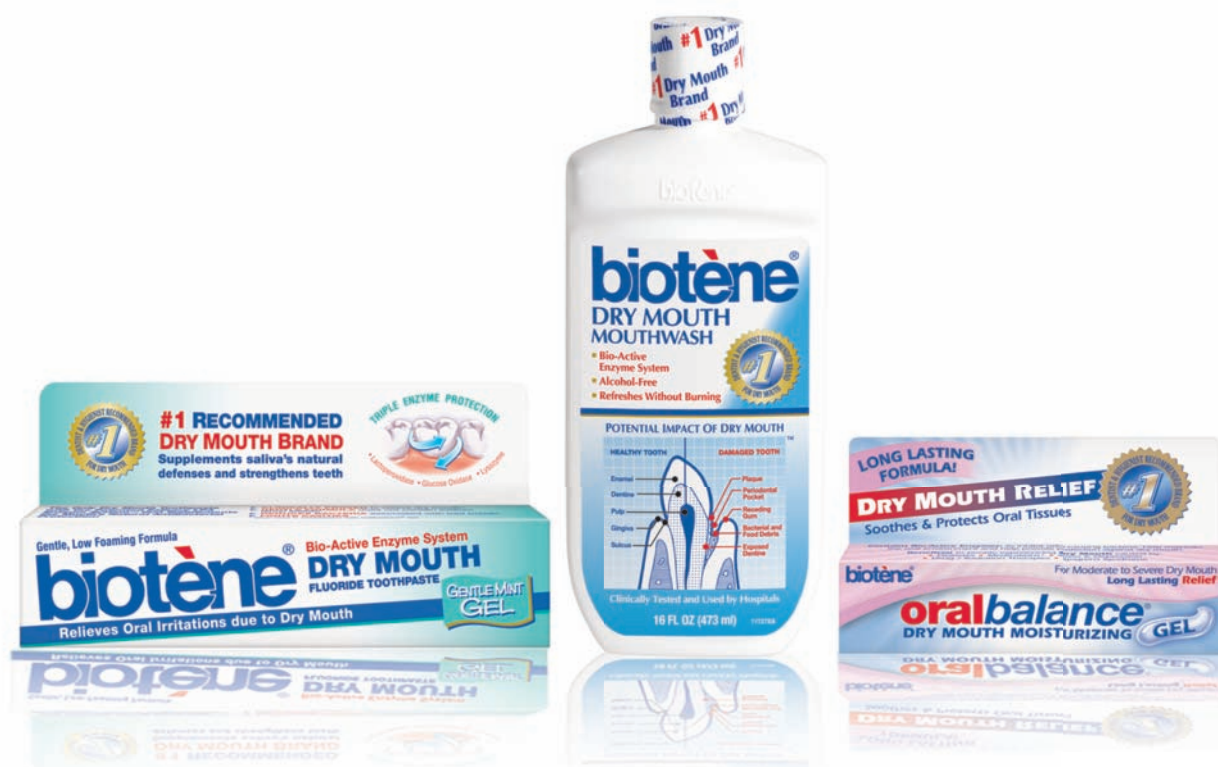AD

Do you suffer from dry mouth?



Try the biotène® range

A complete dry mouth treatment



Visit www.biotene.com to learn more about dry mouth.

biotène® leaders in dry mouth treatment

gsk GlaxoSmithKline Consumer Healthcare



Oral cancer: Early detection saves lives

The article has been accredited by Health Authority - Abu Dhabi as having educational content and is acceptable for up to 2 (Category 1) credit hours. Credit may be claimed for one year from the date of subscription.

By Arlene Guagliano, RDH, MS

Cancer of the mouth or oral cavity is one of the most preventable cancers in the United States today. According to the Journal of the National Cancer Institute, more than 35,000 Americans will be diagnosed with oral or pharyngeal cancer this year.

It will cause more than 8,000 deaths, killing roughly one person per hour, 24 hours per day. Of those 35,000 newly diagnosed individuals, only half will be alive in five years. This is a number that has not significantly improved in decades.¹

Although the overall incidence of oral cancer has remained stable with numbers only slightly increasing each year², currently this is the second year in a row in which there has been an increase in the rate of occurrence, about 11 percent over last year.

The death rate for oral cancer is higher than that of other cancers that we hear about routinely, such as cervical cancer, Hodgkin's lymphoma, laryngeal cancer, cancer of the testes and endocrine system cancers such as thyroid or skin cancer (malignant melanoma).¹

Oral squamous-cell carcinomas (OSCCs) are the eighth most common cancer among men and the 14th most common among women in the United States.³

It includes many parts of the mouth: the lips, the buccal mucosa of the lips and cheeks, the gingiva and the area behind the wisdom teeth, the floor of the mouth, the hard palate, the soft palate and the uvula, the tonsils and the tongue.⁴

The ratio of men to women diagnosed with oral cancer is 2:1 over a lifetime, although the ratio comes closer to 1:1 with advancing age. Approximately 96 percent of oral cancer is diagnosed in persons older than 40, and the average age at the time of diagnosis is 65 years.

However, recent evidence has emerged indicating that oral cancers are occurring more frequently in younger persons, those under 40 years old.²

Common symptoms of oral cancer include:

- A sore or lesion in the mouth that does not heal within two weeks.

- A lump or thickening in the cheek.
- A white or red patch on the gingiva, tongue, tonsil or lining of the mouth.
- A sore throat or a feeling that something is caught in the throat.
- Difficulty chewing or swallowing.
- Difficulty moving the jaw or tongue
- Numbness of the tongue or other area of the mouth.
- Swelling of the jaw that causes dentures to fit poorly.¹

Oral cancer is caused by damage to the DNA of cells in the mouth. There are two distinct pathways through which most people come to have oral cancer. Many years ago, the most prevalent pathway was through the use of tobacco and alcohol, but today the growing pathway is through exposure to the human papilloma virus (HPV), the same one that is responsible for the vast majority of cervical cancers in women.

Whichever the pathway, damage to the cells occurs and they malfunction, mutating into cancer cells. The anatomical malignancy sites associated with each pathway appear to also be different from each other.

In the broadest terms, they can be differentiated into the following areas: HPV-related appear to occur on the tonsillar area, the base of the tongue and the oropharynx while non-HPV positive tumors tend to involve the anterior tongue, floor of the mouth, the mucosa that covers the inside of the cheeks and alveolar ridges.

It is now confirmed that HPV is the most common virus group in the world today, affecting the skin and mucosal areas of the body. More than 100 different types/versions of HPV have been identified. Different types of the human papilloma virus are known to infect different parts of the body. There are certain forms of HPV that are sexually transmitted and are a serious problem.

Today, in the younger age group, including those who have never used tobacco products, there are those who have oral cancer, which is HPV-viral based.

Two types of genital tract HPV in particular, HPV 16 and HPV 18, are known to be linked to oral cancer and have been conclusively implicated in the increasing incidence of young, non-smoking, oral cancer pa-

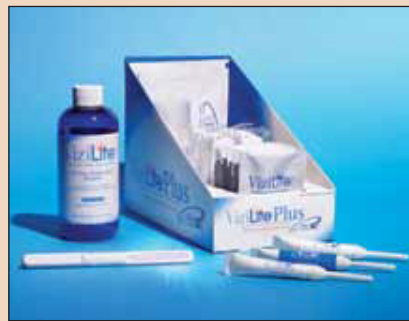

Fig. 1: The ViziLite Plus.

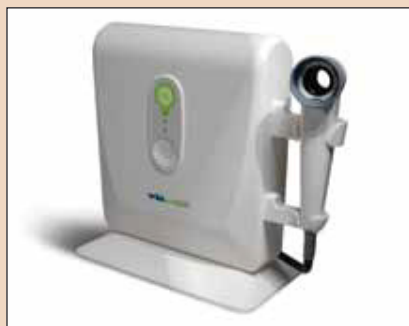

Fig. 2: The VELscope.

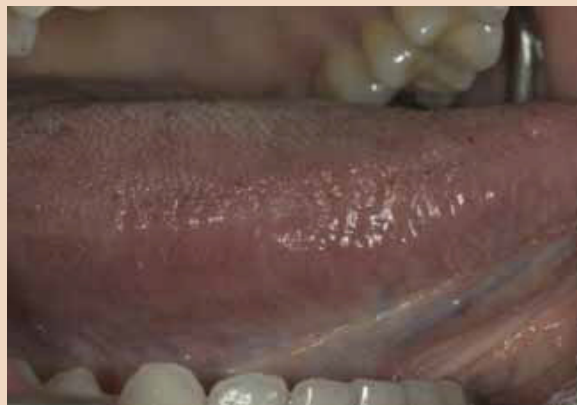

Fig. 3a: Normal tongue in normal light.

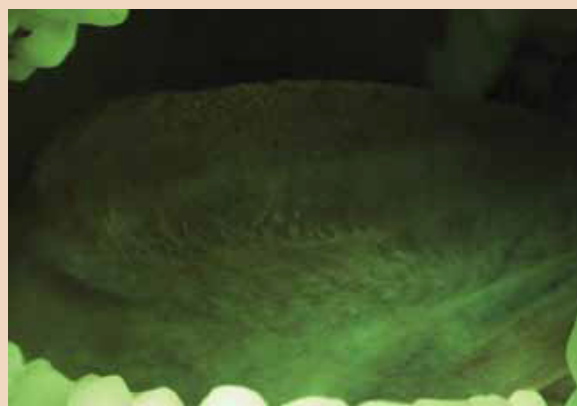

Fig. 3b: Normal tongue viewed with the VELscope.

tients. The HPV group is the fastest growing segment of the oral cancer population to date.¹

Oral cancer is among the most debilitating and disfiguring disorders seen in today's oral health environment. Tumors affecting a patient's mouth, tongue and soft palate can prohibit proper swallowing and speech.⁵

In addition, the cancer can spread to other parts of the body, causing disability and even death. The survival of patients and the quality of life after treatment depend on early diagnosis. Eighty-one percent of patients with oral cancer survive at least one year after

diagnosis. Early detection is the key.⁴

The best defense against oral cancer is early discovery. Early detection is complicated by the fact that many lesions in their earlier stages may be completely asymptomatic. Historically, unaided visual examination, palpation and radiographs were the only methods available for oral cancer screening. In recent years, screening technologies have become available to supplement the visual examination and help the clinician identify suspicious lesions that require further investigation.⁶

Adjunctive screening aids

ViziLite Plus. Technology such as light-based detection systems increases a clinician's ability to see tissue changes that the naked eye

ViziLite can assist a dentist or hygienist in identifying an abnormality in the oral cavity that may need further testing, such as a biopsy.

It has been difficult to determine which tissues in the mouth are cause for concern. It is with continued research that technology has forged forward and developed adjuncts for the oral health care professional to intervene when early signs are unclear.

VELscope. The VELscope integrates four key elements: illumination, sophisticated filtering, natural tissue fluorophores and the power of human optical and neural physiology (Fig. 2).

Next to public awareness, which is essential regarding the risk factors in oral cancer, the role of the dental professional is the first line of defense in early detection of the disease.

The VELscope illuminates tissue with specific wavelengths that interact with and provide metabolic and biochemical information about the cells at and just beneath the surface.

This gives clinicians the ability to see early biochemical changes before they present more obviously, and therefore to detect lesions earlier in the disease process.⁷

Figure 3a is an image of a normal tongue in normal light, and Figure 3b is an image of a normal tongue with the use of the VELscope (images courtesy LED Dental).

Figure 4a shows a tongue with an area that appears normal under white light. However, Figure 4b shows the area as seen under the VELscope. The dark area is VELscope positive, which was confirmed by biopsy as carcinoma in situ (images courtesy of LED Dental).

In-office tissue test

OralCDx BrushTest. An essential tool for early detection of oral cancer is the OralCDx BrushTest, or oral brush biopsy (Fig. 5). This is the only painless test for oral dysplasia (pre-cancer) and cancer.

The BrushTest was found to be at least as sensitive as a scalpel in ruling out dysplasia and cancer in every study in which the same tissue was simultaneously tested by both OralCDx and a scalpel biopsy.^{8,9}

Normal epithelium will absorb the light and appear dark.

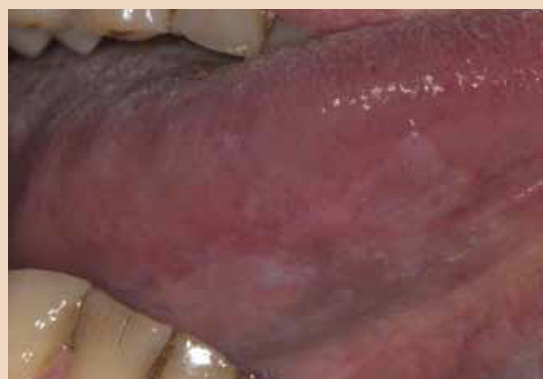

Fig. 4a: Close-up of the tongue in normal light.

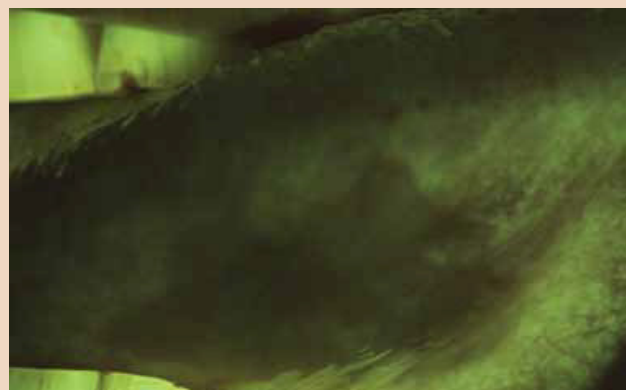

Fig. 4b: Tongue close-up with the VELscope showing in situ carcinoma that was confirmed by biopsy.

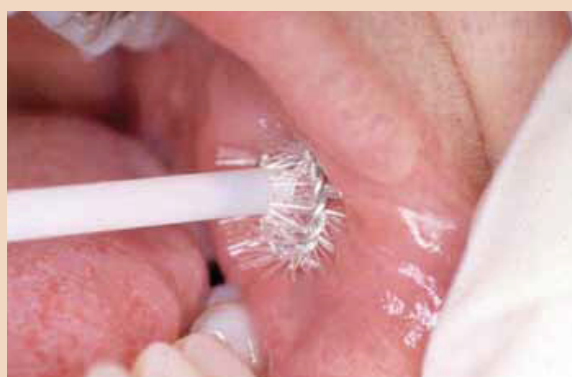

Fig. 5: The OralCDx BrushTest.

This procedure is simple and can be done right in the dentist's chair. It results in very little or no pain or bleeding, and requires no topical or local anesthetic.

Firm pressure with a circular brush is applied to the suspicious area. The brush is then rotated five to 10 times, causing some pinpoint bleeding or light abrasion. The cellular

material picked up by the brush is transferred to a glass slide, preserved and dried.

The slide is then mailed to a laboratory along with written documentation about the patient and a detailed description of the questionable area of the mouth. At the laboratory, the sample will be examined for cells that show signs of change,

such as dysplasia or full malignancy.

A pathologist examines the cells to determine the final diagnosis. A lab report is then sent to the dentist, and experts from the pathology department provide patient-specific follow-up guidance by telephone for every abnormal OralCDx report.

A final word

The American Dental Association states that 60 percent of the U.S. population sees a dentist every year.

One only has to look at the impact of the annual PAP smear for cervical cancer, the mammogram to check for breast cancer, or PSA and digital rectal exam for prostate cancer to see how effectively an aware and involved public can contribute to early detection, when coupled with a motivated medical community.

The dental community needs to incorporate adjunctive technology to the screening process and assume the same leadership role as the

medical community if oral cancer is to be brought down in the future from its undeserved high ranking as a killer. 1

References

- 1 The Oral Cancer Foundation 2007; www.oralcancerfoundation.org.
- 2 Inside Dentistry—The Forgotten Disease “Oral Cancer: Early Detection and Prevention” Nelson L. Rhodus, DMD, MPH; January 2007; Vol 5, No 1.
3. Chaturvedi, Anil K., Engels, Eric A., Anderson, William F., Gillison, Maura L.; Incidence Trends for Human Papillomavirus – Related and Unrelated Oral Squamous Cell Carcinomas in the United States; Journal of Clinical Oncology; February 1, 2008; Vol. 26, No. 4.
4. University of Texas Cancer Center; Oral Cancer M.D. Anderson Cancer Center; www.mdanderson.org/diseases/oralcancer.
5. Baker, Gerry I.: Radiation Therapy to Head and Neck, Dental Hygiene News, Fall 1991, Vol. 4 No. 4, p 1, 2.
6. Oral Cancer Risk and Detection: The Importance of Screening Technology; Lynch, Denis P. DDS Ph.D; www.ineedce.com/pathology.html.
7. John C. Kois, DMD, MSD, and Edmond Truelove, DDS, MSD; Detecting Oral Cancer: A New Technique and Case Reports, Dentistry Today, 2006, Oct; 25(10):94, 96-7.

8. “Oral cytology revisited”; R. Mehrotra, M. Hullmann, R. Smeets, T. E. Reichert, O. Driemel; Journal of Oral Pathology & Medicine Volume 38, Issue 2, Date: February 2009, Pages: 161–166.
9. “Improving Detection of Precancerous and Cancerous Oral Lesions: Computer-Assisted Analysis of the Oral Brush Biopsy”; James J. Sciubba, D.M.D., PH.D.; and for the U.S. Collaborative OralCDx Study Group (JAMA) Journal of the American Dental Association 1999;150:1445–1457.

About the author

Arlene Guagliano, RDH, MS, is an associate professor at Farmingdale State College in the department of dental hygiene and an assistant professor at Hostos Community College in the dental hygiene unit. Her professional experience includes 29 years in clinical practice specializing in geriatric dental care, oral cancer screening for early detection, dental hygiene education, caries management and periodontics. She can be reached at arlene.guagliano@farmingdale.edu, or via phone at (516) 6800231.

MEDIA CME Self-Instruction Program

Dental Tribune Middle East & Africa in collaboration with CAPP introduce to the market the new project mCME - Self Instruction Program.

mCME gives you the opportunity to have a quick and easy way to meet your continuing education needs.

mCME offers you the flexibility to work at your own pace through the material from any location at any time. The content is international, drawn from the upper echelon of dental medicine, but also presents a regional outlook in terms of perspective and subject matter.

How can professionals enroll? They can either sign up for a one-year (10 exercises) by subscription for the magazine for one year (\$65) or pay (\$20) per ar-

ticle. After the payment, participants will receive their **membership number** and will be able to attend to the program.

How to earn CME credits? Once the reader attends the distance-learning program, he/she can earn credits in three easy steps:

1. Read the articles.
2. Take the exercises
3. Fill in the Questionnaire and Submit the answers by Fax (+971 4 36868883) or

Email: info@cappmea.com

After submission of the answers, (name and membership number must be included for processing) they will receive the Certificate with unique ID Number within 48 to 72 hours.

Articles and Questionnaires will be available in the website after the publication.

www.cappmea.com

EARN 20_mCME credit hours

Accredited by Health Authority - Abu Dhabi

www.cappmea.com

E-mail: info@cappmea.com / info@dental-tribune.ae

Emergency dental implant procedures

Drs. Nicholas Caplanis and Jaime Lozada

Patients often present to the office with unscheduled emergency conditions that require immediate tooth removal.

These situations have become increasingly complex to deal with given the myriad available treatment options, which impact the treatment approach and methodology of both tooth extraction as well as provisionalization.¹

Unrestorable crown and root fractures are often ideal clinical scenarios for immediate implant placement given the frequent lack of overt infection and alveolar bone damage, which is often associated with other emergency conditions such as endodontic

therapy was performed, specifically, endodontic treatment, post and core buildup and a tooth-supported crown.² Immediate implant placement following an emergency extraction should therefore be an integral part of emergency treatment.

A one-year prospective study reported a 100 percent implant success rate and also suggested improved esthetic outcomes are achieved following this approach when compared to extraction alone without implant placement.⁵ The ability to quickly and effectively treat these emergency scenarios improves patient satisfaction, facilitates patient management and is a tremendous clinical service.

Therefore, the dental office and team should be well-equipped, or referral guidelines be effectively established, to allow for efficient and predictable dental implant placement during these types of emergency appointments. The following two clinical case reports describe a simple and effective process to treat hopelessly fractured teeth using dental implants and either a bonded restoration as a provisional or a provisional placed immediately on the implant.

Patient 1

A 65-year-old Asian female presents for a new patient emergency exam, with an oblique crown and root fracture affecting her maxillary right central incisor. The fracture occurred spontaneously while eating, involved the entire facial surface of the tooth and extended

to the alveolar crest (Figs. 1a, 1b). The clinical crown exhibited severe mobility and

was painful upon palpation and percussion.

The prognosis was poor and extraction was advised.

Treatment options to replace the tooth were discussed and included a fixed partial denture as well as an implant-supported crown. Given the excellent condition of the adjacent teeth as well as the patient's prior history of having successful dental implant-supported restorations, she elected to have an implant placed.

The crown portion of the tooth was easily removed and, given its excellent condition, was retained to be used as a bonded provisional (Fig. 1c). The tooth root was extracted atraumatically without flap elevation and the socket debrided, irrigated and evaluated with a periodontal probe. The extraction defect had minor horizontal bone loss associated with a reduced periodontium secondary to a prior history of periodontitis, but the adjacent socket walls including the buccal crest were otherwise intact. Therefore the defect appeared amenable for immediate implant placement. A 4.3 x 16 mm Replace® Select implant (Nobel Biocare™) was placed and utilized the entire length of the alveolus and engaged the nasal floor, in order to achieve effective primary stability (Fig. 1e). After implant placement, the residual socket defect was grafted with a composite anorganic bovine bone matrix (BioOss® Osteohealth®) and a demineralized cortical bone allograft (Ora-Graft® LifeNet®). Composite was bonded to the fractured surface of the clinical crown in order to develop an ovate surface to maintain soft tissue esthetics. The modified clinical crown was then bonded to the adjacent teeth and served as a primary provisional restoration (Fig. 1d). The patient was then referred back to her restorative dentist the next day to fabricate an immediate provisional supported by the implant. The emergency appointment including the extraction, placement of the implant, grafting of the residual socket defect and bonding of the primary provisional restoration took approximately one hour of clinical time.

Patient 2

A 35-year-old female presented at the emergency clinic of Loma Linda University School of Dentistry and was immediately referred to the Center for Implant Dentistry. She complained of trauma to her maxillary anterior dentition after an alleged assault, a "blow to the face," two days previously. Upon examination, the maxillary left

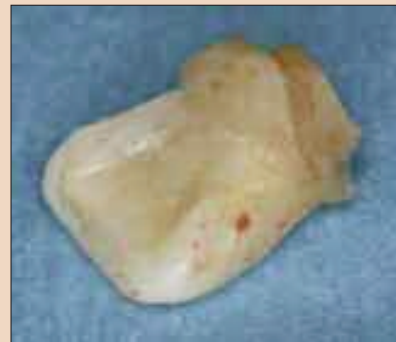

Fig. 1c: Intact clinical crown to be used as a bonded provisional.

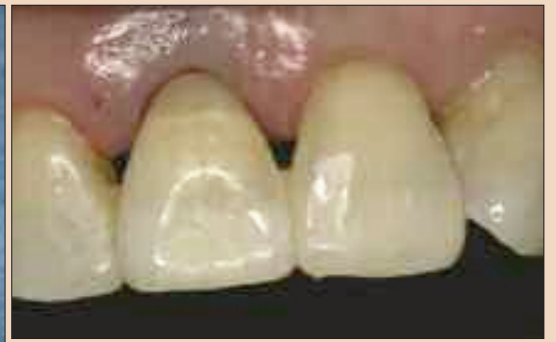

Fig. 1d: Fractured crown bonded to adjacent dentition serving as a primary provisional.

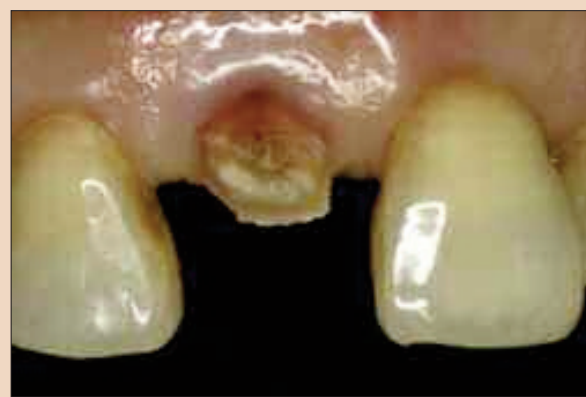

Fig. 1a: Emergency presentation of unrestorable crown and root fracture of tooth #8.

and periodontal abscesses. Failure to perform immediate implant placement or site preservation during the emergency visit often leads to a loss of alveolar bone, which greatly impacts dental implant treatment success. When comparing the excellent long-term success rates of implants with the guarded long-term prognosis of a badly fractured tooth requiring endodontic treatment, crown lengthening surgery, and a post and core buildup, extraction and site preservation or immediate implant placement is frequently the ideal treatment approach.

A clinical study of 554 fractured teeth reported a 20 percent failure rate when conventional




Fig. 1b: Radiograph of oblique crown and root fracture of tooth #8.

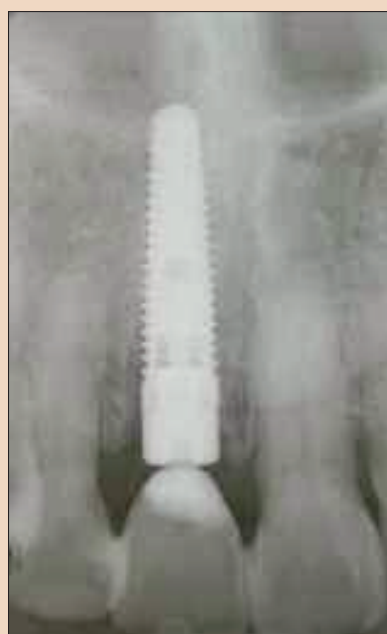

Fig. 1e: Radiograph of immediate implant placement with bonded provisional.

central incisor was partially fractured at mid root and exhibited grade III mobility (Fig. 2a). The left lateral incisor was tender to percussion and exhibited grade 1 mobility, but it recorded a negative response with ethyl chloride and electronic pulp testing.

The patient was then scheduled to undergo an emergency procedure at the clinic consisting of atraumatic extraction of the affected tooth and immediate implant placement with immediate provisionalization. The fractured tooth was extracted and the remaining root fracture was removed utilizing a periosteal instrument (Fig. 2b). The alveolus was curetted and no bone fenestration was noted. A Nobel Active dental implant was used to replace the extracted tooth (Fig. 2c). The osteotomy was performed palatal to the alveolus in order to obtain maximum stabilization for the implant.

The implant was seated at 55 nc stability, which made the clinical situation viable for immediate provisionalization. A prefabricated abutment was placed and hand torqued to provide the support for the acrylic resin restoration. The provisional crown was then relieved from all occlusal contacts (Fig. 2d). Intraoperative radiographs revealed adequate position of the implant in relation to the adjacent dentition and bone implant

level. The emergency dental implant procedure should be considered a viable and often preferable treatment approach to treat emergency situations that ultimately lead to tooth loss such as root fractures. When appropriate, immediate provisionaliza-

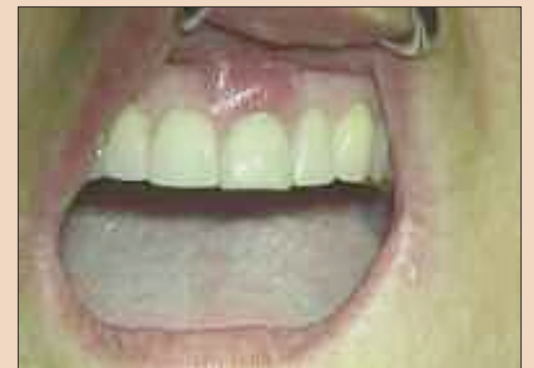

Fig. 2a: Trauma to the maxillary left central incisor with horizontal root fracture.

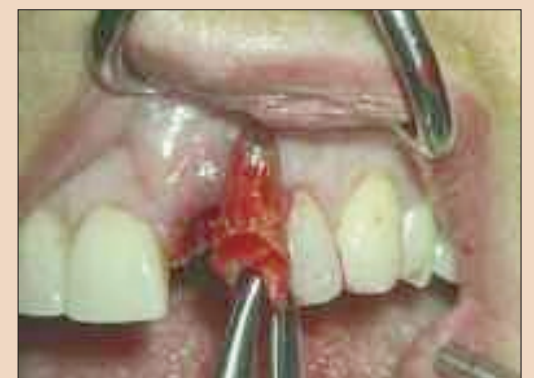

Fig. 2b: Periosteal instrument used for extraction of fractured root.

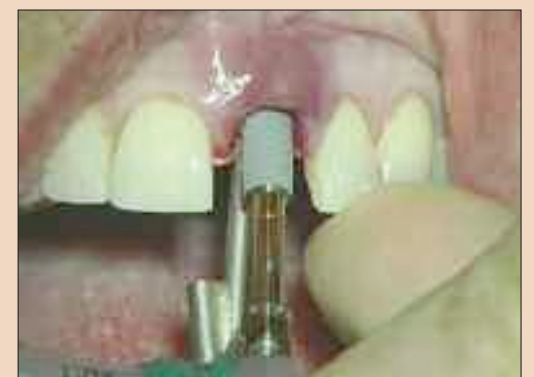

Fig. 2c: Immediate implant placed achieving excellent primary stability.

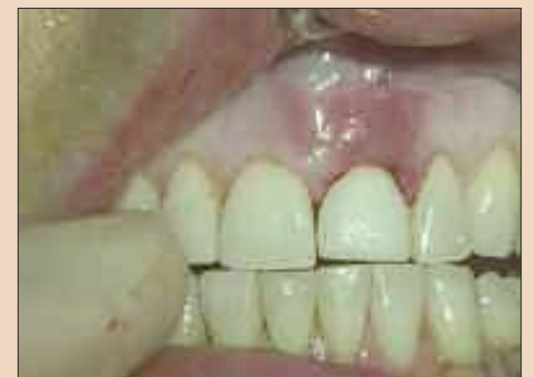

Fig. 2d: An immediate acrylic restoration used as a provisional.

tion or bonding of the fractured crown can be used as a provisional restoration.

References

1. Iasella JM et al. Ridge preservation with freeze-dried bone allograft and a collagen membrane compared to extraction alone for implant site development: A clinical and histologic study in hu-

- mans. J. Periodontol 2005 74(7): 990-9.
2. Cvek M, Tsilingaridis G, Andreasen JO. Survival of 534 incisors after intraalveolar root fracture in patients aged 7-17 years. Dent Traumatol. 2008 Aug; 24(4):379-87.
 3. Caplanis N, Kan J, Lozada JL. Extraction defect assessment, classification and management. Journal of the California Dental Association. 2005; 33(11): 853-865.
 4. Wöhrle PS. Singletooth replacement in the aesthetic zone with immediate provisionalization: fourteen consecutive case reports. Pract Periodont Aesthet Dent. 1998 Nov-Dec; 10(9):1107-14.
 5. Kan JY, Rungcharassaeng K, Lozada J. Immediate placement and provisionalization of maxillary anterior single implants: 1-year prospective study. Int J Oral Maxillofac Implants. 2003 JanFeb; 18(1):51-9.

Low fluoride toothpaste no good for children

LONDON, UK: Children's toothpaste that contains low concentrations of fluoride fails to effectively combat tooth decay. For optimal prevention of cavities in children over age six, toothpastes should contain at least 1,000 parts per million of fluoride, according to a study carried out by the University of Manchester School of Dentistry. Toothpaste containing fluoride concentrations of less than this is as ineffective as toothpaste with no fluoride at all.



AD

About the authors



Dr. Nick Caplanis

Dr. Nick Caplanis is an assistant professor and part-time faculty member within the graduate program in implant dentistry at Loma Linda University School of Dentistry. Caplanis has a unique background with formal residency training in the inter-related fields of implant surgery, prosthodontics and periodontics. He is board certified and a diplomate of both the American Board of Periodontology and the American Board of Oral Implantology and is a fellow of the American Academy of Implant Dentistry. He was also the general meeting chairman for the 57th annual meeting of the AAID, which was held in San Diego from Oct. 29-Nov. 1. Caplanis maintains a full-time private practice limited to periodontics and dental implant surgery, in Mission Viejo, Calif.

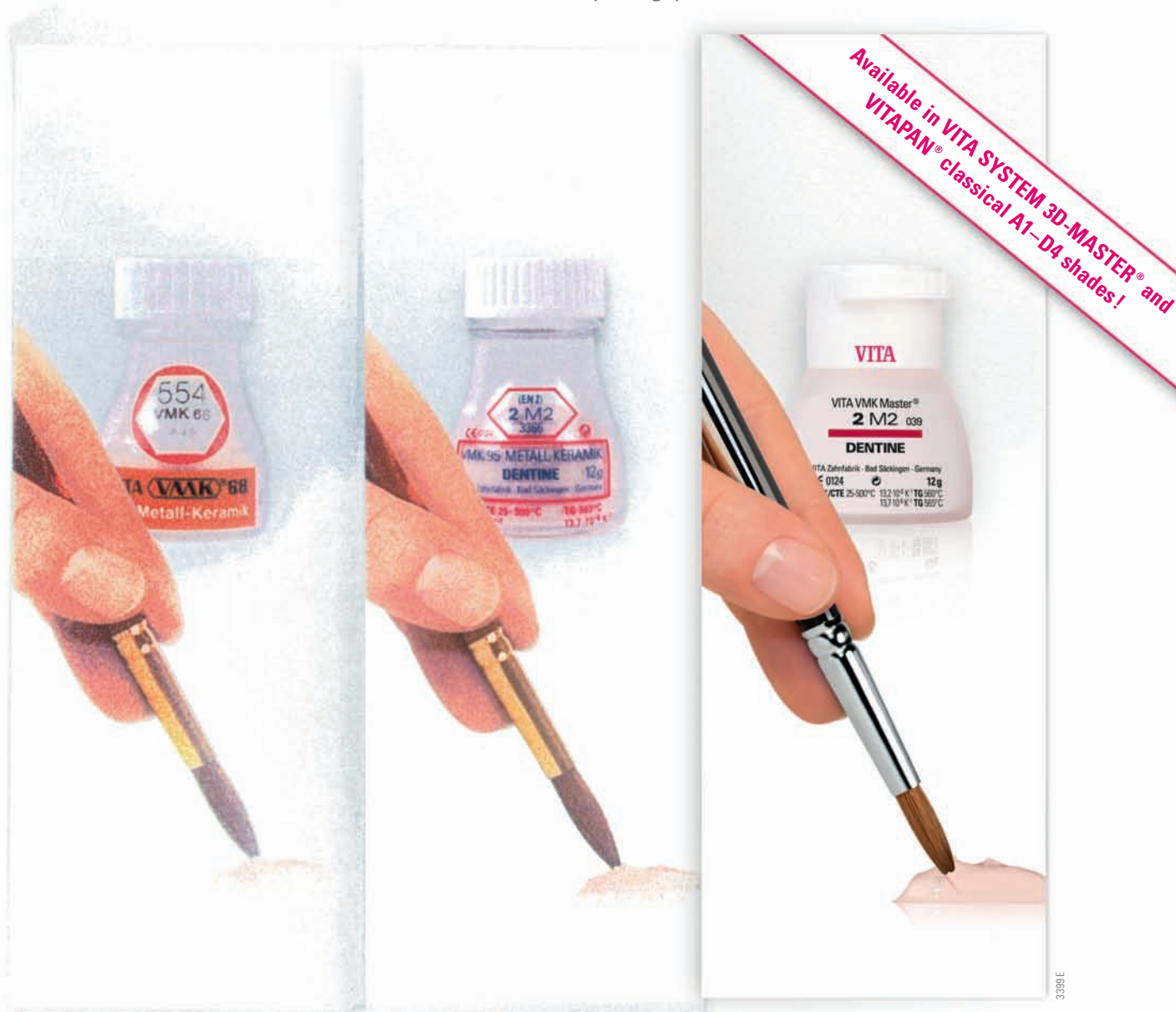

Dr. Jaime Lozada

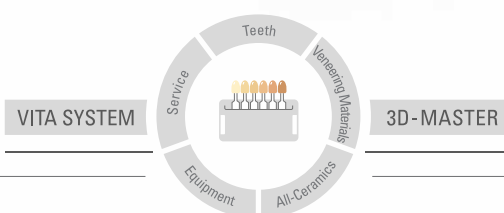
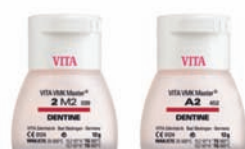Dr. Jaime Lozada is the director of the graduate program in implant dentistry and a professor at Loma Linda University School of Dentistry. Lozada has been involved with implant dentistry for more than 20 years. He completed his residency in implant dentistry in 1987 and his graduate prosthodontics certificate in 1997. Lozada has trained hundreds of residents and fellows in the latest techniques in oral implant surgery and prosthodontics. Lozada is a fellow and past president of the American Academy of Implant Dentistry and a diplomate of the American Board of Implant Dentistry. He is well-published and lectures nationally and internationally on implant dentistry and maintains a faculty practice limited to implant dentistry and prosthodontics at the Loma Linda University School of Dentistry.

VITA VMK Master® Innovation in the third generation!

The new VITA metal ceramic with the familiar layering you're accustomed to.



Available in VITA SYSTEM 3D-MASTER® and VITAPAN® classical A1-D4 shades!



VITA

40 years. 3 letters. 1 original. For generations VMK has been the synonym for metal ceramics. With the power of the original, VITA VMK is the benchmark for easy, safe and cost-efficient handling. With VITA VMK Master this is more true than ever. Thanks to its firing temperature and chemical and physical

characteristics, VITA VMK Master is best suited for the veneering of non-precious metal alloy frameworks. Furthermore, the standard layering continues to provide the most simple handling. VITA VMK Master stands above all for one thing: quality without compromise./www.vita-zahnfabrik.com