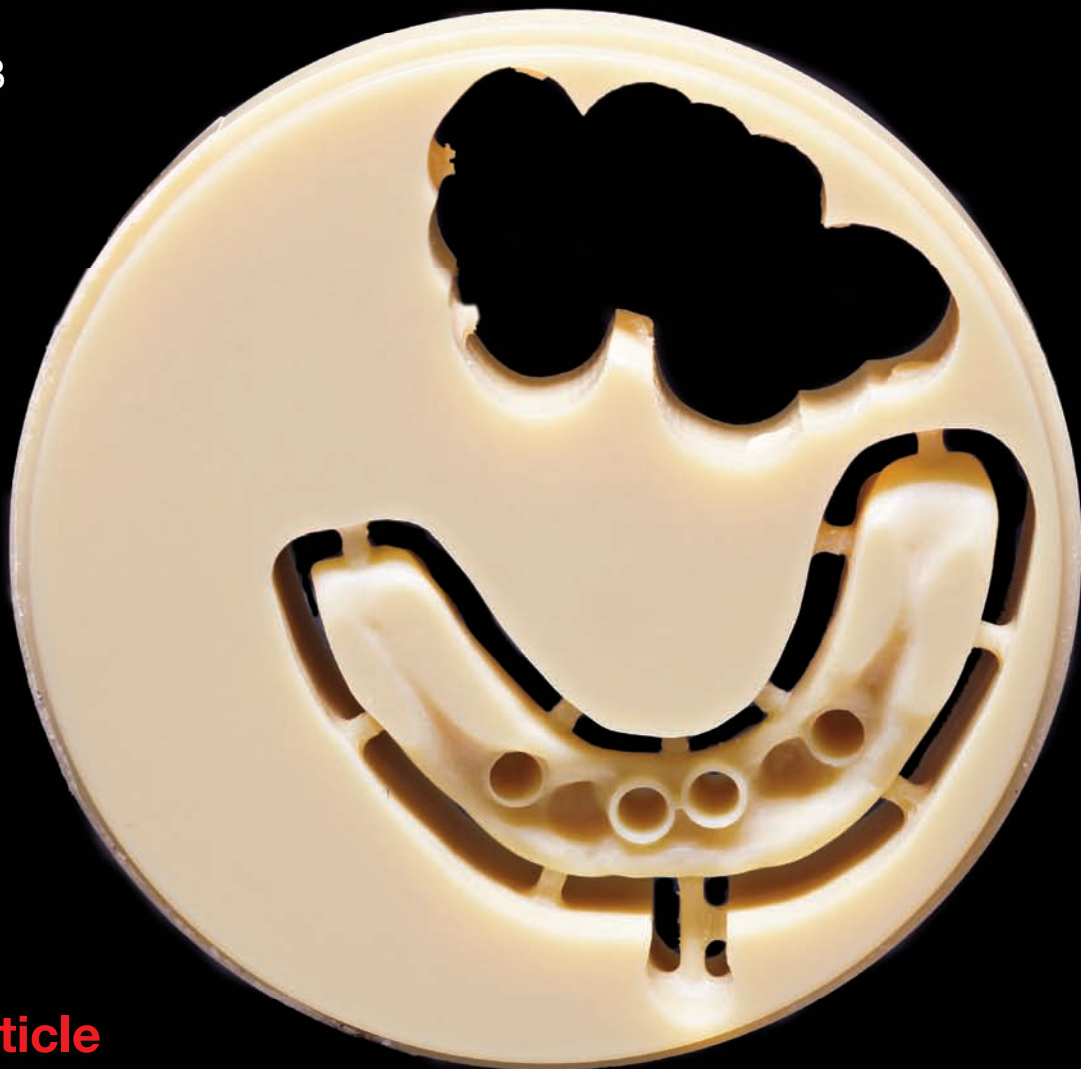

CAD/CAM

international magazine of digital dentistry

3²⁰¹³



| **CE article**

CAD/CAM technology:
Setting the standard and achieving success

| **case report**

Bridge construction in the anterior region of the maxilla

| **feature**

Dentures produced using
3-D printing versus casting and milling



CROIXTURE

PROFESSIONAL MEDICAL COUTURE



EXPERIENCE OUR ENTIRE COLLECTION ONLINE

WWW.CROIXTURE.COM

Dear Reader,

_ It is a great honour and distinct pleasure to present the third 2013 issue of **CAD/CAM** to you! 2013 is a memorable year for dentistry. The 35th International Dental Show in Cologne in Germany will be remembered for the significant number of companies exhibiting upgrades and introducing new products in the field of CAD/CAM and digital dentistry. Countless booths with eye-catching designs and product displays demonstrated the latest trends and technological developments, including CAD/CAM chairside/in the laboratory, computer-guided implantology, 3-D dental imaging, CAD/CAM materials, computerised orthodontics, digital impressions, software, management and education. IDS established that digital dentistry is no longer the future; it is already the present.

In this issue of **CAD/CAM**, you will find beautifully illustrated and well documented articles that report on CAD/CAM restorations, CAD/CAM lingual orthodontic system and implantology.

I am pleased to announce that the **CAD/CAM** is the official publication of the second Asia Pacific CAD/CAM and Digital Dentistry International Conference, organized by CAPP Asia, which will take place in Singapore on 4 and 5 October 2013. The event is already becoming a major platform for shaping the future of digital dentistry in the Asia Pacific region. It will attract the crème de la crème of opinion leaders in dentistry, who will be sharing their knowledge and experience with the world's dental elite. The objectives of the main scientific session and the dental technicians' parallel session will be to exchange valuable knowledge, to help cultivate a spirit of collaboration in the dental team, and to enable networking. These sessions are expected to spark heated discussions on the latest methods and techniques and on how to improve them, thus paving the way forward in dentistry. The exhibition will provide hands-on access to the latest digital dentistry systems. The event will facilitate direct interaction with the leading dental manufacturers, discussions on the scientific relevance of their products, and gathering of useful feedback from current and prospective users. It is from this valuable feedback that the companies taking part in the event will be able to develop their 3-D technologies further, with a view to best meeting the needs of the dental team.

We are proud to welcome to this year's conference in Singapore some of the most exciting names in digital dentistry, who will be presenting papers during the conference: Dr Lutz Ritter, Germany; Dr Andreas Bindl, Switzerland; Dr Eduardo Mahn, Chile; Prof. Tae Weon Kim, South Korea; Morten Ryde, DT, Denmark; Joachim Maier, MDT, Germany; Dr Bernd van der Heyd, MDT, Germany; Werner Gotsch, MDT, Germany; Dr Chanchai Kingawattanagul, Thailand; Dr Simon Kold, Denmark; Dr Khaled Abouseada, Egypt; and Dr Kurt Dawirs, Germany. A parallel session targeted at dental technicians will be held on the second day of the conference, with presentations by Rik Jacobs, the Netherlands; Carsten Kelm, Germany; Ike Intoratat, Thailand; Barış Çakır, Germany; Christopher Adamus, DT, Poland; Simon Docker, UK; and Ralf Oppacher, MDT, Germany.

In December 2012, CAPP joined the elite group of international continuing medical education providers who are accredited by the American Dental Association. Hence, delegates attending can expect to enjoy cutting-edge presentations in the dental field and to benefit from top-quality scientific discussions.

The conference exhibition will be honoured by the presence of the leading dental manufacturers, including Sirona, Ivoclar Vivadent, 3Shape, DeguDent, AmannGirrbach, Wieland Dental, Roland DG, Dentegris and eCligner, all of which will be showcasing their latest masterpieces. There will also be other important industry players at the conference. We look forward to welcoming you to the vibrant city of Singapore.

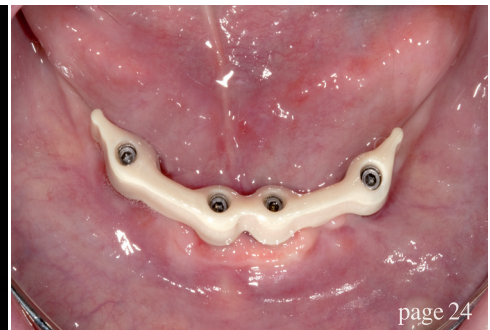
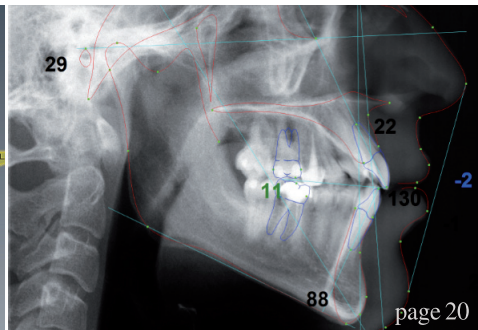
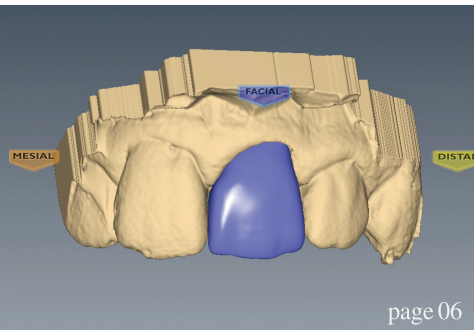
Yours faithfully,



Tzvetan Deyanov
BDM & Business Partner CAPP & Dental Tribune Middle East & Africa



Tzvetan Deyanov
BDM & Business Partner CAPP &
Dental Tribune Middle East & Africa



editorial

03 **Dear Reader**
| Tzvetan Deyanov

CE article

- 06 **E4D chairside CAD/CAM restorations: Case presentations and lessons learned**
| Dr Wally Renne, USA
- 12 **Using in-office CAD/CAM technology and lithium disilicate to fabricate efficient and predictable restorations**
| Dr John C. Schwartz, USA
- 16 **CAD/CAM technology: Setting the standard and achieving success**
| Dr Matthew Krieger, USA

case report

- 20 **Non-extraction treatment of a Class II case with a missing mandibular central incisor using a CAD/CAM lingual orthodontic system**
| Dr Khaled M. Abouseada, Saudi Arabia
- 24 **Immediate restoration in the edentulous mandible According to the Maló procedure using the CAMLOG Guide System and Vario SR abutments**
| Dr Ferenc Steidl & Sebastian Schuldes, Germany
- 28 **Bridge construction in the anterior region of the maxilla**
| Dr Steffen Wolf, Germany

feature

32 **Dentures produced using 3-D printing versus casting and milling**
| Interview with Master Dental Technician Dieter Spitzer

industry news


- 36 **Experience business solutions with Straumann CARES customized prosthetics solutions**
| Straumann
- 38 **3Shape releases CAD solution for post and core restorations**
| 3Shape
- 40 **From veneers to bridges: Zirconia reinforced composite**
| Schütz Dental
- 42 **Nobel Biocare announces new digital workflow and new regenerative product at Global Symposium in New York**
| Nobel Biocare

meetings

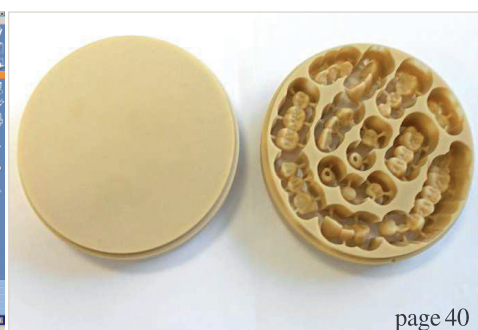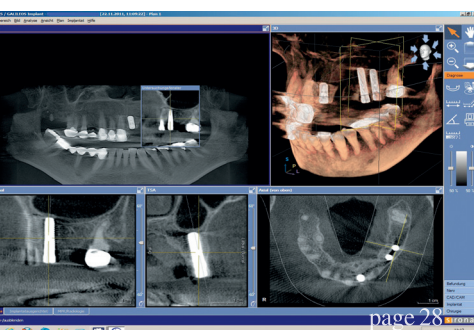
- 46 **IDS 2013 sets new records**
- 48 **International Events**

about the publisher

- 49 | submission guidelines
- 50 | imprint

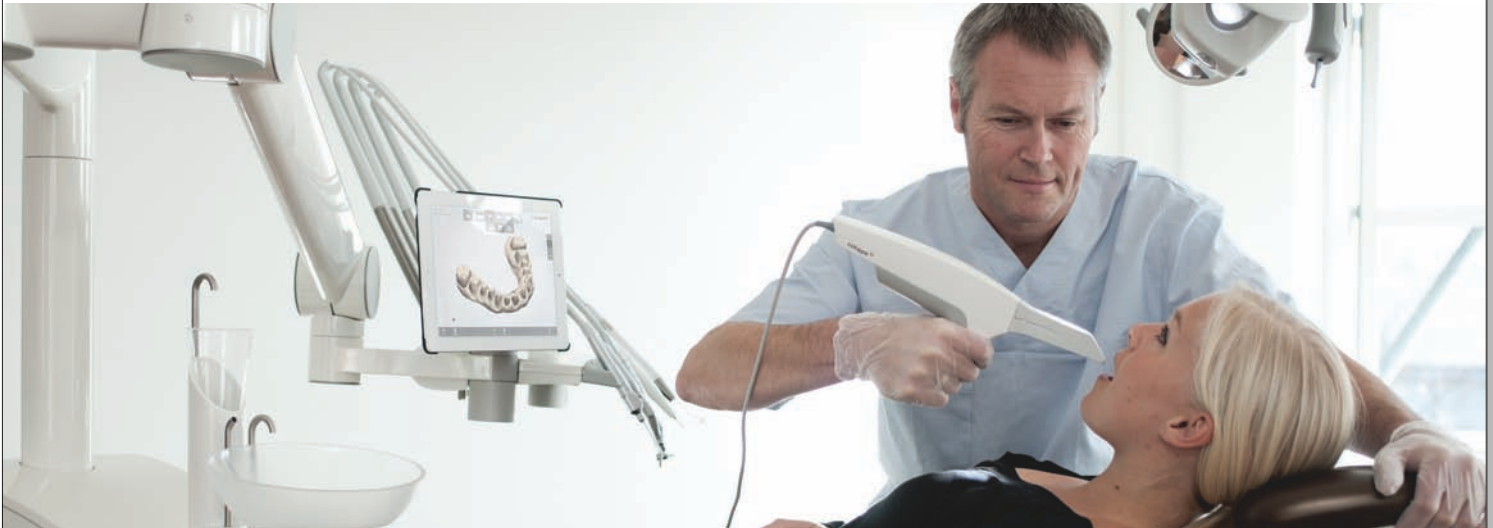

Cover image courtesy of Dr Ferenc Steidl & Sebastian Schuldes.



3Shape TRIOS®

Impression-taking has never been easier



SCAN IN COLOR



3Shape TRIOS® is the next-generation intraoral digital impression solution. Easily create accurate digital impressions and send cases directly to the lab with a single click.

3Shape TRIOS®

- Spray- and powder-free for optimal accuracy and patient comfort
- Optimized Ultrafast Optical Sectioning software - now 40% faster
- Wide range of indications, including implant abutment cases
- Instant impression and occlusion validation and smart edit scan tool
- Autoclaveable tip with anti-mist heater
- Choose TRIOS Color or TRIOS Standard

TRIOS® Pod solution

Use TRIOS® with your iPad, laptops, PC's in your treatment rooms, or with the PCs integrated in your chair units.



Stay up to date with the latest news, product announcements, special offers, articles, and more

Sign up for our newsletter – Digital Trends

Scan the QR code to register.



Follow us on:



E4D chairside CAD/CAM restorations: Case presentations and lessons learned

Author _ Dr Wally Renne, USA

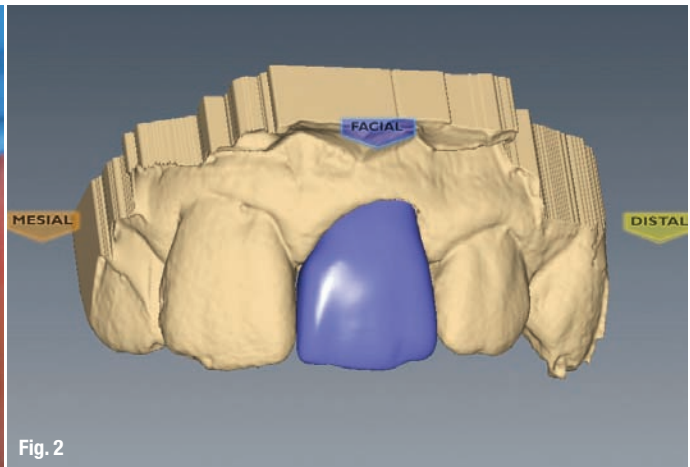
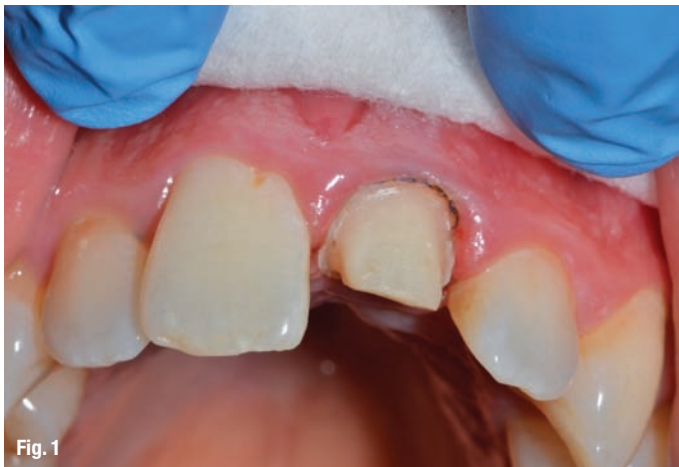

Fig. 1 Patient presents with crown missing from tooth #9.

Fig. 2 E4D Dentist System is used to take a digital impression, then the restoration is designed using E4D DentaLogic Software.

(Photos courtesy of Dr Wally Renne)

Despite the increasing popularity of the current CAD/CAM laboratory systems and continuing technical advances, some clinicians have remained reluctant to incorporate the very same CAD/CAM techniques into their clinical chairside practices. Two often-repeated misconceptions relate to the perceived lack of strength and lack of aesthetics of the ceramics available for use with these systems. A wide variety of materials are available to use with the E4D Dentist System (D4D Technologies), and each has a separate set of aesthetic and mechanical properties that must be considered. This article will review current materials and show clinical examples of restorations made using the E4D Dentist System.

One distinct advantage of chairside CAD/CAM is having the ability to make restorations in a single visit from a solid pre-manufactured block that is essentially flawless in construction. A pre-manufactured block is made in ideal conditions, and as a result, has an ideal density with none of the residual porosity found in many layered or pressed porcelains.

Porosities may act as a weak point and lead to the build-up of internal tensile stress in the ceramic and eventually cause a catastrophic failure. Monolithic restorations have several distinct advantages over

layered restorations when it comes to mechanical properties. Layered restorations are often veneered with weak feldspathic glasses that can chip or break, especially if not supported properly by the framework.

Furthermore, one does not need to worry about delamination and micro-chipping of the veneering porcelain, which has been reported to be as high as 25 per cent for porcelain-fused-to-zirconium restorations.¹

IPS Empress (Ivoclar Vivdent) is a feldspathic glass with approximately 45 % leucite crystals for dispersion strengthening. The 5 µm leucite crystals improve strength and fracture toughness by acting as "road-blocks" to prevent crack propagation. IPS Empress is an aesthetic material and is available in polychromatic blended shades that give the restoration a layered appearance. Empress Multiblock has a flexural strength around 160 MPa and requires isolation and attention to detail when bonding to ensure long-term success.

IPS Empress has been on the market for approximately 24 years, and as a result, good clinical research on the longevity of these restorations exists in the literature. A literature review conducted by Brochu and El-Mowafy evaluated and summarized six clinical studies that met their inclusion criteria. They

_ce credit CAD/CAM

By reading this article and then taking a short online quiz, you can gain ADA CERP CE credits. To take the CE quiz, visit www.dtstudyclub.com. The quiz is free for subscribers, who will be sent an access code. Please write support@dtstudyclub.com if you don't receive it. Non-subscribers may take the quiz for a \$20 fee.



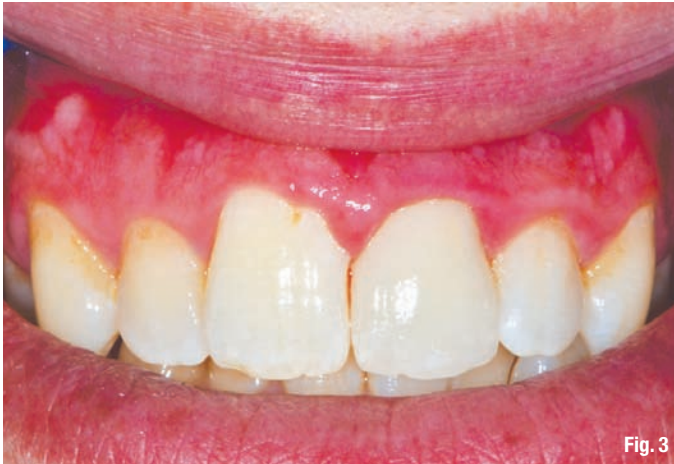

Fig. 3

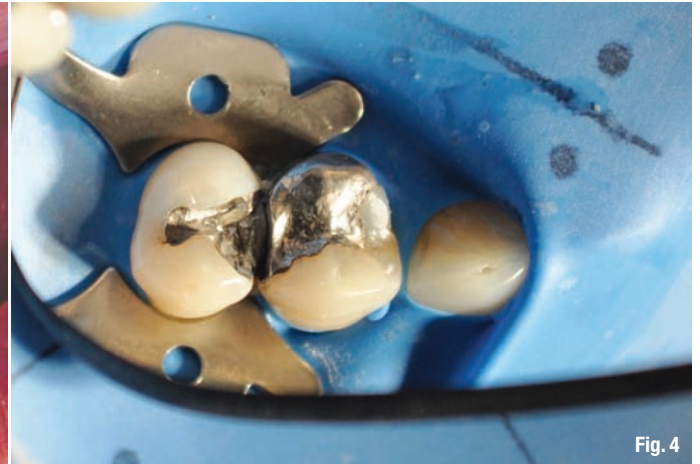

Fig. 4

concluded the survival rates for IPS Empress inlays and onlays ranged from 96 per cent at 4.5 years to 91 per cent at seven years. IPS Empress crowns had a survival rate ranging from 92 per cent to 99 per cent at three to 3.5 years.

For both crowns and onlays, most failures were due to bulk fracture.² In general, IPS Empress has higher failure rates in the posterior than the anterior and higher fracture rates on molars compared with premolars.³⁻⁶ Therefore, IPS Empress is an excellent material choice in the anterior for aesthetically demanding patients. However, alternative materials exist for posterior use.

Case presentation

A new patient called the office and said his crown "exploded." He presented to the clinic with the crown missing on tooth #9 (Fig. 1). The E4D Dentist System was used to make a digital impression of the preparation and the bite registration. Using the intuitive design features in the E4D software, a restoration was designed (Fig. 2). An IPS Empress CAD Multi A1 restoration was milled and characterized using IPS Empress Universal Stains. For delivery, the crown

was prepared by etching with 4.9% hydrofluoric acid for 60 seconds and silanated for 60 seconds with Monobond-Plus (Ivoclar Vivadent). The tooth was pumiced; Optibond XTR (Kerr) was applied and cured for 20 seconds; and Nexus 3 resin cement (Kerr) was used to bond the crown (Fig. 3).

The use of IPS Empress has been selective partly because of the popularity of IPS e.max CAD (lithium disilicate). IPS e.max CAD comes in a lithium metasilicate state (blue colour) that is not fully crystallized but can be easily machined. The milled restoration is then placed in the oven for 19 to 26 minutes to crystallize the glass. During crystallization, the lithium metasilicate crystals are replaced with lithium disilicate crystals, increasing flexural strength from around 160 MPa to 360 MPa.

IPS e.max was introduced to the market in 2006. Gehrt and colleagues followed 104 IPS e.max crowns in 44 patients and found the corresponding survival rate for all restorations was 97.4 per cent after five years and 94.8 per cent after eight years of clinical service with location not significantly impacting survival rate.⁷ These results were for IPS e.max press restorations that were cut back and veneered. It

Fig. 3 An IPS Empress DAC Multi A1 restoration is milled and custom characterized using IPS Empress Universal Stains.

Figs. 4-6 In this case, a patient who was not happy with the aesthetics of an amalgam restoration presented with recurrent caries on the mesial of tooth #13. The E4D Dentist System was used to make a digital model, and restorations were milled out of IPS e.max CAD HT A2 blocks.

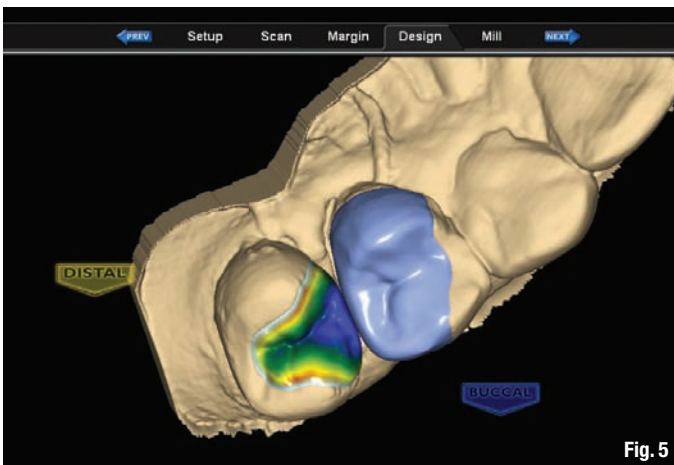


Fig. 5

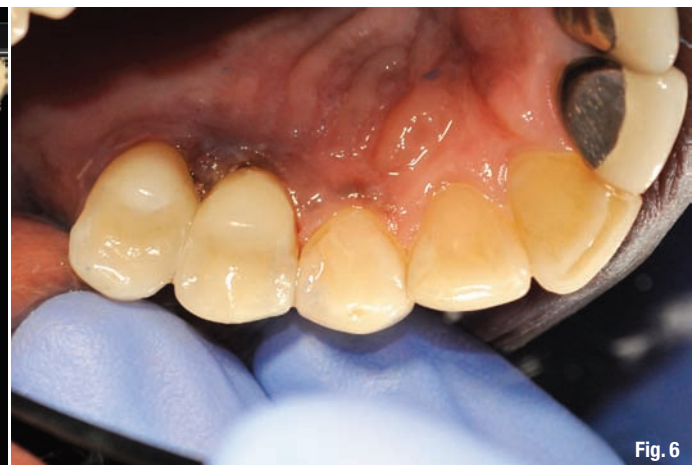

Fig. 6

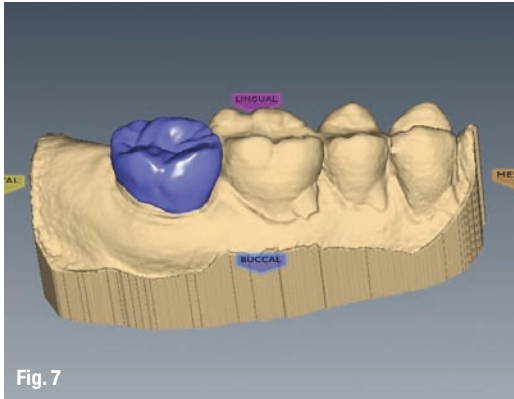


Fig. 7

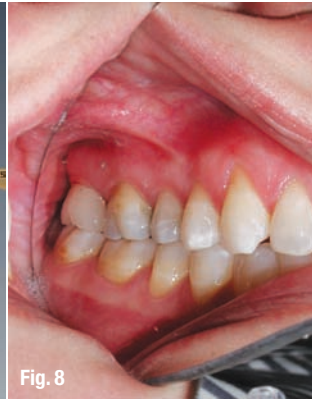

Fig. 8

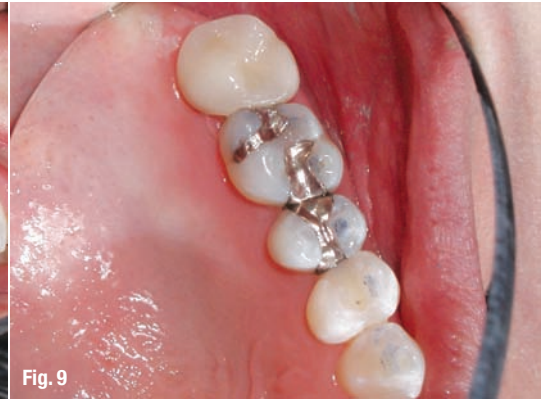

Fig. 9

Figs. 7–9 With the strength of IPS e.max, predictable restoration of second molars using the E4D Dentist System is possible.

can be hypothesized that monolithic chairside milled IPS e.max may perform better.

In a 10-year study, Kern et. al. found three-unit fixed partial dentures (FPDs) made from monolithic lithium disilicate ceramic showed five- and 10-year survival and success rates that were similar to those of conventional metal-ceramic FPDs.⁸ They concluded that for the monolithic lithium disilicate FPDs, the calculated survival rate was 100 per cent after five years and dropped to 90.8 per cent (when considering only catastrophic ceramic fractures) and 87.9 per cent (when considering catastrophic ceramic fractures and biological failures) after 10 years.⁸ It is interesting to note that all catastrophic failures occurred in molars.⁸ Single-unit monolithic IPS e.max can be expected to perform better than FPDs in this study.

Interestingly for both clinical studies mentioned, the restorations that were conventionally cemented performed just as well as those that were bonded.^{7,8} Therefore, assuming proper retention and resistance form has been achieved, it is acceptable to conventionally cement monolithic IPS e.max restorations.

Because of the incredible flexural strength of IPS e.max, some clinicians were concerned that

IPS e.max may be aggressive on the opposing dentition. In a clinical study, Silva et. al. found IPS e.max to be more gentle on the opposing enamel than feldspathic ceramics with a wear rate on enamel similar to natural definition.⁹ Chairside CAD/CAM allows the clinician to predictably provide more conservative restorations, such as IPS e.max inlays and onlays, that have a longevity similar to full coverage crowns.¹⁰ The advantage to onlays over crowns is the conservation of healthy tooth structure and subsequent prolonging of the tooth's life cycle.

Chairside milled onlays are an ideal restoration compared with direct resins. Despite their popularity, large posterior resin-based composite (RBC) restorations last only six to seven years.^{11,12} RBC restorations have poor clinical longevity, higher recurrent caries and greater need for replacement compared with the alternative, high-copper amalgam.^{13–17}

Amalgam and cast gold are not a popular option for many patients because of aesthetic concerns, and an E4D onlay restoration is the ideal treatment for many patients who refuse these alternative treatments. Milled inlays and onlays have been shown to be very successful.

Figs. 10 & 11 In this case, a 37-yearold male presented with severe acid erosion and abrasion from gastroesophageal reflux disease and bruxism.

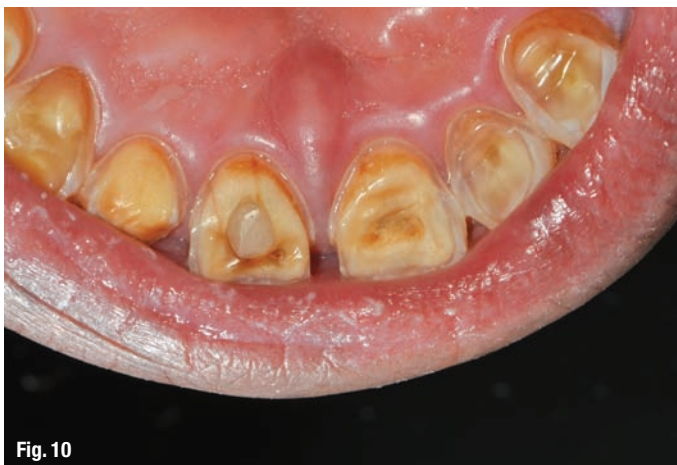

Fig. 10

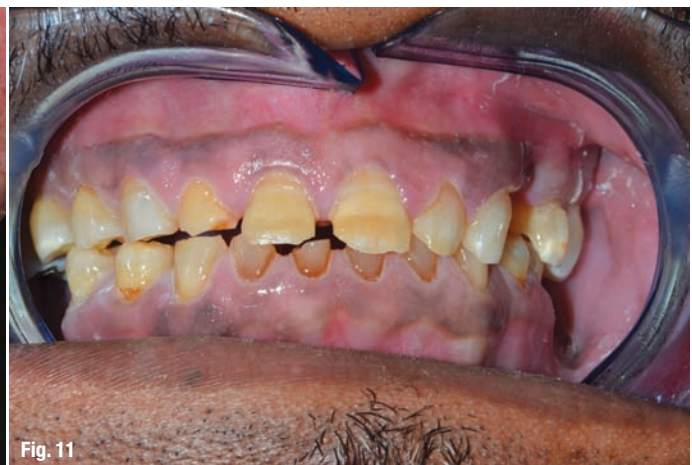

Fig. 11

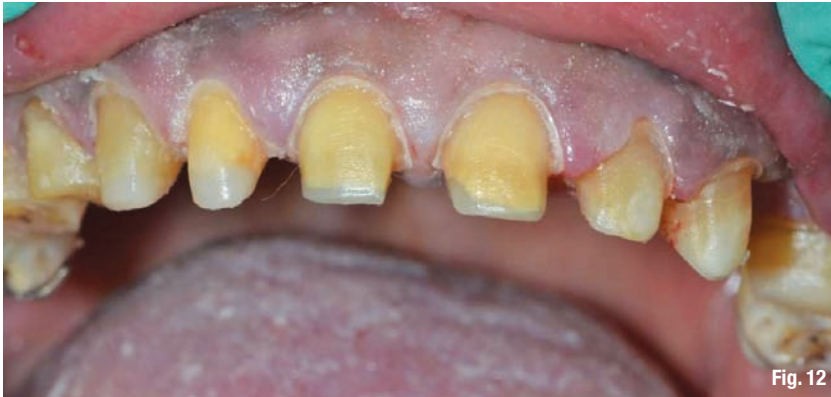

Fig. 12

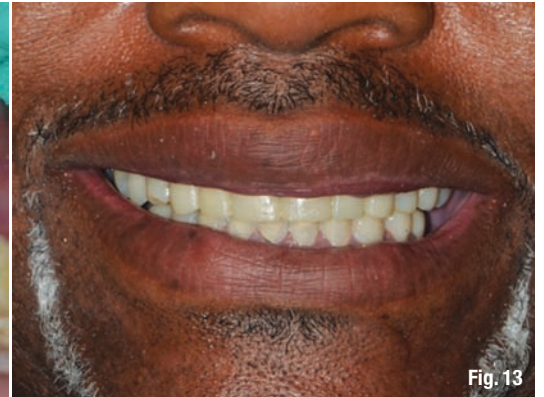

Fig. 13

One study found a success rate of 90.4 per cent after 10 years with older feldspathic ceramics as well as older milling and design technology.¹⁸

In this case, the patient was not happy with the aesthetics of the amalgam restorations, and she had recurrent caries on the mesial of tooth #13. The E4D Dentist System was used to make a digital model, and the design software proposed well-contoured, anatomical restorations that were milled out of e.max CAD HT A2 blocks. For delivery, the restorations were prepared by etching with 4.9 % hydrofluoric acid for 20 seconds and silanating for 60 seconds with Monobond-Plus (Ivoclar Vivadent). The tooth was pumiced clean; Optibond XTR (Kerr) was applied and cured for 20 seconds; and Nexus 3 resin cement (Kerr) was used (Figs. 4–6).

Despite the benefits of onlays, single-unit crowns are still the preferred restoration for the general dentist, and the E4D Dentist System fabricates excellent restorations with a short learning curve. With the strength of IPS e.max, predictable restoration of second molars using the E4D Dentist System is possible (Figs. 7–9).

Once the learning curve of single-unit restorations is mastered, it will not be long before the benefits of the E4D Dentist System become apparent for more complicated cases. A 37-year-old male presented for a consult for dentures. He had been to several dentists and an immediate denture was the treatment plan he had selected. He presented with severe acid erosion and abrasion from a combination of gastroesophageal reflux disease (GERD) and bruxism (Figs. 10 & 11).

Occlusal examination revealed a lack of anterior guidance and posterior support. The lateral pterygoids were sensitive to palpation, and upon visual examination it was noted that he had hypertrophic masseters. Lip commissures were folded and he appeared to have a collapsed vertical dimension of occlusion (VDO). He did not close in a repeatable

position and had a severe anterior deviation from centric relation.

When evaluating the location of the gingival margins it was determined that compensatory eruption had taken place. However, based on the closest speaking space during the production of sibilant sounds, the patient had excess freeway space.

It was determined that the patient lost vertical dimension of occlusion, and therefore compensatory eruption did not keep up with the rate of erosion. Two centric-relation (CR) records were made using bimanual manipulation, a custom triad jig and a rigid bite material. The case was mounted on a semi-adjustable articular in centric relation and the mounting was verified with the second CR record.

It was decided (based on freeway space, aesthetics and phonetics) that to recapture the lost VDO the patient needed to be opened 2.5 mm in the anterior; this correlated to around 1 mm in the posterior. A diagnostic wax-up was made. The teeth were prepared and temporized based on the diagnostic wax-up (Figs. 12 & 13). The patient was kept in temporaries for six weeks to verify tolerance of the new vertical dimension, phonetics (particularly "F" and "S" sounds) and CR.

In the provisionals, anterior guidance was established with no balancing interferences during lateral excursive movements. CR was stable and at the end of the six-week trial period the patient was pain-free upon palpation of his lateral pterygoid muscles,

Figs. 12 & 13 After a diagnostic wax-up was made, the teeth were prepared and temporized.

Fig. 14 The E4D Dentist System clone feature copies the occlusion and anatomy of the temporaries exactly.

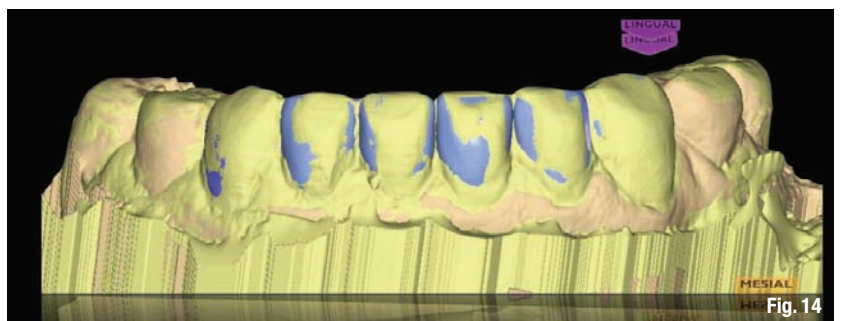


Fig. 14