

DENTAL TRIBUNE

The World's Dental Newspaper • Pakistan Edition



PUBLISHED IN PAKISTAN

www.dental-tribune.com.pk

JANUARY, 2015 - Issue No. 01 Vol.2

6th Dental-Facial
Cosmetic Int'l
Conference attracts
1,527 participants
in Dubai



► Page 2

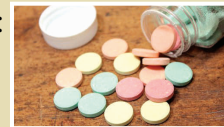Advantages of 3-D
planning for
implants



CLINICAL PRACTICE

► Page 4

Head and neck cancer:
Antacids could
increase survival rate



INTERNATIONAL NEWS

► Page 6

PDA congress to be the biggest dental show in Pakistan

DT Pakistan Report

KARACHI: All arrangements are set to hold the biggest Dental Congress by Pakistan Dental Association which is jointly hosted by PDA Karachi and Sindh zone, this was stated by Dr Asif Niaz Arain the chairman of the congress while talking to Dental News - the media partner for the congress with Badar Expo as the event manager.

The congress is being organized at the Expo center Karachi from 23-25 January and is expected to attract speakers of international standing from overseas and locally. The patron-in-chief of the congress is Dr Inayatullah Padhiar, patrons include Dr Saqib Rashid, Dr Mahmood Shah and Dr Navid Rashid with Dr Ali Farhan as the congress secretary.

The co-chairmen of the congress are Dr Anwar Saeed, Dr Abdul Ghani Pathan and Dr Syed Shah Faisal. The congress committee chairmen include Dr Kashif (scientific), Dr Feroz (Trade), Dr Ahmed Bari (Finance), Dr Nasir (Registration), Dr Imran (Travel & Accommodation), Dr Aizaz (Cultural), Dr Abid Mehmood (Publication), Dr Irshad (security), Dr Musaddiq (Audio Visual) Dr Faizan (student Affairs) and Dr Uzma (Spouse committee).

The congress will have an elaborate scientific programme with pre and post congress workshops to provide maximum knowledge to the participants. The highlight of the congress will be its state of the art lectures delivered by world renowned speakers coming from



around the globe. Local speaker of international stature will also deliver their lectures and conduct workshops.

The congress is fully backed by the largest dental trade exhibition ever held in Pakistan introducing innovative products and offering handsome discounts to the registered participants. The early bird registration ends December 31st, so get going and register now before it is too late.

Dr. Sonny Prince Akpabio -Founder President Commonwealth Dental Association Passes Away

Report by Dr. Fazal Ghani, Glasgow UK

It is with great sadness to announce that Dr Sunday (Sonny) Prince Akpabio, DS, MDS (London) died peacefully after a long illness on 20 November, at the age of 90 years. He is remembered with love by Thelma, Basi and Rachel. A funeral for Dr Akpabio was held on 8th December 2014, at the Church of St John the Baptist, Stone, Buckinghamshire, England (UK). I am fortunate to have been associated with him during my postgraduate studies in UCH Dental School which he was visiting quite often those days.



Continued on page 11

PDA Symposium ACADEMIC EXCELLENCE IN DENTISTRY

DT Pakistan Report

KARACHI: The Pakistan Dental Association central council held its inaugural Symposium titled Academic Excellence in Dentistry sponsored by Close-up and organized by Dental News. The event was largely attended by students, house officers, trainees residents, private practitioners and leading academic professionals from Pakistan's dental community.

The Symposium began with the recitation from the Holy Quran followed by a presentation by Dr Navid Rashid, an enlightening lecture on oral ulcers, their identification, treatment and management. Prof Dr Saqib Rashid President Pakistan Dental Association in his welcome address announced the launching ceremony of the PDA Dental Congress, and urged students and professionals to



make an extra effort to promote the upcoming World Oral Health Day 2015 as well. He said that students are the future of PDA, and Pakistan's entire dental community must join hands and with unity, help strengthen the PDA in working towards social welfare as well as the promotion of quality oral healthcare for all.

President PDA Sindh Dr Mehmood Shah elucidated participants regarding the different activities of dental associations. He stated that the Dental Act in Pakistan must be of critical importance to all dental organizations, and the

students, professional and academic experts must actively contribute in the matters of the Pakistan Dental Association. Shields were then awarded to Dr Navid Rashid and Dr Mehmood Shah as tokens of appreciation, and in recognition of their relentless efforts in the field of dentistry.

After a short tea break, participants were then distributed in two halls to attend simultaneous sessions being presented simultaneously by the distinguished speakers at the event. Dr Syed Abrar Ali presented a highly informative

Continued on page 10

DTMA to host the largest Dental Show in Pakistan - Ashraf Ghauri

DT Pakistan Report

KARACHI: Dental Trade & Manufacturers Association better known as DTMA is all set to host the largest dental show ever held in Pakistan by putting up more than 250 stalls at the Karachi Expo Center 23-25 January 2015. The show is part of the Pakistan Dental Association's dental congress.

Dental News recently interviewed the Vice President of the DTMA Ashraf Ghauri who is the Chairman of this show ably supported by his other team members comprising Altash Butt, Arif, and Fawad to name a few. Talking to Dental News the chairman said that through untiring efforts of his team and the confidence of DTMA members, the forthcoming show will be the



Continued on page 11

6th Dental-Facial Cosmetic Int'l Conference attracts 1,527 participants in Dubai

DT International Report

DUBAI, UAE: The 6th Dental-Facial Cosmetic International Conference 2014 took place on 14-15 November 2014 closing with a total of 1,527 participant

All of us, organizers, speakers, and sponsors spare no time or effort to bring to you the most up to date developments in the various fields of dentistry.” – Dr. Munir Silwadi.



in Jumeirah Beach Hotel Dubai.

The Event Organized by Centre For Advanced Professional Practices (CAPP), Emirates Dental Society (EDS) and co-organized by Saudi Dental Society (SDS) and Lebanese Dental Association (LDA). The event stretched over 5 days including a 2 day conference, 12 Hands-Courses and a Dental Hygienist Day. Newcomers, providers and experts from 34 countries gathered for the 6th time a great number of attendance. There was support from 13 sponsors including Sirona, Ivoclar Vivavent, 3MESPE, Planmeca, Oral-B, KaVo, VITA, KERR, Carestream, Southern Implants, Ritter, MPC and Philips Sonicare.

The Scientific Program

Dr. Munir Silwadi, the conference chairman and scientific program advisor introduced a total of 24 international speakers who shared their experience within the fields of Dental and Facial Cosmetics. “A unique blend of science, clinical knowledge, and cutting edge technology in the field of dentistry and beyond.

Hands-On Courses

A total of 12 Hands-On Courses took place between 12-16 November 2014. Topics included: Indirect Veneers, Veneers vs. Crowns, Direct Veneers, Laser in Modern Day Practices, Esthetic in Same Day Dentistry, Face & Smile Analysis, Polishing will Brighten your smile, Periodontal Instrumentation and Laser in Esthetic Dentistry.

Dental Hygienist Day

Dental Hygienist Day took place on 15 November 2015. Dr. George Sanoop was the Chairman of the Scientific Program which included topics from oral health and orthodontic management, communication, polishing, whitening and sharpening.

Save The Date 2015

In 2015, CAPP will celebrate its 10th year Anniversary of providing top quality continuing dental education in the Middle East and Asia region. This milestone will be celebrated at the 10th CAD/CAM & Digital Dentistry Int'l Conference (08-09, May 2015) and at the 7th Dental-Facial Cosmetic Int'l Conference (13-14 November 2015). Both will take place at Jumeirah Beach Hotel Dubai. The 3rd Asia – Pacific CAD/CAM & Digital Dentistry Int'l Conference will take place at Suntec, Singapore (04-05 December 2015).

DENTAL TRIBUNE

The World's Dental Newspaper • Pakistan Edition

Publisher/CEO

Syed Hashim A. Hasan
hashim.hasan@dental-tribune.com.pk

Editor Clinical Research:

Dr. Inayatullah Padhiar

Editors Research & Public Health

Prof. Dr. Ayyaz Ali Khan

Editor - Online

Haseeb Uddin

Graphics Designer

Sh. M. Sadiq Ali

Dental Tribune Pakistan

3rd floor, Mahmood Centre, BC-11, Block-9
Clifton, Karachi, Pakistan.

Tel.: +92 21 35378440-2 | Fax: +92 21 35836940

www.dental-tribune.com.pk info@dental-tribune.com.pk

Dental Tribune Pakistan cannot assume responsibility for the validity of product claims or for typographical errors. The publisher also does not assume responsibility for product names or statements made by advertisers. Opinions expressed by authors are their own and may not reflect of **Dental Tribune Pakistan.**

International Imprint

Group Editor

Daniel Zimmermann

newsroom@dental-tribune.com

Tel.: +49 341 48 474 107

Clinical Editor

Magda Wojtkiewicz

Online Editors

Yvonne Bachmann

Claudia Duschek

Sabrina Raaff

Hans Motschmann

Copy Editors

Publisher/President/CEO

Torsten Oemus

Chief Financial Officer

Dan Wunderlich

Business Development Manager

Claudia Salwiczek

Events Manager

Lars Hoffmann

Media Sales Managers

Matthias Diessner

(Key Accounts)

Melissa Brown

(International)

Peter Witteczek

(Asia Pacific)

Maria Kaiser

(North America)

Weridiana Mageswki

(Latin America)

Hélène Carpentier

(Europe)

Marketing & Sales Services

Nadine Dehmel

Nicole Andrä

Accounting

Karen Hamatschek

Anja Maywald

Manuela Hunger

Executive Producer

Gernot Meyer

Dental Tribune International

Holbeinstr. 29, 04229 Leipzig, Germany

Tel.: +49 341 48 474 302 | Fax: +49 341 48 474 173

info@dental-tribune.com | www.dental-tribune.com

Regional Offices

Asia Pacific

Dental Tribune Asia Pacific Limited

Room A, 20/F, Harvard Commercial Building,

105-111 Thomson Road, Wanchai, Hong Kong

Tel.: +852 3113 6177 | Fax: +8523113 6199

The Americas

Tribune America, LLC

116 West 23rd Street, Ste. 500, New York, N.Y. 10011, USA

Tel.: +1 212 244 7181 | Fax: +1 212 244 7185

SENSODYNE®

COMPLETE PROTECTION POWERED BY NOVAMIN

Sensodyne® understands that dentine hypersensitivity patients have differing needs


Sensodyne® Complete Protection, powered by NovaMin®, offers all-round care with specially designed benefits to meet your patients' different needs and preferences. With twice-daily brushing, Sensodyne® Complete Protection:

- Is clinically proven to provide dentine hypersensitivity relief¹⁻³
- Contains fluoride to strengthen enamel
- Helps to maintain good gingival health⁴⁻⁶

Sensodyne® Complete Protection, powered by NovaMin® – an advanced approach to dentine hypersensitivity relief

- NovaMin®, a calcium and phosphate delivery technology, initiates a cascade of events on contact with saliva⁷⁻¹² which leads to formation of a hydroxyapatite-like restorative layer over exposed dentine and within dentine tubules.^{7,9-13}
- In vitro* studies have shown that the hydroxyapatite-like layer starts building from the first use^{7,9} and is up to 50% harder than dentine.^{9,14}
- The hydroxyapatite-like layer binds firmly to collagen within exposed dentine^{10,15} and has shown in *in vitro* studies to be resistant to daily physical and chemical oral challenges,^{9,14-17} such as toothbrush abrasion¹⁶ and acidic food and drink.¹⁴⁻¹⁷

In vitro studies show that a hydroxyapatite-like layer forms over exposed dentine and within the dentine tubules:^{7,9,10,12,13}



Hydroxyapatite-like layer over exposed dentine

Hydroxyapatite-like layer within the tubules at the surface

5 µm

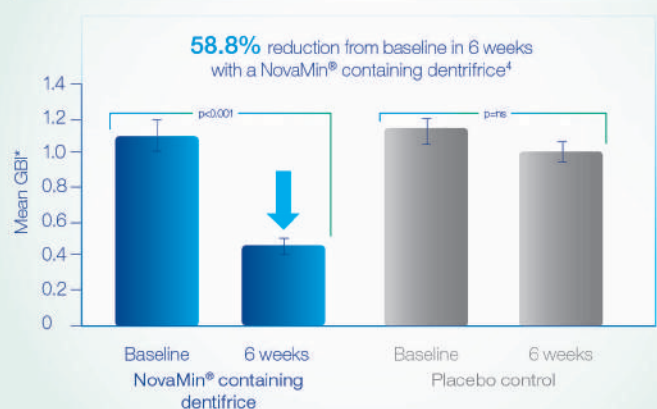
Adapted from Earl et al, 2011 (A).¹³ *In vitro* cross-section SEM image of hydroxyapatite-like layer formed by supersaturated NovaMin® solution in artificial saliva after 5 days (no brushing)¹³

Sensodyne® Complete Protection helps to maintain good gingival health⁴⁻⁶

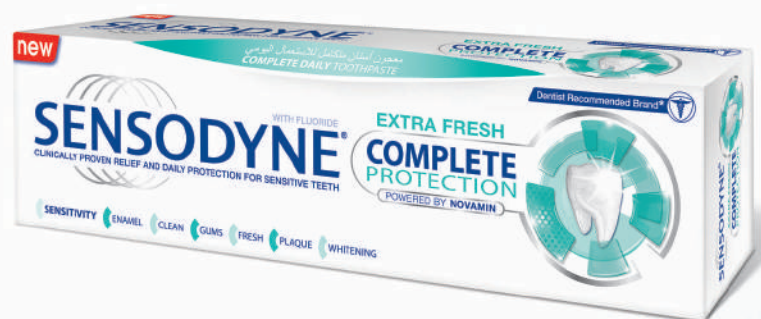Good brushing technique can be enhanced with the use of a specially designed dentifrice to help maintain good gingival health.^{18,19}

In clinical studies, NovaMin® containing dentifrices have shown up to 16.4% improvement in plaque control as well as significant reduction in gingival bleeding index, compared to control toothpastes.⁴⁻⁶

Significant reduction in gingival bleeding index (GBI) over 6 weeks with a NovaMin® containing dentifrice⁴



Adapted from Tai et al, 2006.⁴ Randomised, double-blind, controlled clinical study of 95 volunteers given NovaMin® containing dentifrice or placebo control (non-aqueous dentifrice containing no NovaMin®) for 6 weeks. All subjects received supragingival prophylaxis and polishing and were instructed in brushing technique.⁴ *GBI scale ranges from 0–3.



References:

1. Du MQ et al. Am J Dent 2008; 21(4): 210–214. 2. Pradeep AR et al. J Periodontol 2010; 81(8): 1167–1173. 3. Sallan S et al. J Clin Dent 2010; 21(3): 82–87. 4. Tai BJ et al. J Clin Periodontol 2006; 33: 86–91. 5. Devi MA et al. Int J Clin Dent Sci 2011; 2: 46–49. 6. GSK data on file (study Z3690864) 7. LaTorre G, Greenspan DC. J Clin Dent 2010; 21(3): 72–76. 8. Edgar WM. Br Dent J 1992; 172(8): 305–312. 9. Burwell A et al. J Clin Dent 2010; 21(3): 66–71. 10. Eflandt SE et al. J Mater Sci Mater Med 2002; 13(6): 557–565. 11. de Aza PN et al. J Mat Sci: Mat in Med 1996; 399–402. 12. Arcos D et al. A J Biomed Mater Res 2003; 6(3): 344–351. 13. Earl JS et al. J Clin Dent 2011; 22(3): 62–67. (A) 14. Parkinson CR et al. J Clin Dent 2011; 22(3): 74–81. 15. West NX et al. J Clin Dent 2011; 22(3): 82–89. 16. Earl JS et al. J Clin Dent 2011; 22(3): 68–73. (B) 17. Wang Z et al. J Dent 2010; 38(5): 400–410. 18. "Dentifrices" Encyclopedia of Chemical Technology 4th ed. vol 7, pp. 1023–1030, by Morton Puder Consumer Products Development Resources Inc. 19. Van der Weijden GA and Hioe KPK. J Clin Periodontol 2005; 32 (Supp 1.6): 214–228. Date of Preparation: September 2013. GCSAE/CHSENO/0231/12

GSK is committed to the effective collection and management of human safety information relating to our products and we encourage healthcare professionals to report adverse events to us on +92 (21) 111-475-725 or pk_pharmasafety@gsk.com

All-round care for dentine hypersensitivity patients¹⁻⁶

Advantages of 3-D planning for implants

by Drs Andrea Grandoch & Peter A. Ehrl, Germany

Implantology is predominantly a surgical and prosthetic subject area. Its aim is both functional and aesthetic restoration. Today, one can place an implant in the jawbone with a high probability of success if there is good bone support. There are, however, concerns with regard to bone defects, optimum aesthetic and functional positioning of the implant and the soft-tissue situation, possible requiring partial reconstruction. The ideal number of implants for large superstructures is still a matter of debate.

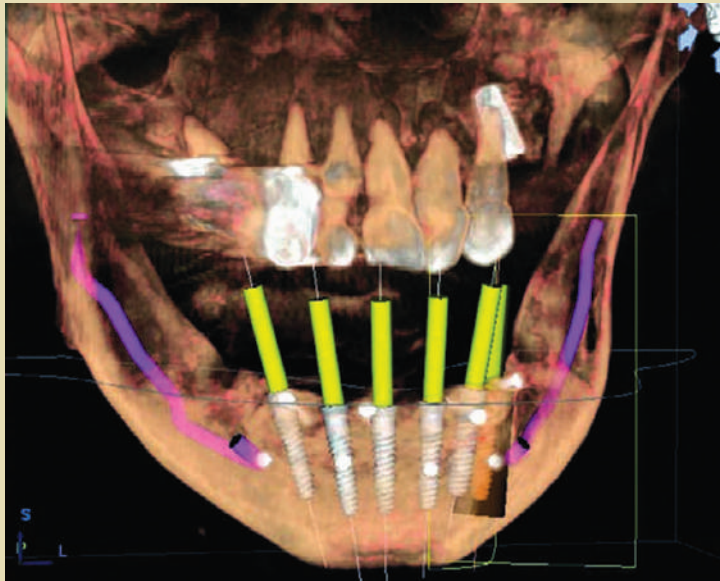
Functionality, durability and aesthetics are aims that should, in general, be achieved as simply as possible using favourable and conditionally reversible techniques with minimal damage, even in problematic cases. Restoring teeth today has become easier to achieve but whether the cost-benefit ratio is satisfactory must be established for each case. There is still no consensus on these aims and perhaps success can be defined only individually. Expectations regarding implantological solutions have increased owing to significant technological advances. One may distinguish between general success criteria valid for all implants and criteria for special indications. While some scientific societies recommend replacing lost teeth with implants as the optimal treatment, and bearing in mind that the goal is restoration of natural conditions, one has to ascertain whether this is valid for single-tooth and multiple-tooth replacement for each case. Reasons for suboptimal solutions are manifold, ranging from poor initial conditions associated with a higher treatment risk to socio-economic limitations.

One cannot write about implant treatment in general, as too many parameters play a role, particularly because each case differs from another. Moreover, there are no general recommendations with regard to methodology. This is hardly surprising, since various methods are used, of which many have limited application and quickly become out of date. There is no widely agreed upon gold standard.[1]

Methods

In 2000, CBCT was introduced to our clinic with hesitation initially and limited to more extensive problems and progressive diseases. It was used increasingly and has been used for almost all implant surgeries since 2008. Three-dimensional diagnostics undisputedly offer greater insight, thus increasing the quality of the treatment. Three-dimensional planning, however, always means considering the prosthetic planning and the anatomical substratum. This is done digitally or via conventional casts.

Even before the introduction of 3-D technologies, backward planning[2] demonstrated that viewing the desired treatment result is helpful in achieving the result. Here too, we initially applied backward planning to cases requiring extensive treatment at



first, until we learned that planning is useful for single-tooth replacement too. Each of these techniques—conventional casts and CBCT scans—can be helpful, contributing to a distinct improvement in the treatment results in the hands of the experienced implantologist. The next step would therefore be to connect these two techniques. After purely digitally controlled navigation was found to be inaccurate, surgical guide systems, based on planning software, became available.

Currently, we are making the step from plaster cast and wax-up to digital model and digital reconstruction. This interesting new approach has to prove its worth in the practice first. Therefore, we have to determine which of the many digital features are essential in treatment of the patient.

Main features of 3-D planning

Only by the evaluation of 3-D data does a preoperative decision on how the desired prosthetic result can be obtained become possible. With the final result in view and mind, a solid basis for deciding upon the necessity and type of augmentation and whether removable or fixed dentures are indicated in edentulous jaws is provided. There are often bone defects, whose extent must be evaluated. They are classified according to Fallschüssel and Atwood and the classification demonstrates that, as a rule, horizontal bone loss occurs first, while vertical bone is lost gradually.

Restoring horizontal bone is important for prosthetic restoration primarily for aesthetic reasons in the anterior area and primarily for functional reasons in the lateral areas concerning the position of the implant in the dental arch. These defects can be optimally corrected via surgical restoration of the original bone volume. For each case, measurements for positioning the implant (such as inclination—to be performed by the surgeon) and measurements for the prosthesis (to be done by the dental technician) must be taken. The latter, for example, buccal crown overhangs or mucosal facings, prevent hygienic design of the superstructure and quite often result in aesthetic deficiencies.

If restoration of vertical bone volume is necessary,

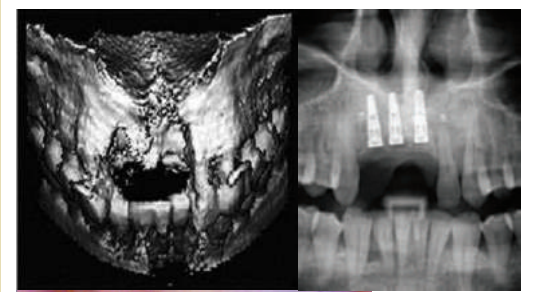


Fig. 1: Single-tooth replacement with 3-D planning pre- and post-augmentation: Massive defects in the buccal lamella, regions 11 and 21
Fig. 1b: Post-implantation
Fig. 1c: Patient with crowns

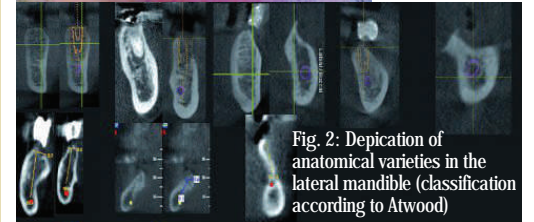
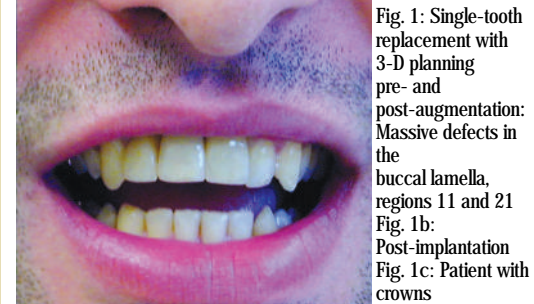

Fig. 2: Depiction of anatomical varieties in the lateral mandible (classification according to Atwood)

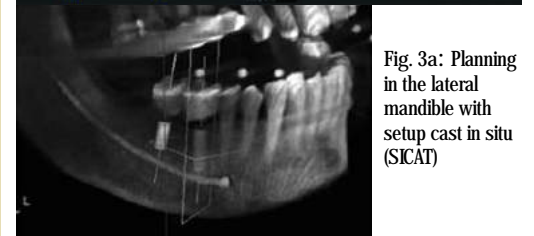


Fig. 3a: Planning in the lateral mandible with setup cast in situ (SICAT)

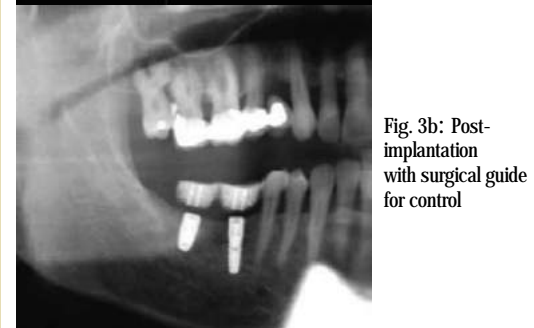


Fig. 3b: Post-implantation with surgical guide for control

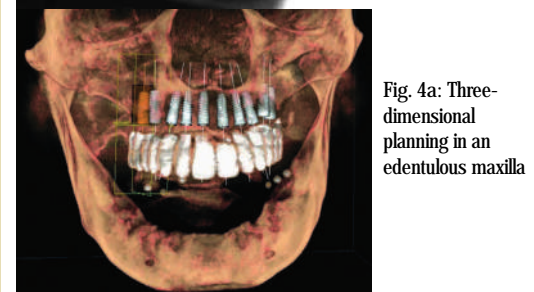


Fig. 4a: Three-dimensional planning in an edentulous maxilla

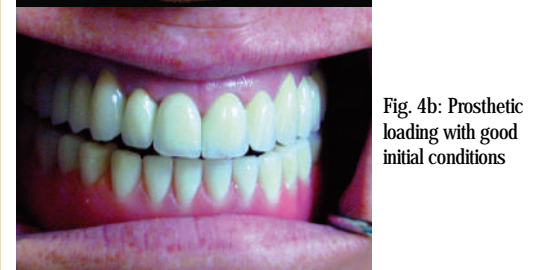

Fig. 4b: Prosthetic loading with good initial conditions

for instance with Fallschüssel Class 4 frontal or 2 lateral or Atwood Class 4 defects, a more costly two-step technique has to be followed in most cases. At this point, it should be noted that almost all the atrophy patterns mentioned only involve the jaw and do not concern the functional components of the dental arches. Arutinov et al.[3] postulate that this must be compensated for by angled implants. Kinsel et al.[4] conclude that only the length of the implant is significant for implant loss. This means that as great a bone volume as possible must be used. All of the above-mentioned planning decisions can only be made soundly if information about both the 3-D anatomy and the desired prosthetic solution is available.

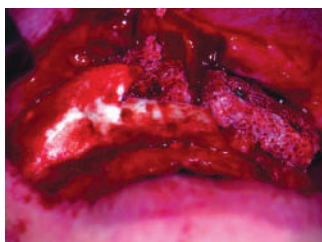


Fig. 5a: Two-step technique in a case of advanced atrophy of the alveolar process before fixed prostheses. Horizontal and vertical augmentation intra-operatively, fixed bone block (left) and covered with membrane cover.

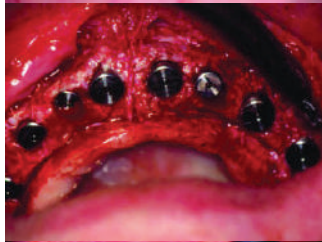

Fig. 5b: Healed post-augmentation

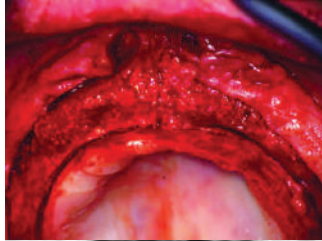


Fig. 5c: Post-implantation

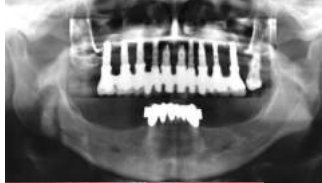

Fig. 5d: Radiograph after placement of the bridge

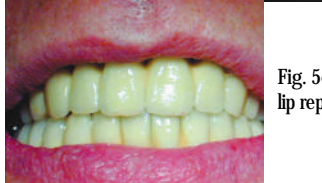

Fig. 5e: Prosthetic result, lip repose

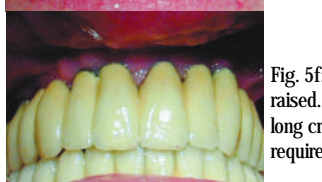

Fig. 5f: Prosthetic result, lip raised. Despite augmentation, long crowns were still required

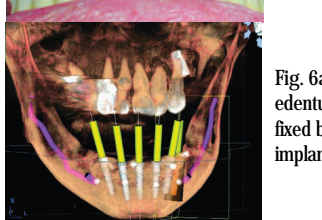


Fig. 6a: Loading of an edentulous mandible with a fixed bridge on inter-foraminal implants: Planning detail

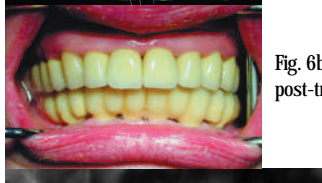

Fig. 6b: Four years post-treatment

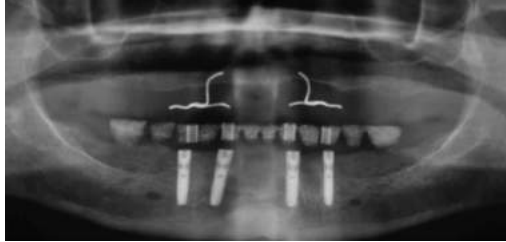


Fig. 7a: X-ray after implantation with mucosa-born drilling template in situ

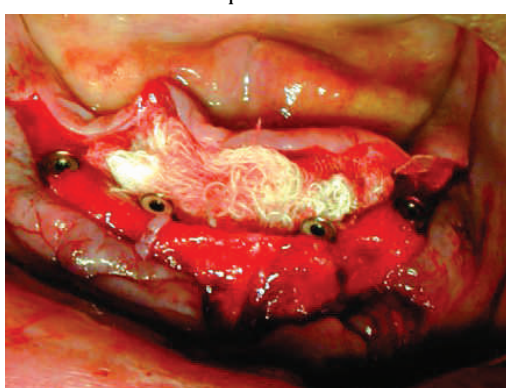


Fig. 7b: Surgical site with lingual position of the medial implants

of angled and short implants. Angled implants require a bone quality above 3, 3-D planning and guided implantation, among others. Planning based on an impression with fabrication of a planning cast is critical for the final outcome of implant placement and thus for the procedure. This will determine the required treatment steps and desired treatment outcome. Quite often, this step is not accorded the necessary importance in daily practice. Adequate planning should be done by the dentist and a special appointment with the patient should be made to obtain consent. With two-step procedures, repeating planning after augmentation and a second 3-D radiograph may become necessary.

Digital 3-D planning

Today's prosthetic planning possibilities offer alternatives to conventional casts. Two digital prosthetic planning tools will be discussed here, SimPlant (Materialise Dental) and SICAT/CEREC (Sirona). Both these tools are alternatives to the conventional approach described above via digital planning. With both methods, the surface of the neighbouring teeth and soft tissue is scanned and minor augmentation, longer prostheses are necessary for short implants, which are situated more lingually than the natural teeth. The use of short implants in the lateral jaw is subject to several restrictions, such as good bone quality, primarily connected crowns or caps, no extension bridges, no lateral excursion contacts and no para-functional habits. Angulation is limited to 20 degrees. Furthermore, angled implants are not recommended for a shortened row of teeth according to the guidelines of the European Association of Dental Implantologists.[5] If alignment is carried out with respect to antagonists in the natural dentition, positioning the new implant-borne crowns will not lead to any functional losses, unless the antagonists were not functionally situated in the dental arches originally.

Space towards the cheeks must be regained, even if patients with a long case history sometimes complain about spontaneous cheek biting and bolus retention. One must choose carefully between the more pleasant approach of using short and angled implants with long crowns and the more difficult approach of bone augmentation. Three-dimensional planning provides indispensable information in cases like these. With reference to typical defect patterns, Figure 2 demonstrates that restoring bone volume for very different defects can be problematic. A typical reconstruction using a surgical guide for pilot drillings in a shortened row of teeth with good initial conditions is depicted in Figures 3a and b.

Edentulous jaw

Three-dimensional planning is of vital importance for determining the treatment approach for implantation in edentulous jaws. For instance, one has to decide upon whether and which augmentative measures are required and whether a removable or fixed prosthesis is suitable. With regard to the last point, it must also be decided whether extensive single-tooth replacement is possible, whether small or large bridges must be used, and whether a greater intermaxillary distance must be filled prosthetically by longer crowns or by a mucosa substitute.

The number of implants for fixed dental prostheses include the All-on-4 concept (Nobel Biocare), the consensus conference recommendations of six implants in the mandible and eight in the maxilla, and tooth-by-tooth reconstruction up to the first molar. The multitude of planning information and treatment possibilities requires a great deal of planning, which is always justified because of its significant consequences.

Planning based on digital casts is not appropriate in these cases, since the support of the cheeks and lips by the prosthesis is important and this can only be determined with the help of and for each patient. Here, the advantages of prosthetic planning are particularly evident.

Edentulous jaws often require a special approach (see Figs. 4a & b for an example). Extensive augmentation is frequently necessary (Figs. 5a-f). The required length of the teeth, however, has to be clarified with the patient before treatment and depends on the amount of tooth displayed during lip repose (Fig. 5e). Quite frequently, implants are placed inter-foraminally in the mandible, often because extensive augmentation is still problematic in the lateral mandible. Figures 6a and b show a patient with six implants and an extension bridge.

Even in cases of seemingly simple implantation for removable dentures in an edentulous jaw, 3-D planning and a planning cast are needed to verify functional reconstruction and soft-tissue support. In addition, they can aid determination of the positions of the implants in consultation with the dental technician and planning for adequate space for the attachment box.

Discussion

Three-dimensional planning for implants holds the advantage of higher quality owing to (a) risk identification; (b) planning reliability; (c) production of near-natural structures; (d) targeted and fast work; (e) patient compliance; and (f) cost transparency. These advantages are largely due to the greater amount and quality of information gained. Three-dimensional diagnostics enable us to obtain reliable information about the condition of the alveolar process and important anatomical structures. With the additional planning cast, information about the restoration of function and aesthetics is obtained. Combining both information sources will result in optimal treatment planning. In addition, an experienced surgeon can address surprises if the patient is flexible. Intra-operative decisions may also need to be made if unexpected situations arise. Knowledge of 3-D data permits planning, which entails devising a well-considered procedure and obtaining the necessary tools and substitute material, for example suitable implants and bone substitutes. Owing to the traceability of diagnosis and treatment, as well as the resulting safety, patients will regard the procedure particularly positively.

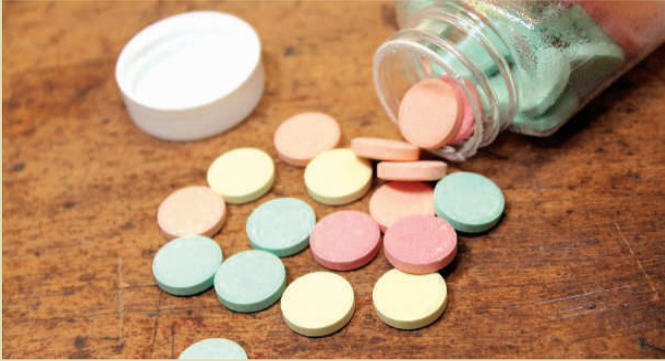A disadvantage is the higher initial outlay, but this is balanced by increasing use owing to a targeted and quicker workflow and thus less reworking. Implantation always requires a 3-D radiograph. These new techniques have greater logistical requirements than conventional dental procedures do and require extensive involvement of the teams involved in order to achieve treatment success.

It should be borne in mind that every surgery is accompanied by a certain risk in spite of the safety precautions taken. In addition, too much confidence in methodologies may lead to carelessness. Errors may even arise with 3-D planning, which may hold negative consequences for treatment. Therefore, it is important to be familiar with each step and error source and thus expert training is crucial. In addition, maintaining a critical attitude throughout treatment is necessary to avoid errors. The advantages of 3-D planning are so significant that it has become indispensable.

Editorial note: This article was published in cone beam international magazine of cone beam dentistry 03/2014. A list of references is available from the publisher.

The guidelines of the European Association of Dental Implantologists[5] offer a critical discussion

Head and neck cancer: Antacids could increase survival rate



DT International Report

ANN ARBOR, Mich., USA: Antacids are usually prescribed to manage acid reflux, a common side effect of chemotherapy or radiation treatment in head and neck cancer patients. However, this medication might also aid in halting cancer progression, according to new research. A study conducted at the University of Michigan has found that patients who took antacids had better overall survival compared with patients who did not receive such medicine.

The study included 596 patients with previously untreated head and neck squamous cell carcinoma, of whom two-thirds took antacid medication while the remainder served as controls.


"Patients taking antacid medications had significantly better overall survival," the researchers said. Participants who took proton pump inhibitors had a 45 percent decreased risk of death compared with the controls, and patients who took histamine receptor-2 blockers had a 33 percent decreased risk of death.

Although these findings indicate that routine use of antacid medications may have a significant therapeutic benefit in patients with head and neck cancer, the mechanisms underlying the effect are not well understood yet. Therefore, additional studies are planned to investigate whether antacids can be used to halt cancer progression and to reduce the risk of developing head and neck cancer.

Proton pump inhibitors, such as Prilosec, Nexium and Prevacid, and histamine-2 blockers, such as Tagamet, Zantac or Pepcid, are regarded as relatively safe and typically have few adverse side effects.

The study, titled "Proton Pump Inhibitors and Histamine 2 Blockers Are Associated with Improved Overall Survival in Patients with Head and Neck Squamous Carcinoma," was published in the December issue of the Cancer Prevention Research journal.

Dentists develop saliva test for lung cancer



DT International Report

LOS ANGELES, USA: Dental researchers have developed a novel technology that can detect mutations characteristic of lung cancer in saliva. In a series of tests, the researchers were able to demonstrate that detecting such mutations in saliva using the new method was as effective as testing with plasma. Thus, they believe it could be a noninvasive, cost-effective and rapid alternative to conventional test approaches.

The new technology, called electric field-induced release and

Society's poorest have eight fewer teeth

DT International Report

NEWCASTLE, UK: The poorest people in society have eight fewer teeth by their seventies than the richest, one of the largest studies of its type ever undertaken has found. The research, a collaboration between Newcastle University, the Newcastle upon Tyne Hospitals NHS Foundation Trust, University College London (UCL) and the National Centre for Social Research, showed that oral health is substantially worse among the poorest 20 per cent of society compared with the most wealthy. For those over 65 years old, the least well off averaged eight fewer teeth than the richest—a quarter of a full set of teeth.



More than 6,000 people aged 21 and over from all income groups and regions of the UK, excluding Scotland, were involved in the study, which was funded by the Economic and Social Research Council and used data from the recent UK Adult Dental Health Survey. Those with lower income, higher deprivation and lower educational attainment, and in a lower occupational class generally had the worst clinical outcomes, including increased tooth decay, periodontal disease, and diastemas, as well as fewer teeth overall.

Despite these social differences, oral health is improving and the oral health of young British adults overall is much better than it used to be. However, previously published research by the same team showed that, while the youth had much healthier mouths than did their predecessors, when asked how good or bad their own oral health was and how it affected them, the social divisions between rich and poor were evident, and even more pronounced than in older people. The poorest young people were very aware of their poor health and much more likely than the wealthiest to rate their oral health as poor or say that it affected their day-to-day life.

Mix of reasons for poor oral health


Prof. Jimmy Steele, CBE, Head of the School of Dental Sciences at Newcastle University and lead author, said: "It's probably not a big surprise that poorer people have worse dental health than the richest, but the surprise is just how big the differences can be and how it affects people. Eight teeth less on average is a huge amount and will have had a big impact for these people. From our data it is hard to say which specific factors are driving each of the differences we are seeing here, but there is probably a real mix of reasons and it

Continued to page 11

Saliva test in dental setting could help diagnose deadly diseases

DT International Report

LOS ANGELES, USA: Salivary fluid has become an emerging medium for the detection of oral and systemic diseases, as well as for health surveillance in recent years. Now, a study conducted at the University of California, Los Angeles



(UCLA), has shown that a simple saliva test conducted in the dental practice could be capable of diagnosing serious illnesses such as diabetes and cancer at an early stage.

The UCLA School of Dentistry has been researching biomarkers in saliva for over a decade. In the present study, the researchers analyzed 165 million genetic sequences and discovered that saliva contains various RNAs that are biomarkers for diseases and can thus be used to detect and monitor diseases.

According to the researchers, the study is the most comprehensive analysis ever conducted on RNA molecules in saliva. It found that saliva contains many of the same disease-revealing molecules that are contained in blood. Overall, they were able to identify more than 400 circular RNAs in human saliva, including 327 forms that were previously unknown. By comparing microRNA levels in saliva to those in blood and other body fluids, they also found that these levels were very similar, indicating that a saliva sample could serve as a good measure of microRNA in the body.

Dr. David Wong, a senior author of the study and associate dean of research at the school, suggested that dentists might be able to take saliva samples to analyze for a variety of diseases, including Type 2 diabetes and gastric cancer, in the future. The findings could also lead to a new category of self-diagnostic devices, he said.


The study will be published in the January 2015 special print issue of the *Clinical Chemistry* journal, titled *Molecular Diagnostics: A Revolution in Progress*.



Bio-Emulation™



Tribune CME



Bio-Emulation™ Colloquium 360°

4-5 July, 2015, Berlin, Germany

Mentors



Ed McLaren



Michel Magne



Pascal Magne

Emulators



Akinobu Ogata (guest)



Andrea Fabianelli



Antonio Saiz-Pardo Pinos



August Bruguera



David Gerdolle



Fernando Rey



Gianfranco Politano



Jason Smithson



Javier Tapia



Jungo Endo



Leandro Pereira



Marco Gresnigt



Oliver Brix



Panos Bazos



Sascha Hein



Stephane Browet



Thomas Singh

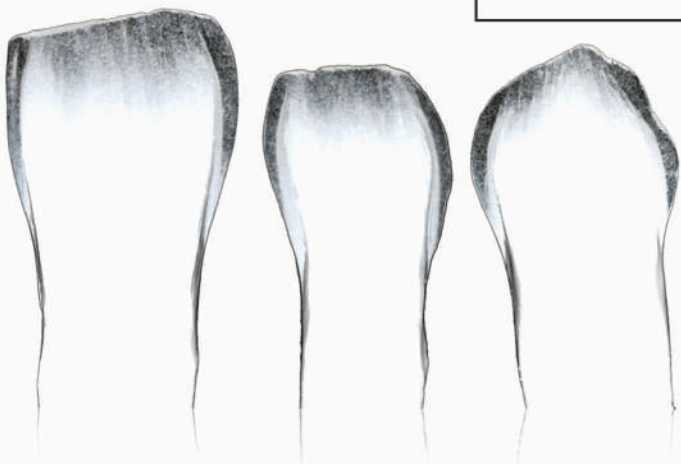

Walter Gebhard (guest)

Details & Online Registration

www.BioEmulationCampus.com

Registration fee: 599 EUR



ADA CERP®
Continuing Education Recognition Program



Tribune Group is an ADA CERP Recognized Provider. ADA CERP is a service of the American Dental Association to assist dental professionals in identifying quality providers of continuing dental education. ADA CERP does not approve or endorse individual courses or instructors, nor does it imply acceptance of credit hours by boards of dentistry.

Tribune Group GmbH is designated as an Approved PACE Program Provider by the Academy of General Dentistry. The formal continuing dental education programs of this program provider are accepted by AGD for Fellowship, Mastership, and membership maintenance credit. Approval does not imply acceptance by a state or provincial board of dentistry or AGD endorsement.

Main Sponsor





CROIXTURE

PROFESSIONAL MEDICAL COUTURE




THE NEW 2014-2015 COLLECTION

EXPERIENCE OUR ENTIRE COLLECTION ON WWW.CROIXTURE.COM

worldoralhealthday.org

#WOHD15



20th March 2015
World Oral Health Day
Smile for life!

Organized by:



Media partner:



In partnership with:

