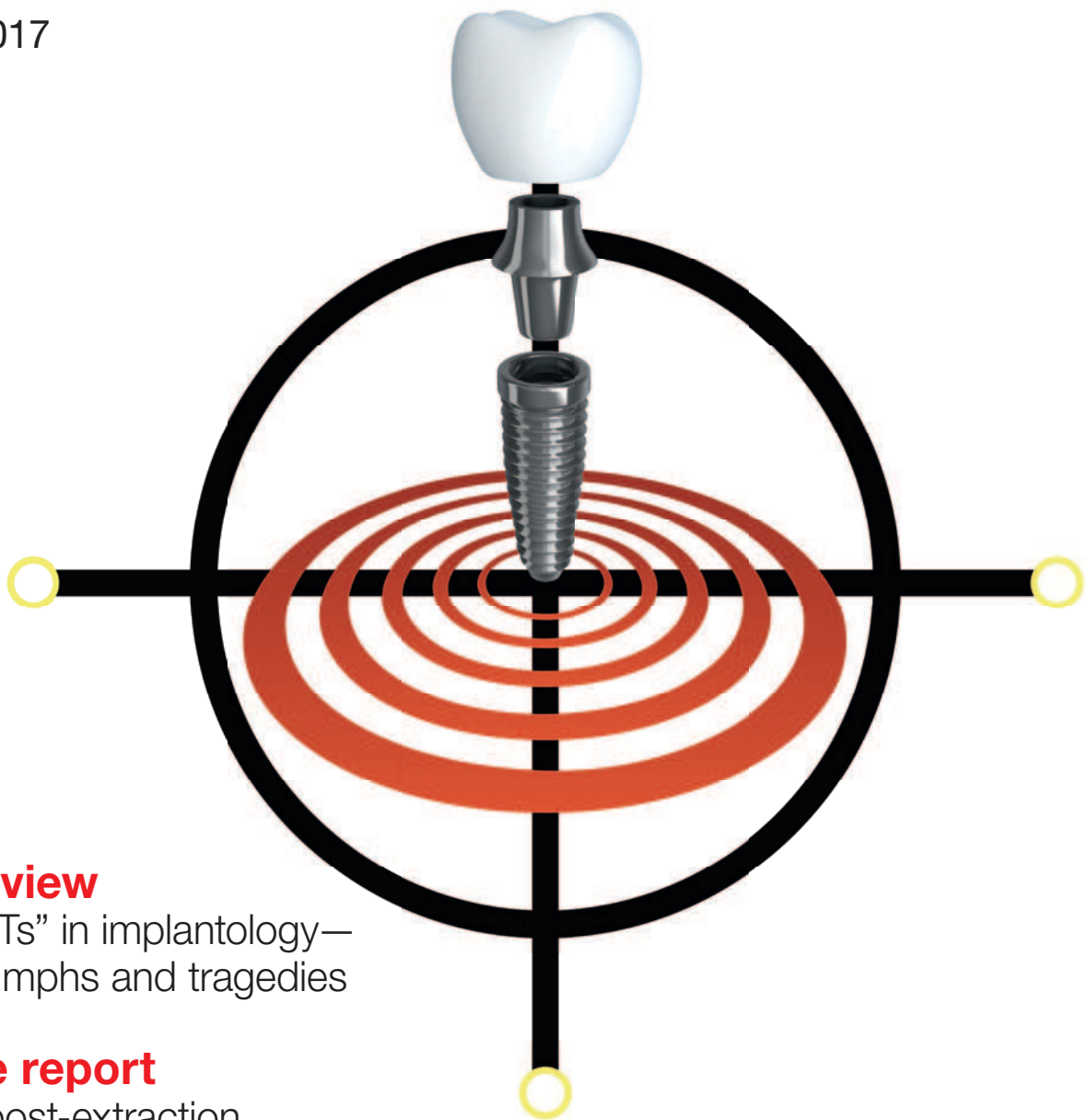


# implants

international magazine of oral implantology

1 2017



## overview

The “Ts” in implantology—  
of triumphs and tragedies

## case report

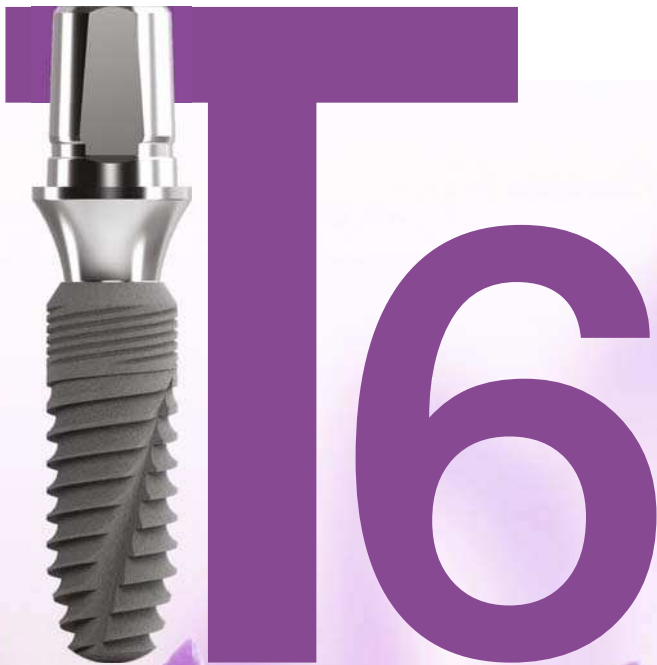The post-extraction  
immediate implant

## industry

Dynamic navigation for  
precise implant placement



much **more**  
implant



*Smart Designs  
Brave Smiles...*

# Full speed ahead— Implantology in 2017



Dr Rolf Vollmer

Dear colleagues,

2017 seems to have plenty to offer with regard to implantology: The DGZI has already started invitations for its scientific awards presented at the 47<sup>th</sup> International Annual DGZI Congress on 29 and 30 September in Berlin, Germany. This includes the DGZI Implant Dentistry Award 2017 (5,000 EUR) as well as the DGZI Thesis Award 2017 (2,000 EUR). The final deadline for both of the two awards is 31 May 2017.

And of course, the 37<sup>th</sup> International Dental Show in Cologne, Germany, already is promising to become another record-breaking dental trade show, once more featuring innovations in implantology as the driving force behind dentistry. Numerous new partnerships will enhance integrative workflow solutions, both digital and analogous. At each new IDS, we observe new market participants contributing their entrepreneurial spirit and determination to the greater good of a progressing health industry.

In this regard, I would especially like to point out the latest developments in zirconium dioxide-based implant systems. In this branch, we can find several companies offering their new and innovative systems to the still growing niche sector of ceramic implant technology. However, conventional titanium-based implant systems and their progresses are presented at or will have their debut at the IDS. This gives both specialists in implantology and oral surgery the demanding task to wisely choose among the many innovations presented at this year's International Dental Show.

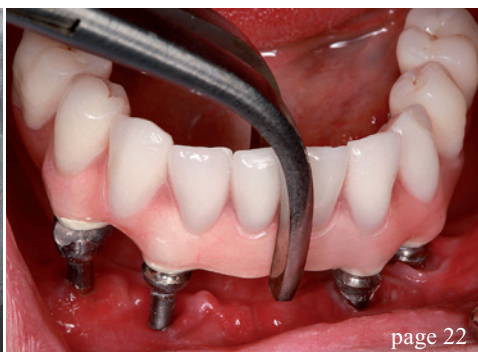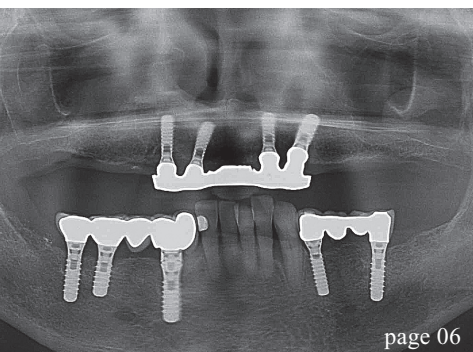
Which leaves me only to wish you a pleasant and informative reading of this latest issue of **implants international magazine of oral implantology**, hoping that it will give you helpful input for your decision-making process.

For this, you can find us at the IDS booth of OT medical (hall 11.2., L060), our long-term industrial partner and main sponsor of our annual congresses. You can also learn more about our international annual congresses and other international educational events and activities. Please contact the DGZI headquarters if you wish to make appointments in advance.

With warm collegial regards,

Dr Rolf Vollmer

First Vice President and Treasurer of the German Association of Dental Implantology



**editorial**

- 03 **Full speed ahead—Implantology in 2017**  
Dr Rolf Vollmer

**overview**

- 06 The “Ts” in **implantology**—  
of **triumphs** and **tragedies**  
Dr Georg Bach

**case report**

- 16 The **post-extraction** immediate implant  
Prof. Dr Mauro Labanca, Dr Ernesto Amosso &  
Prof. Dr Luigi F. Rodella

**industry**

- 22 **TRINIA™**—**Metal-free** restorations  
Prof. Dr Rolf Ewers, Paolo Perpetuini,  
Dr Vincent J. Morgan, Prof. Dr Mauro Marincola,  
Richard Wu & PD Dr Rudolf Seemann
- 28 **Dynamic** navigation for **precise** implantation  
in cases of **critical** anatomy  
Dr David Burgess

- 32 **Osteo-mucous restoration** and **implant-**  
**supported overdenture**  
Dr Ugo Torquati Gritti, Dr Daniele Vrespa,  
MDT Buongiovanni Armando & MDT Giancarlo Riva

**interview**

- 36 “The RFA **technique** must be **accurate**  
and **reliable**”

**events**

- 42 **Japan Annual Meeting 2016**  
of **ISOI** and **DGZI** in **Tokyo**  
Dr Rolf Vollmer

**news**

- 38 **manufacturer news**
- 46 **news**

**about the publisher**

- 50 **imprint**



Cover image courtesy of ClaroNav Inc.  
[www.claronav.com](http://www.claronav.com)



a perfect fit™

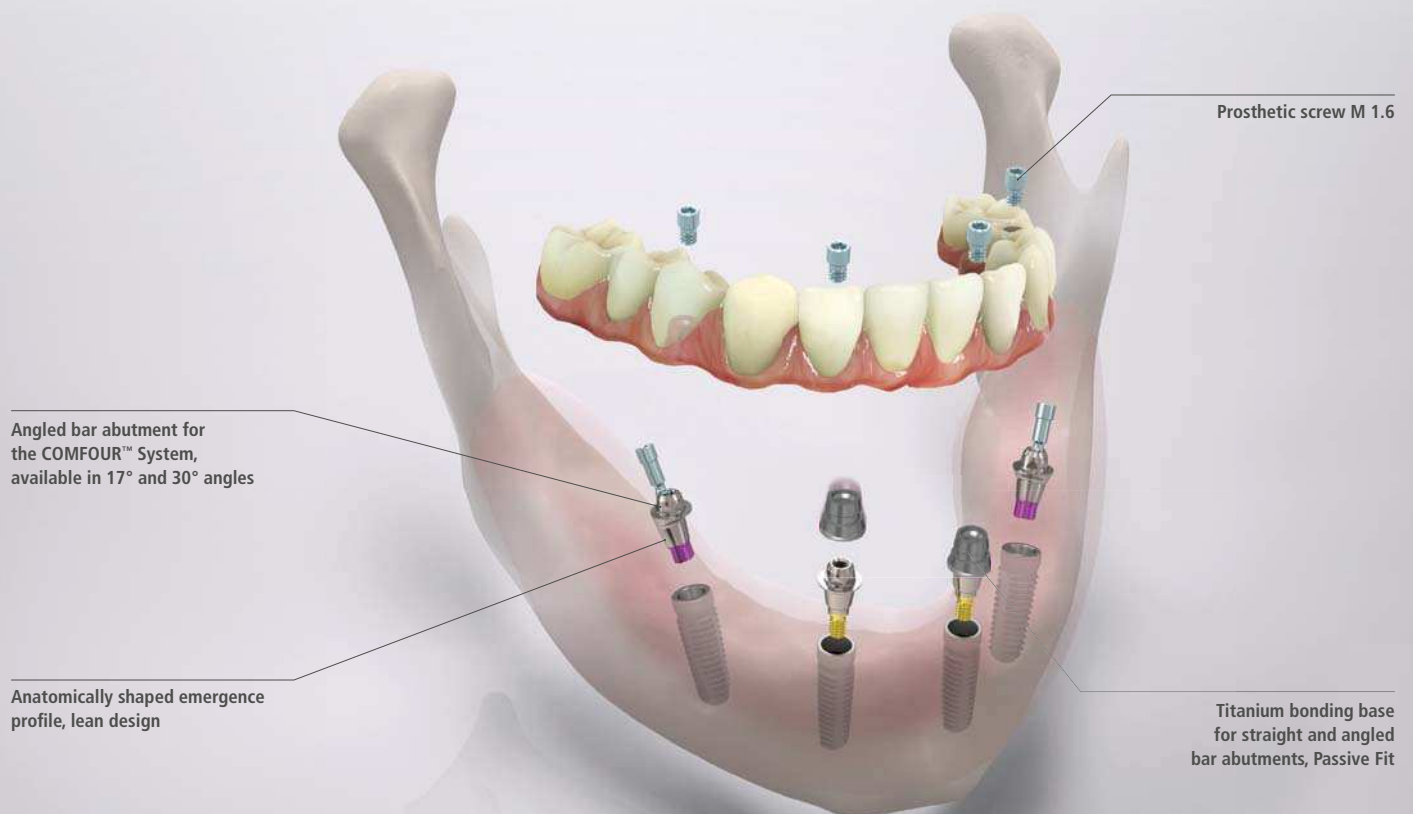camlog

## THE NEW COMFORT CLASS.

The COMFOUR™ Abutment System for occlusal screw-retained restorations is an ideal addition to the CAMLOG® and the CONELOG® Implant System. With the COMFOUR™ System, you can offer your edentulous patients the option of an immediate, comfortable and permanent denture on four or six implants – and thus a considerable gain in quality of life. [www.camlog.com](http://www.camlog.com)

CAMLOG®  
SYSTEM

CONELOG®  
SYSTEM



Aligning tool



Scanning cap



Titanium cap



Flexible handle

COMFOUR™ offers you a range of options to overcome the challenges you face in your implant practice, making them easier while saving time.

# The “Ts” in implantology—of triumphs and tragedies

**Author:** Dr Georg Bach, Germany

## Introduction

Implantology has become a commonplace in dentistry. Indeed, insertion techniques have progressed more and more in the past two decades, while the dental industry has provided users with improved implant surfaces and instruments. Hardly any other dental discipline has experienced more innovation and investments within such a short time span. These developments have been rewarded with a comprehensive product range and highly increased numbers of inserted implants that seemed out of reach only one and a half decades ago. However—despite all of this euphoria—implantology does not exclusively entail positive facets. Therefore, this article is designed

to report on the “Ts” in implantology, on triumphs and tragedies.

## Triumphs

Three case examples, differing in their respective initial situation and indications, are presented: 1) Implant-based denture of a maxillary anterior tooth; 2) complete restoration of the edentulous maxilla and a mandibular with residual frontal dentition via implant-based fixed dentures; 3) complete restoration of the edentulous maxilla with removable prostheses and a partially edentulous mandibular with fixed dentures. All three patients were loaded with tissue-level implants (Straumann) and now feature a positive long-term prognosis.

## Data Case 1

Implant regio 11  
Insertion: April 1999  
Prosthetic restoration: Juli 1999  
X-ray controls: post-operatively, 2001, 2004, 2007, 2010, 2013 and 2016  
Recall: bianullay  
Special characteristics: none

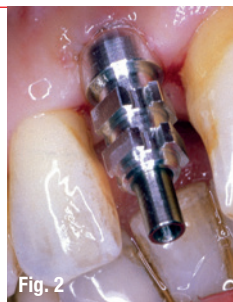

Fig. 2

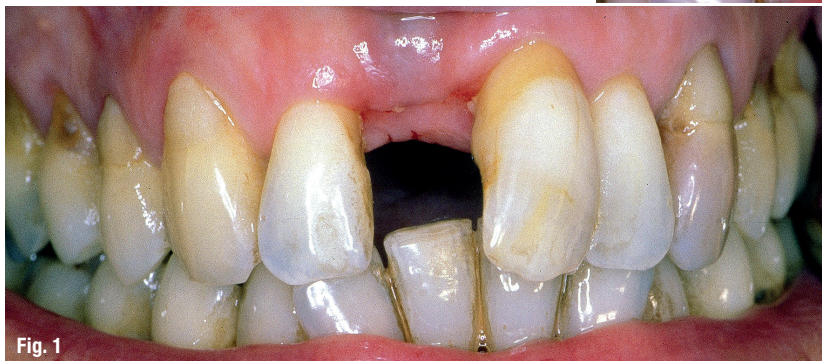

Fig. 1

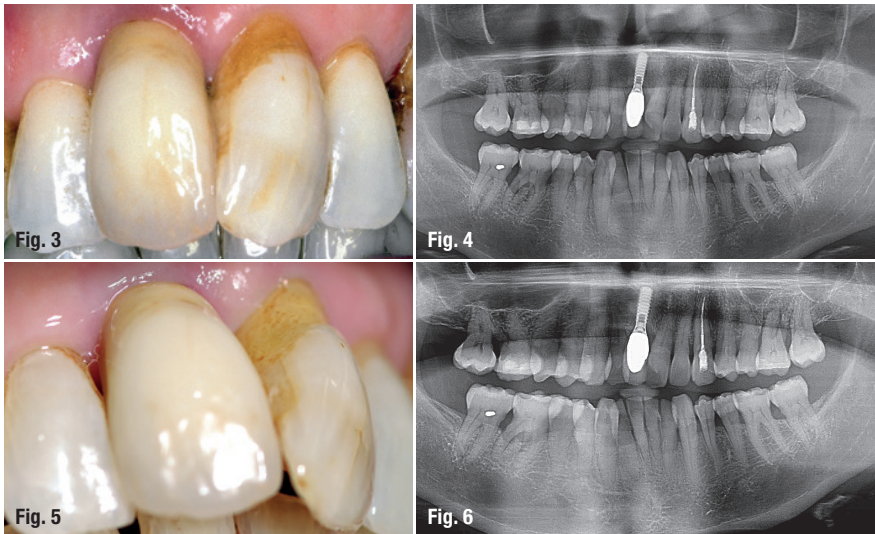**Fig. 1:** Initial situation. – **Fig. 2:** Impression taking.

## Case 1

A female patient and teacher, 56 years old at the time of implant insertion, was facing a possible loss of tooth 11 due to a reduction in supporting tissue. Before, a progressed periodontopathy with a reduction in supporting tissue had been restored and the patient was already in the recall phase of this process. Tooth 11 thus was the last legacy of this past periodontal disease.

After tooth extraction, an implant was inserted and loaded with a crown after three months. The dental technician was able to integrate the crown harmoniously in the patient's dentition which was markedly influenced by recession and reduction in supporting tissue. The patient diligently observed recall dates every six months, which have been combined with a professional hygiene session since 2005.

X-ray controls and clinical results did not indicate any pathological findings at the implant, only show-



**Fig. 3:** After implant integration. – **Fig. 4:** OPG 1999. – **Fig. 5:** Check-up 2016. – **Fig. 6:** OPG 2016.

ing that the bifurcation at 46 and 36 had increased minimally since the beginning of the treatment (Figs. 1–6).

In conclusion, this case proved to be ideal – long-term stability and a both motivated and cooperative patient.

#### Case 2

Shortly before his 60<sup>th</sup> birthday, a university professor wanted to end his state of suffering from an edentulous maxilla and a partly edentulous mandible. Most of all, he wanted to exchange his total prosthesis in the maxilla and partial prosthesis in the mandible for fixed dentures.

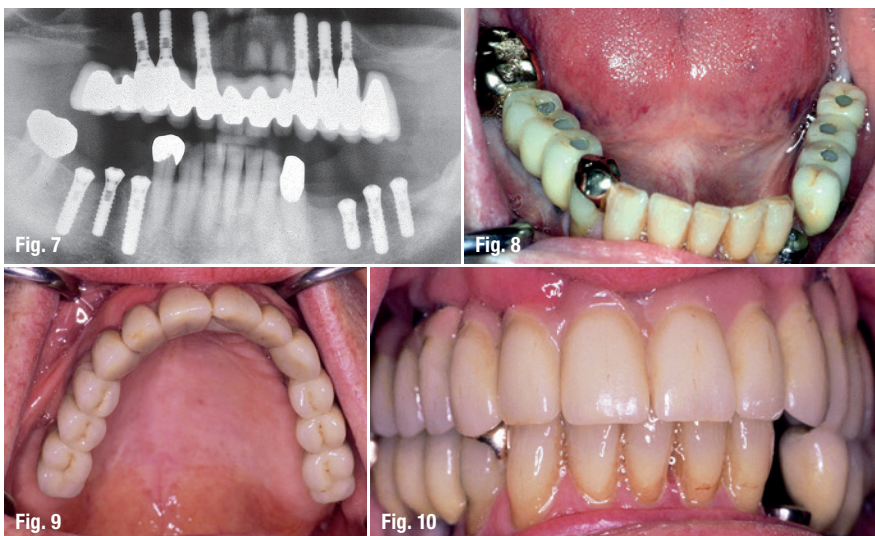Thirteen implants were inserted in two sessions and loaded with a continuous

bridge 16 to 26 in the maxilla and exclusively implant-based crowns and an extension bridge in the left mandible.

There were no regular control sessions, as the patient did not attend these in 2003, 2005 und 2008. In 2009, we achieved that he attended one control date and one professional hygiene session at least once every year.

X-ray controls and intraoral examinations did not indicate any decrease in the constitution of the residual dentition or implants (Figs. 7–14).

In conclusion, this case exhibits long-term stability of fixed, implant-based dentures and only partial compliance of the patient.



**Fig. 7:** OPG after Implantation 1996. – **Fig. 8:** Mandible after implant integration 1996. – **Fig. 9:** Maxilla after implant integration 1996. – **Fig. 10:** Frontal view 1996.



## Shortest Implants – Longest History.

## Think Short!

For more than 30 years Bicon® short implants are unchanged in clinical use.

According to the 11<sup>th</sup> European Consensus Conference (EuCC) 2016 in Cologne, provided the specific treatment parameters are observed, the use of short, angulated or diameter-reduced implants in sites with reduced bone volume can be a reliable treatment option, given the risks associated with the use of standard-dimension implants in combination with augmentation procedures.

For more Information:

**Bicon Europe Ltd.**

Hauptstr. 1

55491 Buechenbeuren

Germany

Phone +49 (0)6543 818200

germany@bicon.com

[www.bicon.de.com](http://www.bicon.de.com)



**bicon**  
DENTAL IMPLANTS



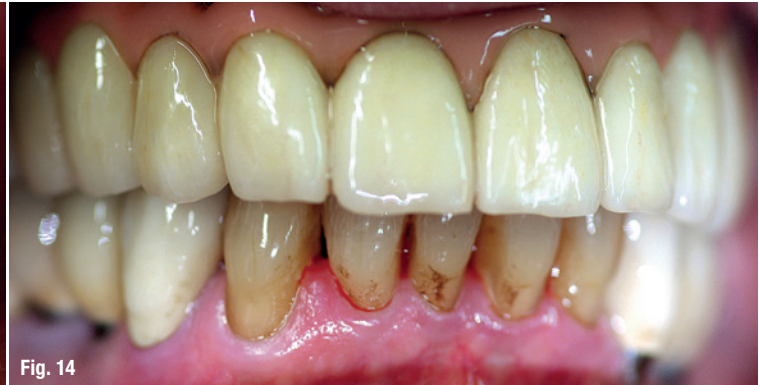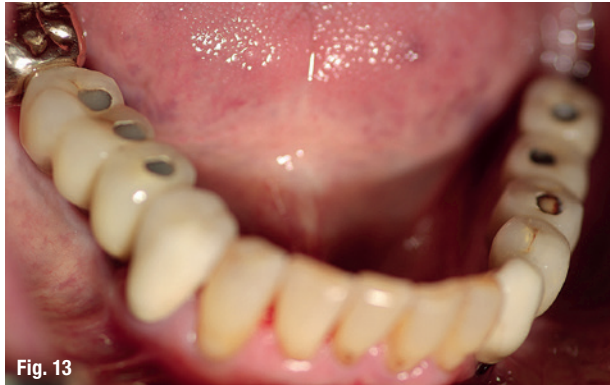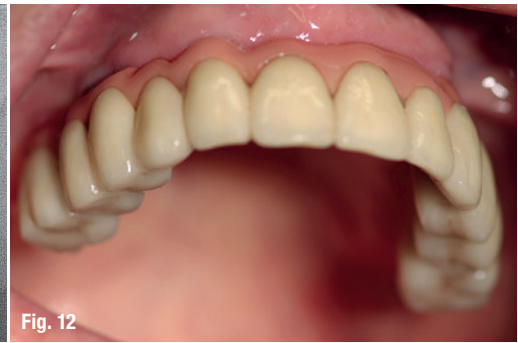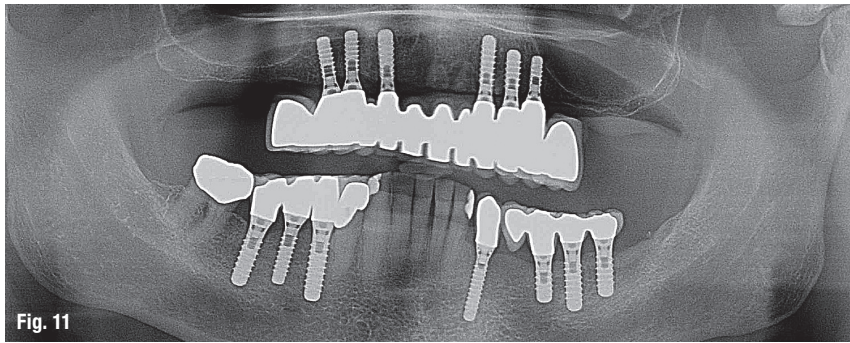


Fig. 11: OPG 2016. – Fig. 12: Maxillary situation 2016. – Fig. 13: Mandibular situation 2016. – Fig. 14: Frontal view 2016.

### Case 3

A then 50-year-old female patient had suffered from an edentulous maxilla since she was 46 years old. Handling her total prosthesis in everyday life was difficult for her, especially as it covered her covered, which made singing difficult for her. In addition, she also suffered from an edentulous mandible.

Due to a reduced bone volume in the posterior region of the maxilla, a manifest atrophy, the patient chose removable dentures for the maxilla and fixed, implant-based dentures in the posterior region of the mandible. The maxilla was restored in the beginning of 1996, while the mandible was treated in the autumn of the same year. Patient acceptance for the newly integrated prosthesis was high and her compliance has proved to be exemplary. In the past two decades, she rigorously attended each biannual control and dental hygiene

date. She still wears the same prostheses, except for two artificial teeth which had to be replaced after a fall (Figs. 15–21).

In conclusion, extensive augmentations were avoided and the patient was granted chewing comfort similar to that of fixed dentures because of a milled bar in the maxilla and implantation in the extended maxillary anterior teeth. Implants were inserted as the bone volume in the posterior mandible was favourable, making fixed, implant-based dentures in the posterior region possible. A highly motivated, compliant and very reliable patient was a further beneficial factor for the long-term success of this case of implant treatment.

### Tragedies

Implant restorations can fail. This failure may occur early or later after loading of the implants and

### Data Case 2

Maxilla (n=6): October 1995  
 Mandible (n=7): February 1997  
 Prosthetic restoration: March 1996 (maxilla) and June 1997 (mandible)  
 X-ray controls: postoperatively, 1999, 2001, 2004, 2007, 2012, 2016  
 Recall: biannually until 2012, no controls in 2003, 2005 and 2008, since 2009 once every year  
 Special characteristics: none

### Data Case 3

Maxilla (n=4): January 1996  
 Mandible (n=5): November 1996  
 Prosthetic restoration: April 1996 (maxilla) and September 1996 (mandible)  
 X-ray controls: post-operatively, 1998, 2001, 2004, 2007, 2010, 2013, 2016  
 Recall: biannually  
 Special characteristics: none



**IDS<sup>®</sup>**  
**2017**

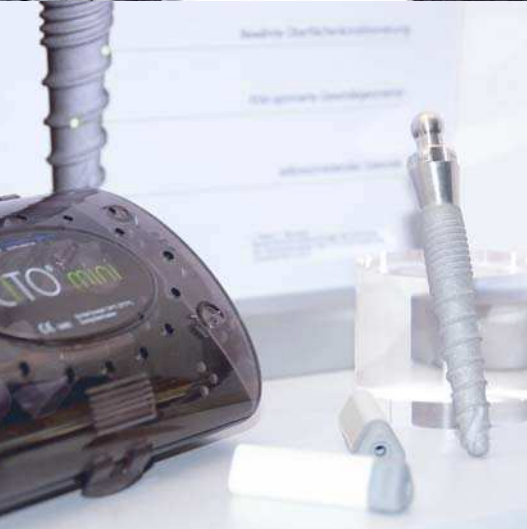**21. - 25.3.2017**  
**HALL 10.1 STAND E10/F11**



*tiologic<sup>®</sup>*



## IMPLANTS FROM DENTAURUM



CITO mini<sup>®</sup>



DENTAURUM  
QUALITY  
WORLDWIDE  
UNIQUE



Dentaaurum was founded over 130 years ago and has been developing and manufacturing dental implants in Germany for more than 20 years. The number of users around the world is growing continuously and users are happy to see a steady flow of innovations, improvements and extended indications in the product portfolio.

And they are impressed by our training center CDC and the large number of training courses there are at all levels.

Come to the Dentaaurum Group stand and find out about the latest product developments and courses on offer for implantologists and for those in the making.

**The Dentaaurum Implants team is looking forward to meeting you.**

 **DENTAURUM  
IMPLANTS**

Turnstr. 31 | 75228 Ispringen | Germany | Telephone +49 72 31/803-0 | Fax +49 72 31/803-295  
[www.dentaaurum-implants.com](http://www.dentaaurum-implants.com) | [info@dentaaurum-implants.com](mailto:info@dentaaurum-implants.com)