

# laser

international magazine of laser dentistry

3 2011



| **overview**

LANAP — Laser-Assisted New Attachment Procedure

| **research**

Swap Drills for Light Energy

| **meetings**

3<sup>rd</sup> European Congress of the WFLD in Rome



After endodontic laser treatment there is no smear layer around the opening of the lateral canal.

The universe at your fingertips.



# LightWalker®

Introducing the highest technology dental laser system

**Supreme clinical results in:**

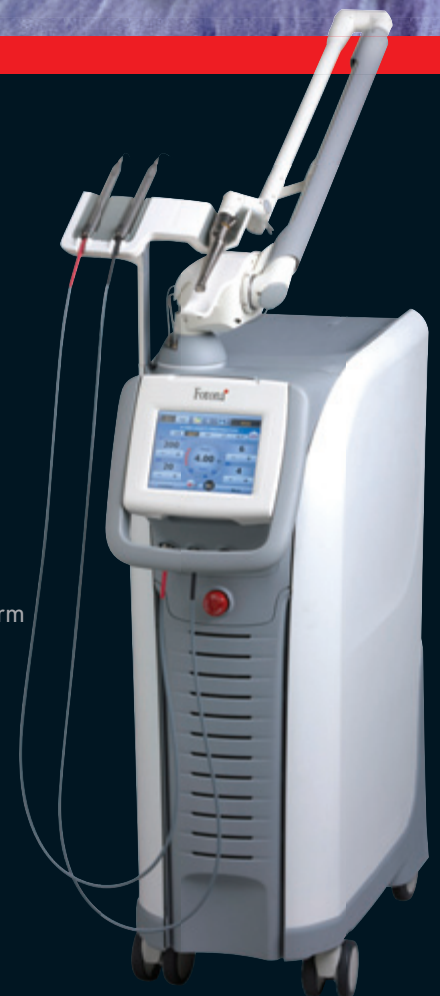- TwinLight™ Perio Treatments (TPT)
- TwinLight™ Endo Treatments (TET)
- No-sutures soft tissue surgery
- Gentle TouchWhite™ bleaching
- Patient-friendly conservative dentistry

**Unmatched simplicity of use:**

- Pre-sets for over 40 applications
- Intuitive user navigation
- Balanced and weightless OPTOflex arm
- Nd:YAG handpiece detection system
- Er:YAG scanner ready

Journey into a new dental experience with speed, precision and great results.  
Visit [www.lightwalkerlaser.com](http://www.lightwalkerlaser.com) today!

**Fotona**  
choose perfection



# Happy Birthday DGL!



Prof Dr Norbert Gutknecht  
WFLD President  
Editor-in-Chief

Twenty years ago, the DGL (German Society for Laser Dentistry) was founded in Stuttgart, Germany. The DGL was the third laser society to be founded following the foundation of the ISLD (International Society for Lasers in Dentistry) in 1988 in Japan and the ALD (Academy for Laser Dentistry) in 1990 in the US.

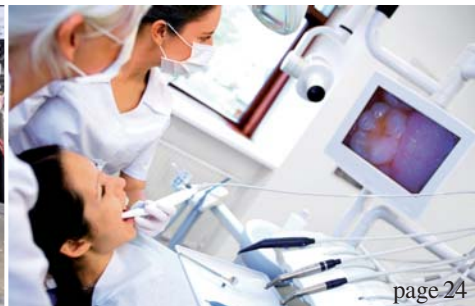
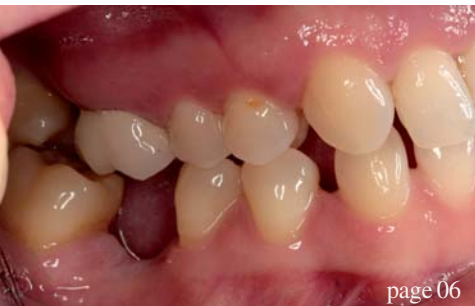In addition to the formation of international and regional societies, the establishment of national societies is one of the most important promotion activities in the field of laser dentistry in order to explain and promote the use of lasers in the daily dental office. Furthermore, national laser societies can establish positive relationships with national dental associations in order to dispel long-existing prejudices resulting from a lack of information.

The integration of the DGL into the German Dental Association (DGZMK) might prove to encourage all the other laser societies worldwide to continue developing a network with the dental associations and universities in their respective regions.

A handwritten signature in black ink, appearing to read 'Norbert Gutknecht', written in a cursive style.

Prof Norbert Gutknecht  
Editor-in-Chief





| editorial

03 Happy Birthday **DGL!**  
| Prof Dr Norbert Gutknecht

| overview

06 **LANAP**—Laser-Assisted New Attachment Procedure  
| Dr David Kimmel

| research

10 Swap Drills for **Light Energy**  
| Prof Matthias Frentzen

| case report

12 **Lase to amaze**  
| Dr Kirpa Johar

16 **Treatment of epulis** using the 980 nm diode laser  
| Dr Merita Bardhoshi

18 Novel technique for using the diode laser to treat refractory erosive **oral lichen planus**  
| Prof Dr Sajee Sattayut

| user report

22 **Laser** ridge preservation  
| Dr Darius Moghtader

24 **Optical imaging** in the oral cavity  
| Danielle Le *et al.*

30 **Morphological changes** in hard dental tissue prepared using Er: YAG laser  
| Dr Snejana Ts. Tsanova *et al.*

36 Efficient and ergonomic **apical resection** using the Kaiserswerth algorithm  
| Prof Marcel Wainwright

| feature

40 “The Scanner mode is going to **revolutionise dentistry**”  
| An interview with Dr Ladislav Grad & Dr Matjaz Lukac

| meetings

42 **International** events 2011 & 2012

44 3<sup>rd</sup> European Congress of the **WFLD** in Rome  
| Umberto Romeo

46 Basic **Laser Certification** Course in Malaysia

| news

48 **Manufacturer** News

| about the publisher

50 | Imprint



Cover image courtesy of A.R.C. Laser GmbH, [www.arclaser.de](http://www.arclaser.de)



Photodynamic breakthrough

**A.R.C.  
LASER**

**EmunDo<sup>®</sup>**  **FOX**

- Extreme effective against Gram-positive and Gram-negative bacteria
- The reliable PDT-therapy – designed for the treatment of periodontitis



[www.arclaser.de](http://www.arclaser.de)





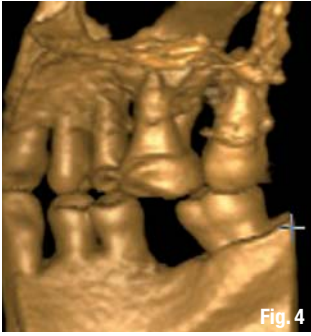


Fig. 4

DATE:	8/3/10																
EXAM TYPE:	Comprehensive <input type="checkbox"/> Limited <input type="checkbox"/> Screening <input type="checkbox"/> Reevaluation <input type="checkbox"/> Post-Operative Evaluation <input checked="" type="checkbox"/>																
TOOTH #	1	2	3	4	5	6	7	8	9	10	11	12	13	14	15	16	17
Pockets:	F 333	333	333	312	333	333	333	333	333	333	333	333	333	333	333	333	333
Recession:	F 2	3															
Na.AG:	F																
Ma.AG:	F																
Mobility:																	
Function:	F																
Codes:																	
Other:																	
H & N Exam:	• Class: Malocclusion																
POS / NEG:	• Fremitus in Sliding Movements: # in C.O. #																

Fig. 5

Fig. 4 Pre-op CBT scan.

Fig. 5 Post-op periodontal probing at 15 months.

periodontal disease. Regeneration is a rather complex event and, as seen with guided tissue regeneration or scaling and root planning alone, can be very unpredictable. LANAP is predictable. Clinically, those clinicians who have been using the LANAP protocol for some time know this, and its predictability was reinforced when new attachment was found on all the LANAP-treated teeth in the initial histology studies done by Dr Ray Yukna. LANAP is also a very safe protocol. The use of the Nd:YAG laser has often been of concern by some owing to possible damage to root surfaces and the tissue attachment but, with a basic understanding of laser physics, laser-tissue interaction parameters were developed that enabled the use of an Nd:YAG in a very safe and effective manner. LANAP is also standardised. That is, before a doctor can obtain his laser he goes through three days of training: one day of laser physics and laser-tissue interaction and then two days of hands-on training with patients. This is then followed up by two more separate days of treating patients to refine techniques and add other treatment modalities utilising the Nd:YAG. Because of the simplicity, predictability and standardisation of LANAP, it has become a very safe and effective way to treat periodontal disease.

The simplicity of the LANAP protocol can be seen in Table I.

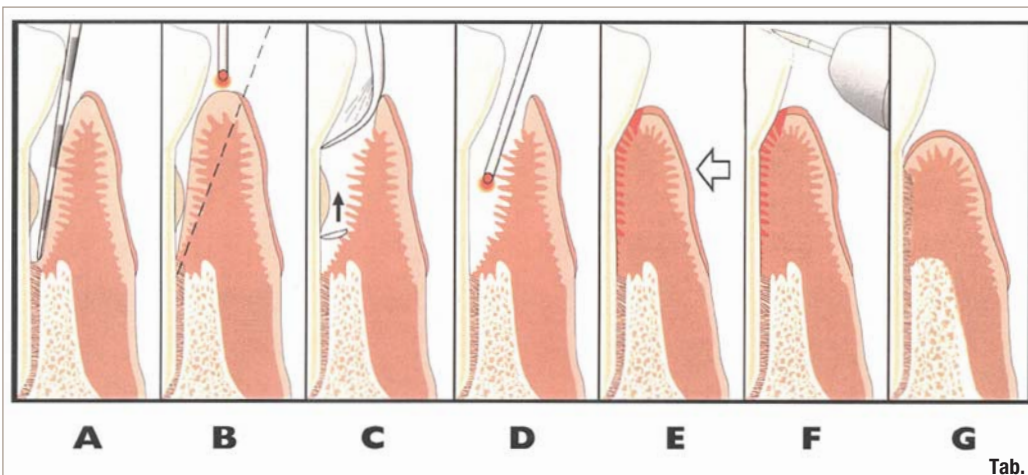
### The LANAP protocol

#### Step A

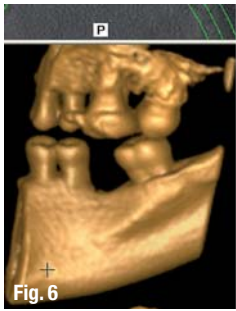
Patients undergo a full dental examination and treatment plan—as with all dentistry. If they have an appropriate diagnosis of Type III or greater periodontal disease, all treatment options are presented to the patient. The initial step of the LANAP protocol, after anaesthesia has been administered, is bone sounding around each tooth. The objective is to determine areas of osseous defects that cannot be seen radiographically.

#### Step B

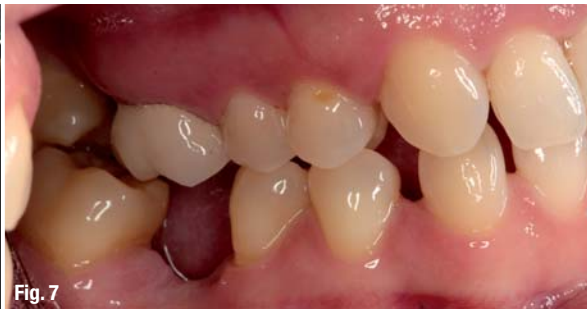This is the first time the laser is used. The objective of this step is to remove only diseased epithelium, to affect selectively bacteria associated with periodontal disease, to affect the calculus present, and to affect thermolabile toxins. The bacteria that are associated with periodontal diseases are pigmented and are found in the sulcus, within the root surface and within the epithelial cells. One of the reasons for the predictability of this step is in the selection of a free-running pulsed Nd:YAG laser with a wavelength of 1,064 nm and pulsed in a range of seven different microseconds. The shorter 1,064 nm wavelength was selected for its affinity for melanin or dark pigmentation, unlike the longer wavelengths that are highly absorbed in water and would have a shallow depth of



Tab. I



**Fig. 6**\_CBT scan 15 months post-op LANAP.



**Fig. 7**\_Pre-op photograph.

penetration. This ability to increase the depth of penetration of the laser energy with minimal collateral damage is the reason that the diseased epithelium can be selectively removed without damage to the underlying tissue, leaving intact rete pegs. The diode lasers are also known for this selective absorption in pigmented tissues, but the free-running, pulsed Nd:YAG lasers differ in their ability to operate at very high peak powers in very short timeframes, which allows the Nd:YAG to have the greater depth of penetration and the lack of collateral damage (Fig. 1).

*Step C*

This step in the LANAP protocol is straightforward; it is just a matter of using the piezo-scalers to remove the calculus present on the root surfaces. The removal of calculus is believed to be easier after the interaction of the laser energy with the calculus. The first interaction of the laser results in the initial formation of a mini-flap, thereby further assisting in the removal of calculus because of increased visibility and access to the calculus.

*Step D*

The next step again utilises the laser. This time the parameters are varied to enhance the ability to form a fibrin clot to close the mini-flap and to disinfect the site again. The formation of the stable fibrin clot is significant, as it is stable for approximately 14 days. The role of the fibrin clot is to keep the sulcus sealed against bacterial infiltration and to prevent the growth of epithelium down into the sulcus. Other laser wavelengths not only lack the ability to form this stable fibrin clot, but also require repeated

treatments to prevent epithelium growth down into the sulcus. The ability to select the laser-tissue interaction specifically is unique to the PeriLase MVP-7 (Millennium Dental Technologies). Through the use of specific fibre sizes, energy, repetition rates, pulse durations and standardisation of the energy at the fibre tip, this protocol can be followed in a predictable and reproducible manner. The high standard of training that each LANAP doctor receives also contributes to the predictability of this protocol and to its safety. Patients often present with different tissue types along with different degrees of disease. One of the purposes of the hands-on training is learning to recognise these differences and how to change the laser parameters accordingly so that the desired laser-tissue interactions are achieved. (Fig. 2)

*Step E*

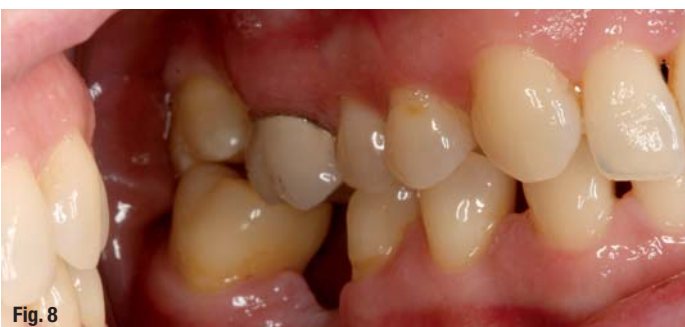The fifth step in LANAP is the compression of the fibrin clot to enhance the healing process. Because laser wounds heal by secondary intention, closer approximation enhances the healing time.

*Step F*

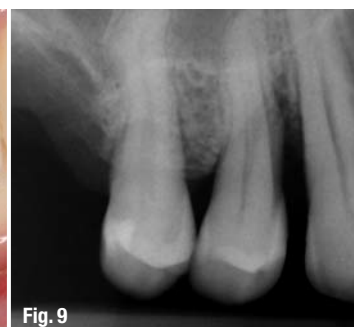Following the compression and stabilisation of the clot, the last step of LANAP is refining the occlusion. Occlusion has been considered a greater co-factor in the progression of periodontal disease than smoking. In order to minimise this role, extensive adjustments are made to the dentition.

The patients are then followed for nine to 12 months with routine supra-gingival cleanings and occlusal refinements. No sub-gingival restorative or periodontal probing is done during this time. Only during the final post-operative visit is a periodontal probing done.

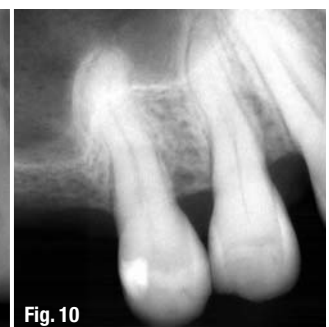The results that are seen from LANAP treatment are very similar to the following cases, where new bone fill can be seen in vertical osseous defects. The bone fill ranges from simple proximal defects to the more complex furcation defects. The hallmark of LANAP is pocket reduction, new tissue attachment and a lack of tissue recession.



**Fig. 8**



**Fig. 9**



**Fig. 10**



**\_LANAP case 1**

The patient in this case was a 40-year-old female patient with a history of lupus, rheumatoid arthritis and Sjögren's syndrome. She was also a smoker. There was generalised deep pocketing as seen in her periodontal charting (Fig. 3). The extent of the osseous defect is shown on the lingual view of the right quadrant preoperative CBT scan (Fig. 4). The initial post-LANAP evaluation was done at 15 months. Post-operative probing is shown in Figure 5. The CBT from the lingual view of the right quadrant at 15 months post-operatively is shown in Figure 6. The change in the osseous defects is apparent. Minimal to no recession is shown in the preoperative clinical photograph in Figure 7 and the post-operative in Figure 8.

**\_LANAP case 2**

The patient in this case was a 59-year-old male patient, with Type 1 diabetes and a smoker. His periodontal pocketing was 7 mm on the mesial second premolar. The preoperative X-ray is shown in Figure 9 and the 36-month post-LANAP X-ray in Figure 10. The 7 mm pocket had been stable and maintained at 3 mm for the last 36 months. The LANAP protocol will be 21 years old this year. It is coming of age. It has stood

the test of time. There are over 1,000 trained clinicians applying LANAP. They have all been standardised. The uniqueness of the protocol is that whether the doctor is new to LANAP or a veteran "LANAP'er", his results are similar. During its early stages, early adopters accepted LANAP with anecdotal evidence alone, which was reinforced by the individual successes seen clinically. It was further validated by Dr Ray Yukna's histological studies in 2003. As the LANAP multicentre clinical studies move to completion, it would be reasonable to expect to see LANAP become the conventional manner or the standard for the treatment of periodontal disease. It is a very simple but eloquent protocol, one in which the patient has no to minimal discomfort and treatment acceptance is high.

**\_contact****laser****Dr David Kimmel**


12124 Cobble Stone Dr  
Bayonet Point, Florida 34667  
USA

E-Mail: [dskimmel@mac.com](mailto:dskimmel@mac.com)  
Tel.: +1 727 862 8513

AD

**LaserHF®**

# Laser meets Radio Frequency

**LaserHF®****Worldwide first combined Laser plus HF unit**

- Pre-adjusted programs for all dental soft tissue treatments, with individual programming
- Easy handling by dual operating concept: touch-screen and automatic starting system
- Modern radio frequency surgery (2.2 MHz) allows easy, fast and precise cutting
- Diode laser (975 nm) for periodontology, endodontology and implant exposure
- Therapeutic laser (650 nm) for Low Level Laser Therapy (LLLT) and antimicrobial Photodynamic Therapy (aPDT)
- Good value of money

[www.hagerwerken.de](http://www.hagerwerken.de)

Tel. +49 (203) 99269-26 · Fax +49 (203) 299283


**HÄGER  
WERKEN**