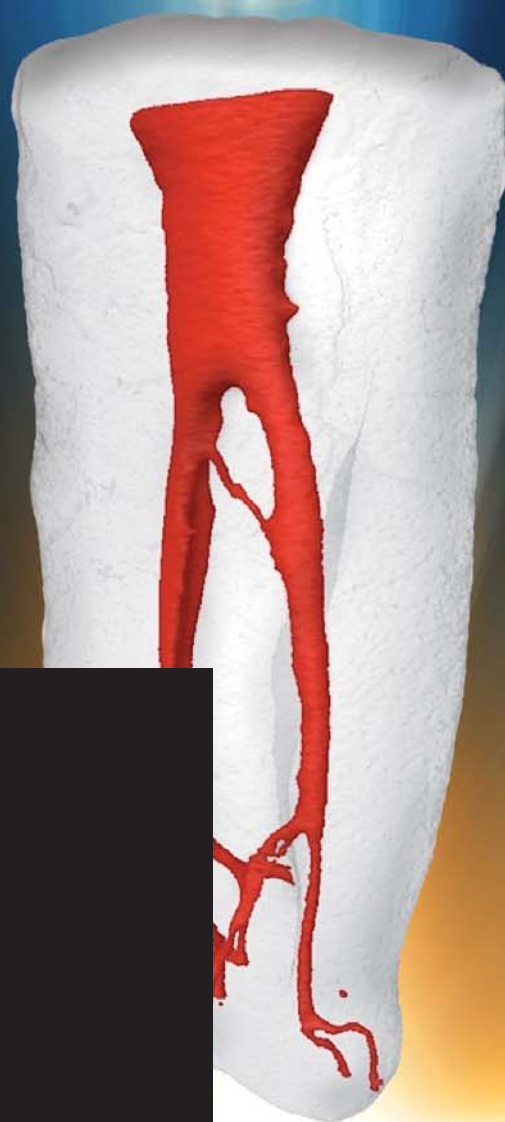

# roots

international magazine of endodontology

2<sup>2014</sup>



## | CE article

Passive micro-volume management of sodium hypochlorite in endodontic treatment

## | review

Instrument fracture removal revisited

## | industry report

BT-Race: Biological and conservative root canal instrumentation with the final restoration in mind

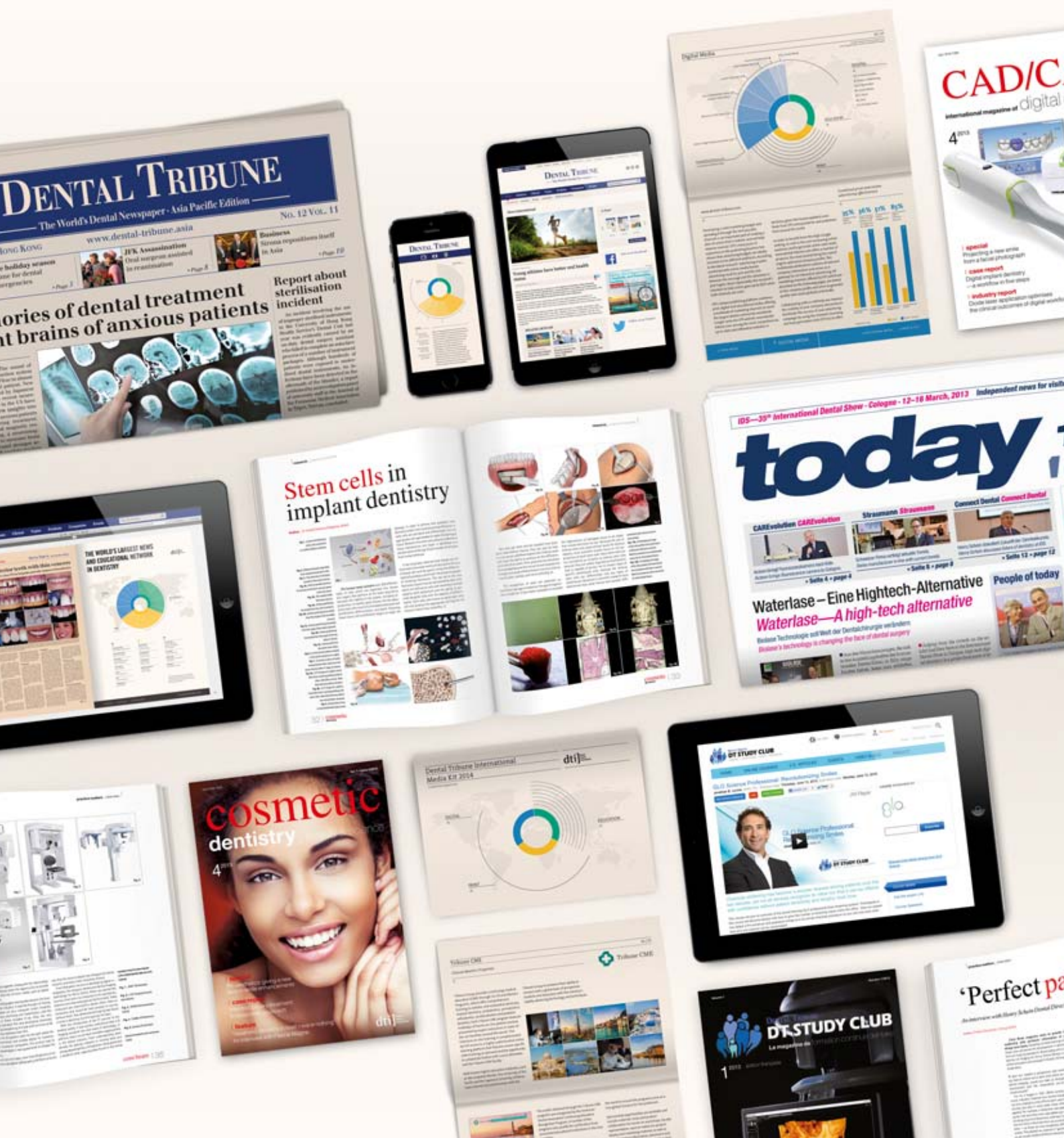

# Dental Tribune International

## The World's Largest News and Educational Network in Dentistry

dti] Dental  
Tribune  
International

[www.dental-tribune.com](http://www.dental-tribune.com)



# Dear Reader,

\_Mahatma Gandhi once said, "Live as if you were to die tomorrow; learn as if you were to live forever." Learning, thus, is a never-ending process, more so in dentistry and particularly in endodontics. In this present era, knowledge is just a click away; however, the authenticity of such information is not always reliable. Literature plays a vital role in the shaping of a dentist into a concept-driven clinician. Apart from textbooks and journals, various educational forums where knowledge and clinical skills are shared without barriers contribute to the field of dentistry. One such online forum is Roots, which has been passionately educating and motivating young general dentists and endodontists. It has welcomed all those who have a passion for endodontics into its fold.



Dr Sekar Mahalaxmi

The majority of the advancements in endodontics are technology driven. Complete dependence on gadgets, however, without application of basic concepts makes us technicians, not endodontists. These tools can only be useful adjuncts to good theoretical knowledge and clinical skills. What better place to obtain the best of both, the latest in technological advancements and the training to use them to enhance your concept-driven clinical acumen, than dental meetings? Roots Summits have been held in various parts of the world. The last one was held at Foz do Iguaçu in Brazil in 2012. This year's Roots Summit will be held in Asia for the first time, in Mahabalipuram, a peaceful beach town near the southern city of Chennai in India. The organising committee has been working tirelessly to make this summit a memorable one. An array of national and international speakers are working on presentations, including the complexities of the root canal, the management of separated instruments, and regenerative endodontics, which are critical areas in today's clinical scenario in endodontics. To add to this, there are more than a dozen pre-summit workshops to choose from for those who wish to gain first-hand experience. This will be a golden opportunity for all dentists from Asian countries and from far to meet in India to further enhance their knowledge and skills in a positive way. To learn more about the technological advancements, there is no better place than the summit, where there will be a plethora of dental companies showcasing the latest in the field of endodontics.

roots magazine has always been known for its superior quality, in its articles, illustrations and print. This issue too covers topics that will offer insights on instrument retrieval, pre-endodontic restorations, conservative root canal instrumentation and phototherapy, among others.

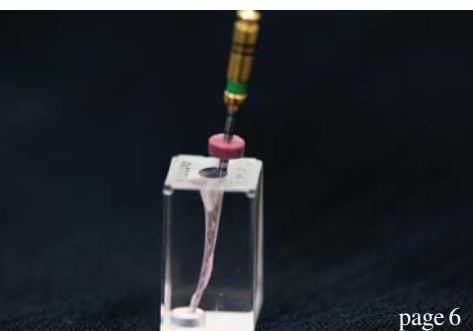I wish to sign off with an invitation to every reader and member of the Roots community to attend Roots Summit 2014 and contribute to its success.

Yours faithfully,

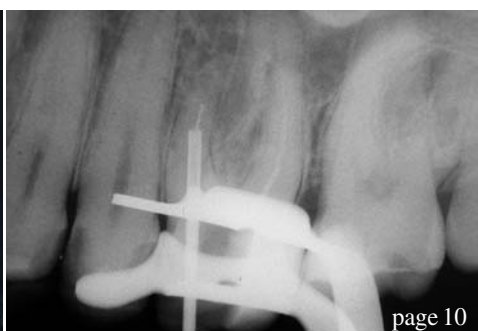*Mahalaxmi*

Dr Sekar Mahalaxmi  
Head of the Department of Conservative Dentistry and Endodontics  
SRM University, College of Dentistry, Chennai, India

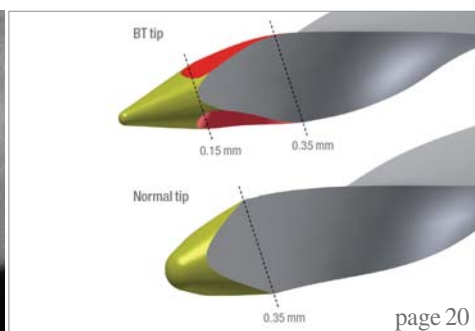




page 6



page 10



page 20

## editorial

- 03 **Dear Reader**  
| Dr Sekar Mahalaxmi

## CE article

- 06 **Passive micro-volume management of sodium hypochlorite in endodontic treatment**  
| Dr Les Kalman

## review

- 10 **Instrument fracture removal revisited**  
| Drs Dominique Martin & Pierre Machtou

## industry report

- 20 **BT-Race: Biological and conservative root canal instrumentation with the final restoration in mind**  
| Drs Gilberto Debelian & Martin Trope

## case report

- 24 **Managing coronal destruction**  
| Dr Andreas Schult

## feature

- 28 **Root canal therapy setting your teeth on edge?**  
| Dr Peter Southerden

## research

- 30 **Diclofenac, dexamethasone or laser phototherapy? Part I**  
| Jan Tunér

## industry news

- 34 **SIROLaser Factbook: Comprehensive information on diode lasers**  
| Sirona Dental
- 36 **Planmeca and the University of Turku found Nordic Institute of Dental Education**  
| Planmeca

## events

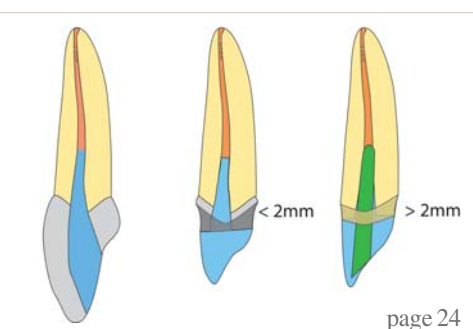
- 38 **"Striving for perfection"—AAE holds 2014 Annual Session in Washington**  
| AAE
- 40 **International Events**

## about the publisher

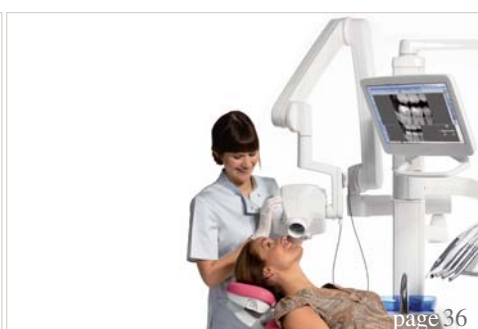
- 41 | submission guidelines  
42 | imprint



Cover image: first mandibular premolar anatomical variation  
by Ronald Ordinola Zapata



page 24



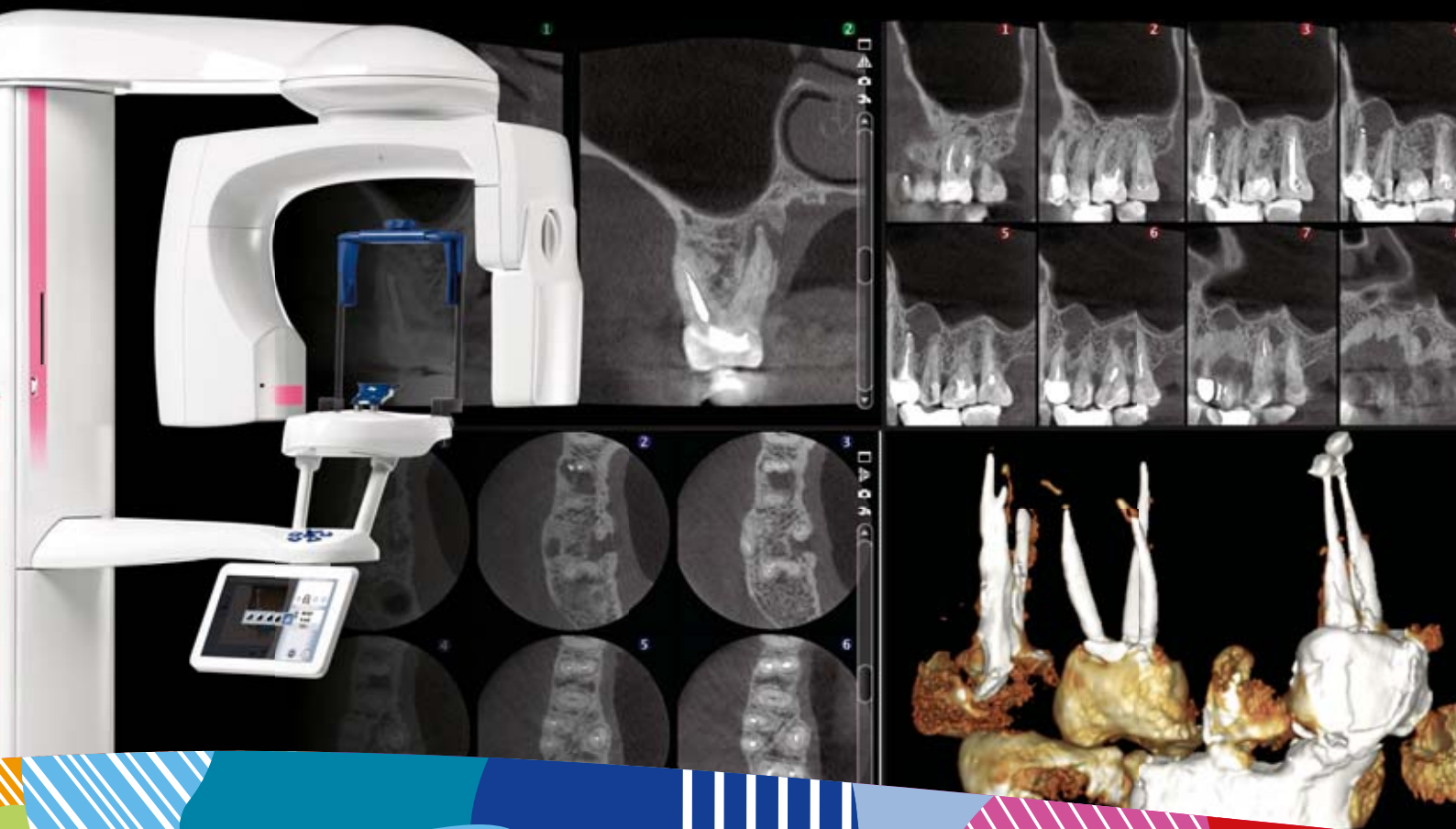
page 36



page 38

# Planmeca ProMax® 3D

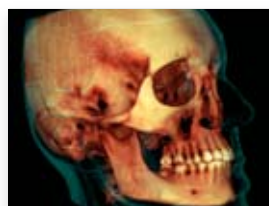## Endodontic imaging mode – a new era in precision



### Perfect visualisation of the finest details

- Extremely high resolution with 75  $\mu\text{m}$  voxel size
- Noise-free images with intelligent **Planmeca AINO™** filter
- Artefact-free images with efficient **Planmeca ARA™** algorithm

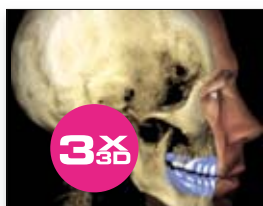Other unique features in Planmeca ProMax® 3D family units:



#### Ultra low dose imaging

CBCT imaging with an even lower patient dose than panoramic imaging.

Adult female, FOV  $\varnothing 200 \times 180 \text{ mm}$   
Effective dose **14.7  $\mu\text{Sv}$**   
Planmeca ProMax® 3D Mid



#### Create your virtual patient

A world first:  
One imaging unit,  
three types of 3D data.  
All in one software.

CBCT + 3D model scan + 3D face photo

Find more info and your local dealer  
[www.planmeca.com](http://www.planmeca.com)

# PLANMECA



Planmeca Oy Asentajankatu 6, 00880 Helsinki, Finland. Tel. +358 20 7795 500, fax +358 20 7795 555, sales@planmeca.com

# Passive micro-volume management of sodium hypochlorite in endodontic treatment

Author\_ Dr Les Kalman, USA

\_ce credit

roots



This article qualifies for CE credit. To take the CE quiz, log on to [www.dtstudyclub.com](http://www.dtstudyclub.com). Click on 'CE articles' and search for this edition of the magazine. If you are not registered with the site, you will be asked to do so before taking the quiz. You may also access the quiz by using the QR code.

## \_Abstract

The passive utilization and micro-volume management of sodium hypochlorite as an endodontic irrigant has been illustrated with a laboratory demonstration and several clinical cases. By limiting the volume and pressure of sodium hypochlorite, the injurious effects can be minimized while still benefiting from the ideal disinfecting characteristics. Further studies are required to understand the behaviour of fluids, especially sodium hypochlorite, within the context of permeability, fluid mechanics and multi-phase fluid flow through porous media.

## \_Introduction

Endodontic treatment addresses the removal of the tooth's internal pulp and micro-organisms,<sup>1</sup> primarily due to infection and necrosis. Once proper diagnosis and prognosis has been established, the patient has the option of maintaining the tooth's form and function while the vitality becomes lost. Current endodontic treatment consists of utilizing rotary files to remove the pulpal tissue and shape the internal dentin chamber of the tooth. Chemicals, in the form of gels and liquids, are then implemented to disinfect the canal(s) and eliminate bacteria.<sup>2</sup> The chemicals are then dried and the canal space filled with either gutta-percha or resin to create a hermetic seal.

The chemicals employed to clean and disinfect the intracanal space are vast and include file lubricants such as Prolube (DENTSPLY) and irrigants such as QMix (DENTSPLY). During clinical endodontics, the canal is filled with a cocktail of chemicals, as file lubricants and irrigants become a mixture.

**Fig. 1\_** DENTSPLY Vortex rotary file with sodium hypochlorite.

**Fig. 2\_** DENTSPLY Profile rotary file with dyed sodium hypochlorite.



Fig. 1



Fig. 2

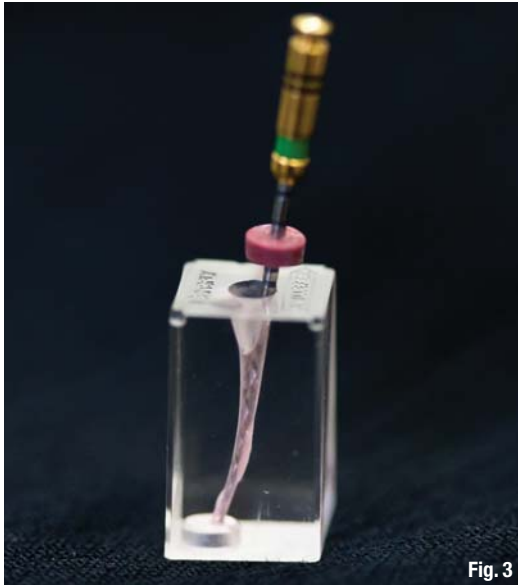


Fig. 3

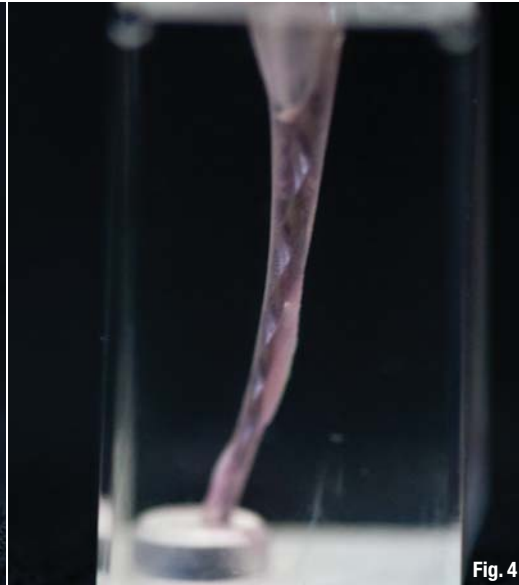

Fig. 4

**Fig. 3** \_Micro-volume delivery of sodium hypochlorite with rotary file.  
**Fig. 4** \_Sodium hypochlorite in block with rotary file.

Chlorhexidine gluconate (CHX) is an uncommonly used irrigant<sup>3</sup> with several desirable properties. It provides antimicrobial activity against certain aerobic and anaerobic bacteria, exhibits no significant changes in bacterial resistance in the oral microbial environment and has no injurious effect to the skin or mucosa<sup>4</sup>. In fact, CHX has a role as an oral rinse at the 0.12 per cent concentration.<sup>4</sup>

Sodium hypochlorite (NaOCl) still remains the most commonly used chemical,<sup>2,3</sup> due to its availability, cost and effectiveness.<sup>2,5</sup> Sodium hypochlorite is effective against broad-spectrum bacteria and has the ability to dissolve both vital and necrotic tissue.<sup>6</sup> However, this irrigant is equally damaging to the patient and has a history of injurious effects.<sup>5</sup> Typically the NaOCl is delivered into the canal space with a syringe dose of 2–10 ml that is expelled under pressure. The ability of NaOCl to escape either through poorly sealed isolation or other means can cause serious injury to the patient.<sup>5</sup>

Injury from NaOCl is well established in the literature<sup>3,5,6</sup> and has been attributed to three main errors: poor handling, injection beyond the apical foramen and allergy.<sup>6</sup> Poor handling injury can result in operator and/or patient injury to the eye and/or skin.<sup>6</sup> Injection beyond the apical foramen can result in the following:<sup>6</sup>

- \_ immediate and severe pain,
- \_ edema to adjacent tissue edema,
- \_ edema to the lip, infraorbital region, and side of face,
- \_ intense bleeding from within the canal space,
- \_ skin and mucosa bleeding,
- \_ intestinal bleeding,
- \_ paraesthesia,
- \_ secondary infection.

Allergy from NaOCl is rare but has been reported and may result in severe pain, a burning sensation, edema and transient paraesthesia.<sup>6</sup>

### \_Methodology

Although there is no universally accepted irrigation protocol regarding endodontic treatment,<sup>3</sup> it is the duty of the clinician to apply evidence-based dentistry within clinical parameters to provide their patients with the highest standard of care with minimal morbidity. The use of NaOCl has numerous beneficial factors that maximize treatment success; however, it is the application of the liquid that can cause injury.

Micro-volume management of NaOCl has been proposed. The concept is based on the premise that endodontic instruments have irregular surfaces, crucial for dentinal preparation, and that liquids exhibit surface tension characteristics.<sup>7</sup> By placing an instrument into a suitable container, the NaOCl will be carried within the surface texture of the instrument (Figs. 1 & 2). As the operator inserts the instrument into the canal (Fig. 3), the NaOCl is carried with it. Upon instrument movement, the NaOCl is released into the canal space (Fig. 4). Surface tension and permeability of porous media (dentin) will also increase the ability of the liquid to percolate into the canal.<sup>7</sup> This approach is radically different than current philosophies, as the NaOCl is introduced into the canal space in a micro-volume amount without any pressure. The operator has control of the minimized liquid while benefitting from its effectiveness.

The micro-volume management of sodium hypochlorite has been applied to numerous clinical cases. Post-operative obturation radiographs of completed clinical cases have been presented (Figs. 5–9).



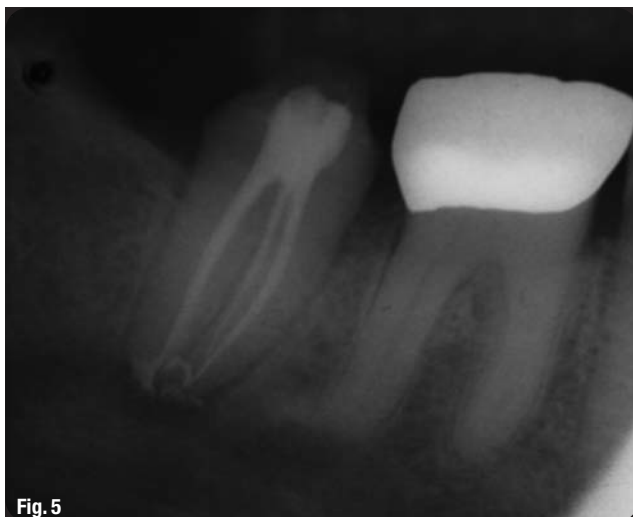


Fig. 5

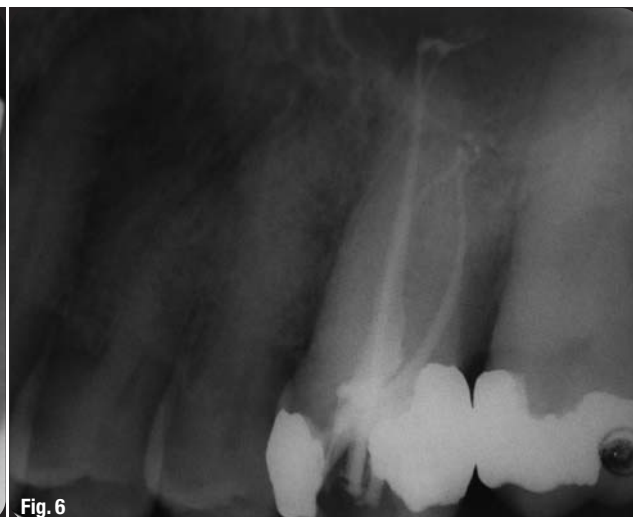

Fig. 6

**Fig. 5\_** Radiograph of endodontic treatment on tooth #47.

**Fig. 6\_** Radiograph of endodontic treatment on tooth #26.

## \_Discussion

The canal system inside a tooth is very complex. Although there is the presence of one or more canals, there also exist numerous micro tunnels, ribbons and sheets throughout the canal network.<sup>8</sup> The canals are also housed within a porous dentinal structure, for which the permeability has been distinguished.<sup>9</sup> Although the elimination of the pulp is a relatively predictable clinical procedure, the introduction of liquids into this complex micro-network porous development further complicates matters. If the clinician introduces liquids, then the successful removal of those liquids is key to clinical success. Concepts of multi-phase fluid flow through porous media and capillaries,<sup>10</sup> permeability of porous media<sup>11</sup> and surface tension fluid mechanics<sup>7</sup> must be recognized to validate and further advance canal irrigation.

**Fig. 7\_** Radiograph of endodontic treatment on tooth #16.

**Fig. 8\_** Radiograph of endodontic treatment on tooth #36.

Micro-volume management of NaOCl has been suggested as a delivery modality to maximize its bactericidal effects yet minimizing its injurious effects.

Surface tension fluid mechanics and permeability<sup>7,10,11</sup> suggest that the NaOCl can be carried within the surface irregularities of endodontic instrumentation and deposited into the canal space and percolate within the complex network of the canal. The passive management of the irrigant in micro-volume would greatly reduce complications due to poor handling. CHX has been suggested as the larger volume, positive pressure irrigant that may be delivered into the canal space. CHX has favourable antibacterial characteristics but minimal injurious effects, if mismanagement of the irrigant has occurred. If positive pressure delivery of CHX is required, the operator should regulate the pressure and avoid the risk of injection beyond the apex. The use of EDTA (ethylenediamine-tetraacetic acid) could be employed after NaOCl, to minimize the formation of precipitates.<sup>2</sup>

The application of micro-volume management of NaOCl suggests that the canal space can be effectively cleaned in a conservative manner. Application of this principle has been applied to clinical cases with little

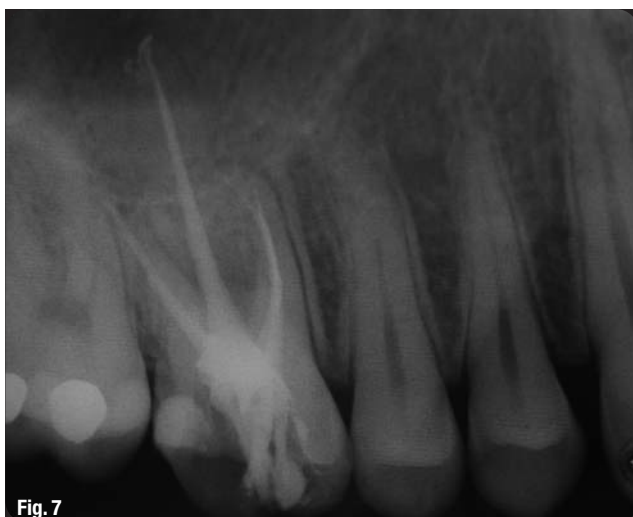

Fig. 7

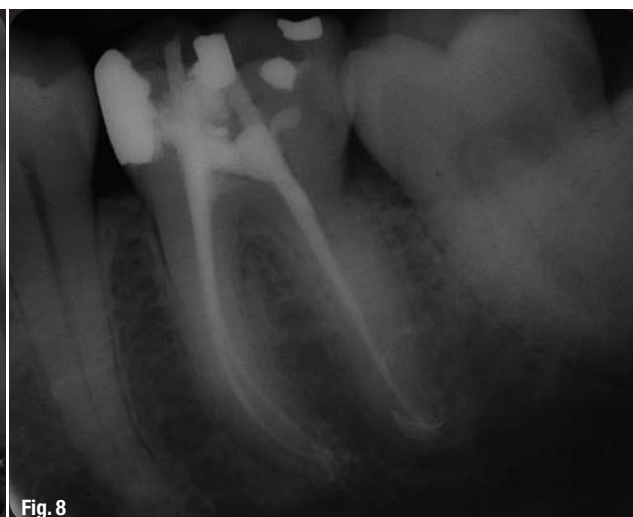

Fig. 8



to no post-endodontic sensitivity. Obturation has been completed with ThermaSeal and Thermafil (DENTSPLY). Even though there is evidence of sealer extrusion, the absence of post-operative symptoms and pathology suggests adequate volume for sufficient disinfection.

Further laboratory studies are required to understand permeability, fluid mechanics and multiphase fluid flow through porous media and their relation to the micro-management of NaOCl. Additional clinical investigations should be implemented to assess and validate the efficiency and efficacy of micro-volume management of sodium hypochlorite on endodontic therapy.

## \_Conclusions

Introduction of lubricants and irrigants into the canal complex is crucial for endodontic success. The action of fluids in the canal complex must be understood within the context of permeability, fluid mechanics and multiphase fluid flow through porous media.

NaOCl has several advantages for its role as an endodontic irrigant, but its use must be exercised with caution in order to prevent injury. Application of NaOCl as a passive, micro-volume liquid has been illustrated.

Further consideration is required to validate the theory. The potential to minimize morbidity while maximizing clinical endodontic success seems promising for both clinician and patient.

## \_References

1. Dang E. Comparison of sodium hypochlorite and chlorhexidine gluconate: quality of current evidence. *The Journal of Young Investigators: An Undergraduate, Peer-Reviewed Science Journal* 2008;23(1):1–9.
2. Basrani BR, Manek S, Rana SNS, Fillery E. and Manzur A. Interaction between sodium hypochlorite and chlorhexidine gluconate. *J Endod* 2007;33: 966–969.
3. Dutner J, Mines P, and Anderson A. Irrigation trends among American Association of Endodontists members: a web-based survey. *J Endod*: 2011: 1–4.
4. 3M ESPE: Peridex™ Chlorhexidine Gluconate (0.12%) Oral Rinse Fact Sheet: 2009.
5. Clarkson RM, and Moule AJ. Sodium hypochlorite and its use as an endodontic irrigant. *Australian Dental Journal* 1998;43(4):250–6.
6. Hülsmann H. & Hahn W. Complications during root canal irrigation-literature review and case reports. *International Endodontic Journal*: 2000;33:186–193.
7. Trefethen L. Surface tension in fluid mechanics. *Encyclopaedia Britannica*. (12<sup>th</sup>) Wiley: Chicago, 1969;1–7.
8. West JD, Roane JB and Goering AC. Cleaning & shaping of the root canal system. In Cohen S. and Burns RC. *Pathways of the Pulp*. (6<sup>th</sup> ed.) Mosby: St. Louis, 1994;179–218.
9. Trowbridge HO. and Kim S. Pulp development, structure & function. In Cohen S. and Burns RC. *Pathways of the Pulp*. (6<sup>th</sup> ed.) Mosby: St. Louis, 1994;296–336.
10. Templeton CC. and Rushing SS. Jr. Oil-water displacements in microscopic capillaries. *Journal of Petroleum Technology*. 1956;8(9):211–214.
11. Crotti MA. *Motion of Fluids in Oil and Gas Reservoirs*. Mosby: New York, 1978;8–14.

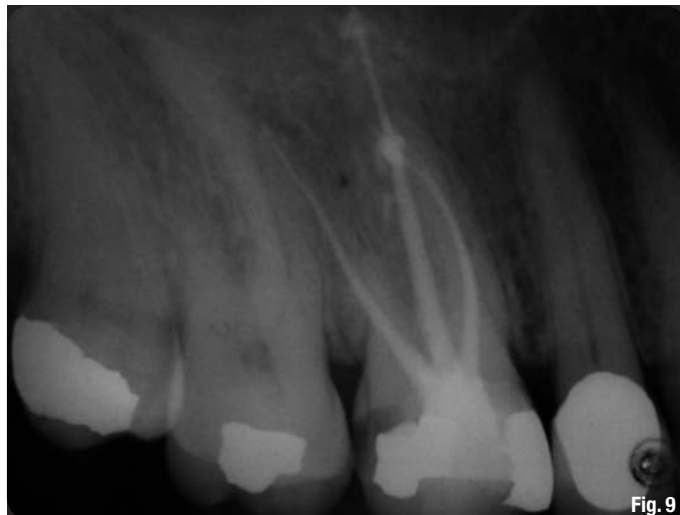

Fig. 9

**Fig. 9** Radiograph of endodontic treatment on tooth #16.

## \_about the author

## roots



**Dr Les Kalman, B.Sc. (Hon), DDS**, graduated from the University of Western Ontario with a doctor of dental surgery degree in 1999. He then completed a GPR at the London Health Sciences Centre. He has been involved in general dentistry within private practice since 2000. He has served as the chief of dentistry at the Strathroy-Middlesex General hospital. In 2011, he transitioned to full-time academics as an assistant professor at the Schulich School of Medicine and Dentistry. Kalman's research focuses on clinical innovations, including the Virtual Facebow app. Kalman is also the director of the Dental Outreach Community Services (DOCS) program, which provides free dentistry within the community. Kalman has authored articles ranging from paediatric impression to immediate implant surgery in both Canadian and American journals. He has been a product evaluator for several companies, including GC America and Clinician's Choice. Kalman is the co-owner of Research Driven, a company that deals with intellectual property development. Kalman is a member of the American Society for Forensic Odontology, International Team for Implantology, Academy of Osseointegration, American Academy of Implant Dentistry and the International Congress of Oral Implantology. He has been recognized as an Academic Associate Fellow (AAID) and Diplomate (ICOI). In his spare time, Kalman enjoys photography as an accredited MotoGP photojournalist. He can be contacted at [lkalman@uwo.ca](mailto:lkalman@uwo.ca)