

laser

international magazine of laser dentistry

1 2012



| overview

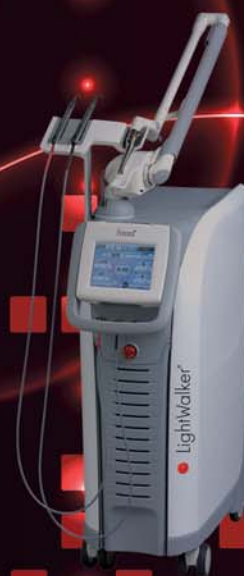Laser treatment of dentine hypersensitivity

| industry report

Bleaching: New approaches to a traditional minimally invasive therapy

| meeting

13th WFLD World Congress in Barcelona



dentis

The universe at your fingertips.

TouchWhite™ Laser Assisted Tooth Whitening

A perfect white smile now faster and safer than ever before

- Utilizing the unique laser tissue interaction of the Er:YAG laser wavelength and Fotona's VSP pulse mode
- Up to 10 times shorter treatment times
- Safer - no unnecessary thermal burden on the tooth or pulp
- More comfortable for patients while achieving the same or better whitening efficacy
- Any bleaching gel color can be used
- Perfect, natural looking results after one single treatment

Available only with



LightWalker[®]



Welcome to the WFLD World Congress in Barcelona



Prof Dr Norbert Gutknecht
Editor-in-Chief

It's hard to believe that already two years have passed since we said Goodbye in Dubai. It seems time has passed faster and faster, maybe because more and more dental events are on display. Today, hardly anybody is able to visit all the conferences and congresses which are offered.

It's all the more pleasing to know that certain conferences like the WFLD congress have maintained a permanent place in your agenda. Looking at the high numbers of poster and abstract submissions, one can estimate that lasers in dentistry are a topic more relevant than ever.

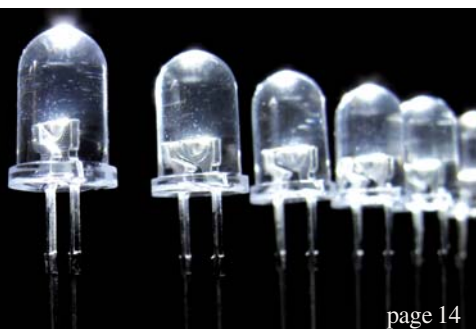
The active participation of the largest manufactures of dental lasers as sponsors and exhibitors, along with the high number of laser manufacturers in general who partake in the exhibition, also has a high impact on the congress: visitors and participants benefit from the opportunity to see different laser systems in exhibitions, workshops or live demonstrations.

Last but not least, the cultural aspects of the congress venue, the city of Barcelona, are worth undertaking a trip to the upcoming WFLD Congress. Springtime in the streets of Barcelona, a sunset dinner with friends on the shore of the Mediterranean Sea, the visit of historical museums, all combined with lectures, workshops and seminars of the congress, will make this event unforgettable.

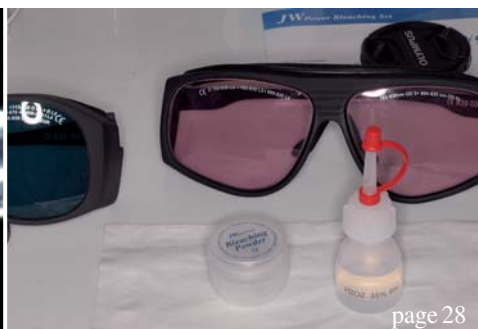On part of the *Laser Journal* I send my best wishes to the organizers, the board of the WFLD, the speakers and all participants for an inspiring and successful conference.

A handwritten signature in black ink, which appears to read 'Gutknecht'.

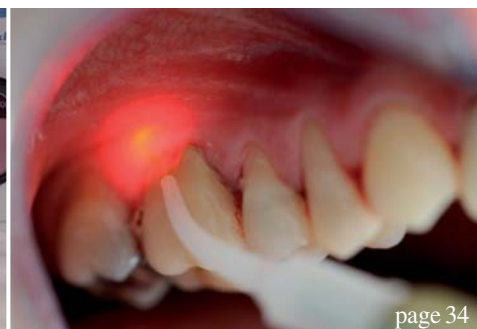Prof Dr Norbert Gutknecht
Editor-in-Chief



page 14



page 28



page 34

| editorial

- 03 Welcome to the **WFLD World Congress** in Barcelona
| Prof Dr Norbert Gutknecht

| research

- 06 Laser in **oral surgery** and medicine
| Antonio Batista-Cruzado et al.
- 10 Influences on the treatment of **recurrent aphthous ulcers** with the Nd:YAG laser
| Dr Iris Brader
- 14 Treatment of **chronic periodontitis** by laser and LED-PDT light
| Dr G. Karakitsos

| overview

- 20 Laser treatment of **dentine hypersensitivity**
| Dr Ute Botzenhart et al.

| case report

- 26 The management of **pyogenic granuloma** with the 980 nm diode laser
| Dr Merita Bardhoshi

| industry report

- 28 **Bleaching**: New approaches to a traditional minimally invasive therapy
| Dr Kresimir Simunovic et al.
- 34 **Effective** treatment of **periodontal** problem areas
| Prof Frank Liebaug

| education

- 38 Laser-assisted Pediatric Dentistry
| Dr Gabriele Schindler-Hultzsich
- 44 The Mundus ACP Program: aiming for a **brighter future**
| Prof Dr Norbert Gutknecht
- 46 **11th** "MSc in Lasers in Dentistry" class graduates at RWTH Aachen University
| Dajana Klöckner

| meetings


- 42 **13th WFLD World Congress** in **Barcelona**
| Dr Antoni España
- 47 **International** events 2012

| news

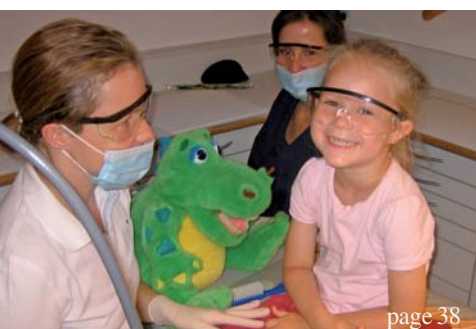- 40 **Manufacturer** News
- 48 **News**

| about the publisher

- 50 | imprint



Cover image courtesy of Fotona d.d.,
www.fotona.com.
Artwork by Sarah Fuhrmann, OEMUS MEDIA AG.



page 38



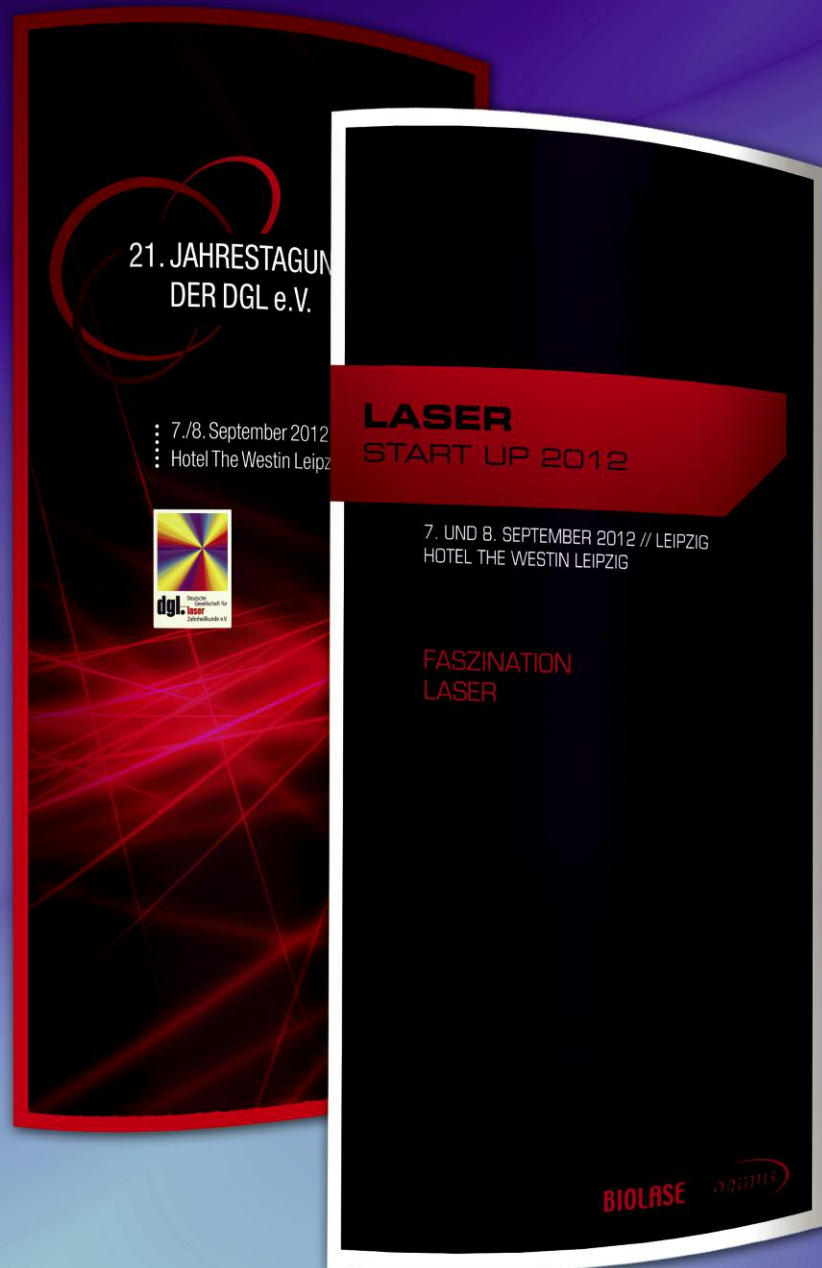page 42



page 44

» FASCINATION OF LASER DENTISTRY

FOR EXPERTS AND BEGINNERS



SEPTEMBER 7–8, 2012//
LEIPZIG//HOTEL THE WESTIN
LEIPZIG, GERMANY

MAIN SPONSOR

BIOLASE

ORGANIZATION/
REGISTRATION

OEMUS MEDIA AG
Holbeinstraße 29
04229 Leipzig
Tel.: +49 341 48474-308
Fax: +49 341 48474-390
event@oemus-media.de
www.dgl-jahrestagung.de
www.startup-laser.de



FURTHER INFORMATION

PLEASE FAX THIS FORM

+49 341 48474-390

Further information about:

- ☐ LASER START UP 2012 ☐ 21st ANNUAL CONGRESS OF THE DGL e.V.
September 7–8, 2012, Leipzig, Germany

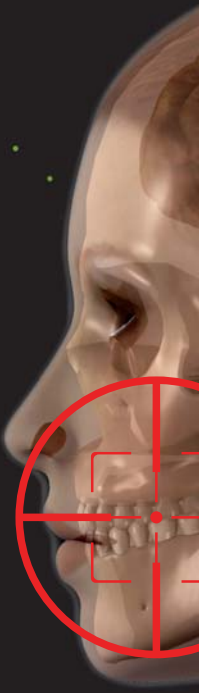NAME/E-MAIL

OFFICE STAMP

laser 1/12

Laser in oral surgery and medicine

Authors Antonio Batista-Cruzado, Daniel Torres-Lagares, Blanca Moreno-Manteca, Gerd Volland, Patricia Bargiela-Perez, Martin Jorgen & Jose-Luis Gutierrez-Perez, Spain



Introduction

The laser has been used in the field of oral surgery for a wide range of indications. In this article, we focus on its surgical uses. The success of the surgical treatment of lesions in the oral cavity depends greatly on knowledge of the aetiology and histology of the lesion. There are pathologies that can be treated with laser, such as cancer sores and hyperkeratosis. Others, like candidiasis, cannot be treated with laser. Furthermore, laser has quickly become a predictable and favourable treatment modality for leukoplakia, haemangioma and epulis.

In vitro studies

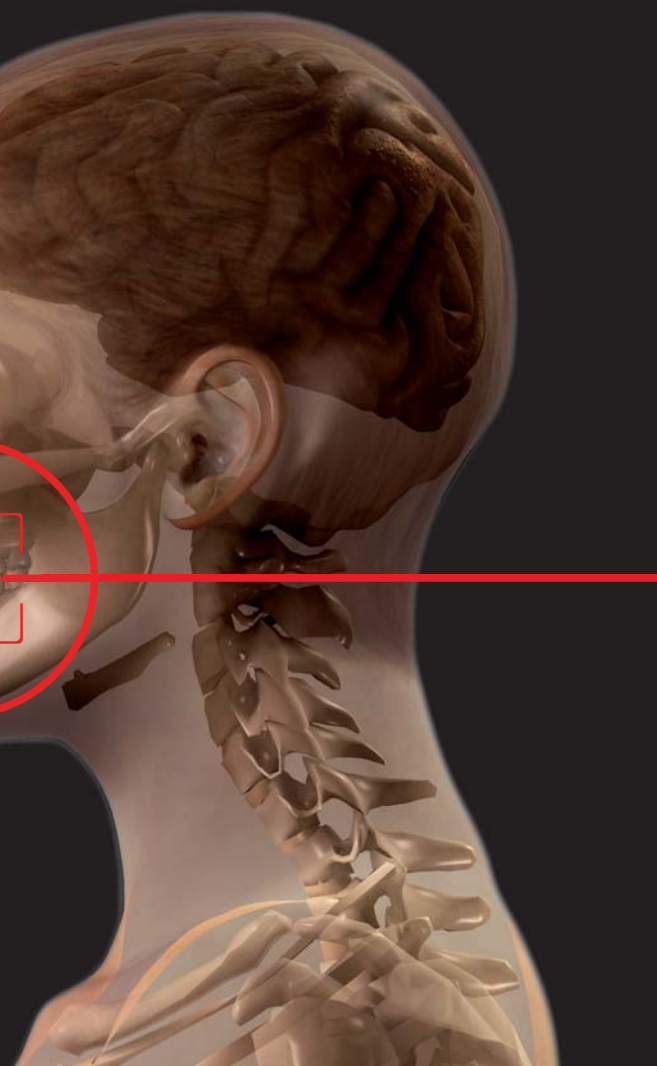There have been only few in vitro studies on the application of laser in oral surgery. For example, the study by Leco Berrocal et al.¹ explored the power of Er:YAG laser sterilisation on dental structures and dental roots in particular. Microbiological cultures indicated lower growth of bacteria after increased

energy irradiation, correlating higher energy irradiation with a greater sterilising effect of the Er:YAG laser.

In vivo studies on animals

One of the most important contributions to research in the period studied is that by Silvestri et al.² It describes the possibility of avoiding the development of a third molar via laser treatment. The use of a diode laser (20 W) in the development area of the third molar in newborn rats was able to halt the development of the tooth by 80% with only few side-effects.

Silvestri et al.² also applied this model to dogs. They employed a diode laser at either 20 W or 100 W in the formation area of the molar at the age of six to seven weeks when it begins to form. In those places where 20 W was applied, the molar continued its development, but this development was halted at 100 W. These findings indicate new



cal perspective. During the healing process, they detected similar changes in the two groups in the study overall. However, they identified TGF- β 1 as lower in the scalpel wounds on the first post-operative day than in the laser wounds. At seven days, the TGF- β 1 level was high in the scalpel group only. Therefore, they concluded that the highest tissue damage occurred in the wounds made by the diode laser, although they considered it a good cutting device for oral mucosa.

Yamasaki et al.⁶ studied coagulative necrosis in the gingiva of rats produced by irradiation with a CO₂ laser in pulsed mode and at low power. The structural characteristics of the injury and the subsequent healing process were examined in terms of histology, immunohistochemistry and

electron microscopy. The study suggested that coagulative necrosis produced by the CO₂ laser does not alter healing, but it promotes its steady progress and subsequent tissue remodelling.

A similar study was conducted by D'Arcangelo et al.,⁷ who examined the effects of scalpel versus diode laser treatment (808 nm, 4 and 6 W) with regard to the expression of eNOS and iNOS from an immunohistochemical perspective. At the histological level, the results partly agreed with the results of Jin et al.⁵ and partly with Yamasaki et al.,⁶ given that the group with the worst healing was that treated with the diode laser (6 W). The results, however, were also similar to those of the scalpel and the diode (4 W) group. Immunohistochemically, the concentrations of eNOS and iNOS were greater initially than seven days after the treatment in the laser group.

Demir et al.⁸ studied the influence of low-level laser therapy (LLLT) on the healing of the oral mucosa. They applied LLLT to wounds inflicted by scalpel and laser, noting improved clinical scarring in both of the groups when using LLLT. A histological analysis showed an improvement in epithelisation when LLLT was applied.

Finally, the study by Seoane et al.⁹ is noteworthy, in which the thermal damage and the histological types resulting from the use of laser are relevant to decision-making regarding biopsies. This study examined the wounds caused by the CO₂ laser in 25 Sprague rats, assigned randomly to five groups: four pilot groups in which glossectomies were performed using a CO₂ laser (3, 6, 9 and 12 W); and one control group treated with a scalpel. Samples were prepared, then stained and

avenues to be investigated with application to humans.

Lasers have already been used satisfactorily for the treatment of various diseases in animals. For example, Lewis et al.³ addressed stomatitis in a cat with a CO₂ laser. Kovács et al.⁴ removed proliferative inflammatory eosinophilic granulomatosis from a cat's tongue with a diode laser. This helped them to control bleeding, which had been impossible before owing to the high number of blood vessels in the area.

In vivo studies on humans

Wound healing

Several new studies have added to the body of recent research on surgical scarring owing to laser treatment. Jin et al.,⁵ for example, analysed the healing of incisions made by scalpels and diode and Er,Cr:YSGG lasers in the mucosa of guinea pigs from both a histological and immunohistochemi-

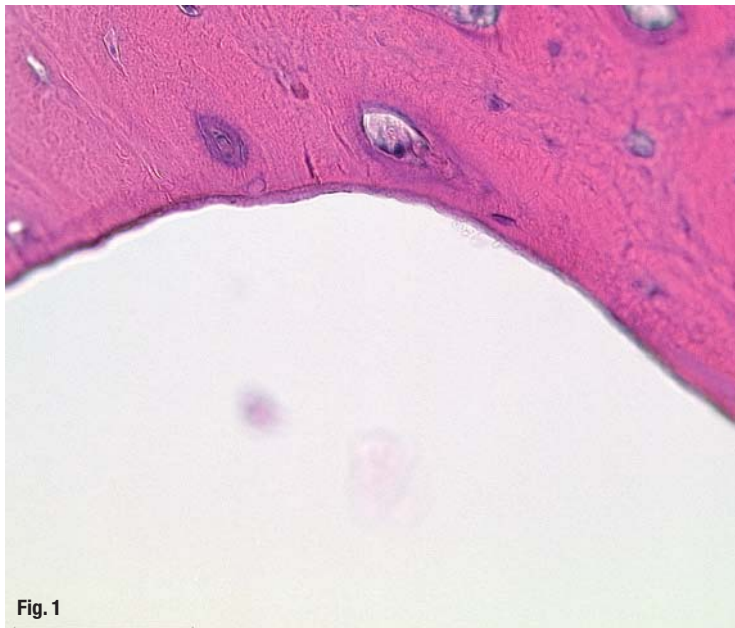

Fig. 1

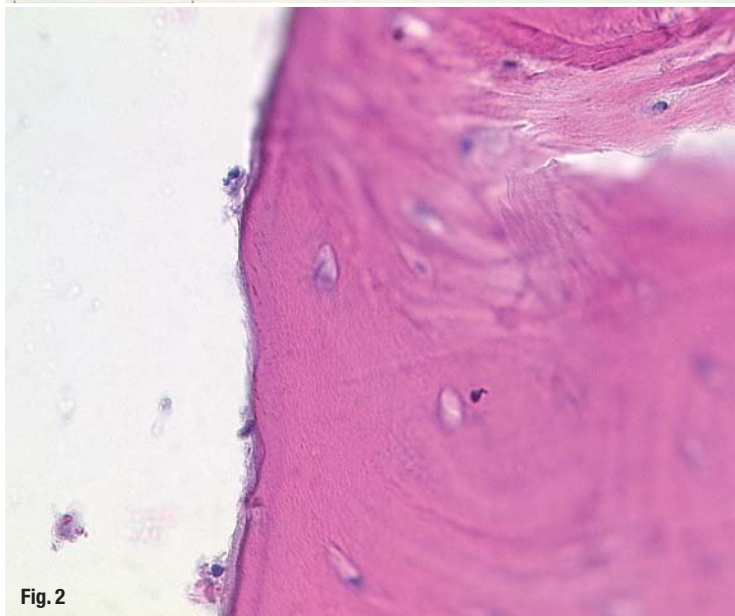


Fig. 2

Fig. 1 Histological section of the bone: very small zone of necrosis, approximately 12 µm. Er:YAG application (200 mJ, 10 Hz, 400 µs, pulse, with spray).

Fig. 2 Histological section of the bone: very small zone of necrosis, approximately 11 µm, osteoblasts are not altered. Er:YAG treatment (200 mJ, 10 Hz, 100 µs, pulse, with spray).

a double-blind study conducted on them by two pathologists. Cellular and nuclear polymorphism, nuclear aberration and the loss of intercellular adhesion were identified, especially in the basal and supra-basal layers of the oral epithelium, but no differences between the experimental groups were observed. No histological or structural changes were observed in the control group. For all these reasons, the CO₂ laser (3–12 W) should be considered to generate epithelial damage which can simulate dysplasia. This, in turn, can lead to an unsuccessful therapy.

Bone studies

There are no larger studies that provide new evidence for the results already mentioned in the previous section. Pourzarandian et al.¹⁰ confirmed that osteotomies carried out with Er:YAG laser, CO₂

laser or a surgical bur resulted in greater revitalisation of osteoblasts and fibroblasts and more pronounced revascularisation in the tissue treated with the Er:YAG laser. The study by Martins et al.¹¹ found that the healing of an osteotomy in the jaw is improved after Er:YAG laser treatment compared with wounds inflicted by a mechanical bur or CO₂ laser. For this reason, long-term studies of 60 to 90 days are needed in order to provide more evidence to support these findings. Accordingly, many studies on these issues have been published in recent years. Other studies, such as Rochkind et al.,¹² have confirmed the positive effect of LLLT on the healing of bone tissue (see histological sections, Figs. 1–3).

Clinical studies

Soft-tissue surgery

Studies on soft-tissue surgery have investigated heat damage in biopsies, the need for anaesthetic, post-operative pain, as well as intra- and post-operative complications with regard to scalpel versus laser treatment. Tuncer et al.¹³ confirmed that the CO₂ laser produces less damage in soft-tissue surgery than the scalpel. In particular, they found a 50% reduction in the need for use of anaesthetic, as well as a 60% reduction in the number of patients who needed analgesic medication post-operatively. No complications were observed for either of the two groups, and the authors suggested that thermal changes had not affected the histopathological results. The findings are in agreement with other studies published recently, for example Stübinger et al.¹⁴

The study by Matsumoto et al.¹⁵ provides further findings concerning soft-tissue surgery. It compared the emergence and importance of changes at the margins of the biopsies taken by CO₂ laser (in continuous wave and pulsed mode) and through electrocautery. Thermal changes associated with the biopsy instrument were found in all of the samples, but these changes were more significant in the electrocautery group and continuous-wave laser group. Therefore, the authors recommend the use of the CO₂ laser in pulsed mode in order to minimise changes caused by thermal effects.

Vescovi et al.¹⁶ further explored the suitability of various laser types for biopsies. They studied thermal changes that can alter the pathological diagnosis and assessed resection margins in three groups. Group I consisted of six specimens of human oral mucosa removed using an Nd:YAG laser at a power of 3.5 W and frequency of 60 Hz. Group II consisted of nine specimens removed via an Nd:YAG laser at a power of 5 W and frequency of

30 Hz. Lastly, group III consisted of 11 specimens removed using a #15c Bard-Parker scalpel blade. Their results indicated that the thermal effect of laser on biopsies introduced slight changes at the edges of the specimen. When the laser was used for incisions exceeding 7 mm and at a lower power and high frequency, these results were improved (group I, Nd:YAG—3.5 W, 60 Hz).

Kafka et al.¹⁷ explored the application of diode lasers in the treatment of soft-tissue conditions such as epulis fissuratum. These study found that this kind of laser operates optimally. Similarly, studies that evaluate the treatment of tongue lesions by diode laser, for example the study by Saleh and Saafan,¹⁸ come to the same conclusion.

Cancer treatment via CO₂ laser

Although mucoepidermoid carcinoma is painless and usually does not produce metastases or recur, it must be treated both surgically and with post-operative radiotherapy. The study by Leong et al.¹⁹ advanced the research done so far on the use of laser for the treatment of cancer. They report on the case of a patient with mucoepidermoid carcinoma at the base of the tongue. The authors applied CO₂ laser and achieved very good results.

The changes produced by laser during the surgical excision of precancerous lesions and their possible influence on accurate diagnosis have been widely discussed. Goodson and Thomson present²⁰ 169 cases of oral premalignant lesions removed via CO₂ laser and their subsequent monitoring over several years. A positive correlation was found between the results of the biopsies and those of the histological studies of the tissue removed by laser. Furthermore, hidden invasive carcinoma was identified in 15 patients and removed by laser.

In seeking to determine the recurrence of lesions removed by laser, Hamadah and Thomson²¹ followed 78 patients whose precancerous or dysplastic lesions were treated with a CO₂ laser over a period of at least two years. By the end of this period, 64% of the patients were free of the disease, 32% developed recurrent local dysplasia or dysplasia in new sites and 4% developed squamous cell carcinoma at sites different from their initial disease. The margins of the excisions were clear in 55% of the cases. However, 19% showed mild, 21% moderate and 5% severe dysplasia in the histopathological examination. The authors recommend the CO₂ laser for the excision of lesions, stating that in their study it allowed for complete histopathological evaluation and resulted in minimal post-operative morbidity and 64% of patients free of the disease.

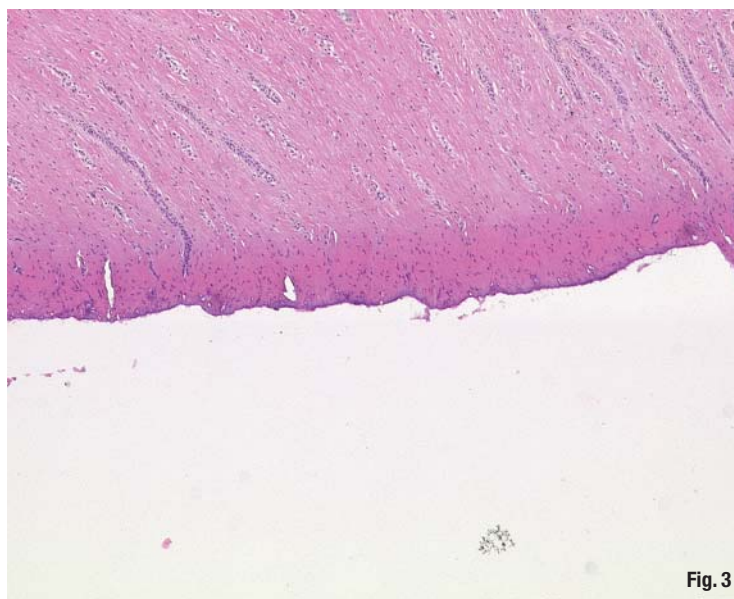


Fig. 3

Cancer treatment via photodynamic therapy

Photodynamic therapy (PDT) has demonstrated efficacy in the treatment of dysplasia and early forms of microinvasive oral cancer. Clinical studies such as the study by Mang et al.²² support this view. Mang et al.²² present a case of squamous cell carcinoma of the maxillary gingiva, which was successfully treated with PDT, sparing the patient surgery and radiation therapy.

Similarly, Schweitzer and Somers²³ evaluated the efficacy of the Photofrin-mediated PDT for the treatment of diffuse field cancerisation in 30 patients for whom conventional treatment had failed. In 80% of the patients, there was complete remission, and the remaining 20% showed partial remission. After two years, 11 of the 24 patients with complete remission were cancer free. PDT is also a form of cancer treatment suitable for the treatment of oropharyngeal tumours, either primarily or in patients whose previous surgeries or radiotherapies have failed.

Editorial note: To be continued with more treatment options and the final conclusion in the next issue of laser.

Fig. 3 Histological section of the gingiva: effect of heat accumulation at the surface, necrosis of about 45 µm. Er:YAG treatment (200 mJ, 10 Hz, 1000 µs, pulse with no spray).

_contact

laser

Prof Dr MSc mult Gerd Volland

Facultad de Odontología
Cirugía bucal
Universidad de Sevilla
C/ Avicena s/n Sevilla, Spain

dr.volland@t-online.de