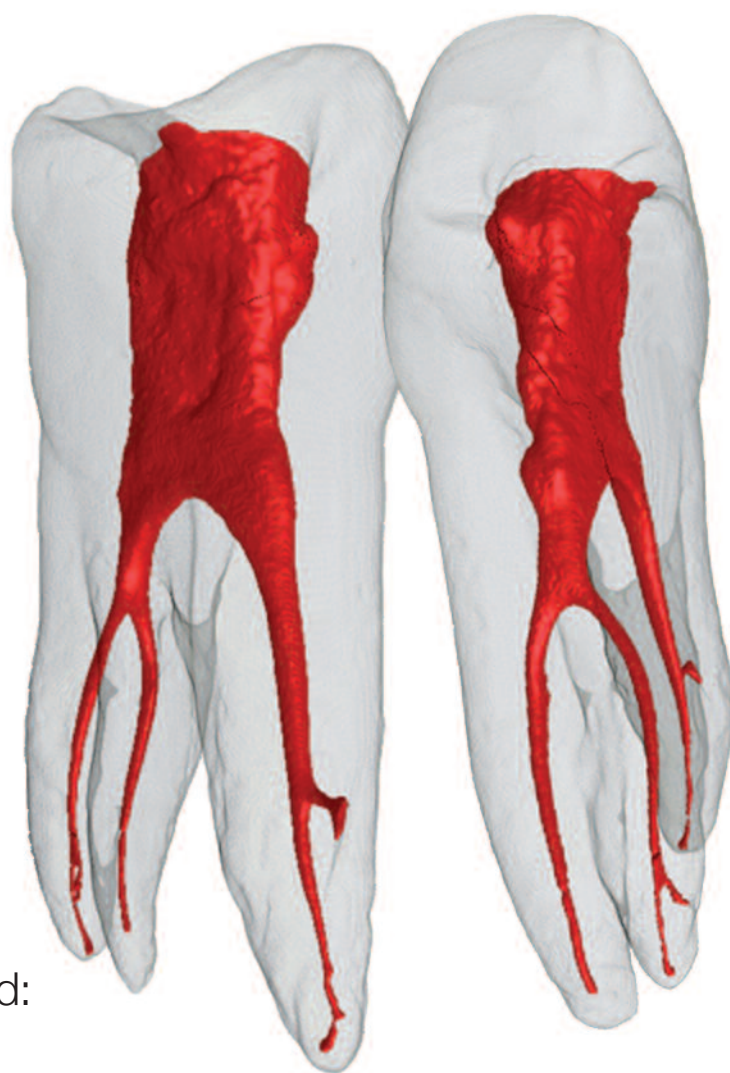

roots

international magazine of endodontology

1 2014



| **CE article**


Mineral trioxide aggregate revisited:
A cement for all seasons

| **special**

“A” sequence of irrigation

| **technique**

Fifth-generation technology in endodontics:
The shaping movement



dti | Dental Tribune International

The collage features several prominent dental industry publications:

- Dental Tribune**: The World's Dental Newspaper - Asia Pacific Edition. No. 12 Vol. 11. The cover includes a headline about "Stories of dental treatment at brains of anxious patients" and a report about sterilisation incidents.
- Dental Tribune International**: Media Kit 2014. The cover features a circular infographic and the DTI logo.
- Today's Dental Practice**: The cover includes a headline about "Waterlase - Eine Hightech-Alternative" and a section titled "People of today".
- cosmetic dentistry**: The cover features a smiling woman's face and the headline "Special cosmetic dentistry".
- DT STUDY CLUB**: The cover features a man's face and the headline "DT STUDY CLUB".
- Perfect patient**: The cover features a headline about "Perfect patient" and a section titled "The perfect patient".

The publications are displayed in various orientations, some as full covers and others as spreads, highlighting their content and design. The collage also includes a smartphone and a tablet displaying the Dental Tribune website, and a small 3D model of a dental chair.

Where we have been, where we are and where we are going?

Is “Big Brother” watching us?



Dr Gary Glassman

The future of endodontics is bright and holds incredible promise as we continue to develop new techniques and technologies that will allow us to perform endodontic treatment painlessly and predictably. For the past 100 years the objective of dentistry has always been and always should be to maintain the natural dentition wherever possible. And the objective of endodontic treatment has never wavered since root canal treatment was first performed; that being to prevent or treat apical periodontitis such that there is complete healing and an absence of infection, while the overall long-term goal is the placement of a definitive, clinically successful restoration and preservation of the tooth. With the emergence of exciting technologies, clinical endodontics is seeing higher successes never seen before.

The Dental Operating Microscope (DOM), and ultrasonics instruments have allowed us to locate canals with surgical precision while allowing maximum conservation of tooth structure. The design and metallurgy of nickel titanium files (NiTi files) with its super elastic characteristics allow better maintenance of the original canal anatomy, while the motion, rotary, reciprocation, or a combination of both produce less extrusion of debris, increased resistance to cyclic fatigue, allow greater cutting efficiency and reduced time for canal shaping compared to stainless steel files.

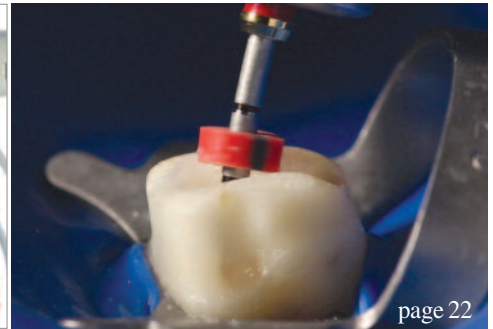
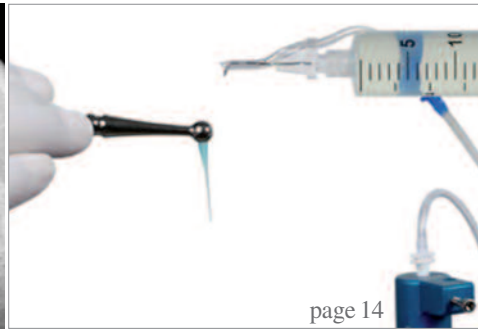
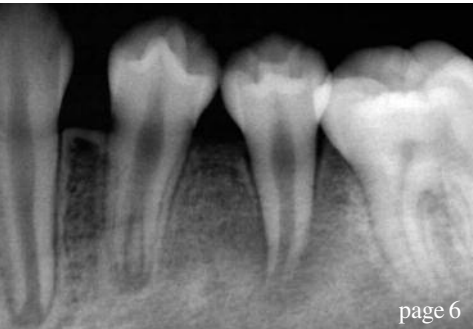
Mineral trioxide aggregate (MTA) has been and continues to be a remarkable and biocompatible restorative material that has become the standard for pulp capping and root perforation, and has salvaged countless teeth that previously had been considered hopeless.

Methods to improve disinfection in the root canal system has been the focus of perhaps the greatest international attention in endodontics. Better root canal disinfection may lead to even greater endodontic successes!

But perhaps the greatest boon to our profession and a pivotal tool in the practice of endodontics is the use of cone beam computed tomography (CBCT). Interpretation of a two-dimensional image of a three-dimensional object can make the interpretation of radiolucencies, complex dental anatomy and surrounding anatomic structures very difficult. CBCT technology, with its three dimensional rendering ability has allowed detection rates of root canal anatomy and detection of periradicular pathology to be dramatically increased. Although the detection of vertical root fractures is difficult at best with both conventional radiology and CBCT, CBCT has been shown to be an excellent supplement to conventional radiography in the diagnosis of root fractures. The differentiation between internal and external resorption; location and size, has allowed diagnosis and subsequent treatment to be more decisive and predictable. Unnecessary investigative treatment may be avoided now that three dimensional evaluation of these 'lesions' can be achieved. The same pertains to the precise nature of a perforation and the role that CBCT plays on its subsequent treatment. Post operative healing can be monitored more accurately with CBCT due to its superior resolution compared to conventional radiology and more 'informed' decisions can be made with respect to treatment planning.

Will the information that the CBCT provides force the clinician to exhaust all efforts to find all the canals and subsequently address the anatomy? Will it force the clinician to elevate their efforts to provide a better debrided canal and a more thorough obturation? Is "Big Brother" watching? I believe the answer to all of the above is YES!!

Dr Gary Glassman
Doctor of Dental Surgery
Fellow of Royal College of Dentists of Canada



| editorial

- 03 **Where we have been, where we are and where we are going?**
Is “Big Brother” watching us?
| Dr Gary Glassman

| CE article

- 06 **Mineral trioxide aggregate** revisited:
A cement for all seasons
| Dr Gary Glassman

| case report

- 10 Apexification with **mineral trioxide aggregate** (MTA):
A case report
| Dr Abu-Hussein Muhamad, Drs Abdulghani Azzaldeen &
Abu-Shilabayeh Hanali

| special

- 14 **“A” sequence** of irrigation
| Dr Philippe Sleiman
- 18 **PHAST PIPS**: The photoacoustic wave of the future?
| Dr Reid Pullen

| technique

- 22 **Fifth-generation technology** in endodontics:
The shaping movement
| Drs Clifford J. Ruddle, John D. West & Pierre Machtou

- 30 **The rationale and use of** electronic apex locators
| Dr L. Stephen Buchanan

| industry news


- 34 **Apex locator more precise** than CBCT
| VDW
- 36 **New endodontic imaging mode** from Planmeca fields
detailed images **without noise or artefacts**
| Planmeca

| events

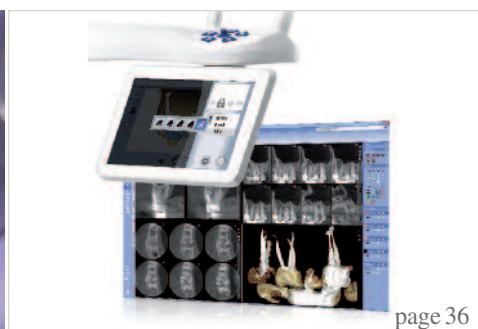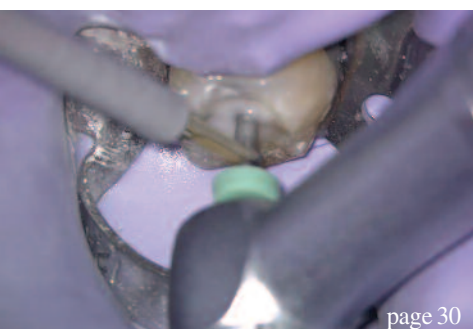- 38 **American** Association of Endodontists organised
Root Canal Awareness Week for the seventh time
| AAE
- 40 **International Events**

| about the publisher

- 41 | submission guidelines
42 | imprint



Cover image: frontal and lateral views of a 3-D reconstruction of a maxillary first premolar showing a three-rooted canal system. This micro-CT image was developed as part of the Root Canal Anatomy Project <http://rootcanalanatomy.blogspot.com> in the Laboratory of Endodontics of the University of São Paulo in Ribeirão Preto, Brazil by Prof. Marco Versiani, Prof. Jesus Pécora & Prof. Manoel Sousa-Neto



INTRODUCING



**DIGITAL
DENTISTRY
SHOW**

AT
INTERNATIONAL EXPODENTAL MILAN

16 17 18 OCTOBER 2014

EXHIBITION

LIVE PRODUCT PRESENTATIONS

HANDS-ON WORKSHOPS

PRINTED REFERENCE GUIDE

COFFEE WITH THE EXPERTS

www.DigitalDentistryShow.com

Organized by Dental Tribune International in cooperation with Promunidi.
Dental Tribune International | Holbeinstraße 29 | 04229 Leipzig | Germany
T +49 341 48474 134 | F +49 341 48474 173
E info@digitaldentistryshow.com | W www.DigitalDentistryShow.com

dti Dental
Tribune
International

PROMUNIDI

Mineral trioxide aggregate revisited: A cement for all seasons

Author_ Dr Gary Glassman, Canada

_ce credit

roots



This article qualifies for CE credit. To take the CE quiz, log on to www.dtstudyclub.com. Click on 'CE articles' and search for this edition of the magazine. If you are not registered with the site, you will be asked to do so before taking the quiz. You may also access the quiz by using the QR code.

_Pulpal and periradicular pathology develop when the dental pulp and periradicular tissues become exposed to microorganisms. In experimental, germ-free conditions, pulpal and periradicular tissues fail to show the development of pathosis and associated lesions when exposed to bacteria.^{1,2} The conclusion: microorganisms are the main irritants of the dental pulp and periodontium, and sealing the pathways of communication between the root canal system and the periradicular tissues is imperative if bacterial leakage is to be prevented.

An ideal orthograde or retrograde filling material that seals the pathways of communication between the root canal system and its surrounding tissues should be non-toxic, non-carcinogenic, biocompatible, insoluble in tissue fluids and dimensionally stable.^{3,4} Furthermore, the presence of moisture should not affect its sealing ability; it should be easy to use and be radiopaque for recognition on radiographs.⁴

Because existing restorative materials used in endodontics did not possess these "ideal" characteristics,⁴ mineral trioxide aggregate (MTA) was developed and recommended initially as a root-end filling material and subsequently has been used for pulp capping, pulpotomy, apexogenesis, apical barrier formation in teeth with open apices, repair of root perforations and, most recently, in revascularization cases. MTA has been recognized as a bioactive material.^{5,6}

MTA has been shown to seal off the pathways of communication between the root canal system and surrounding tissues, significantly reducing bacterial migration.⁷ It is made up of fine hydrophilic particles that set in the presence of water, and it is composed of tricalcium silicate, dicalcium silicate, tricalcium aluminate, tetracalcium aluminoferrite, calcium sulfate dihydrate (gypsum) and bismuth oxide, which provides it with radiopacity.⁸

Portland cement is the most common type of cement in general use around the world, used as a basic ingredient of concrete, mortar, stucco and most non-specialty grout. It usually originates from limestone. MTA is available as Gray MTA and White MTA. The crystalline structure and chemical composition of Gray and White MTA are similar, except for the presence of iron in Gray MTA. Both contain bismuth

Fig. 1_MTA Angelus (Angelus, Londrina, Brazil) available in resealable vials.

Fig. 1



oxide and calcium silicate oxide. Portland cement is composed mainly of calcium silicate oxide and does not contain bismuth oxide but does contain potassium. Calcium oxide is added in both Angelus White and Gray MTA (Angelus, Londrina, Brazil) to reduce the setting time, which is too long in MTA cements of other brands (Fig. 1).

MTA has a similar mechanism of action to calcium hydroxide⁹ in that the main component of the material, calcium oxide, when in contact with a humid environment, is converted into calcium hydroxide.¹⁰ This results in a high pH of 12.5, making its surroundings inhospitable for bacterial growth and producing an antibacterial effect for a long period of time. But unlike calcium hydroxide products, such as Dycal (DENTSPLY, USA) and MTA Angelus (Angelus, Brazil), it has very low solubility, so it maintains a hard, excellent marginal seal.

Finally, unlike most dental materials, MTA actually needs moisture to set, so it thrives in a moist environment. Of the commercially available MTA products, MTA Angelus is well suited for most of the indicated endodontic procedures due to its setting time of 10 minutes, compared with the four-hour setting time of the other commercially available MTA. It is also packaged in air-tight bottles, allowing the practitioner to use only what is exactly needed, without introducing undue moisture into the remainder and without waste.¹¹

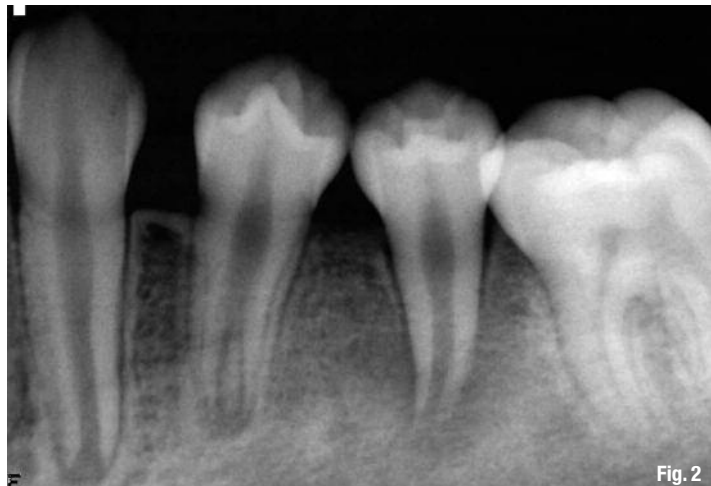


Fig. 2

Endodontic revascularization

Treatment of the immature, non-vital tooth with apical pathology presents several challenges. The mechanical cleaning and shaping of such a tooth with a blunderbuss canal is difficult, if not impossible, to achieve predictably. The thin, fragile lateral dentinal walls can fracture during mechanical filing, and the large volume of necrotic debris contained in a wide root canal is difficult to completely disinfect.¹²

A new technique is presented to revascularize immature permanent teeth with apical periodontitis. The canal is disinfected with copious irrigation and a

Fig. 2 Radiograph of a necrotic lower left second premolar with large periradicular radiolucency with an incompletely formed root, both longitudinally and laterally.

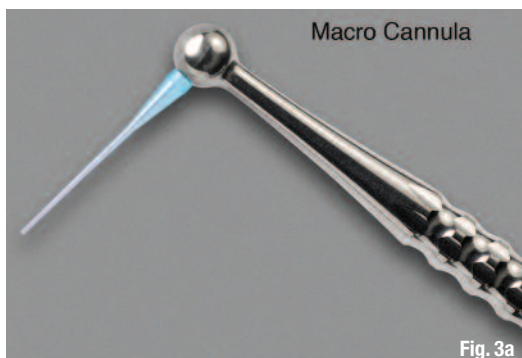

Fig. 3a

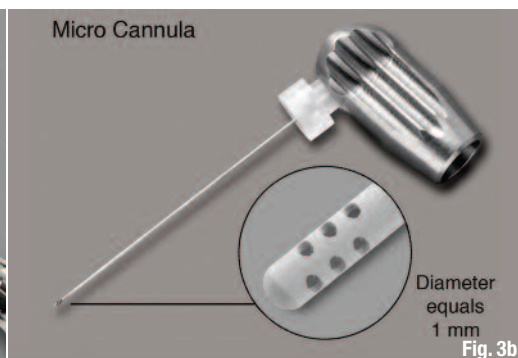


Fig. 3b

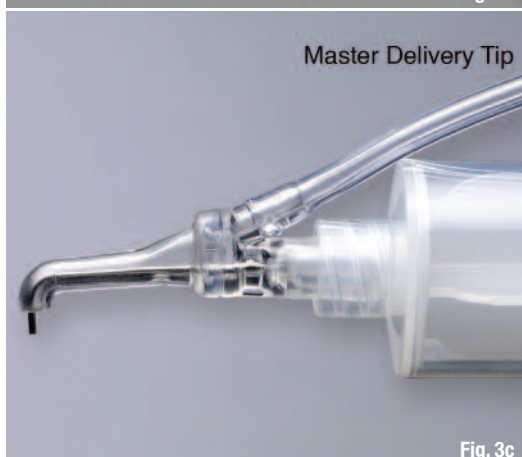

Fig. 3c

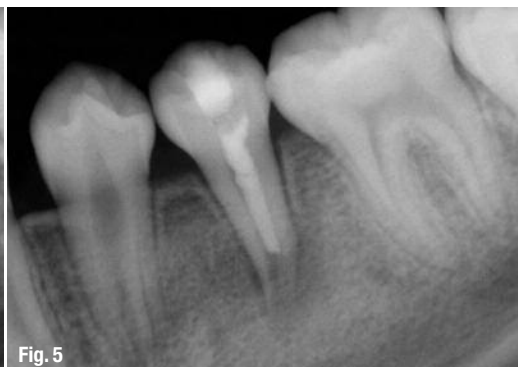
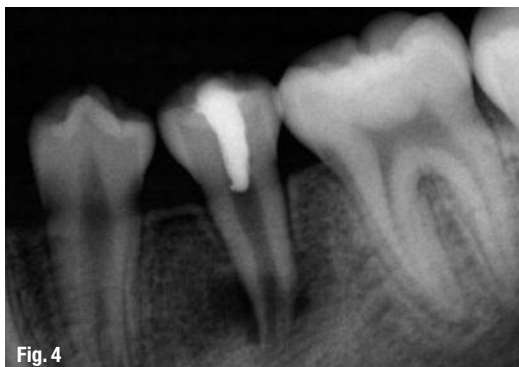
Fig. 3d

Fig. 3a-d EndoVac apical negative pressure delivery system (Axis/SybronEndo, USA).

Fig. 4 After the triple antibiotic paste was inserted into the canal, a temporary restoration was placed.

Fig. 5 Blood clot was induced and MTA Angelus (Angelus, Brazil) was placed over top and then the tooth was restored with bonded composite.



combination of three antibiotics. After the disinfection protocol is complete, the apex is mechanically irritated to initiate bleeding into the canal to produce a blood clot to the level of the cemento-enamel junction.

A double seal of the coronal access is then made, first with MTA over the blood clot and then a bonded composite. The combination of a disinfected canal, a matrix into which new tissue could grow, and an effective coronal seal appears to have the ability to produce an environment necessary for successful revascularization.¹³ The development of normal, sterile granulation tissue within the root canal is thought to aid in revascularization and stimulation of cementoblasts or the undifferentiated mesenchymal cells at the peri-apex, leading to the deposition of a calcific material at the apex as well as on the lateral dentinal walls.¹²

A case of mistaken identity

A 15-year-old girl of Asian descent was referred to the author's private endodontic clinic for evaluation on the lower left second premolar. The healthy young patient with an unremarkable medical history presented with a history of buccal swelling of the left mandibular area and discomfort to direct pressure on the tooth.

On clinical examination, the patient was asymptomatic, and the tooth appeared intact, without caries. The presence of an enamel pearl on tooth #45 suggested that one may have been present on this tooth, which was fractured during function, resulting in a microexposure and necrosis of the pulp. The tooth had an open apex associated with a large radiolucency (Fig. 2). Periodontal probings were within normal limits for all teeth in the lower left region. Diagnostic testing was negative to cold and electric pulp testing, with mild sensitivity on percussion and palpation. Because of the presence of a wider than 4 mm open apex and thin dentinal walls prone to possible future fracture,¹⁴ it was felt that an attempt to achieve regeneration of the pulp should be made by a technique similar to that described by Rule and Winter¹⁵ and Iwaya et al.¹⁶

An access cavity was made, purulent hemorrhagic drainage obtained, and the necrotic nature of the pulp confirmed. The root canal was slowly flushed with 20 ml of 5.25 per cent NaOCl for 15 minutes. It was delivered with the master delivery tip and the macro canulae of the EndoVac apical negative pressure delivery system (Axis/SybronEndo, USA) (Fig. 3). The canal was dried with paper points, and a mixture of ciprofloxacin, metronidazole and minocycline paste as described by Hoshino et al.¹⁷ was prepared into a creamy consistency and spun down the canal with a lentulo spiral instrument to a depth of 8 mm into the canal. The access cavity was closed with a sterile cotton pellet placed in the chamber and blue Cosmecore (Cosmedent, USA) (Fig. 4).

The patient returned three weeks later and was asymptomatic. The access was opened and the canal again flushed with 20 ml of 5.25 per cent NaOCl for 15 minutes. It was delivered in the same manner as in the first visit with the master delivery tip and the macro canulae of the EndoVac apical negative pressure delivery system. The canal appeared clean and dry, with no signs of inflammatory exudate. A #30 K-file was introduced into the canal until vital tissue was felt at a depth of 10 mm into the canal space. It was used to irritate the tissue gently to create some bleeding into the canal. The bleeding was stopped at a level of 5 mm below the level of the CEJ and left for 30 minutes, so that the blood would clot at that level.

After 30 minutes, the presence of the blood clot to approximately 5 mm apical of the CEJ was confirmed. White mineral trioxide aggregate, MTA Angelus was carefully placed over the blood clot and allowed to set for 20 minutes. After confirmation was achieved of its set, a bonded composite was placed and the patient was scheduled for follow-up in three months. Unfortunately, the MTA was placed further apically then would have been preferred (Fig. 5).

At the three-month follow-up appointment, the patient was totally asymptomatic, and the radiograph showed complete resolution of the radiolucency, with closure of the apex and thickening of the dentinal walls. Pulp testing was inconclusive (Fig. 6).

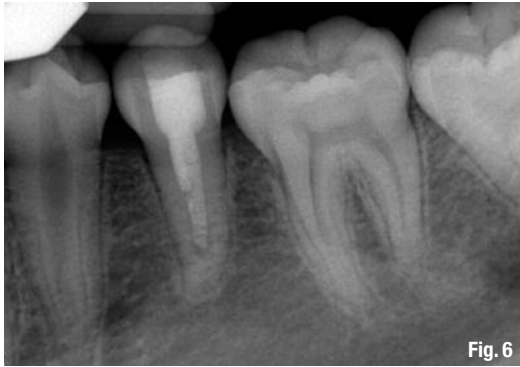

Fig. 6

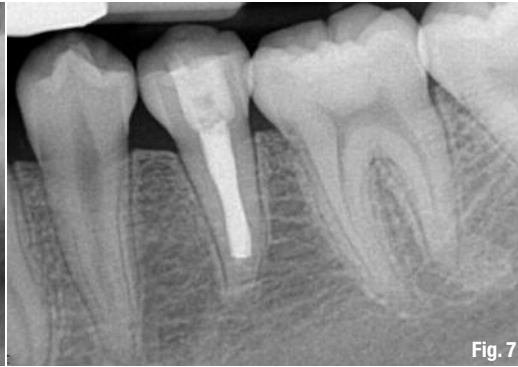

Fig. 7

Fig. 6 Three-month recall reveals excellent longitudinal apical and lateral dentin development.

Fig. 7 One-year recall radiograph reveals that definitive endodontics had been completed by the patient's new dentist.

At the one-year follow-up appointment, the radiograph revealed that treatment had been performed on this tooth by another dentist, different from her original dentist who made the initial referral. The new dentist, not familiar with revascularization treatment performed, had entered the root canal space, cleaned it out and obturated it with gutta-percha and sealer. Fortunately, the treatment was successful (Fig. 7).

Conclusion

The future of endodontics is bright as we continue to develop new techniques and technologies that will allow us to perform treatment painlessly and predictably and continue to satisfy one of the main objectives in dentistry, that being to retain the natural dentition wherever possible and wherever practical.

References

1. Kakehashi S, Stanley HR, Fitzgerald RJ. The effects of surgical exposures of dental pulps in germ-free and conventional laboratory rats. *Oral Surg Oral Med Oral Pathol* 1965; 20: 340–349.
2. Moller AJR, Fabricius L, Dahlen G, Ohman A, Heyden G. Influence of periapical tissues of indigenous oral bacterial and necrotic pulp tissue in monkeys. *Scand J Dent Res* 1981; 89: 475–484.
3. Torabinejad M, Pitt Ford TR. Root end filling materials: a review. *Endod Dent Traumatol* 1996;12:161–178.
4. Ribeiro DA. Do endodontic compounds induce genetic damage? A comprehensive review. *Oral Surg Oral Med Oral Pathol Oral Radiol Endod* 2008;105:251–256.
5. Enkel B, Dupas C, Armengol V, et al. Bioactive materials in endodontics. *Expert Rev Med Devices* 2008;5:475–494. That is hard tissue conductive (7).
6. Moretton TR, Brown CE Jr, Legan JJ, Kafrawy AH. Tissue reactions after subcutaneous and intraosseous implantation of mineral trioxide aggregate and ethoxybenzoic acid cement. *J Biomed Mater Res* 2000;52:528–533., hard tissue inductive, and biocompatible.
7. Torabinejad M, Hong OU, Pitt Ford TR. Physical properties of a new root end filling material. *J Endodon* 1995; 21: 349–353.
8. Dentsply Tulsa Dental. ProRoot™ MTA Root canal repair material; Material safety data sheet (MSDS).
9. Arnaldo Castellucci, MD, DDS. The Use of Mineral Trioxide Aggregate in Clinical and Surgical Endodontics. *Dentistry Today*, March 2003.
10. Duarte MA, Demarchi AC, Yamashita JC, Kuga MC, Fraga Sde C. pH and calcium ion release of 2 root-end filling materials. *Oral Surg Oral Med Oral Pathol Oral Radiol Endod.* 2003 Mar;95(3):345–347.
11. Boksman L, DDS, Friedman M, MTA: The New Material of Choice for Pulp Capping, *Oral Health Dental Journal* August 2011.
12. Shah N, Logani A, Bhaskar U, Aggarwal V, Efficacy of Revascularization to Induce Apexification/Apexogenesis in Infected, Nonvital, Immature Teeth: A Pilot Clinical Study *J Endo*, Volume 34, Number 8, August 2008 pp 919–924.
13. Banchs F, Trope M, Revascularization of Immature Permanent Teeth With Apical Periodontitis: New Treatment Protocol? *J Endo* Vol. 30, No. 4, April 2004 pp 196–200.
14. Cvek M. Prognosis of luxated non-vital maxillary incisors treated with Endod Dent Traumatol 1992;8:45–55.
15. Rule DC, Winter GB. Root growth and apical repair subsequent to pulpal necrosis in children. *Br Dent J* 1966;120:586–590.
16. Iwaya S, Ikawa M, Kubota M. Revascularization of an immature permanent tooth with apical periodontitis and sinus tract. *Dent Traumatol* 2001;17:185–187.
17. Hoshino E, Kurihara-Ando N, Sato I, et al. In-vitro antibacterial susceptibility of bacteria taken from infected root dentine to a mixture of ciprofloxacin, metronidazole and minocycline. *Int Endod J* 1996;29:125–130.

_about the author

roots



Gary D. Glassman, DDS, FRCD(C), graduated from the University of Toronto, Faculty of Dentistry in 1984; and graduated from the Endodontology Program at Temple University in 1987, where he received the Louis I. Grossman Study Club Award for academic and clinical proficiency in endodontics. The author of numerous publications, Glassman lectures globally on endodontics, is on staff at the University of Toronto, Faculty of Dentistry, in the graduate department of endodontics, and is adjunct professor of dentistry and director of endodontic programming for the University of Technology, Jamaica. He is a fellow of the Royal College of Dentists of Canada and the endodontic editor for *Oral Health dental journal*. He maintains a private practice, Endodontic Specialists, in Toronto, Ontario, Canada. He can be reached through his website, www.rootcanals.ca