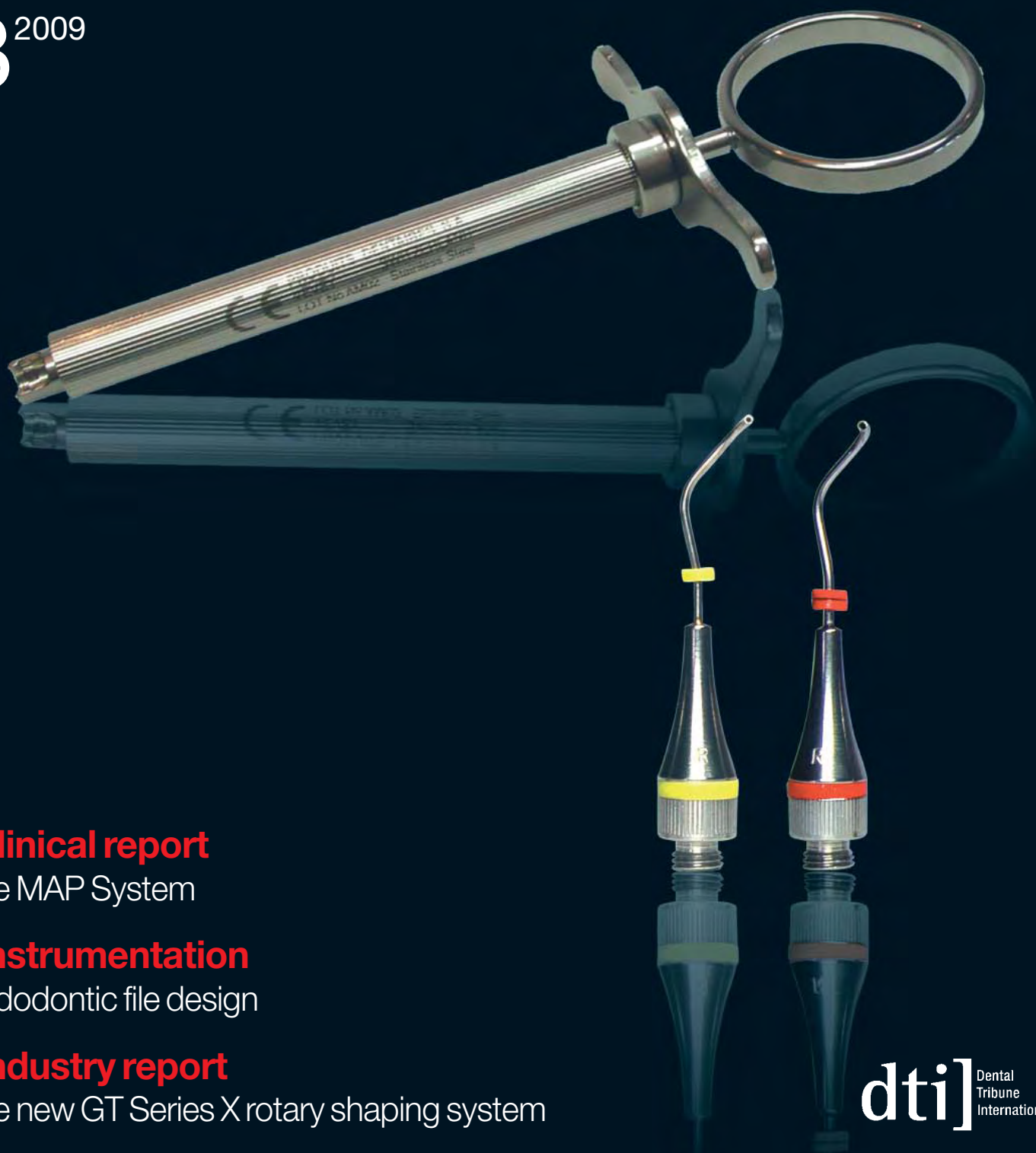

roots

international magazine of endodontology

3²⁰⁰⁹



_clinical report

The MAP System

_instrumentation

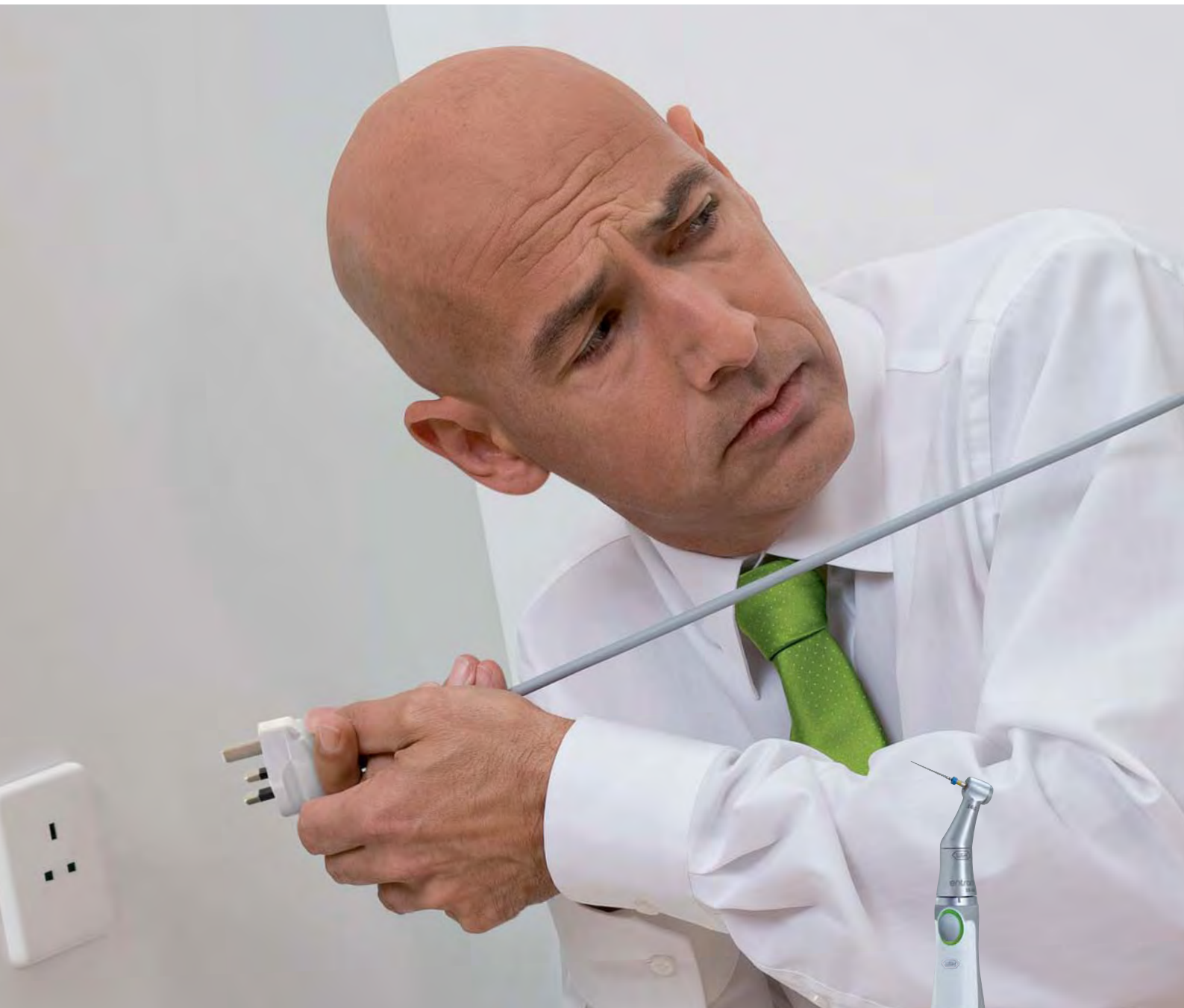Endodontic file design

_industry report

The new GT Series X rotary shaping system



Think Endo cordless!



No cord. Full power. Entran sets new standards in the area of cordless endodontics and combines the highest level of ergonomics with consistent W&H quality. For root canal preparation, there are a number of features at your disposal e.g. torque control, automatic direction change and 5 preset torque levels for NiTi files. Simple to operate, so you can concentrate on the treatment. With Entran you can enjoy complete freedom of movement inside the entire mouth - even in the most inaccessible posterior molar area.

entran

Endodontics. Cordless!

Dear Reader,



Dr Gerald N. Glickman
Guest Editor

It is a great pleasure for me to be addressing you in this publication, and as a speaker at the 14th Biennial Congress of the European Society of Endodontology. As a lifelong learner, career academician and practitioner, and current President of the American Association of Endodontists, I am committed to sharing the best of endodontics with colleagues around the world, and welcome the opportunity for dialogue with you.

There are a great many issues that deserve attention and apply to endodontic professionals in every practice setting and geographic location: access to care for patients in underserved populations, maintaining an interdisciplinary approach to treatment planning, staying abreast of the latest developments in research and technology, evaluating continuing education opportunities for reliable, timely information, and upholding the highest standards of patient care are only a few.

The American Association of Endodontists (AAE) strives to be a truly global resource of endodontic knowledge and education for the profession, our members and the public. We prioritise participation in international endodontic gatherings by our leaders, and promote those events in our publications and online. We recognise that there is thought leadership worldwide, and for this reason invite international speakers to AAE events.

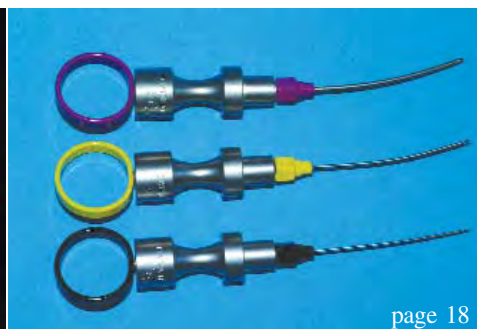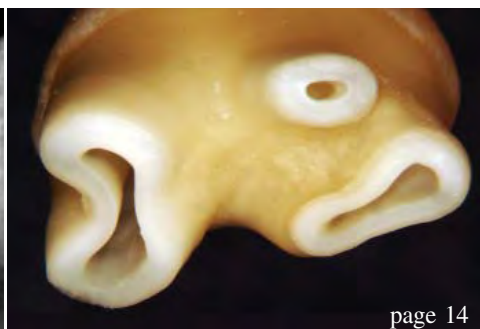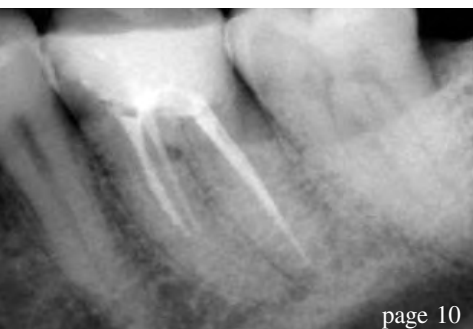A plethora of international endodontic research is submitted and reviewed for publication in our *Journal of Endodontics (JOE)*. Easier online access to quality reference material by our colleagues overseas is also being pursued, as the AAE begins to provide online-only subscriptions to the *JOE* to international endodontic organisations this year, and continues to post publications such as its *Glossary of Endodontic Terms* and *Clinical Guide to Endodontics* for free download to members on its Web site (www.aae.org). The list of similar efforts is bound to grow in the future.

I invite you to use our resources, and to share your own strengths with us. The AAE recently offered an international membership category for specialists residing outside the US. Please consider joining us in whatever capacity meets your needs. I would love to welcome you in person at our 2010 Annual Session in San Diego, California, next April!

With warm regards,

Gerald N. Glickman

Dr Gerald N. Glickman
AAE President



| editorial

- 03 **Dear Reader**
_ Dr Gerald Glickman, Guest Editor

| clinical report

- 06 **Apical microsurgery—Part II**
_ Dr John J. Stropko
- 10 **The problems with canals**
_ Dr Jonathan Murgraff
- 14 **Minimally invasive and biomimetic endodontics: The final evolution?**
_ Dr David J. Clark
- 18 **The MAP System: A perfect carrier for MTA in clinical and surgical endodontics**
_ Dr Arnaldo Castellucci & Dr Matteo Papaleoni

| instrumentation

- 24 **Endodontic file design is crucial**
_ Dr John T. McSpadden

| trends

- 28 **Advanced strategies for the removal of warm carrier based devices: The specialist approach**
_ Dr Richard Mounce

| industry report

- 34 **The new GT Series X rotary shaping system**
_ Dr L. Stephen Buchanan

| lifestyle

- 40 **A dream of ice and snow**
_ Claudia Salwiczek

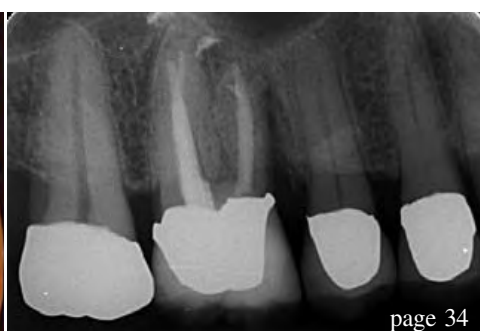
| meetings

- 44 **AAE energised endodontists in Orlando**
_ Fred Michmershuizen
- 48 **Endo events**

| about the publisher

- 49 _submissions
- 50 _imprint

Cover image courtesy of Produits Dentaires SA (www.pdsa.ch).



Ultrastreaming in the root canal



for an effective cleaning

VDW.ULTRA®

New ultrasonic device with endo-focus. Safe operation thanks to clear user guidance following endodontic indications:

- Passive, ultrasonic irrigation reaches all areas inaccessible to instrumentation
- Cavity preparation
- Retreatments
- Removal of metal posts and separated instruments



Want more information?
VDW GmbH · P.O.Box 830954 · 81709 München · Germany
info@vdw-dental.com · www.vdw-dental.com



Endo Easy Efficient®

Apical microsurgery—

Part II: Incision and atraumatic flap elevation

Author_ Dr John J. Stropko, USA

The incision is made using a disposable CK2 microsurgical blade (SybronEndo). With the smaller size of this blade, accurate incisions can be made that have a cleaner cut than those of the much larger BP #15 or BP #15S blades. As the incision is being made, the operator needs to visualise the suturing process. Sometimes just a small variation in the design of the incision can make a significant difference to easier and less traumatic closure of the surgical flap. In general, the operator is working with relatively healthy tissue and no attempt should be made to re-

move or alter the periodontium. This is especially applicable when making a full sulcular flap.

All flaps are full thickness and the incision must be complete, so that there is no inadvertent tearing upon retraction of the flap. The split thickness flap is to be avoided as it is the most traumatic and healing is compromised. The periosteum does not survive the flap reflection procedure. It has been postulated that depolymerised periosteal collagen plays a role in rapid reattachment of the flapped tissues to cortical bone.¹

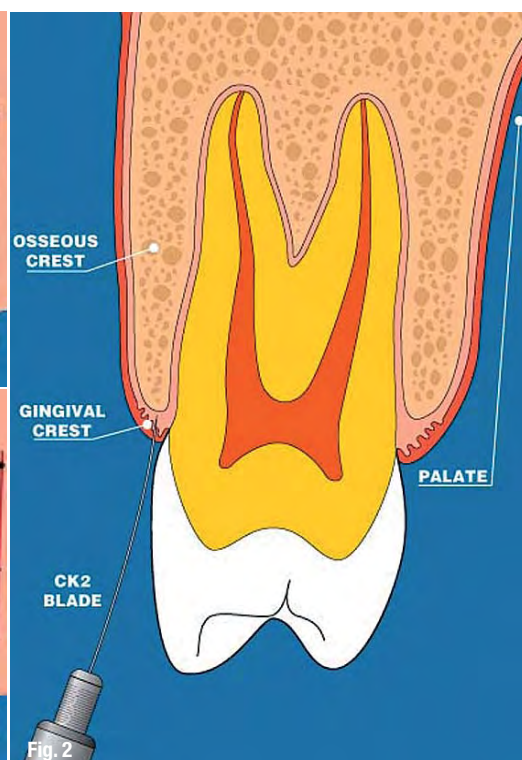
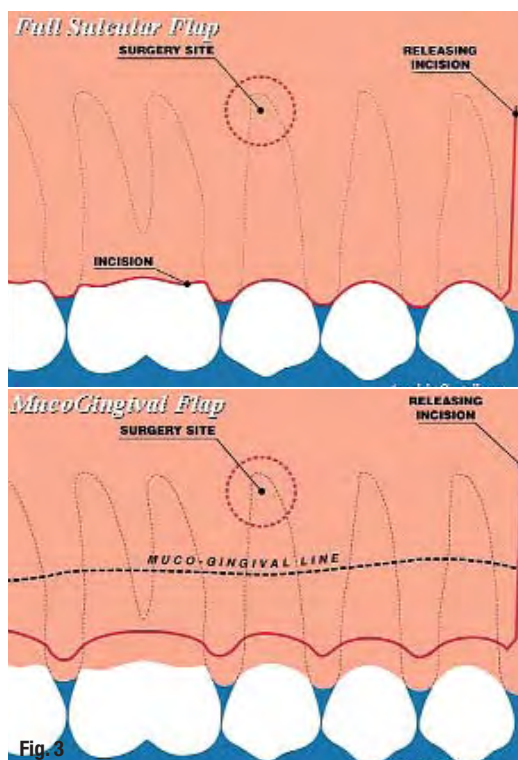


Fig. 1_ Diagram showing the most often used full sulcular incision.

(Image courtesy of Dr Arnaldo Castellucci)

Fig. 2_ Ideally, the incision should be made to the osseous crest to preserve the healthy periodontal attachment.

Fig. 3_ The Leubke-Ochsenbein Flap, or muco-gingival flap, is used when aesthetics are a concern and there is an adequate zone of attached gingiva.

(Image courtesy of Dr Arnaldo Castellucci)

In general, all flaps should be extended, at a minimum, to the mesial of the second tooth anterior to the apex of the root being surgerised. The flap design differs depending on the integrity of the bone over the roots, the amount and nature of the attached gingival tissue, the anatomy of the jaw, and the absence or presence of fixed dental appliances. There are two flap designs: triangular (one releasing incision) and rectangular (two releasing incisions). They are normally either a full sulcular flap or a muco-gingival flap, depending on the location and situation presenting itself to the operator. In general, the longer the length of the flap, the easier it is to control and has no effect on the healing process.

_The full sulcular flap

This design is routinely used in all posterior quadrants. The full sulcular flap should be used in the anterior if there is thin zone of attached gingival tissue, or there is a concern about the possibility of a dehiscence over the root of the tooth being operated on. The incision is made through the gingival crest, following the curvature around the cervical of the teeth involved in the surgical area (Fig. 1). The operator should attempt to incise the tissue through the gingival crest to the osseous crest of bone, leaving the healthy gingival attachment intact (Fig. 2). The advantage of the full sulcular flap is the ability of the operator to visualise the emergence form of the involved teeth easily.

_The Leubke-Ochsenbein or muco-gingival flap

This flap is used only when there is an adequate amount of attached gingival tissue present and the periodontal probing is within normal limits. The incision design should be scalloping in nature and generally follow the architecture of the teeth, which allows for easy repositioning upon completion of the apical microsurgical procedures (Fig. 3).

All releasing incisions are made parallel to the long axis of the teeth. This is important because the blood supply to the area is also parallel to the long axis. If a wide-base flap is made, the blood supply to the tissue adjacent to the flap will be compromised and healing may not be as predictable or uneventful.

The reflection of the flap is accomplished using the Molt, Ruddle R, or Ruddle L (SybronEndo) periosteal elevators. The working end of the instrument is gently inserted into the releasing incision, line into the free gingival tissue apical to the muco-gingival attachment and as far apically as the incision and bony contours will gently permit (Fig. 4). The instrument is manipulated in a gentle up-and-down (apical-to-

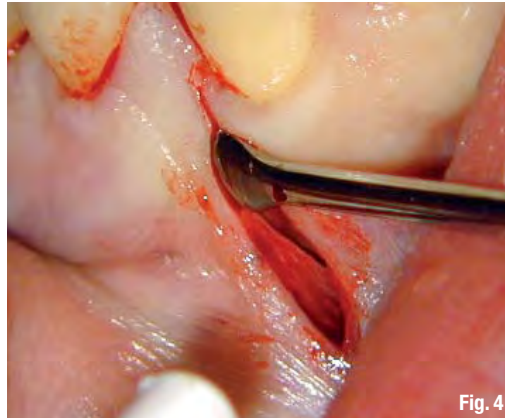

Fig. 4 The Molt, or Ruddle elevator, is inserted into the unattached gingival portion of vertical releasing incision.

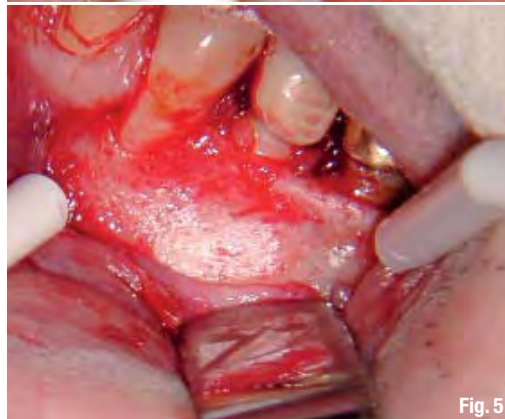


Fig. 5 Tissue impingement by the retractor is the leading cause of post-operative discomfort.

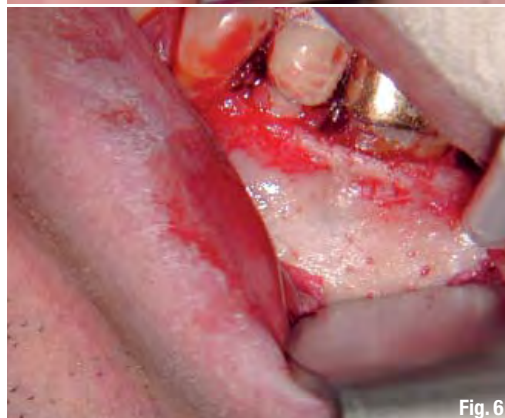

Fig. 6 The retractor is placed into a prepared groove on the cortical plate stability to prevent tissue impingement.

coronal) movement within the unattached gingival portion of the flap. Maintaining the same motion, the instrument is moved slowly towards the same apical position at the more distal extent of the flap. The working end of the elevator should be sharp so that the reflection will be a dissecting process, thus crushing or tearing of the tissue is avoided.

Occasionally, especially in the posterior quadrants of the mandible, the muco-gingival line will actually be firmly attached to a microscopic bony ridge. The attached tissue must be gently dissected from it. Once the mesial few millimetres are loosened, the rest will generally peel away without much effort at all and will gently release from the osseous surface. The time spent initially to gently free the attached gingiva will be rewarded by a healing process that is more likely to uneventful.

This atraumatic elevation and reflection of the flap is a major contributor to the rapid healing response routinely observed only 24 hours post-operatively. It is important that the approximating surfaces of the flap are not touched after the incision is completed, so that there are no crushing injuries to inhibit or retard the healing process. An instrument such as the old wax spatula-shaped periosteal elevator has no place in the armamentarium of the endodontic microsurgeon.

Once the flap is gently and cleanly reflected, any tissue tags should be left intact as they will aid in the healing process. It is not necessary to clean the flap and exposed bone, as these efforts are time-consuming, can be traumatic to both the hard and soft tissue, and ultimately compromise the healing process.

The retraction of the flap must also be accomplished in a gentle and atraumatic manner. The most common cause of post-operative pain and swelling arises from impingement of the tissue during the retraction process (Fig. 5). The operator has to monitor the end of the retractor constantly to ensure there is no inadvertent impingement on the flap. This is when the 'scope' assistant is most helpful because they are observing the surgical site with a different set of eyes!

An effective way to achieve atraumatic retraction is to prepare a groove in the cortical plate of the bone, well apical to the anticipated access to the root end. A surgical length #8 round bur, on a high speed Innovator handpiece (SybronEndo), is used to make the groove. A high-speed handpiece that has air escaping from the working end should never be used because of the danger of air embolism.

The groove creates a definite place for the retractor instrument to seat into, which can then be easily maintained in position, by either the doctor or the assistant, thereby eliminating the problem of inadvertently slipping during the surgery. Impingement of the tissue is also more predictably avoided by using a groove to hold the retractor.

Retraction can be accomplished using either the Carr or Rubinstein Retractors. However, there are many different styles of retractors from which to choose. The specific retractor chosen is the one that will best maintain clear visibility to the surgical area and be comfortable for the operator to hold during the surgical procedure (Fig. 6).

After the flap is retracted and if there is any tension on the flap, the vertical releasing incision can be extended, or an additional releasing incision at the opposite side of the flap can be considered. The releasing incision is usually minimal, only 3 to 4 mm long, and often does not require suturing. In any case, it is imperative that the operator keeps in mind there should be no tension or stretching of the tissues. One should not hesitate to extend or modify the incision, to eliminate tension on the tissues during retraction. When there is tension, there is usually an opportunity for crushing or ischaemia of the tissue and a resultant delay in the healing process. Generally speaking, the larger the flap, the easier it is to maintain atraumatically during the surgical procedure.

_Reference

1. Harrison JW, Jurosky KA. Wound healing in the tissue of the periodontium following periradicular surgery. II. The dissectional wound. *J Endod* 1991; 17 (11): 544-552.

_author info

roots



Dr John J. Stropko received his DDS from Indiana University in 1964 and for 24 years practised restorative dentistry. In 1989, he received a certificate for endodontics from Boston University. He recently retired from the private practice of endodontics in Scottsdale in Arizona. Dr Stropko is an internationally recognised authority on micro-endodontics. He has been a visiting clinical instructor at the Pacific Endodontic Research Foundation (PERF), an Adjunct Assistant Professor at Boston University and an Assistant Professor of graduate Clinical Endodontics at Loma Linda University. His research on in vivo root canal morphology has been published in the *Journal of Endodontics*. He is the inventor of the Stropko Irrigator, has published in several journals and textbooks, and is an internationally known speaker. Dr Stropko has performed numerous live micro-endodontic and microsurgical demonstrations. He is the co-founder of

Clinical Endodontic Seminars and is currently an instructor of Microsurgery in the Endodontic Faculty at the Scottsdale Center for Dentistry. He can be contacted at topeno@aol.com.

Diagnostic
Information
Treatment
Care
Healing



Design meets precision

There is hardly another dental equipment manufacturer who demonstrates such a passion for perfection as the Japanese family-owned company Morita. Our work reflects the highest standards in terms of quality, reliability, precision and customer satisfaction.

One example: the high-performance Apex Locator Root ZX mini. Root ZX mini uses the ratio technique of the Root ZX, the winner of many awards, to provide the highest measurement accuracy. Its function and precision are not affected by temperature fluctuations or moisture in the canal. Hardly larger than a smartphone, the Root ZX mini is compact and light, ideally suited for the hand or patient's chest if you like. There is space for this elegant high quality device wherever your treatment requires it. The coloured display is easy to read, the automatic calibration and the automatic zero balance make its use both comfortable and safe.

Talk to your dental equipment specialist retailer about the Root ZX mini, or call us directly: +49 (60 74) 8 36-0!

www.jmoritaeurope.com