

roots

international magazine of endodontology

4²⁰⁰⁹

| **clinical report**

The X-Files: four case reports

| **research**

Determining working length

| **industry report**

The DownPak Device

Hygiene Made Simple.

VDW'S STERILE
ENDODONTIC INSTRUMENTS
ARE IN STRICT CONFORMITY WITH
DIN EN ISO 11137 - STERILISATION
OF HEALTH CARE PRODUCTS



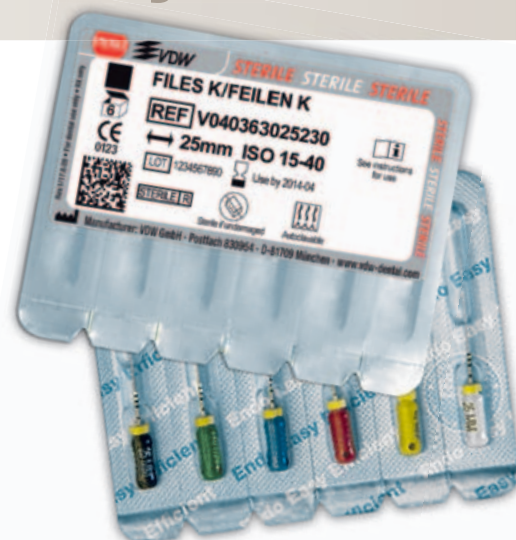Sterile Endo Instruments by VDW.

Enhanced safety for you and your patients

- No sterilisation prior to first use
- Ready to use instruments, individually packed
- Sterile product range: stainless steel instruments, NiTi files (Mtwo®, FlexMaster®), paper points
- TÜV-certified quality management

Please contact us for more information:

VDW GmbH
P.O. Box 830954 • 81709 München • Germany
Tel. +49 89 62734-0 • Fax +49 89 62734-304
www.vdw-dental.com • info@vdw-dental.com



Look for the red dot.

VDW. Over 30 years' experience in sterile products.



Endo Easy Efficient®

Dear Reader,

I am very pleased to be able to address colleagues from nearly all fields of dentistry in the editorial for this issue of **roots**, which will be distributed at the 2009 Greater New York Dental Meeting.

Endodontic therapy is often the last opportunity to preserve a natural tooth. If a tooth has a sufficient restorative and periodontal prognosis and the necessary endodontic treatment is done properly, the longevity of patients' teeth can be extended to decades. There is ongoing debate comparing endodontics and implants as therapy alternatives. Yet, there seems to be a tendency towards the replacement of natural teeth with implants, sometimes even in cases in which the tooth could have been preserved.

Research figures show that there is a significant difference between the high success rates of endodontic treatment in controlled studies and the incidence of apical periodontitis after endodontic treatment, as demonstrated in cross-sectional studies. This may be an indication of the difference of what is possible with treatment following a controlled protocol and what is achieved in reality, thereby explaining the endodontic treatment results we often see in our patients.

Controlled studies in implantology have mostly presented data indicating implant survival and not implant success, as demanded by Dale, Albrektsson and others. Even early implant loss, within the first weeks of placement, is often not included in many statistical calculations. In the last two years, reports have indicated instances of peri-implantitis at a rate of 10 per cent and in some implant types of up to 29 per cent. Some studies have shown higher incidences of peri-implantitis in patients that have lost teeth because of periodontitis before and therefore suggest a possible predisposition. Additionally, we are only beginning to understand the treatment of peri-implantitis.

In my opinion, implants are a very valuable instrument if the natural tooth has already been lost or has an insufficient prognosis. But if a tooth has a sufficient restorative, periodontal and endodontic prognosis, it should be preserved in most cases. Thus, I consider that the situation is not one of endodontics versus implants but one of two disciplines working alongside in the goal of best serving our patients.

So, I hope that you will enjoy this issue of **roots**, which demonstrates the possibilities of endodontic treatment through cases treated by excellent clinicians.

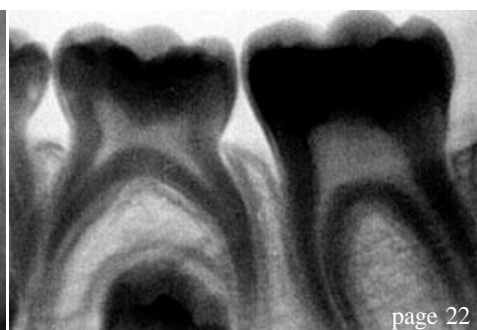
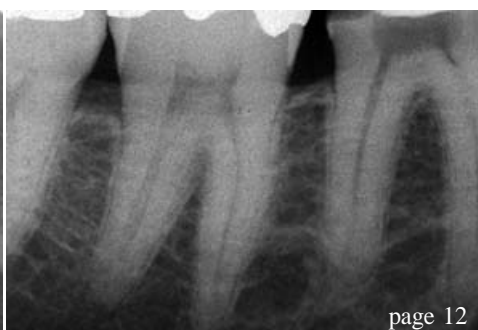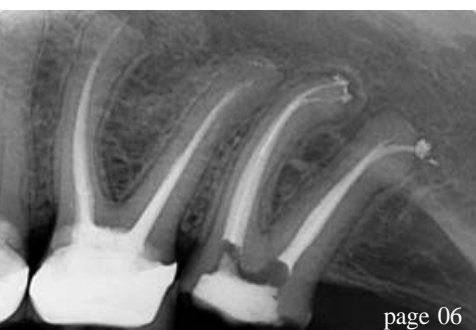
Sincerely yours,



Dr Carsten Appel
Guest Editor
President of the German Society of Endodontology
Niederkassel, Germany



Dr Carsten Appel
Guest Editor



| editorial

- 03 **Dear Reader**
| Dr Carsten Appel, Guest Editor

| clinical report

- 06 **The X-Files: four case reports**
| Dr L. Stephen Buchanan
- 12 **Endodontically speaking, the proof is in the pudding**
| Dr Barry Musikant
- 18 **Apical microsurgery—Part III**
| Dr John J. Stropko
- 22 **The future of endodontics: pulp revascularisation**
| Dr Philippe Sleiman

| trends

- 24 **Practical clinical considerations in endodontic re-treatment**
| Dr Richard E. Mounce & Dr Gary D. Glassman

| research

- 30 **Determining working length, or how to locate the apical terminus**
| Prof Vladimir Ivanovic & Dr Katarina Beljic-Ivanovic

| industry report

- 38 **The DownPak Device: obturation with heat and vibration**
| Dr Stephen Cohen et al.

| lifestyle

- 42 **Enjoy your trip and indulge in the journey!**
| Annemarie Fischer

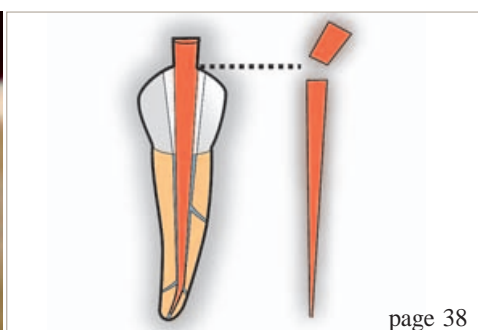
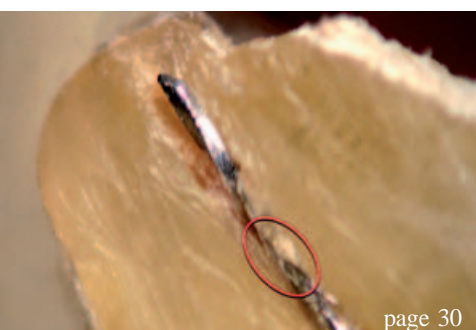| meetings

- 46 **ESE holds another record meeting in Scotland**
| Daniel Zimmermann
- 48 **Endo events**

| about the publisher

- 49 | submissions
- 50 | imprint

Cover image courtesy of alphaspirt.




TOOLS TO KEEP SMILING

No less than ...
...4 launches !

D-RaCe

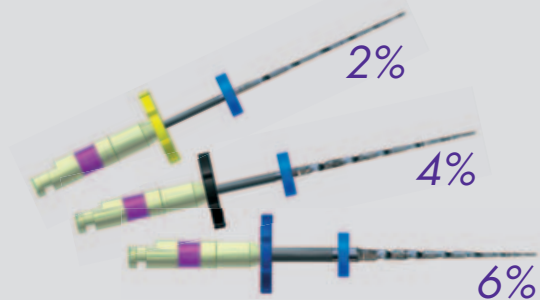
Desobturation made easy



www.d-race.ch

FKG RaCe ISO 10

Mechanical Glide Path




Spreader 4%

NiTi & Electro-chemical polishing



SMG handle

Indicator of uses



For K/H files and reamers

www.fkg.ch

FKG
FKG DENTAIRE
Swiss Dental Products



The X-Files: four case reports

Author_Dr L. Stephen Buchanan, USA

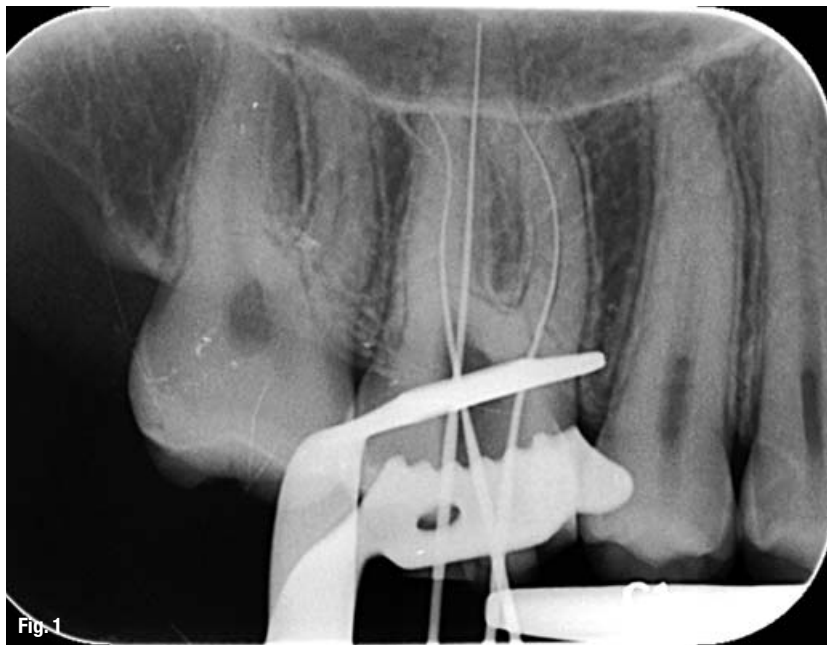


Fig. 1 Maxillary molar with files in each root to lengths determined by Root ZX (J. Morita); note the curvatures in the MB and DB canals, as well as the lengths in the palatal and DB canals that are short of the radiographic root apices but at the termini of those canals.

In his book *Innovation and Entrepreneurship*, business guru Peter Drucker stated that a new technology is not widely taken up by users unless it provides a 10x improvement over their current methods of work. This is certainly true in dentistry. Incorporating a new concept, technique, or instrument into a fully scheduled day is a huge stressor. It also entails significant training costs for the dentist and staff, as well as high costs for the new inventory needed. Because of this, the most financially successful dentists watch carefully for the point in time at which the benefits of the new technology outstrip the costs of taking it on. Only early adopters, who are driven by wanting to be on the cutting edge of technology, will jump in sooner.

When the 10x factor of improved results becomes a reality, clinicians who recognise these advantages can accomplish the treatment in less time, with fewer steps and greater confidence in

the outcome. The new GTX Rotary File with M-Wire metallurgy satisfies these requirements. This new file has the attributes of much greater resistance to cyclic fatigue failure—the major cause of instrument separation. In addition, fewer files and procedural steps are needed to create ideal shapes in root canals. As an improvement to the GT File series, the GTX Files have landed cutting blades for prevention of transportation, although the radial lands have been optimised. This has been accomplished by varying the land widths along the file length to increase cutting efficiency without losing their resistance to straightening curved canal paths. Furthermore, the blade angles have been opened up (fewer twists), which not only increases cutting speeds, but also increases their flexibilities and the size of their chip spaces between the flutes.

All of these changes in efficiency were accomplished without forsaking one of the unique features of the GT File series: the 1 mm maximum flute diameter (MFD) limitation, which prevents over-enlargement of the coronal region of the root canal. This is a key factor in reducing the loss of structural integrity of the tooth after endodontic treatment. So, with the pre-existing safety features of landed cutting blades and limited MFDs, and the newly enhanced safety of R-Phase NiTi metallurgy, the only thing that could be better would be to reduce the number of files and procedural steps needed to accomplish shaping procedures in canals.

This article is intended to describe how these files are able to cut the shapes that are needed in most root canals, using one or two instruments with four to five procedural steps. I will detail the shaping procedures used in molars with moderate-to-severe canal curvatures by me and two of my esteemed endodontic colleagues.

Case 1: Maxillary molar treatment

This case was treated as a live demonstration at the California Dental Association meeting in Anaheim in USA on 3 May 2008. Figure 1 is a radiograph showing the final negotiating files in each canal. I do not consider this a means of length determination because they are not as accurate as my J. Morita apex locator for this purpose. This image was taken to demonstrate for my audience the curvatures of the different canals in this tooth. The mesio-buccal (MB) and disto-buccal (DB) canals have obvious, significant curvatures. The palatal canal appears to be straight in this X-ray angle but could be curved in the buccal or lingual planes, a possibility that will be discovered during the shaping of the canal. This image shows the negotiating prerequisite to shaping with GTX Files: a #15 K-file (or larger) to the terminus of all canals.

The shaping objective for GTX File use has been changed (streamlined) from that suggested for GT File shaping. Notably, the small-canal shaping objective is now limited to a .06 shape and the shaping objective for medium-large canals is typically limited to a .08 shape. This is with the understanding that some medium and large canals may occasionally need a .10 or even a .12 shape, if their apical canal form is large. So, the MB and DB canals will be shaped to a .06 taper and the palatal canal to a .08 taper, with the final apical diameters to be determined by apical gauging procedures followed after the initial shape has been cut.

This tooth had two MB canals that were apically confluent. GTX File shaping is achieved in the presence of 6 % NaOCl, and the shaping routine in small canals is always begun with the 20/.06 GTX File used at 300 rpm with a torque limit of around 250 gm/cm. The 20/.06 GTX File is spun up and introduced into the canal with a light but steady apical movement. This is where the biggest difference between GT File and GTX File function becomes apparent. The GT Files (with their smaller chip space) typically cut for about four to six seconds before stalling in their apical progress, owing to the cut debris filling the chip spaces; whereas the GTX Files (having twice the chip space) will cut for ten to twelve seconds before stalling. I usually let the file continue its apical progress without any interruption. However, many of my colleagues cut with the file for three to four seconds, withdraw by 0.5 mm, and then continue further apical progress until the file stalls.

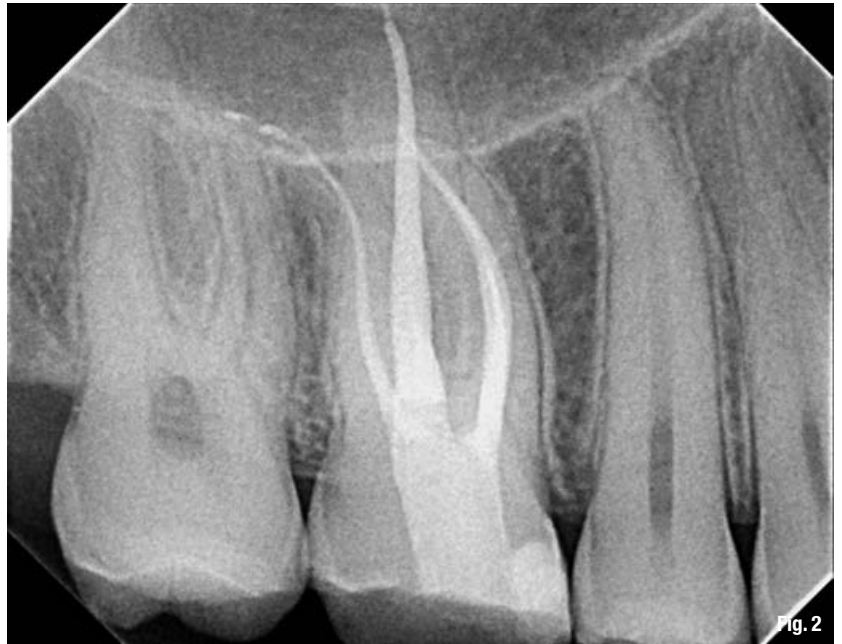

Fig. 2 Post-op radiograph showing conservative coronal shapes, apically accurate fills, and an ideally cut access cavity with the mesial and distal access walls parallel to the mesial surface of the tooth.

The main issue is that landed blade files do not cut effectively when used with an in-and-out pecking motion; they require the blades to be set against the canal walls for cutting to occur. While this is sometimes perceived as a less effective cutting event than the bite of non-landed blades, the time to completion of shape belies that perception. Obviously, when the GTX File finally stalls, it is retrieved, the blades are cleaned with alcohol gauze, and then the file is re-introduced for further cutting. When the same GTX File starts to stall again, it is time to drop down in size to a 20/.04 GTX File so that initial shaping in small canals can continue safely. In this case, the 20/.06 GTX File cut all the way to length in the MB1 and MB2 canals in two or three cutting cycles, but in the DB canal a 20/.04 GTX File was needed to achieve length. This is typical in maxillary molars.

One of the new technique strategies taught for GTX File use is visual gauging at the end of initial shaping, looking at the first 20 Series GTX File that cuts to length to determine whether there is dentine debris in the tip flutes. When the first GTX File to length has debris packing the last flute space, there is a good chance that the terminus is no larger than the tip diameter of that file. When that file is devoid of chips at its tip, it is most likely that the terminal diameter of the canal is larger.

This is a time saver, as it eliminates the need to introduce NiTi K-files (tactile gauging) to determine whether a larger apical size will be needed to create apical continuity of taper—confirmation that the taper in the preparation extends all the way to the apical terminus.

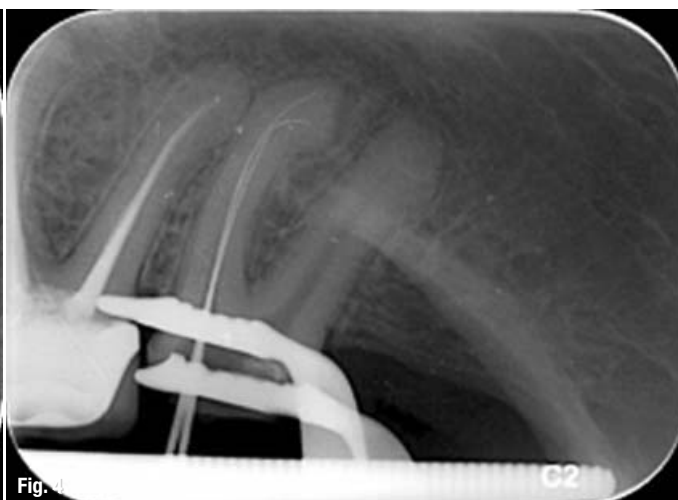
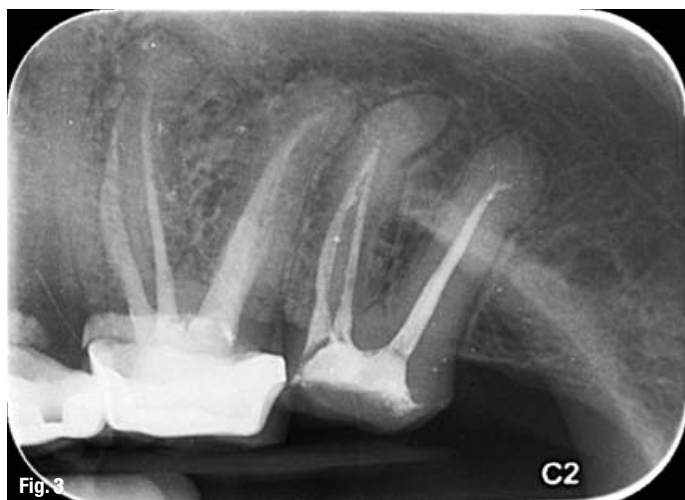

Fig. 3_ Mandibular molar with failing endodontic therapy due to apically inadequate treatment in all canals.

Fig. 4_ Negotiation files in mesial canals after removal of filling material and advancement through apical blockage; note the severe curvatures.

Fig. 5_ Post-op radiograph showing apical confluence of mesial canal shapes and the second apical portal of exit branching off the point of confluence; note the apical ledge at the curvature in the distal canal, bypassed with bent stainless-steel K-files and finished with a pre-bent GTX Rotary File.

Apical continuity of the taper is what gives us the greatest chance of having apical accuracy when we fill the canal, so this is a critical element of the GT and GTX File technique. Visual gauging allows a quick decision to be made on the likely final shape, and in this clinical case the 20/.06 GTX File had no tip debris after reaching the terminus of the MB1 and MB2 canals, indicating that a 30/.06 GTX File should then be used. In the DB canal, the first file to length (the 20/.04 size) showed tip flutes packed with debris, indicating that a 20 Series GTX File would probably suffice to complete the shape in that canal. And in fact, when the 20/.06 file was cut to length and tactile gauging was achieved, this proved to be the case.

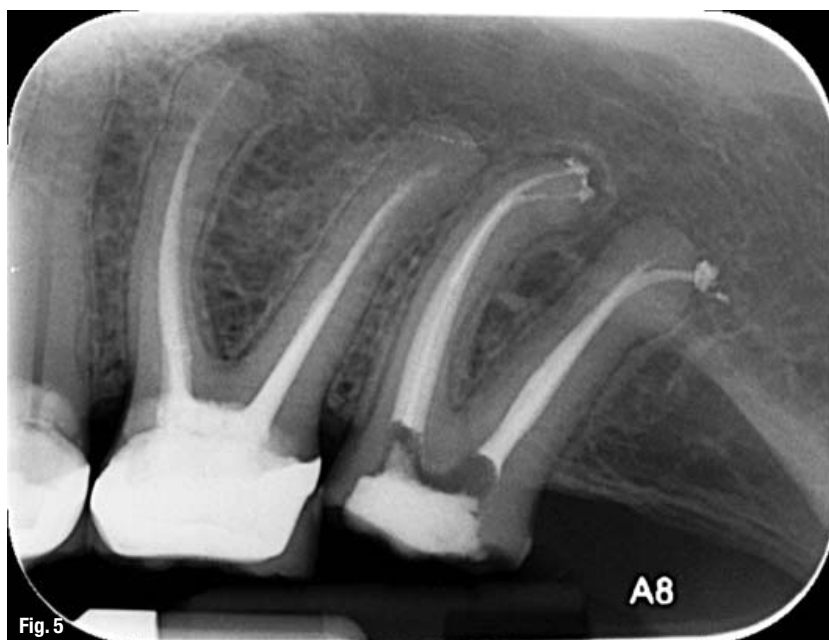
This technique shows the clinician which tip size of a .02 tapered K-file binds at length, indirectly revealing the apical diameter of the

canal. Tactile gauging is achieved with NiTi K-files to increase the accuracy of the test because the more rigid stainless-steel K-files can cause misreadings of apical diameters. Tactile gauging is achieved in the presence of 17 % aqueous EDTA, so that the smear layer is removed at the same time that shaping is completed (in visual gauging dentists will still place EDTA in the canal for a minute to remove the smear layer before reintroducing NaOCl), and it is absolutely critical that the NiTi gauging files are used with a straight-in, straight-out motion—not even a wiggle can occur or the apical constricture will be cut open and further shaping will be required to recreate apical continuity of taper.

Shaping of the palatal canal (a medium-size canal) was begun with a 30/.08 GTX File and it easily cut to length, showing no chips at the tip of the file. A 40/.08 GTX File was then cut to length with visual gauging, indicating that shape might then be complete—a fact that was confirmed by tactile gauging. Each canal was shaped with just two GTX Files, and the post-operative radiograph shows very conservative coronal shapes and excellent apical accuracy in the obturation (Fig. 2).

Case 2: Mandibular molar re-treatment

Figure 3 shows a previously treated tooth that was sensitive to percussion and biting pressure. It had an overt apical lesion on the mesial root apex due to the inadequacy of apical treatment. After removal of the gutta-percha, lubricant and small K-files were used to bypass the apical blockage in the mesial canals (Fig. 4) and the ledge in the distal canal. The mesial canals had separate apical openings that were each negotiated. However, they were also confluent



and my shaping files working through those canals cut into a common terminal opening. The second apical portal of exit in the root was kept patent with a #15 K-file, the gutta-percha points were fitted into the confluence, and the second opening was filled during the Continuous Wave of Condensation Downpack. The canals were initially shaped with a single 20/.06 in three cutting cycles, followed by a 30/.06 GTX File to finish as the 20/.06 had no tip flute debris upon reaching length.

The distal canal was more difficult because it had a sharply bent canal with a ledge at the apex of the curve (created by the previous dentist who treated the patient). Pre-bent, stainless-steel K-files were used to bypass the ledge impediment and a series of files (sizes 15 to 30) were used in a light serial step-back technique to rough out the apical shape. I had used this technique to cut tapered-preparation shapes in root canals for about ten years, and although it was the only method we had prior to variably tapered NiTi shaping instruments, it was slow and tedious, and created less-than-perfect tapers in canals. So in this case, although it was necessary to cut an initial shape with this method, I wanted an apical taper that would improve the apical accuracy of obturation in the canal.

The technique taught to me by Dr David Rosenberg, (a dear friend) who tragically passed away earlier this year and will always be an inspiration, in these situations is to pre-bend the NiTi shaping files with Endo-Bender pliers. While NiTi (even with its shape memory) is commonly thought to be impervious to bending, it actually requires greater flexure—about a 180 degree bend—to achieve a residual bend of approximately 30 to 45 degrees. This can be done to GT Hand Files or to GTX Rotary Files (I prefer using

handpiece-driven files for this procedure). After a 30/.08 GTX File was bent and the directional indicator on the stop was aligned with the bend, I tapped the foot pedal until the bend on the file in the handpiece was in a distal direction, dropped it past the ledge impediment, and depressed the foot pedal. The file quickly cut to length and the canal was tactilely gauged at a 30 K-file size.

However, the ledge was so large that it was virtually impossible to fit a gutta-percha cone beyond it, so this canal was filled with a GTX Obturator. These filling devices always move the sealer and gutta-percha ahead of the carrier. So, in this case I filled beyond the impediment by inserting the obturator to the ledge point in four seconds, thereby accelerating the apical movement of filling material ahead of the carrier by 3 to 4 mm. This was instead of the usual six- to eight-second insertion time, described in my typical GTX Obturator technique, necessary to limit the filling material to only end up 1 mm ahead of the carrier—which is obviously the goal when the carrier can be placed to a length 1 mm short of the terminus.

This case was shaped with just two GTX Files in the reasonable curvature of the mesial canals. However, as is typical with difficult canals, the distal canal required four K-files and a single GTX File (Fig. 5).

_Cases 3 and 4

The two cases shown in Figures 6 and 7 were treated by my good friend Dr Giuseppe Cantatore. As is typical of his GTX technique for virtually all canals, he negotiated each canal up to a K-file size 20, cut a 20/.06 GTX File to length, then cut a 30/.04 GTX File to length, and finished with a 30/.06 GTX File. Dr Cantatore is known for

Figs. 6 & 7 _Maxillary molars with S-shaped curves in the DB canals; note the MB root structure in Figure 6 with its narrow width and remarkable curvature. No anti-curvature brushing motion was needed because of the GTX File lands and their limited MFDs. These cases were filled with carrier-based obturation. (Courtesy of Dr Giuseppe Cantatore)

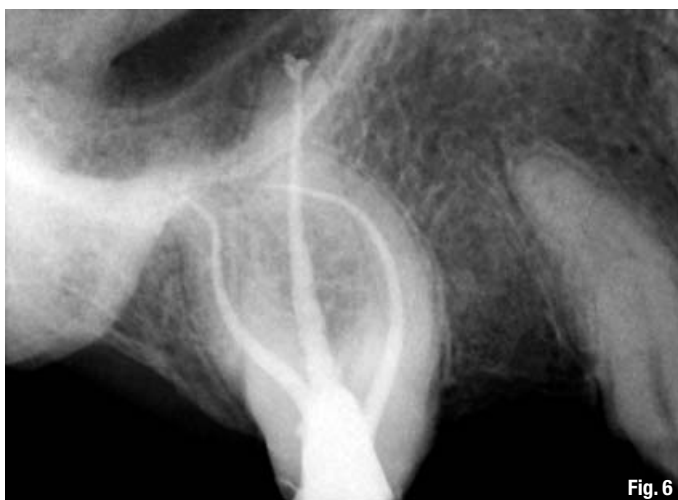

Fig. 6

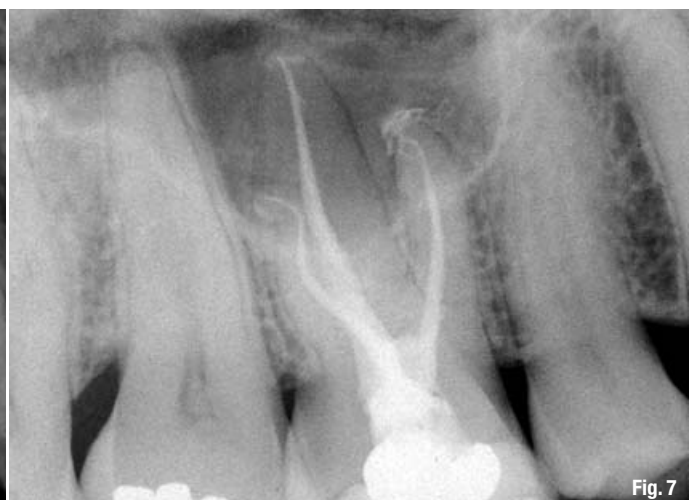

Fig. 7