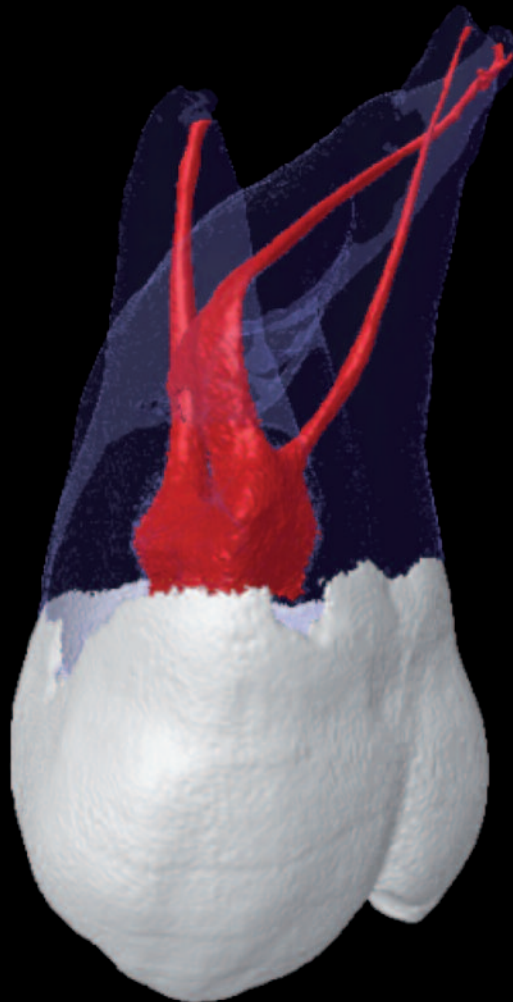

roots

international magazine of endodontology

3²⁰¹¹



| **case report**

White lines or white lies?

| **opinion**

Is rotary NiTi the new paradigm?

| **practice management**

Connectivity in the dental world



Touch Precision



High-tech apex locator for precise length determination

Sets new standards with respect to user-friendliness and design

- Unique 3-D style colour touch screen
- Smart user interface
- Foldable, pocket-sized design



VDW GmbH
P.O. Box 830954 • 81709 Munich • Germany
Tel. +49 89 62734-0 • Fax +49 89 62734-304
www.vdw-dental.com • info@vdw-dental.com

RAYPEX® 6

Apex locator



Endo Easy Efficient®

Dear Reader,



Dr Rafaël Michiels

Endodontics is changing—for better or for worse, that depends on your point of view. Recently, the introduction of new endodontic files aroused the endodontic community. We have seen the arrival of the Self-Adjusting File (SAF), with its revolutionary design and atypical shaping approach. Other recent developments are the WaveOne and Reciproc files, which use a reciprocating movement instead of a continuous rotating movement.

While these innovations offer some advantages to the existing files, we should remain wary. In the last couple of years, a number of innovations have been hyped for a while and then disappeared.

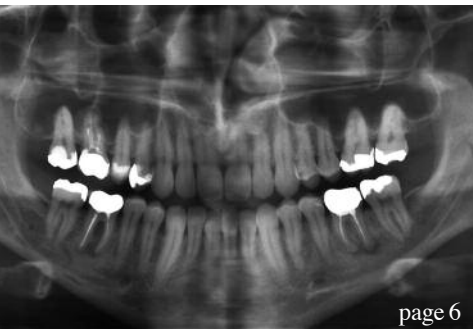If we take a good look at them, then it is my opinion that this is mainly because there is not much new about them. The WaveOne and Reciproc files, for example, are simply automated versions of the "old" balanced force technique propagated by Dr Roane in 1985. "Obturation in three dimensions", the slogan employed by many current obturation devices, has been possible since Dr Schilder's classic article in 1967. Many more examples can be given this way.

There are many other classic articles that describe materials, techniques, anatomy, etc. If you are an optimist, you could say that the recent inventions make it easier and more predictable to achieve the goal of a root-canal treatment according to the fundamental principles. If you are a realist, then you recognise that the problem lies herein: there is a general lack of knowledge of the basic literature in endodontics. If you are not armed with this knowledge, then you are vulnerable to marketing and aggressive sales representatives. We ourselves have the responsibility of stopping this loss of critical thought. We have to keep ourselves up to date by attending congresses, following independent courses and reading the literature. If we manage to do this and if we succeed in teaching our students and colleagues to do the same, then I am sure we can change endodontics for the better with many new materials, techniques and devices to come.

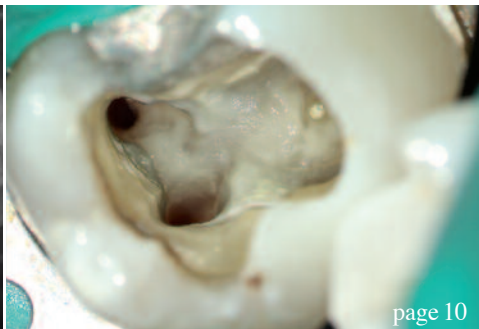
I am honoured to contribute to this edition of **roots** and hope you will enjoy this issue and can use it to improve your endodontic treatment.

Yours faithfully,

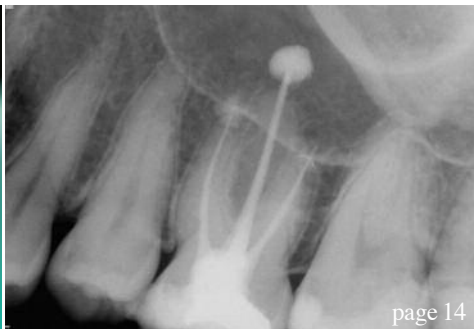Dr Rafaël Michiels
Hasselt, Belgium



page 6



page 10



page 14

| editorial

03 **Dear Reader**
| Dr Rafaël Michiels, Guest Editor

| case report

06 **Efficient and ergonomic apical resection**
using the Kaiserswerth algorithm
| Prof Marcel Wainwright

10 **White lines or white lies?**
| Dr Rafaël Michiels

14 **A race to the apex—Crown-down in 1!**
| Dr Philippe Sleiman

16 **Do we treat patients based on radiolucency?**
—A case report
| Dr Sander Loos

18 **Are endodontists invited**
to the treatment planning party?
| Dr Daniel Flynn

| opinion

24 **Is rotary NiTi the new paradigm?**
| Dr Barry L. Musikant

| research

28 **CBCT study of root-canal morphology**
of mandibular first molars in a Spanish population
| Dr Óliver Valencia de Pablo *et al.*

| feature

34 An interview with **Dr Reena Gajjar, My Dental Hub**
38 An interview with **Dr Ladislav Grad & Dr Matjaz Lukac, Fotona d.d.**

| practice management

40 **Connectivity in the dental world**
| Shane Hebel
44 **Six steps to a chartless practice**
| Dr Lorne Lavine

| industry news

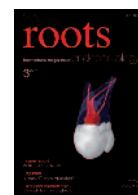47 | Acteon/VDW

| meetings

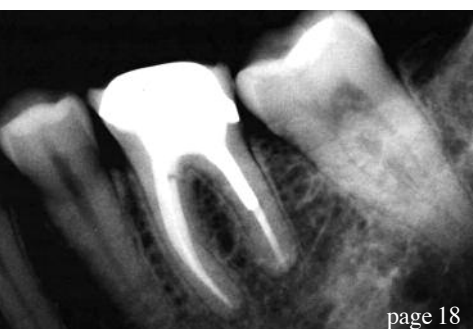48 **International Events**

| about the publisher

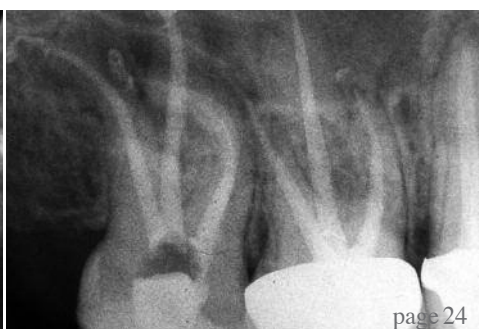49 | submission guidelines
50 | imprint



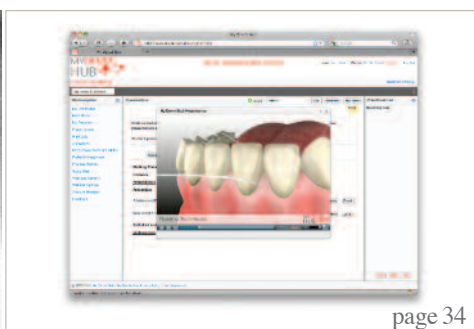
Cover image courtesy of Prof Marco Versiani and Prof Manoel D. Sousa Neto, Ribeirão Preto Dental School, University of São Paulo.



page 18



page 24



page 34



Cordless
with an extra-small head

120 Years W&H.
Help us support SOS Children's Villages!



An extra-small head. No cord. And full power. The Entran cordless handpiece provides complete freedom of movement and, thanks to its extra-small head, also gives optimum access to the treatment site. The torque-controlled automatic direction change and the five torque levels set new safety standards in cordless endodontics.

People have Priority! W&H supports the humanitarian organization SOS Children's Villages. Get involved! Further information at wh.com

entran

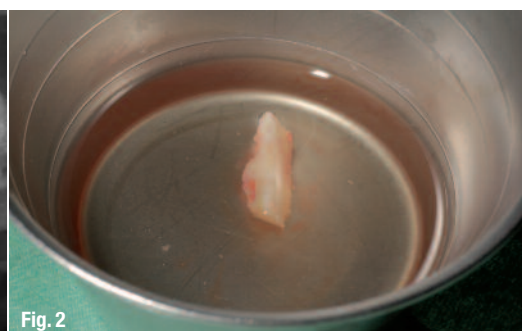
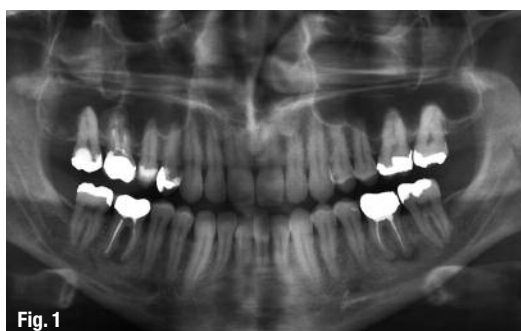Endodontics. Cordless!

Efficient and ergonomic apical resection using the Kaiserswerth algorithm

Author_ Prof Marcel Wainwright, Germany

Fig. 1_OPG showing active infection at sites 16, 36 and 46.

Fig. 2_Bone block, stored in Ringer's solution.



Thanks to minimally invasive techniques, such as ultrasonic surgery and the availability of reliable restorative materials, the surgical revision and rehabilitation of endodontically treated teeth have a significantly better prognosis than only ten years ago. Apical resection is a challenging surgical procedure—not least because of the limited accessibility of the surgical field. Instrumentation of an apical resection case therefore requires a surgical technique that is as simple as it is safe and ergonomic.

_Case I

A 34-year-old male patient presented at our clinic for the first time. The orthopantomogram (OPG) yielded an accidental finding of apical translucencies at teeth #14, 36 and 46, which had been insufficiently treated endodontically. Clinically, these translucencies were asymptomatic and diagnosed as instances of chronic apical periodontitis or apical osteitis (Fig. 1).


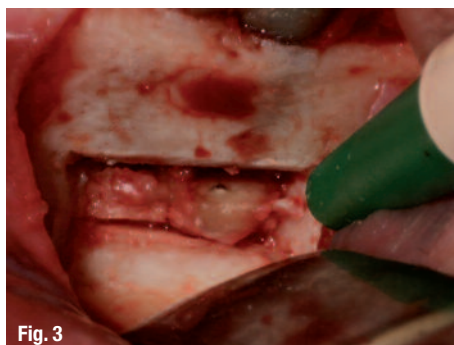
Fig. 3_Surgical site after removing a bone block and performing apical resections on tooth #36.

Fig. 4_The MAP System.

Fig. 5_Autoclavable box with syringe, mixing cup and tips.

This report presents two clinical cases in illustrating a system for applying retrograde endodontic filling materials that has proven a consistently viable option in our clinical practice.

Together with the patient, we planned for an apical resection of tooth #36 in conjunction with a retrograde root-canal filling with subsequent removal of the non-salvageable teeth #16 and 46.




Following extensive consultation and patient education, surgery was performed under local infiltration anaesthesia. With our protocol, block anaesthesia is unnecessary in 98 % of all surgical interventions in the mandible, and dispensing with it minimises the risk of iatrogenic nerve damage.

An incision was performed in the marginal gingiva, with a mesiodistal relief incision, followed by preparation of a full flap for adequate access to the surgical site. Using the Piezotome 2 (Acteon), a buccal bone window of adequate depth was prepared to gain access to the apical region at tooth #36 in order to perform the apical resection. It is helpful for the preparation to provide for undercuts in order to facilitate subsequent removal of the bone block. As no rotary instruments were used and because ultrasonic surgical instruments have a vaso-constrictor effect, the surgical field remained impressively free of bleeding and afforded a clear view of the site. The bone block was stored in Ringer's solution to facilitate subsequent repositioning (Fig. 2). The root apices were then exposed and ultrasonically removed (Fig. 3).

After apical resection, our protocol called for thorough removal of all soft tissue using instruments, followed by complete decontamination of the cyst lumen using a diode laser. Care had to be taken to ensure that the laser tip did not make direct contact with the bone. Retrograde preparation of the root canals was also performed ultrasonically, which only takes a few seconds when using the Piezotome 2.

Following chlorhexidine-digluconate and sodium-hypochlorite rinses, the retro-prepared root canals



were dried with paper points. In our clinic, we have had excellent success with the MAP (Micro-Apical Placement) retro system (PDSA), which has been on the market for many years (Fig. 4). The system comes in a sterilisable metal container (Fig. 5). The triple-angled endo tips (Fig. 6) greatly simplify the uptake and application of the material, with the syringe facilitating "injection" (retrograde obturation) of the root canal to a depth of several millimetres. This well-targeted application of the restorative material keeps the surgical field open (Fig. 7).

On application of ProRoot MTA (DENTSPLY Maillefer), the material was allowed to set, the cross-section surface of the resected area was smoothed and polished, the resection lumen was filled with a

- Fig. 6** Endo tips with different angulations.
- Fig. 7** Applying MTA using the MAP System.
- Fig. 8** The bone block is repositioned and secured with bone cement (VitalOs).
- Fig. 9** Post-op OPG detail following apical resection of tooth #36.
- Fig. 10** Base-line status of tooth #14 following apical resection *alio loco* and reinfection.
- Fig. 11** Surgical site 14 following the semilunar incision.
- Fig. 12** Retrograde ultrasonic preparation (Piezotome 2).

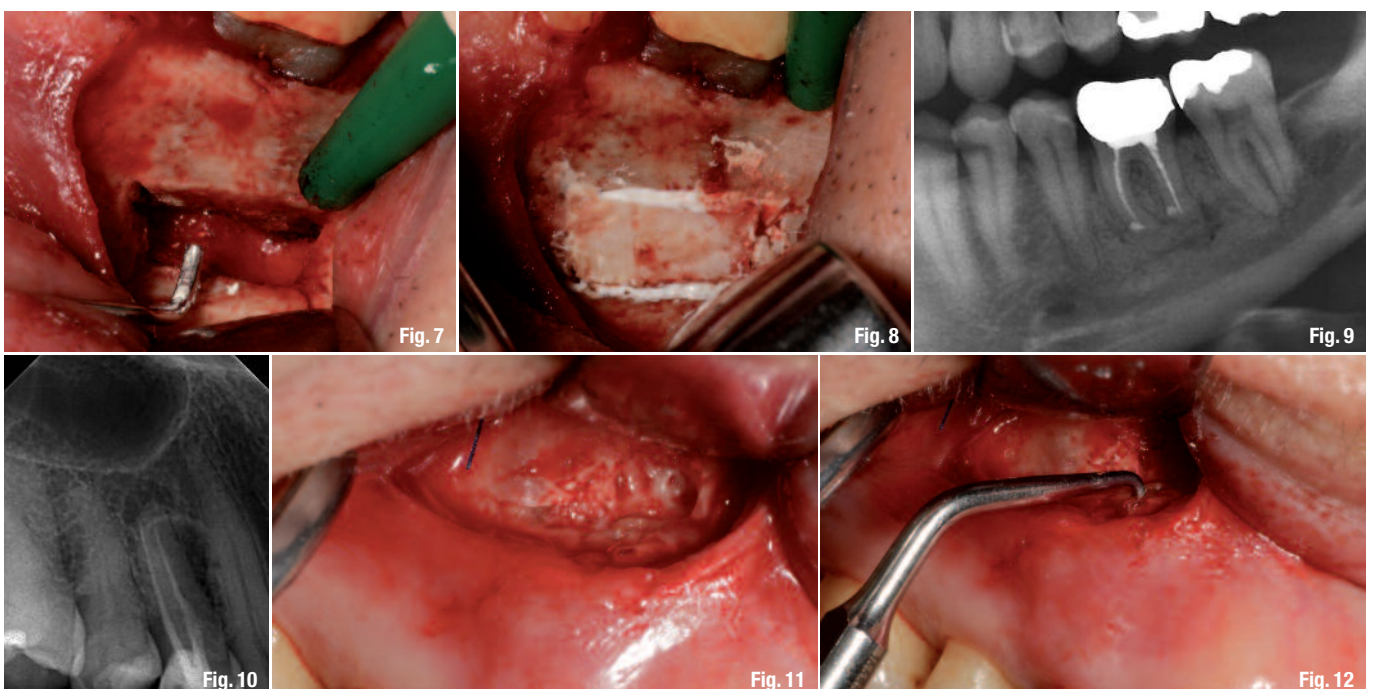




Fig. 13 _Mixed ProRoot MTA prior to application.

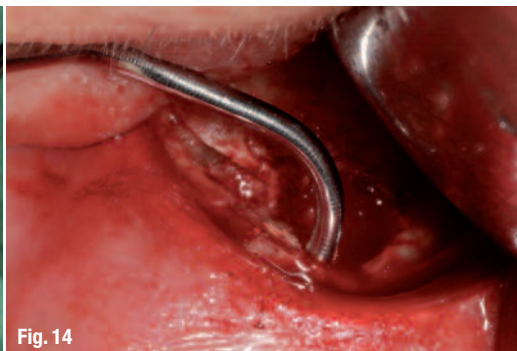

Fig. 14

Fig. 14 _Applying the MTA using the MAP System.

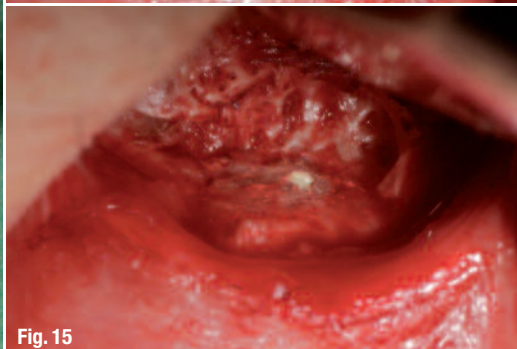

Fig. 15

Fig. 15 _Resected and retro-filled tooth #14.

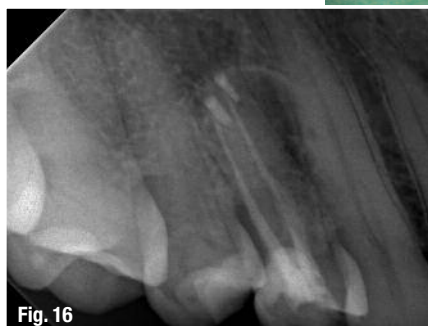

Fig. 16

Fig. 16 _Revision treatment outcome for tooth #14.

quick-hardening bone cement (VitalOs, PDSA), and the bone block was returned to its place (Fig. 8). The post-operative radiograph shows the site following apical resection and retrograde root filling (Fig. 9).

radiograph (Fig. 16) shows an efficient retrograde filling of both root canals following revision of tooth #14. Owing to a projection artefact, the restorative appeared beside the canals, when it was in fact clinically located exactly within.

The patient was prescribed Amoxicillin 750 mg and Ibuprofen 600 mg post-operatively, as well as Arnica C30 to prevent swelling. Post-operative healing was uncomplicated and the sutures could be removed after eight days. Swelling was minimal, and the patient reported virtually no post-operative pain.

Case II

A 65-year-old female patient presented with an apical resection on tooth #14 that had been performed *alio loco* five years before. The patient was looking for help because the site had become infected again. She reported pain at tooth #14 on occlusal contact and percussion. A local digital radiograph clearly showed the area of apical resection, the two root-canal fillings, and a cystic peri-apical radiolucency (Fig. 10). Since this was a surgical re-entry case, the same incision technique was used as chosen by the primary treatment provider, i.e. a crescent-shaped incision as described by Pichler (Fig. 11). The procedure was otherwise the same as in Case I. Following retrograde ultrasonic preparation (Fig. 12), ProRoot MTA was mixed to a working consistency and applied using the MAP System (Figs. 13 & 14). This clean and efficient application mode and controlled handling shortened the surgical procedure and reduced post-operative complaints (Fig. 15). The post-operative

Conclusion

Apical resection is a routine procedure in our clinic. Thanks to the use of ultrasonic surgery, the surgical laser and the MAP System, this procedure is reliable, predictable and simple, and we have preserved the natural teeth of many patients. Being an oral implantologist myself, I do not perceive anything contradictory in looking at these treatment methods; rather, apical resection is a complementary treatment mode and an attempt to preserve teeth over the longer term that would otherwise be considered lost.

Editorial note: A complete list of references is available from the author.

<u>_contact</u>	roots
<p>Prof Marcel Wainwright Dental Specialists and White Lounge Kaiserswerth Kaiserswerther Markt 25–27 40489 Düsseldorf Germany</p> <p>www.dentalspecialists.de</p>	



Simplicity is the real innovation



wave.one™

- Only one sterile NiTi instrument per root canal in most cases
- Decreases the global shaping time by up to 40%
- Reciprocating technology respecting the root canal anatomy
- Single use as new standard of care