

roots

international magazine of endodontics

3²⁰¹⁶

CE article

Treatment planning:
Retention of the natural dentition
and the replacement of missing teeth

technique

Twisted files and adaptive motion technology:
A winning combination

study

Long-term analysis of primary,
non-surgical root canal treatments



ROOTS SUMMIT

NOV. 30 - DEC. 3, 2016

24 C.E.
CREDITS

21 C.E. CREDITS
additional for workshops on Nov. 30

THE MASTERS OF ENDODONTICS



Antonis Chaniotis
Greece



David E. Jaramillo
USA



Freddy Belliard
Dominican Republic/Spain



Oscar von Stetten
Germany



Rafaël Michiels
Belgium



Gianluca Plotino
Italy



Nicola M. Grande
Italy



Sergio Rosler
Argentina



Imran Cassim
South Africa



Siju Jacob
India



Bojidar Kafelov
Bulgaria



Mile Churlinov
Bulgaria



Ana Arias
Spain



Walter Vargas
Obando
Costa Rica



Roberto Cristian
Cristescu
Romania/Netherlands



Luis Chávez
de Paz
Peru/Sweden



Carlos Aznar
Portoles
Spain/Netherlands



Ahmed Abdel
Rahman Hashem
Egypt



Piotr Wujec
Poland



Gary Glassman
Canada

ARE MEETING IN DUBAI WITH THE ROOTS COMMUNITY

DATE: NOV. 30 - DEC. 3, 2016
LOCATION: CROWNE PLAZA, DUBAI

MAIN SPONSORS:

Kerr endo★star

PARTNERS & SPONSORS:



ADA CERP®
Continuing Education Recognition Program

This continuing education activity has been planned and implemented in accordance with the standards of the ADA Continuing Education Recognition Program (ADA CERP) through joint efforts between Tribune Group GmbH and Roots Summit.

Still looking for MB2: Endodontic nirvana

Finding the Holy Grail. Grabbing the Brass Ring. Finding the MB2 canal in maxillary molars! Pie in the sky? We think not!

With all the technological advances that have occurred in dentistry, certainly in endodontics, the biologic objectives have remained the same, those being to eliminate and/or prevent apical periodontitis. How does one do this? There is no magic wand nor is there a simple recipe to achieve this objective. However, one thing is for sure, if a general practitioner embarks on root canal treatment, whether on a tooth with relatively simple or complex anatomy, he/she should be held to the a standard that is expected of a specialist for the procedure being performed; thorough debridement of the entirety of the canal anatomy, followed by three-dimensional obturation.

To achieve endodontic success one must be skilled, understand the biologic system that one is working in and understand the objectives of the treatment. One should also employ the correct armamentarium, as long as he/she first has the tools. High magnification and the development of ultrasonics for conventional endodontics have enabled many practitioners to treat complex root canal anatomic variations more thoroughly.

Dental imaging has made leaps and bounds with the advent and use of the cone beam computed tomography (CBCT). Limited field of view images taken preoperatively will allow a three-dimensional rendering of the tooth to be treated. In essence, this will provide the practitioner with a more precise 'road map' with respect to the anatomic makeup of the tooth to be treated. CBCT has enlightened us to the complexity of the root canal system and thereby obliges us to 3-D disinfection and obturation.

An updated joint position statement of the American Association of Endodontists (AAE) and the American Academy of Oral and Maxillofacial Radiology is intended to provide scientifically based guidance to clinicians regarding the use of CBCT (available on AAE website).

In addition to the many recommendations that were given for the use of CBCT in endodontics, the position paper stated that 'limited FOV (Field Of View) CBCT should be considered the imaging modality of choice for initial treatment of teeth with the potential for extra canals and suspected complex morphology, such as mandibular anterior teeth, and maxillary and mandibular premolars and molars, and dental anomalies'. Why look for an MB2 canal when it doesn't exist and risk comprising the structural integrity of the tooth and risk perforation? After all, if it does exist then the CBCT may reveal it. That being said, one should also take the CBCT results with somewhat of a 'pinch of salt', as what often may appear as a lesion of endodontic origin may only be a variation of normal. A proper systematic diagnostic protocol should always be followed by, which includes but is not limited to, pulpal and periradicular testing of the tooth (teeth) in question.

So how do we reach this idyllic Endodontic Nirvana? Even with all the technological advances that we have at our fingertips, we need to provide the patient with best possible care, and the only way one can capitalise on these advances is plain old education, experience and practice, practice, practice!

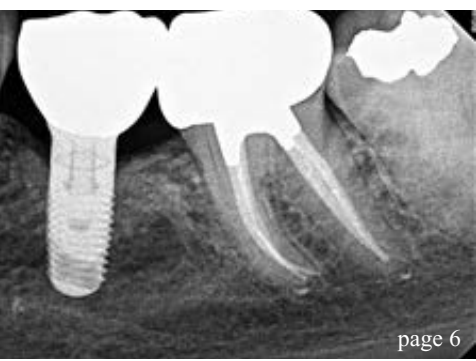
Drs. Gary Glassman & Ian Watson
(Guest Editors)



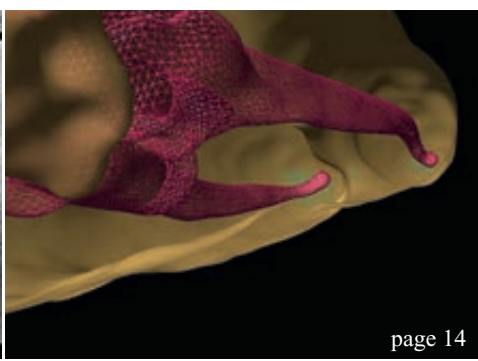
Dr Gary Glassman



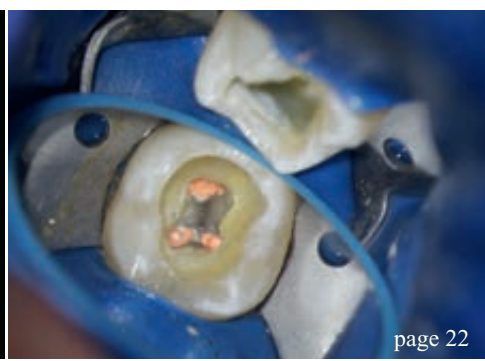Dr Ian Watson



page 6



page 14



page 22

| editorial

03 Still looking for MB2: **Endodontic nirvana**
Drs. Gary Glassman & Ian Watson (Guest Editors)

| CE article

06 **Treatment planning:**
Retention of the natural dentition
and the replacement of missing teeth
Dr Scott L. Doyle

| technique

14 **Twisted files and** adaptive motion
technology: **A winning combination for
safe and predictable root canal shaping**
Dr Gary Glassman, Prof. Gianluca Gambarini &
Dr Sergio Rosler

| case report

22 **From a distal**
Dr Sam Alborz

| study

26 **Long-term analysis** of primary,
non-surgical root canal treatments –
A retrospective study
Dr Robert Teeuwen

| products

36 **Latest** technology and products **information**

| meetings

38 **Roots Summit 2016**—Premier global forum
for endodontics takes place in Dubai

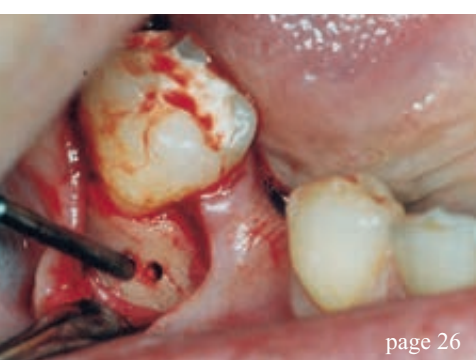40 International **Events**

| about the publisher

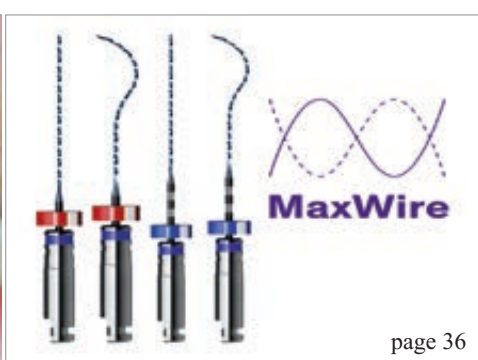
41 submission guidelines
42 imprint



Cover image courtesy of FKG Dentaire (www.fkg.ch)



page 26



page 36



page 38



CROIXTURE

PROFESSIONAL MEDICAL COUTURE



NEW COLLECTION

EXPERIENCE OUR ENTIRE COLLECTION AT WWW.CROIXTURE.COM

Treatment planning:

Retention of the natural dentition and the replacement of missing teeth

Author: Dr Scott L. Doyle, USA

CE credit



This article qualifies for CE credit. To take the CE quiz, log on to www.dtstudyclub.com. Click on 'CE articles' and search for this edition of roots magazine. If you are not registered with the site, you will be asked to do so before taking the quiz. You may also access the quiz by using the QR code above.

Introduction

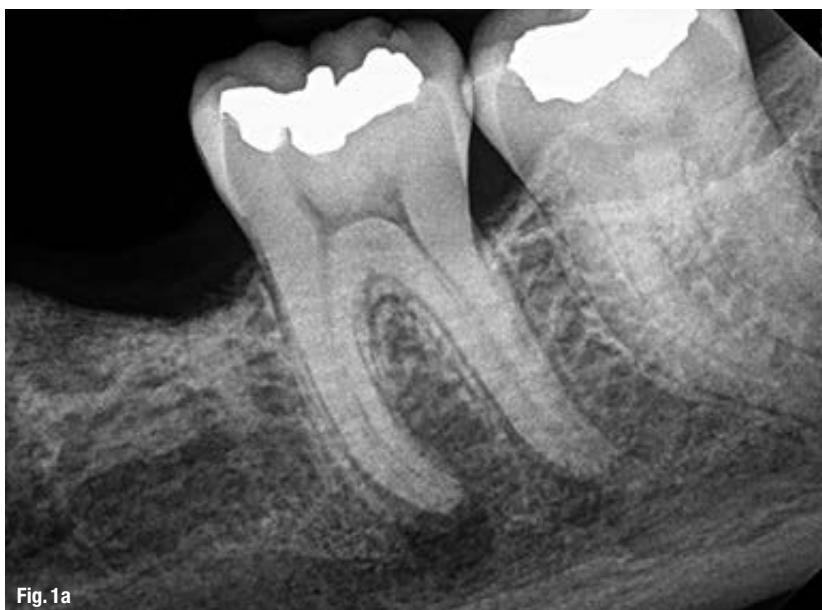Preservation of the natural dentition is the primary goal of dentistry. Published surveys indicate that patients generally value teeth and express a desire to save their natural dentition in favour of extraction whenever possible.^{1,2} Significant technological and biological improvements have been made in all disciplines of dentistry, making long-term retention of natural teeth more attainable. Patients entrust dental professionals to make appropriate recommendations regarding the maintenance and restoration of their oral health and function. It is essential to employ an evidence-based, interdisciplinary approach that addresses the interests of the patient when determining the best possible course of treatment.

In July 2014, the American Association of Endodontists, in collaboration with the American Col-

lege of Prosthodontists and the American Academy of Periodontology, hosted a two-day Joint Symposium titled *Teeth for a Lifetime: Interdisciplinary Evidence for Clinical Success*. Approximately 375 general dentists and specialists assembled in Chicago to focus on preserving the natural dentition. The educational program included evidence-based presentations on advanced regenerative techniques, improvements in technology, minimally invasive restorative methods and best practices for interdisciplinary treatment planning. Dr Alan Gluskin, chair of the 2014 Joint Symposium Planning Committee, concluded that the current evidence directs clinicians to consider saving the natural dentition as the first option when developing treatment plans.

Dental implants are one of the most significant advancements in contemporary dentistry. This innovation has had profound effects on endodontic, periodontic and prosthodontic treatment planning for the rehabilitation of edentulous spaces and for teeth with an unfavorable prognosis.³ Implant-supported restorations minimize unnecessary preparation of intact abutment teeth and allow fixed prosthodontic replacement when suitable abutments are absent. With appropriate usage and case selection, implant dentistry provides a viable option for the replacement of missing teeth.^{4,5}

There has been an increasing trend toward replacing diseased teeth with dental implants. Often, an inadequate or inappropriate indication for tooth extraction has resulted in the removal of teeth that may have been salvageable.⁶ Teeth compromised by pulpal or periodontal disease have value and should not be extracted without thoroughly evaluating restorability and potential retention therapies.⁷



Survival rates following initial nonsurgical root canal treatment

| Author | Number of teeth | Follow-up (years) | Survival (percent) |
|-----------------------------|-----------------|-------------------|--------------------|
| Salehrabi and Rotstein (24) | 1,463,936 | 8 | 97 |
| Chen et al. (25) | 1,557,547 | 5 | 93 |
| Lazarski et al. (26) | 44,613 | 3.5 | 94.4 |

A recent systematic review published in the Journal of the American Dental Association highlights a key question: "Is the long-term survival rate of dental implants comparable to that of periodontally compromised natural teeth that are adequately treated and maintained?"⁸ Nineteen studies with a follow-up period of at least 15 years were included in the analysis. The results show that implant survival rates do not exceed those of compromised but adequately treated and maintained teeth. These findings support other studies comparing long-term survival of implants and natural teeth,^{9,10} providing an important message: Periodontally compromised teeth can be retained with quality treatment and appropriate maintenance. Therefore, it may be advisable to postpone implant consideration for the periodontitis-susceptible patient to fully utilize and extend the capacity of the natural dentition.¹¹

Treatment planning options

A key focus of the Joint Symposium involved treatment planning decisions regarding endodontic treatment and implant therapy. Should a tooth with pulpal disease be retained with root canal treatment and restoration, or be extracted and replaced with an implant-supported restoration? This assessment involves a challenging and complex decision-making process that must be customized to suit the patient's needs and desires.¹²⁻¹⁴ The topic has received considerable attention in the literature, the media and at dental continuing education courses.

Endodontic treatment and implant therapy should not be viewed as competing alternatives, rather as complementary treatment options for the appropriate patient situation (Figs. 1a & b). Root canal treatment is indicated for restorable, periodontally sound teeth with pulpal and/or apical pathosis. Endodontic treatment on teeth with nonrestorable crowns or teeth with severe periodontal conditions is contraindicated, and other options such as implant placement should be considered.¹⁵ When making treatment decisions, the clinician should consider factors including outcome assessment, local and systemic case-specific issues, costs, the patient's desires and needs, aesthetics, potential adverse outcomes and ethical factors.¹⁶

Outcome assessment: Success and survival

Treatment outcomes play a key role in the assessment of different treatment options. Patients often ask whether a procedure is going to be successful or not. This question can be challenging for a clinician to answer due to the variety of reported outcomes in the literature.¹⁷ There are differences in the methodology and criteria used to evaluate the outcomes for root canal treatment and implant prosthetics, which makes comparisons between success rates difficult, if not impossible.¹⁸ Endodontic studies have historically used "success" and "failure" as outcome measures and have focused on a strict combination of radiographic and clinical criteria.¹⁹ In contrast, the implant literature has primarily reported "survival,"^{20,21} i.e., the implant is either present or absent. Therefore, implant studies that solely evaluate survival as an outcome measure will likely publish higher success rates than endodontic studies that rely on biologic healing and factors related to the entire restored tooth. To establish more valid and less biased comparisons, the same outcome measures should be used. A more patient-centered measure is to compare the outcome of survival, which is considered to be an asymptomatic tooth/implant that is present and functioning in the patient's mouth.^{22,23}

Table 1: Survival rates following initial nonsurgical root canal treatment. (Provided by American Association of Endodontists)

Fig. 1a: Pre-op image of tooth #19 with pulp necrosis and symptomatic apical periodontitis. The patient is interested in rehabilitation of the edentulous space. (Images courtesy of American Association of Endodontists)
Fig. 1b: Three-year recall image. The patient has benefited from both root canal treatment and implant therapy. (Courtesy of Dr Tyler Peterson and the University of Minnesota School of Dentistry)

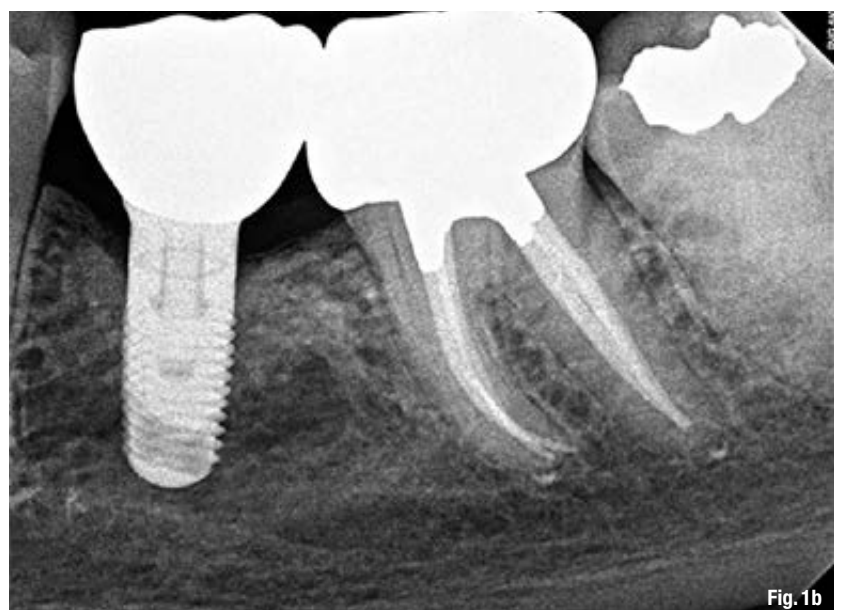
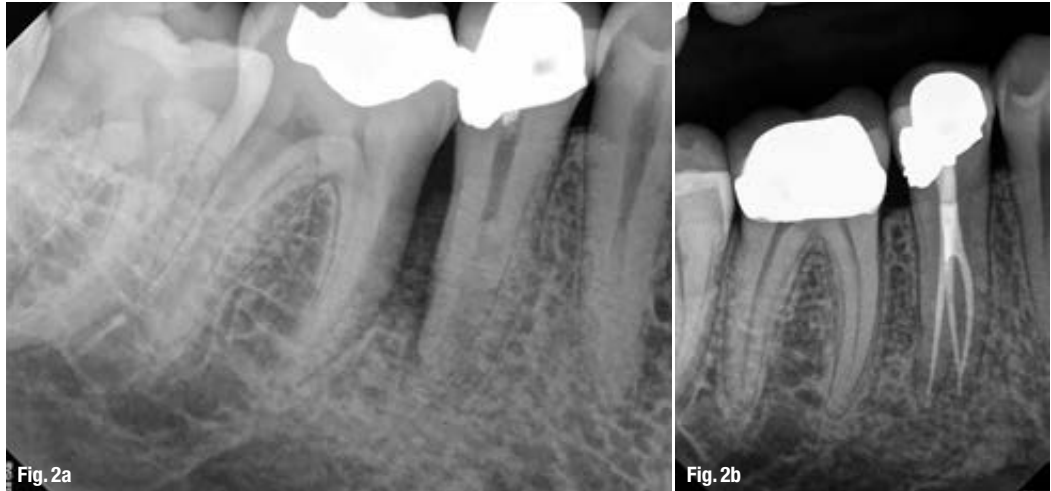


Fig. 2a: Pre-op image of tooth #29. Note lateral radiolucency and complex canal anatomy.

Fig. 2b: Two-year recall image reveals both excellent endodontic and restorative treatment. Note healing of lateral radiolucency. (Courtesy of Dr Joe Petrino)



Multiple large-scale studies including millions of teeth have used survival to assess the outcome following root canal treatment. An investigation using an insurance database of more than 1.4 million root canal-treated teeth demonstrated that 97 percent were retained within an eight-year follow-up period.²⁴ Other studies show similarly high survival rates (Table 1).^{25,26} An epidemiological approach allows for the assessment of tooth retention from a large sample of patients experiencing actual care in private practices. Systematic reviews²⁷ and controlled studies from academic settings complement the previous findings. Two prospective trials each reported 95 percent survival rates at four years²⁸ and four to six years²⁹ for teeth after initial root canal treatment.

complex cases, referral to an endodontist with additional training and expertise may result in more favourable outcomes³⁰ and positive patient experiences.³¹ Interdisciplinary care is important for the management of endodontically treated teeth. The restorative dentist plays a significant role in the outcome by providing an appropriate and timely restoration.³² Root canal treatment is not complete until the tooth is coronally sealed and restored to function. Multiple studies have confirmed that a definitive restoration has a significant impact on survival,^{24,25,27,28,33} Therefore, the likelihood of a favorable outcome increases with both skillful endodontic care and prompt restorative treatment (Figs. 2a & b).³⁴

Fig. 3: A matched-case comparison of survival rates after treatment with either a restored endodontically treated tooth (n = 196) or a restored single-tooth implant (n = 196) performed at the same institution (J Endod 2006;31).

Predictable tooth retention: Nonsurgical root canal treatment and restoration

The majority of endodontic treatment is performed by general dentists with a high degree of success.²⁶ For

Advancements in technology aid in attaining high levels of tooth retention. The dental operating microscope, nickel-titanium instruments, apex locators, enhanced irrigation protocols and dentin preservation strategies are examples of improvements that allow clinicians to predictably manage a greater range of treatment options. Additionally, cone beam-computed tomography facilitates more accurate diagnosis and improved decision-making for the management of endodontic problems.^{35,36}

Comparative studies: Endodontically treated teeth and single-tooth implants

Large-scale systematic reviews have addressed the relative survival rates of endodontically treated teeth and single-tooth implants. The Academy of Osseointegration conducted a meta-analysis using 13 studies (approximately 23,000 teeth) on restored endodontically treated teeth and 57 studies (approximately 12,000 implants) on single-tooth implants. The outcome data demonstrated no difference between the two groups during any of the observation periods.³⁷ Another systematic review supported by the American Dental Association compared the outcomes of endodontically treated teeth with those of a single-

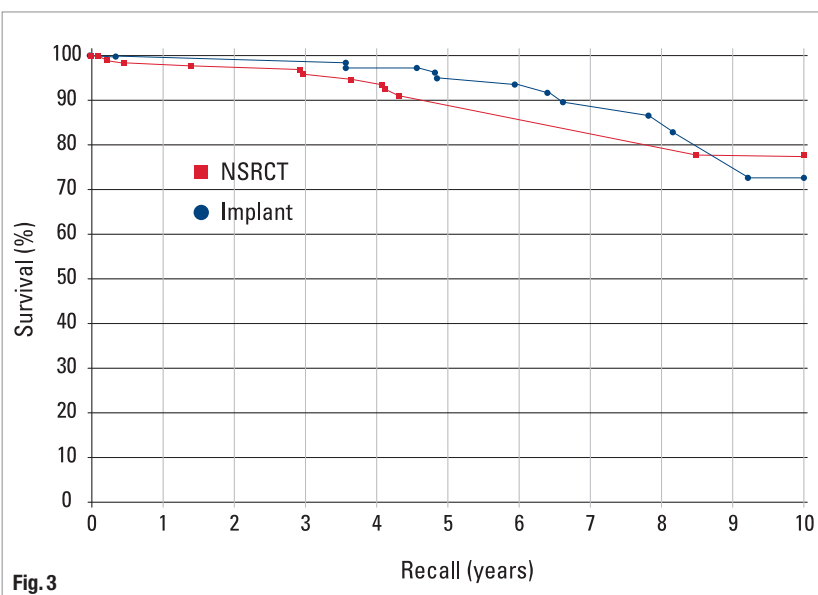


Fig. 3

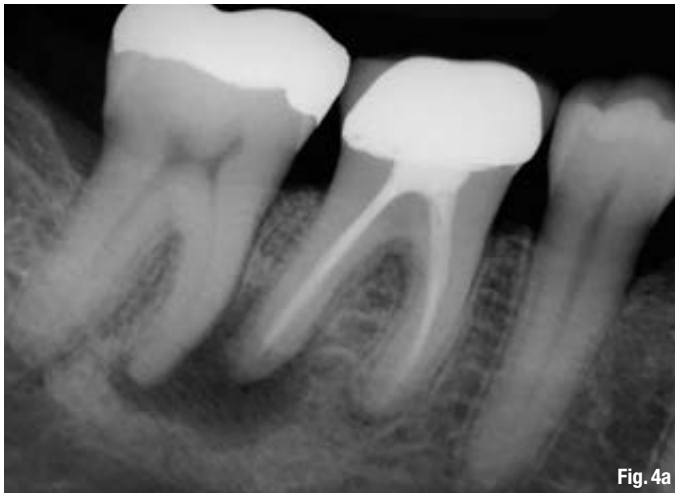

Fig. 4a

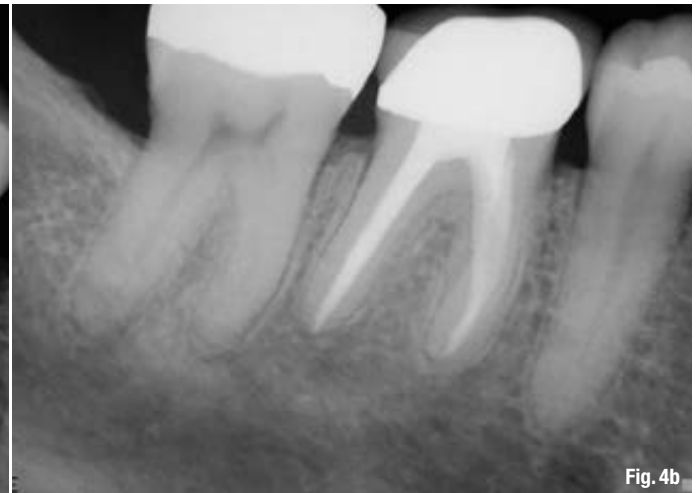


Fig. 4b

tooth implant-restored crown, fixed partial denture, and no treatment after extraction. At 97 percent, the long-term survival rate was essentially the same for implant and endodontic treatments. Both options were superior to extraction and replacement of the missing tooth with a fixed partial denture.³⁸

Retrospective studies also have compared the outcomes for the two treatment options. A study conducted at the University of Minnesota compared the outcomes of 196 restored endodontically treated teeth with 196 matched single-tooth implants.³⁹ Both groups had 94 percent survival rates. The survival curves for these two groups are provided in Figure 3. Another investigation from the University of Alabama provided similar results.⁴⁰

Based upon similar survival rates, the decision to treat a compromised tooth endodontically or replace it with an implant must be based on factors other than treatment outcome.^{37,41} Several factors influence the decision-making process.⁴²⁻⁴⁴ The following lists provide an overview of case-specific factors that should be considered in making this treatment decision.

Systemic factors

- The list of potential risk factors for peri-implantitis or implant failure is extensive. It includes systemic disease, genetic traits, chronic drug or alcohol consumption, smoking, periodontal disease, radiation therapy, diabetes, osteoporosis, dental plaque and poor oral hygiene.⁴⁵
- There are few medical conditions that directly affect endodontic treatment outcomes. Risk factors that may be associated with decreased survival of root canal-treated teeth include smoking,⁴⁶ diabetes,^{28,46} systemic steroid therapy²⁸ and hypertension.⁴⁷
- Patients taking antiangiogenic or antiresorptive (i.e., bisphosphonates) medications may have an increased risk for developing medication-related osteonecrosis of the jaw. This may affect treatment

planning for both implant and endodontic treatment.

- It is generally recommended to wait for the completion of dental and skeletal growth prior to implant placement.⁴⁸

Local factors

- Accurate diagnosis.
- Restorability assessment: removal of caries/restorations; adequate ferrule.
- Strategic nature of the tooth as it fits into the comprehensive restorative plan.
- Caries risk and oral hygiene.
- Periodontal assessment: tissue biotype, adequate biologic width.
- Presence of crack(s), root fracture(s), resorption.
- Occlusion and parafunction.
- Teeth with less than two proximal contacts and those serving as fixed partial denture abutments may have lower survival.²⁷
- Need for adjunctive treatment (crown lengthening, orthodontic extrusion, sinus lift, bone graft, etc.), which may impact financial cost and time to function.
- Quantity and quality of bone.
- Proximity to anatomical structures (maxillary sinus, inferior alveolar nerve, etc.).
- Implant esthetics in the anterior region may be challenging.⁴⁹

In addition to systemic and local factors, it is critical to include the patient's concerns during treatment planning. Common patient-centered factors include costs, treatment duration, satisfaction with treatment and the potential for adverse outcomes.

Financial considerations can influence a patient's decision when weighing treatment options. The availability of dental insurance may also impact choices.⁵⁰ Endodontic treatment and restoration offer considerable economic advantages to the patient.⁵¹⁻⁵³

Fig. 4a: Pre-op image of tooth #30 with previous endodontic treatment and persistent apical periodontitis. A dentist initially recommended extraction and replacement of this tooth with an implant. The patient requested a second opinion from an endodontist who determined the tooth to be treatable.

Fig. 4b: Four-year recall image demonstrates apical healing following nonsurgical retreatment. Accurate diagnosis prevented the unnecessary treatment of tooth #31.

(Courtesy of Dr Martin Rogers)