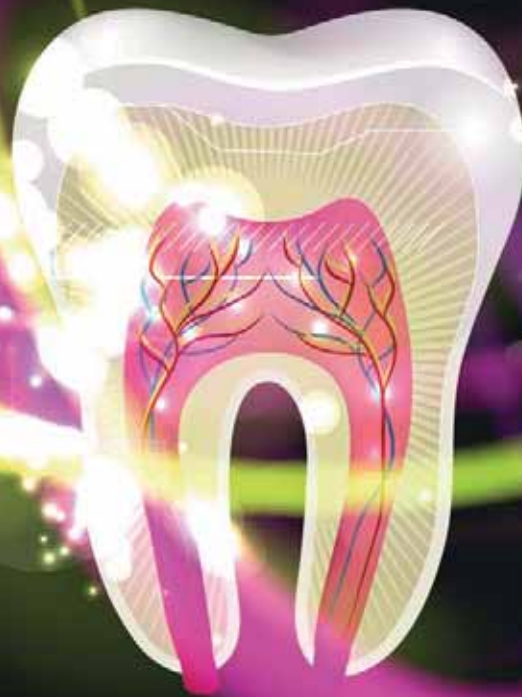

# laser

international magazine of laser dentistry

3<sup>2014</sup>



| **research**

Er:YAG-Laser — The key factor in the therapy of periimplant inflammations

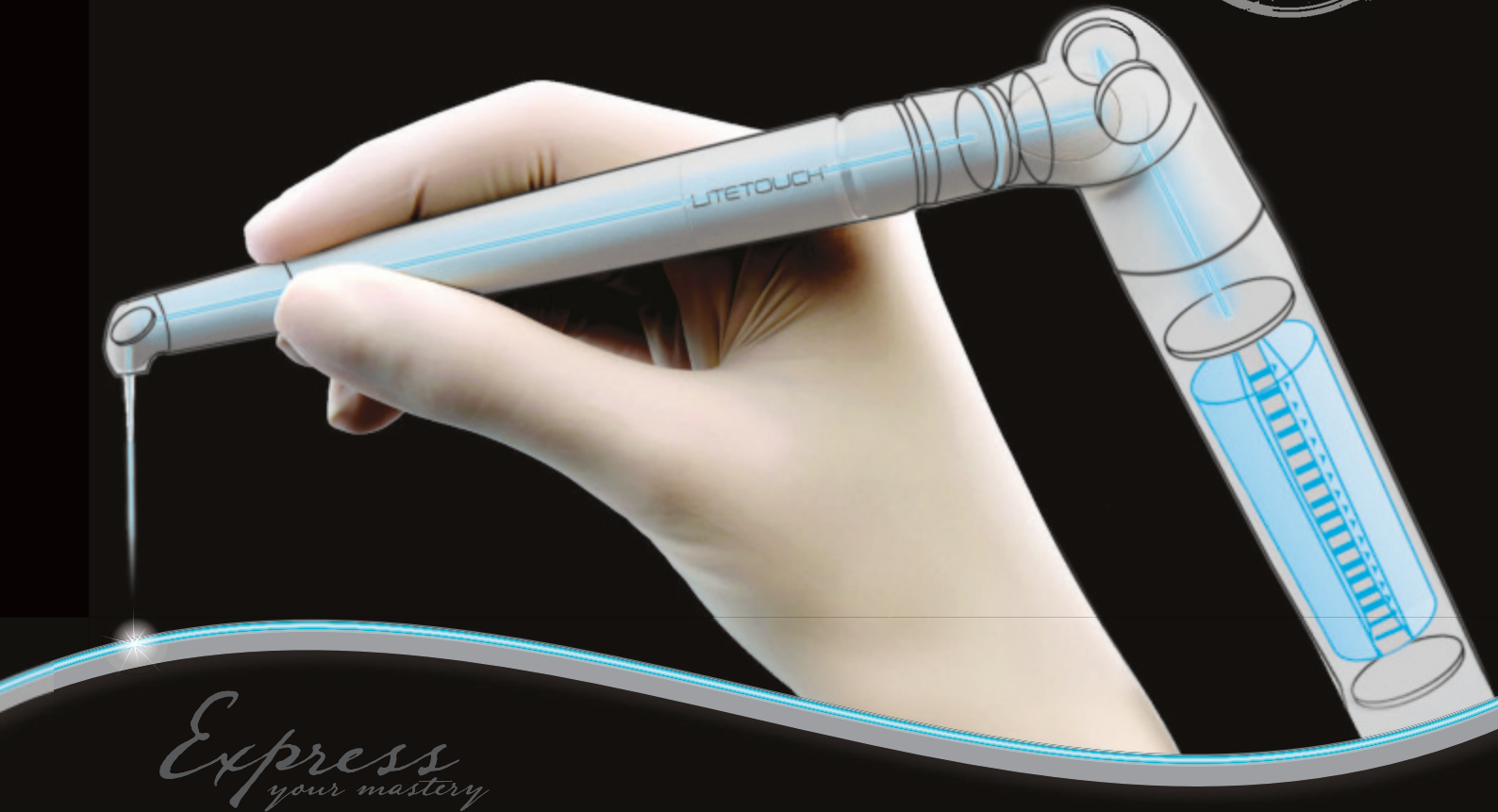| **case report**

Peripheral Giant Cell Granuloma surgery with diode laser

| **industry report**

Subjective acceptance and pain perception of Er:YAG laser therapy in children





*Express  
your mastery*

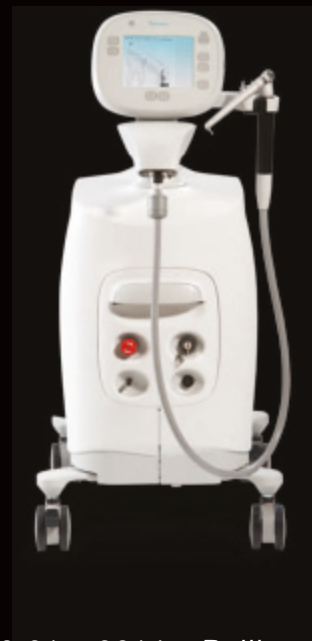Education. Technology. Family.

Join the Light Instruments Family

presenting

LITETOUCH™

The unique fiber-free Er:YAG laser  
that has changed the face of laser dentistry



Live presentations every hour at our booth during Sept 20-21 ,2014, Beijing, China  
at the 8th Congress of the International Society for Oral Laser Applications: <http://tfr852712.douhao.net.cn>

Reserve your personal consultation at [dental@syneron.com](mailto:dental@syneron.com)  
[WWW.SYNERONDENTAL.CN](http://WWW.SYNERONDENTAL.CN) [WWW.SYNERONDENTAL.COM](http://WWW.SYNERONDENTAL.COM)



LHPB77693EN

# A new level in laser dentistry



Prof. Dr. Norbert Gutknecht  
Editor-in-Chief

Dear colleagues,

Laser dentistry would lose its appeal if there was no development in this innovative technology visible. At this year's WFLD congress, a portion of this innovative potential, which is still inherent to laser technology, was presented. This includes technical modifications on laser systems combined with new treatment results and indication areas with proved as well as standardised laser systems.

On the occasion of the WFLD congress, the proceeding integration of laser technology to dental treatment processes could be followed in the individual lectures. Afterwards, the speakers' abstracts could be reread in the WFLD congress edition.

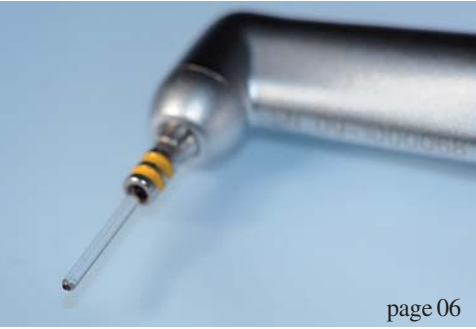The increasingly more refined and differentiated adjustment options of modern laser systems do more and more represent a great challenge for operators. Since control software of individual laser systems also pursue different technical goals, a direct comparison of settings is no longer possible today due to different performances which are emitted on the tissue. In previous times, for handling only few adjustment options a good training of the respective laser systems had been necessary in order to perform a successful treatment. With this in mind, how much more does a dentist need to be engaged to receive a solid training today in view of more than 30 adjustment and combination possibilities?

For this reason, the responsible dentist should look for an educational institute where the technical basics of laser systems, the bio-physical interactions between laser light and tissue as well as the relevant clinical indications are taught and demonstrated. A register of this institutions can be obtained by the WFLD headquarter ([info@wfld.info](mailto:info@wfld.info)).

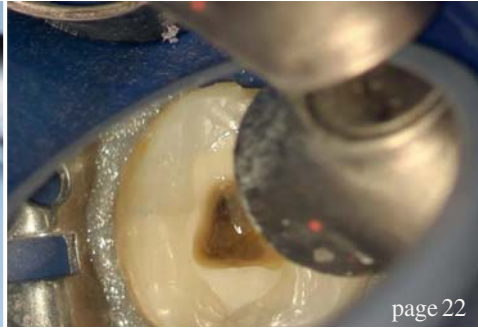
Kind regards,

A handwritten signature in black ink, appearing to read 'Norbert Gutknecht', written in a cursive style.

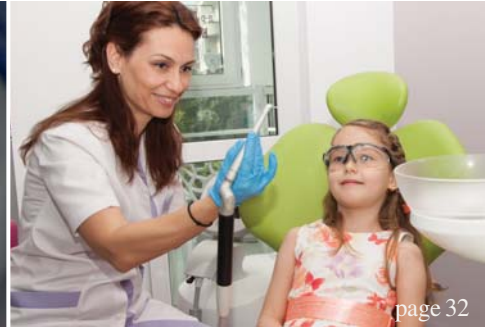Prof. Dr. Norbert Gutknecht  
Editor and CEO WFLD



page 06



page 22



page 32

| editorial

03 A **new level** in laser dentistry  
| Prof. Dr Norbert Gutknecht

| research

06 **Er:YAG-Laser**—The **key factor** in the **therapy**  
of **periimplant** inflammations  
| Jiaoshou (Prof.) Dr Frank Liebaug *et al.*

16 **Alveolar** corticotomies by **laser**cision  
| Dr Brice Savard

| overview

22 **Laser** activated **irrigation**—Part II  
| Prof. Dr Roeland Jozef Gentil De Moor *et al.*

| case report

28 Peripheral **Giant Cell** Granuloma **surgery**  
with **diode laser**  
| Maziar Mir *et al.*

| industry report

32 **Subjective acceptance** and pain perception of  
**Er:YAG laser** therapy in children  
| Ani Belcheva *et al.*

36 The Delta Cube laser:  
a **multi-wavelength diode laser**—Part I  
| Prof. Dr Jean-Paul Rocca *et al.*

| economy

40 How **crisis** made me **doubt** my degrees!  
| Dr Anna Maria Yiannikos

| interview

42 **Laser** application in **dental surgery**:  
**CO<sub>2</sub> laser** for **soft tissues**  
| Interview with Prof. Dr Michael Bornstein

| meetings

44 **Düsseldorf**—Beauty on the **Rhine**  
| Katrin Maiterth

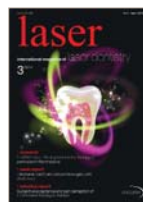46 **14<sup>th</sup> WFLD World Congress**:  
The ever **increasing** use of **laser** in **dentistry**  
| Aldo Brugnera Jr.

| news

48 **News**

| about the publisher

50 | imprint



Original Backgrounds: ©flaxy; GRei  
Artwork by Sarah Fuhrmann, OEMUS MEDIA AG.



page 42



page 44



page 46

Fotona<sup>®</sup>  
choose perfection



The first digitally controlled  
dental laser handpiece

## X-Runner<sup>™</sup>

- instantly adjustable spot size and shape
- precise coverage of large areas
- lightweight, ergonomic design
- for Fotona LightWalker AT laser systems

50 years  
of Fotona laser innovations



The universe at your fingertips.

• LightWalker<sup>®</sup>

# Er:YAG-Laser—The key factor in the therapy of periimplant inflammations

Authors\_Jiaoshou (Prof.) Dr Frank Liebaug & Dr Ning Wu, Germany

## Introduction

Today, dental implants are widely accepted by patients and are seen as a desired therapy for the restoration of partly or wholly edentulous jaws. As a result, this therapy option is applied more and more often in the daily practice. It follows that the number of periimplantitis cases, an infection of the periimplant tissue, increases. Thus, periimplant inflammations will become more and more important for dentists in the future.

The prerequisite for the development of products for the prevention and therapy of periimplant disease is of course a sound knowledge of its aetiology, pathogenesis and epidemiology. The majority of early clinical studies used to judge the quality of treatment results by survival rates, with the implants remaining physically in the oral cavity. In the beginning, authors saw mechanical incidences as the reason for implant loss rather than biological causes. Today, the health status of periimplant tissues has become a focal point for implant survival. Although implant treatment is perceived to be generally successful, periimplant infections occur fre-

quently. These are called periimplant mucositis or periimplantitis. Much like periodontal diseases, periimplant diseases are of an infectious origin and can ultimately lead to the loss of the bone supporting the implant.

In periimplant mucositis, the inflammation is by definition restricted to the periimplant mucosa, while periimplantitis also includes the periimplant bone. For positive long-term results of implants as well as for the prevention and treatment of oral infections, these diseases must be monitored.

The available epidemiological data suggest that one in five patients will develop periimplantitis sooner or later, and that, in general, periimplant mucositis often occurs in implant patients. Currently, only limited data about the treatment of periimplant diseases are available. Most of the procedures are oriented towards periodontitis therapy. The most important therapy aim is infection control. This can include the adjustment of dentures, if their form impairs an adequate oral hygiene or the professional cleansing of the implant surface from biofilm and calcifications.

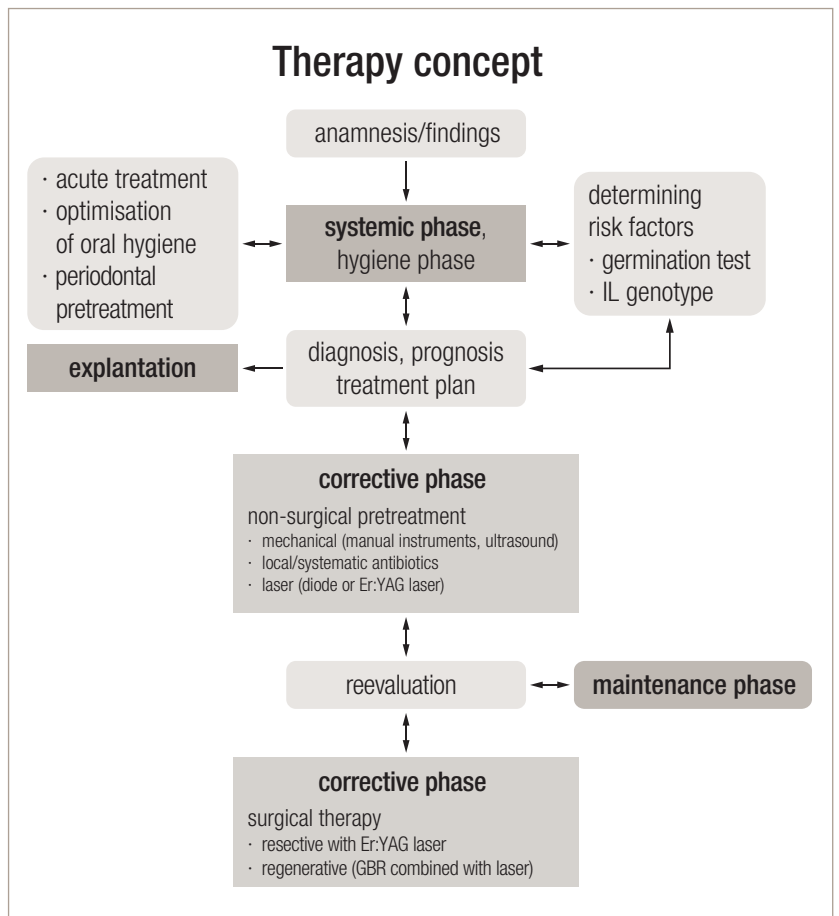
[PICTURE: ©2JENNI]

In advanced periimplantitis, a surgical procedure can be indicated in order to remove the biofilm. A regenerative treatment can be done in the course of those surgical procedures in order to replace lost bone. Therapy interventions in periimplantitis are still predominantly based on the clinical experience, as reliable clinical data have not yet been available. However, research activities in this field have been numerous and new data generated constantly, which is why more distinct guidelines for the treatment of those diseases can be expected.<sup>1</sup> Early diagnosis by periodontal probing and the evaluation of the health status of periimplant tissues are essential for the prevention of periimplant mucositis and periimplantitis. Early diagnostic identification permits early intervention, which can be clinically effective. If early symptoms are misjudged, a complex therapy is necessary, but may produce results which are less predictable.

### Aetiology and pathogenesis

The literature has proven that the presence of microorganisms is an essential prerequisite for the development of periimplant infections. We know today that glycoproteins from the saliva accumulate at the titanium surfaces of the implant or abutment which are exposed towards the oral cavity immediately after implantation. This glycoprotein layer is then colonised by microorganisms. A subgingival microflora forms within a short amount of time after implantation, which is dominated by *Peptostreptococcus micros*, *Fusobacterium nucleatum* and *Prevotella intermedia*. The majority of periimplant diseases are characterised by gram-negative, anaerobic microflora, which is found in a similar fashion in periodontitis. High concentrations of periodontal pathogens, such as *Aggregatibacter actinomycetemcomitans*, *Porphyromonas gingivalis*, *Prevotella intermedia*, *Tannerella forsythia* and *Treponema denticola*, have been detected in periimplantitis cases. Moreover, studies suggest that the microflora often contains *Fusobacterium nucleatum*, *Actinomyces* as well as *Staphylococcus aureus* and *enterococci*. *Staphylococcus aureus* also colonise other foreign elements, which, for example, may lead to complications in hip transplants. Titanium seems to promote the adhesion of *S. aureus*, which is often found in dental implants.<sup>1</sup>

The implant's soft tissue collar consists of an epithelial and a connective-tissue attachment. The epithelial periimplant mucosa, which consists of oral gingiva epithelium, oral sulcus epithelium and non-keratinised junctional epithelium corresponds largely with the epithelial tooth-mucosa contact. The connective-tissue attachment to the



implant is achieved via fibre bundles which are inserted in the marginal bone. They arrange themselves closely to the implant, parallelly and circularly to its surface. Other than the connective tissue surrounding the tooth, the supraalveolar connective tissue is deficient in cells as well as vessels. This leads to a reduction of the defense mechanisms against bacterial influences on the implant. Periimplant inflammations can thus spread faster than comparable inflammations of the periodontium. Missing desmodontal structures limit the defense capacities of the host organism to the vessel proliferation within the marginal soft-tissue collar, which leads to an increase in the manifestation of the clinical inflammation symptoms of the marginal soft tissue.

**Fig. 1** Sequence of a systematic therapy of periimplant infections.

There probably is a connection between the microflora present in the oral cavity during implanta-

**Table 1** Symptoms of periimplant infections.

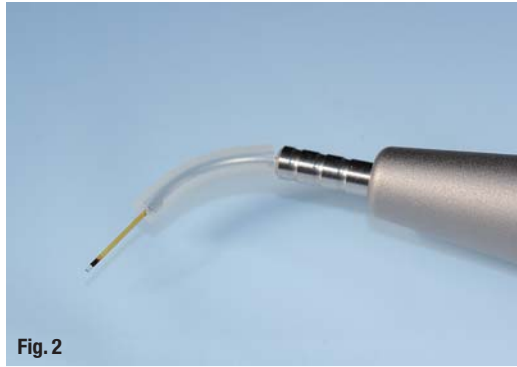mucositis	periimplantitis
bleeding on probing	bleeding and/or pus on probing
reddening and swelling	reddening and swelling
surface inflammation	probing > 4 mm
no loss of bone	loss of bone
slight pocket formation	increased pocket formation

**Fig. 2**\_Fibre tips.

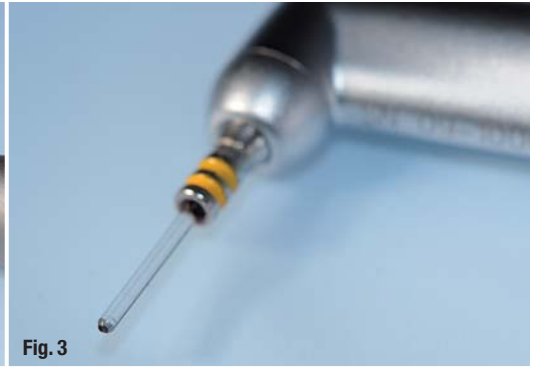**Fig. 3**\_Cylindrical fibre tip.

**Fig. 4**\_Window hand piece.

**Figs. 5 & 6**\_The patient presented with a loss of the implant-supported metal-ceramic bridge 35–37.



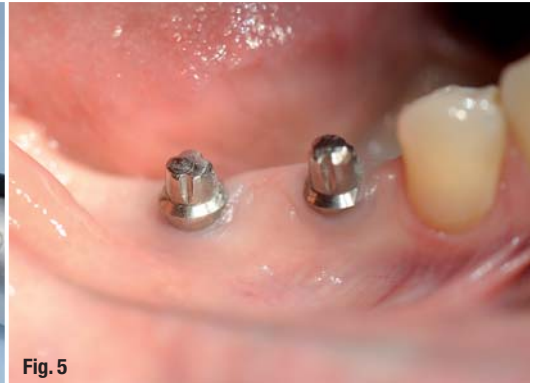**Fig. 2**



**Fig. 3**



**Fig. 4**



**Fig. 5**

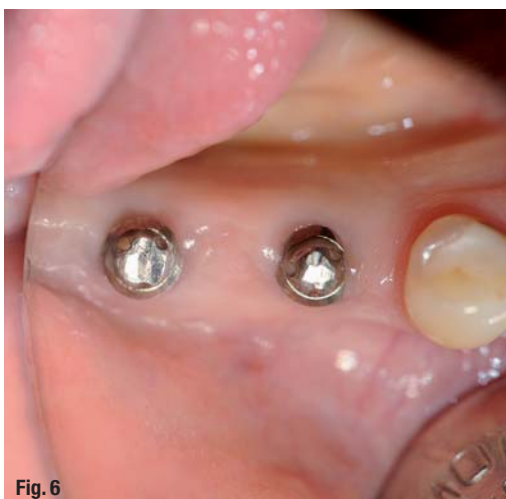tion and the biofilm which develops on the implant. Periodontal pockets can therefore function as a reservoir for microorganisms for natural teeth in the partially edentulous. The microorganisms then settle at the newly-placed implant.

**Periimplantitis: an inflammatory disease caused by infection (Tab. 1)**

- Microorganism colonise implants very shortly after insertion or uncovering of the implant in two-stage procedures.
- Implants are colonised by a microflora similar to that of natural teeth.
- Periodontally diseased teeth can function as a reservoir for pathogenic microorganisms.

- It is imperative that periodontally diseased teeth are treated before implantation.
- Due to the possibility of the pathogenic microflora being transferred from the periodontal lesions to the newly-placed implant, an implantation is contraindicated in cases of an active periodontal disease.

The periimplant mucosa around titanium implants has many things in common with the gingival tissues of natural teeth. Like the gingiva, periimplant mucosa forms a collar-like barrier, which adheres to the surface of the titanium abutment. Periimplant mucosa is a keratinised oral epithelium, whose collagen fibres start at the crestal bone and run parallelly to the implant surface. Similarly to natural teeth, the accumulation of bacterial plaque causes an infection in the periimplant mucosa and increases the probing depth. After longer contact with dental plaque, the periimplant lesion extends apically without being encapsulated by the collagen fibres as in periodontitis cases. The inflammatory infiltrate can extend to the alveolar bone or even the marrow spaces in periimplantitis, while it is separated from the bone by ca. 1 mm of non-inflamed connective tissue in periodontitis. This might explain the varying degree and configuration of the bone defects in periimplant inflammations.



**Fig. 6**

**Diagnosis with dental probe and X-ray**

Bleeding on probing as the clinical symptom which confirms mucositis occurs in up to 90% of functioning implants. Unfortunately, the definition





# Master of Science (M.Sc.) in Lasers in Dentistry

Batch: EN2014 - Fulltime (new) or Module based

Next Start: **21<sup>st</sup> September 2015**  
Aachen, Germany  
4 semesters

## Become part of the International Dental Elite

- Create new economic potential for your practice
- Two year career-accompanying postgraduate programme at the University of Excellence RWTH Aachen
- Combination of lectures, skill training sessions, live ops, tutorials, and practical workshops
- Internationally accepted and accredited by the German Government, the European Union, the Washington Accord and the Bologna Process
- Science-based and practice-orientated on highest national and international level
- Increased patient satisfaction: minimal contact reduced vibration and pain



**RWTH INTERNATIONAL ACADEMY**  
**AACHEN UNIVERSITY**

RWTH International Academy  
Kackertstraße 10 | 52072 Aachen | Germany  
phone +49 241 80 23543 | fax +49 241 80 92525  
info@academy.rwth-aachen.de  
www.academy.rwth-aachen.de

**PROFESSIONAL EDUCATION PROGRAMMES**



**Aachen Dental Laser Center**

AALZ GmbH  
Pauwelsstraße 17 | 52074 Aachen | Germany  
phone +49 241 47 57 13 10 | fax +49 241 47 57 13 29  
info@aalz.de  
www.aalz.de