

laser

the international c.e. magazine of laser dentistry

2²⁰¹²



C.E. article

Laser-assisted new
attachment procedure

trends

Lasers in endodontics

case report

Diode laser applications
in clinical orthodontics

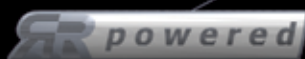The Dual Wavelength *waterlase**iPlus™

Advancing Laser Technology to Its Ultimate

INTUITIVE & INTELLIGENT GRAPHICAL USER INTERFACE

For example, performing a Class I Cavity Prep with the iPlus™ is as easy as 1,2,3...

- Step 1** Select "Restorative" from the first screen
 - Step 2** Choose "Class I" from the next screen that appears automatically
 - Step 3** Specify any other concerns such as patient sensitivity or bond strength
- That's it! Step on the foot pedal, and start working.*



BREAKS THE SPEED BARRIER

- + RR™ powered laser delivers 100 pulses/sec. for superior soft-tissue cutting
- + Patented laser technology delivers 10 watts of power
- + Enables multi-quadrant same-day procedures



ENABLES BIOLOGICALLY FRIENDLY DENTISTRY

- + No micro-fractures or thermal damage
- + More precise, minimally invasive

iLASE™ 940nm DIODE LASER DOCKING STATION

- + Adds dual wavelength versatility and convenience
- + First totally wireless dental laser
- + 5 Watts peak power with ComfortPulse™
- + Battery operated with finger switch activation
- + Exclusive bendable tips in many diameters & lengths

PROVIDES GREAT RETURN ON INVESTMENT

- + Increases treatment acceptance of day-to-day restorative cases
- + Attracts new patients
- + Increases productivity and enables new procedures



©2012

Need an answer?

Look to lasers ...



Torsten Oemus, Publisher
Dental Tribune International

Summer is upon us, and while many will be taking some well deserved vacation time, it's also an excellent time to reassess where you are with your practice. Do you need to make changes to improve your bottom line, such as purchase new equipment or hire a new staff member?

If you are looking to expand your armamentarium, then adding a laser to your practice should be your first consideration. If you already have a laser, have you thought about adding another one? The versatility of dental lasers coupled with their ease of use are just two of the most basic reasons to own one. From uses in general practice, implantology, endodontology and orthodontics, lasers have a place in every clinician's hand. Having been first introduced into dentistry in 1976, lasers have come a long way, and we hope this publication helps to keep you up to date with the latest research and trends. We've gathered experts from within the borders of the United States but also from around the globe to round out this publication and make the most of your reading time.

There is a nice variety of subjects in our C.E. articles within this edition, starting with the LANAP procedure and moving through to frenectomy and, finally, enamel alterations. After you read the articles, visit www.DTStudyClub.com to take the short quiz and earn one unit of ADA CERP-certified C.E. credit. Because this is a quarterly magazine, you'll have the opportunity to earn at least three more C.E. credits this year. Annual subscribers to the magazine (\$50) need only register at the Dental Tribune Study Club website to access these C.E. materials free of charge. Non-subscribers may take the C.E. quiz after registering on the Dental Tribune Study Club website and paying a nominal fee.

In this edition, a large international team brings you the word on research in regard to the effect of low-level laser therapy during rapid maxillary expansion. Similarly, the application of lasers in endodontics and orthodontics are also represented here.

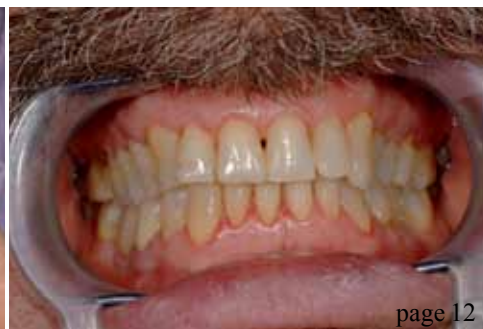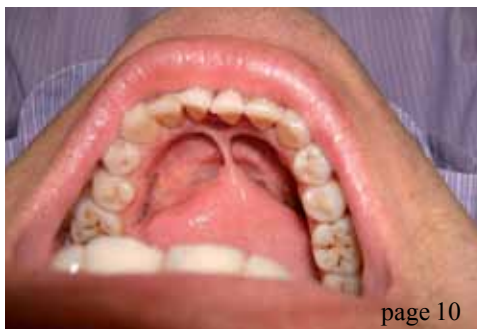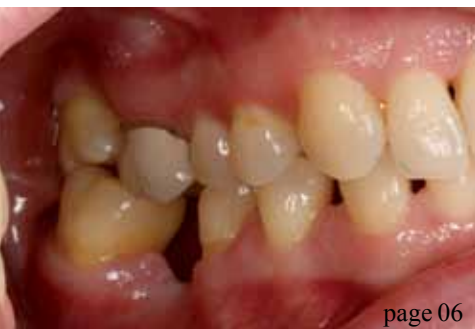Dental Tribune America is part of the largest dental publishing network in the world, Dental Tribune International (DTI), which consists of 23 DTI license partners around the globe publishing in 19 different languages. The DTI network publishes a variety of dental publications that are distributed in more than 90 countries. Please visit us online at www.dental-tribune.com to see the complete list of publications we offer, and at www.DTStudyClub.com to see the complete list of online and offline C.E. opportunities available.

If there is a topic you'd like to see covered in this publication, please don't hesitate to let us know by contacting us at feedback@dental-tribune.com. If you have questions, concerns, praise or a critique about some of the materials presented, we want to hear those comments too, so don't hold back.

Our goal with this publication is to make it a valuable return on your reading time, so if we can help improve that, we certainly want to know!

Sincerely,

Torsten Oemus
Publisher



C.E. article

- 06 Laser-assisted **new attachment procedure** (LANAP)
_David Kimmel, DDS
- 10 A good modality for the treatment of **prominent frenulum**
_Merita Bardhoshi, DDS; Esat Bardhoshi, DDS, MSc; and Ina Thereska, DDS, MSc
- 12 **Enamel** alterations
_Prof. Giuseppe Iaria, MD, DDS

research

- 14 The effect of low-level laser therapy during **rapid maxillary expansion**
_Eyad Hamade, DDS, MSc; Rwaida Saimeh, DDS, MSc; Mina Mazandarani, DDS, MSc; Maziar Mir, DDS, MSc, PhD; and Norbert Gutknecht, DMD, PhD

trends

- 18 **Lasers** in endodontics
_Enrico DiVito, DDS; Prof. Rolando Crippa, MD, DDS; Prof. Giuseppe Iaria, MD, DDS; Prof. Vasilios Kaitsas, DDS; Prof. Stefano Benedicenti, DDS; and Prof. Giovanni Olivi, MD, DDS

case report


- 27 Diode laser (810 nm) applications in **clinical orthodontics**
_Prof. Deepak Rai, MDS; and Prof. Gurkeerat Singh, MDS

industry

- 36 Dental lasers: Improving clinical results and **patient treatment acceptance**
_Anthony R. Cardoza, DDS
- 38 World's first **Android-based control screen** in the dental laser industry

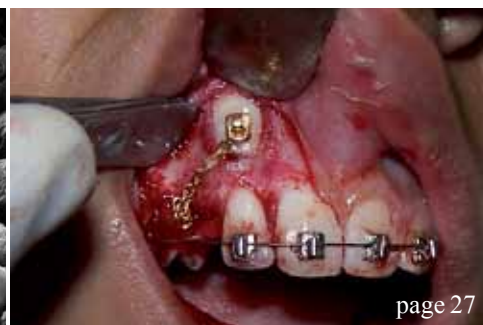
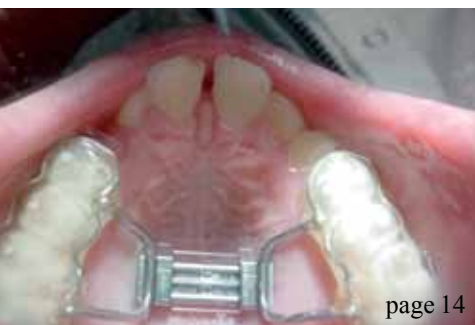about the publisher

- 40 _submissions
- 42 _imprint



on the cover

Cover image provided by Biolase



Technology **4** Medicine™

LIGHTWALKER

Dual Wavelength, Er:YAG & Nd:YAG

The 2 leading **LASERS**, 1 superior package. Invest Less. **Do More.**



Best of Class
Pride Institute

"red dot" Design Award 2012
Superior Design & Technology



red**dot**



Dentistry Today's
Top 100 Products

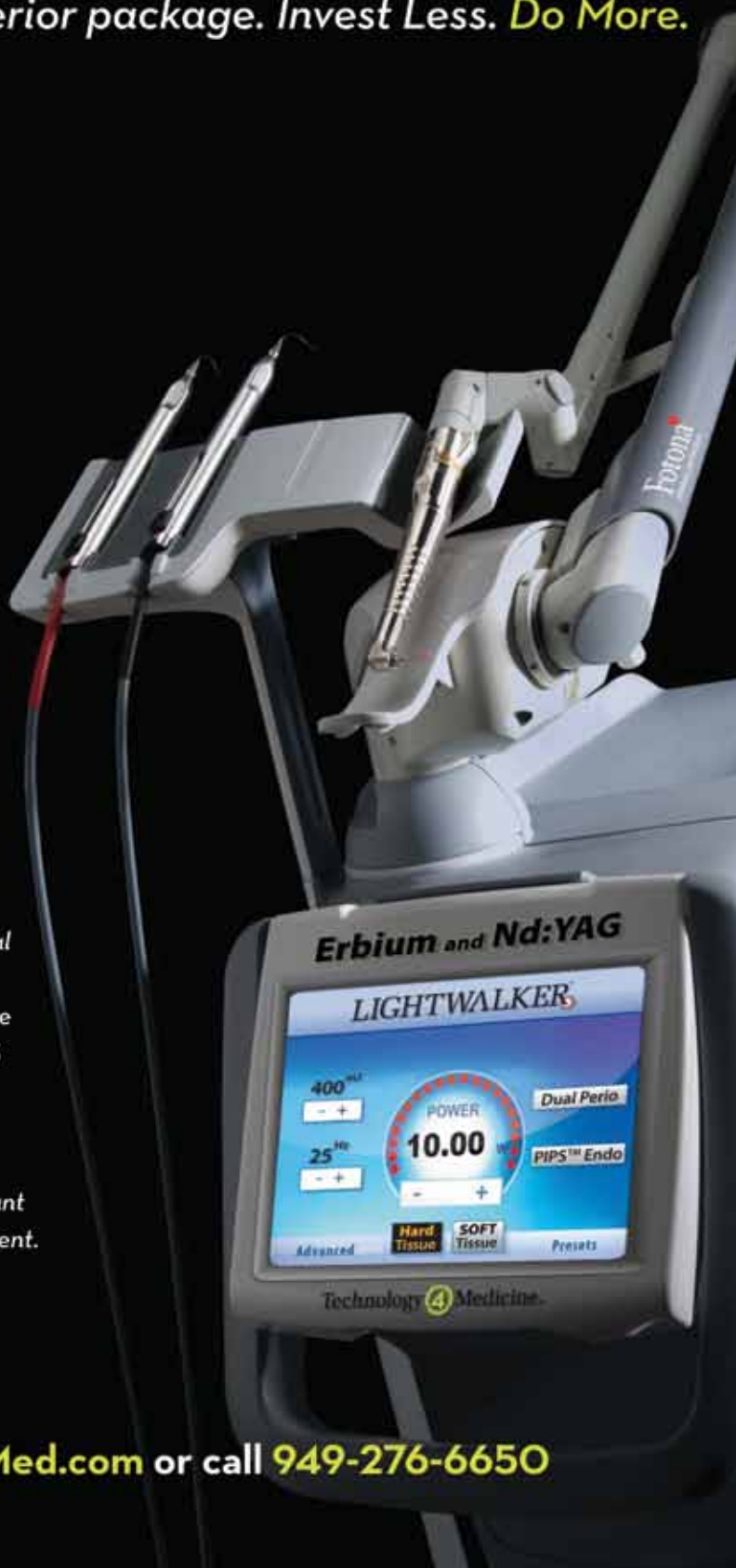PIPS™ - Photon Induced Photoacoustic Streaming™

A Dramatic Breakthrough in Endodontics
Available Exclusively with the Lightwalker

"I have been using PIPS for over a year on most of my cases. Herb Schilder stated that endodontic cases had the potential of 100% success minus X. The X factor being the complexity of the root canal system and the operator's ability to manage the cleansing and shaping of that system. I believe that PIPS enhances my ability to reduce this X factor to as close to 0 as is possible today. The Dual Wavelength LightWalker has also proven to be very valuable to my implant cases. Having both the Er:YAG and the Nd:YAG in one system is an important advancement which allows you to get more for your investment. I recommend this product without reservations."

Bryan M. Beebe D.D.S.
Endodontist, Sarasota, FL

For More Information, visit www.T4Med.com or call **949-276-6650**



Laser-assisted **new** attachment procedure (LANAP)

Author_David Kimmel, DDS

_c.e. credit part I

This article qualifies for C.E. credit. To take the C.E. quiz, log on to www.dtstudyclub.com.

A historical perspective of the development of the laser-assisted new attachment procedure (LANAP) is presented in this article. The simplicity of the protocol is discussed, as well as its nuances. The concept of LANAP was born back in 1989 with Drs. Robert Gregg II and Del McCarthy. As with most general dentists battling with the day-to-day realities of periodontal disease, they were looking for an answer on how to better care for their patients. The reality at the time was that periodontal disease was difficult to treat and maintain. It was primarily based on older concepts of wound debridement and amputation. Once treated, relapse was common.

We know periodontal disease is a multifactorial disease process and patient behavioural routines can play a significant role. It is a wonder that the conventional treatments worked as well as they did. Even when they did work, there often were significant secondary repercussions clinically as well as psychologically.

Clinically, many of these traditionally treated cases were difficult to restore whenever dental prosthetic treatment was needed and patients were often left with the compromised aesthetic result of a long tooth appearance.

Post-surgically, there was significant root surface exposure and with patients' increased life span and the

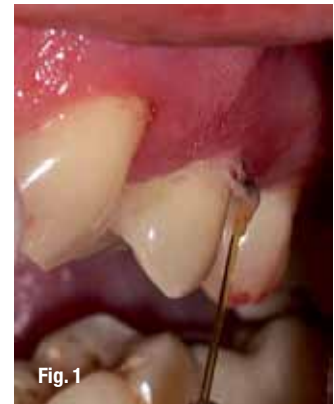

Fig. 1

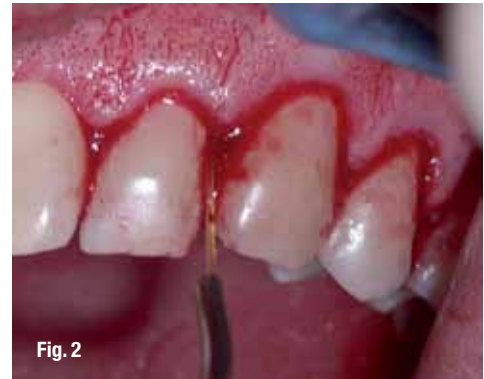

Fig. 2

Fig. 1_Selective thermal ablation of epithelium. (Photos/Provided by Dr. David Kimmel)

Fig. 2_Formation of the stable fibrin clot.

Fig. 3_Periodontal charting.

PERIO ACCESS®

ROCKETS - 1mm
ROCKETS - 2mm
ROCKETS - 3mm
ROCKETS - 4mm
ROCKETS - 5mm
ROCKETS - 6mm
ROCKETS - 7mm
ROCKETS - 8mm
ROCKETS - 9mm
ROCKETS - 10mm
ROCKETS - 11mm
ROCKETS - 12mm
ROCKETS - 13mm
ROCKETS - 14mm
ROCKETS - 15mm
ROCKETS - 16mm
ROCKETS - 17mm
ROCKETS - 18mm
ROCKETS - 19mm
ROCKETS - 20mm
ROCKETS - 21mm
ROCKETS - 22mm
ROCKETS - 23mm
ROCKETS - 24mm
ROCKETS - 25mm
ROCKETS - 26mm
ROCKETS - 27mm
ROCKETS - 28mm
ROCKETS - 29mm
ROCKETS - 30mm
ROCKETS - 31mm
ROCKETS - 32mm
ROCKETS - 33mm
ROCKETS - 34mm
ROCKETS - 35mm
ROCKETS - 36mm
ROCKETS - 37mm
ROCKETS - 38mm
ROCKETS - 39mm
ROCKETS - 40mm
ROCKETS - 41mm
ROCKETS - 42mm
ROCKETS - 43mm
ROCKETS - 44mm
ROCKETS - 45mm
ROCKETS - 46mm
ROCKETS - 47mm
ROCKETS - 48mm
ROCKETS - 49mm
ROCKETS - 50mm
ROCKETS - 51mm
ROCKETS - 52mm
ROCKETS - 53mm
ROCKETS - 54mm
ROCKETS - 55mm
ROCKETS - 56mm
ROCKETS - 57mm
ROCKETS - 58mm
ROCKETS - 59mm
ROCKETS - 60mm
ROCKETS - 61mm
ROCKETS - 62mm
ROCKETS - 63mm
ROCKETS - 64mm
ROCKETS - 65mm
ROCKETS - 66mm
ROCKETS - 67mm
ROCKETS - 68mm
ROCKETS - 69mm
ROCKETS - 70mm
ROCKETS - 71mm
ROCKETS - 72mm
ROCKETS - 73mm
ROCKETS - 74mm
ROCKETS - 75mm
ROCKETS - 76mm
ROCKETS - 77mm
ROCKETS - 78mm
ROCKETS - 79mm
ROCKETS - 80mm
ROCKETS - 81mm
ROCKETS - 82mm
ROCKETS - 83mm
ROCKETS - 84mm
ROCKETS - 85mm
ROCKETS - 86mm
ROCKETS - 87mm
ROCKETS - 88mm
ROCKETS - 89mm
ROCKETS - 90mm
ROCKETS - 91mm
ROCKETS - 92mm
ROCKETS - 93mm
ROCKETS - 94mm
ROCKETS - 95mm
ROCKETS - 96mm
ROCKETS - 97mm
ROCKETS - 98mm
ROCKETS - 99mm
ROCKETS - 100mm

Periodontal Exam Record

PATIENT: _____
DATE: _____
PERIO DIAGNOSIS: _____
PERIO CASE TYPE: _____
MED ALERT: _____

TOOTH #	EXAM TYPE	Comprehensive	Limited	Screening	Non-surgical	Post-Operative Evaluation
1	33	1	1	1	1	1
2	33	1	1	1	1	1
3	33	1	1	1	1	1
4	33	1	1	1	1	1
5	33	1	1	1	1	1
6	33	1	1	1	1	1
7	33	1	1	1	1	1
8	33	1	1	1	1	1
9	33	1	1	1	1	1
10	33	1	1	1	1	1
11	33	1	1	1	1	1
12	33	1	1	1	1	1
13	33	1	1	1	1	1
14	33	1	1	1	1	1
15	33	1	1	1	1	1
16	33	1	1	1	1	1
17	33	1	1	1	1	1
18	33	1	1	1	1	1
19	33	1	1	1	1	1
20	33	1	1	1	1	1
21	33	1	1	1	1	1
22	33	1	1	1	1	1
23	33	1	1	1	1	1
24	33	1	1	1	1	1
25	33	1	1	1	1	1
26	33	1	1	1	1	1
27	33	1	1	1	1	1
28	33	1	1	1	1	1
29	33	1	1	1	1	1
30	33	1	1	1	1	1
31	33	1	1	1	1	1
32	33	1	1	1	1	1
33	33	1	1	1	1	1
34	33	1	1	1	1	1
35	33	1	1	1	1	1
36	33	1	1	1	1	1
37	33	1	1	1	1	1
38	33	1	1	1	1	1
39	33	1	1	1	1	1
40	33	1	1	1	1	1
41	33	1	1	1	1	1
42	33	1	1	1	1	1
43	33	1	1	1	1	1
44	33	1	1	1	1	1
45	33	1	1	1	1	1
46	33	1	1	1	1	1
47	33	1	1	1	1	1
48	33	1	1	1	1	1
49	33	1	1	1	1	1
50	33	1	1	1	1	1
51	33	1	1	1	1	1
52	33	1	1	1	1	1
53	33	1	1	1	1	1
54	33	1	1	1	1	1
55	33	1	1	1	1	1
56	33	1	1	1	1	1
57	33	1	1	1	1	1
58	33	1	1	1	1	1
59	33	1	1	1	1	1
60	33	1	1	1	1	1
61	33	1	1	1	1	1
62	33	1	1	1	1	1
63	33	1	1	1	1	1
64	33	1	1	1	1	1
65	33	1	1	1	1	1
66	33	1	1	1	1	1
67	33	1	1	1	1	1
68	33	1	1	1	1	1
69	33	1	1	1	1	1
70	33	1	1	1	1	1
71	33	1	1	1	1	1
72	33	1	1	1	1	1
73	33	1	1	1	1	1
74	33	1	1	1	1	1
75	33	1	1	1	1	1
76	33	1	1	1	1	1
77	33	1	1	1	1	1
78	33	1	1	1	1	1
79	33	1	1	1	1	1
80	33	1	1	1	1	1
81	33	1	1	1	1	1
82	33	1	1	1	1	1
83	33	1	1	1	1	1
84	33	1	1	1	1	1
85	33	1	1	1	1	1
86	33	1	1	1	1	1
87	33	1	1	1	1	1
88	33	1	1	1	1	1
89	33	1	1	1	1	1
90	33	1	1	1	1	1
91	33	1	1	1	1	1
92	33	1	1	1	1	1
93	33	1	1	1	1	1
94	33	1	1	1	1	1
95	33	1	1	1	1	1
96	33	1	1	1	1	1
97	33	1	1	1	1	1
98	33	1	1	1	1	1
99	33	1	1	1	1	1
100	33	1	1	1	1	1

H&N Exam: _____
PCS: _____
Class: _____
Fracture in Gliding Movement: _____
in CO: _____

Fig. 3



Fig. 5



Fig.4 Pre-op CBT scan.

Table 1 The LANAP protocol.

This is then followed up by two more separate days of treating patients to refine techniques and add other treatment modalities utilising the Nd:YAG. Because of the simplicity, predictability and standardisation of LANAP, it has become a very safe and effective way to treat periodontal disease. The simplicity of the LANAP protocol can be seen in Table I.

_The LANAP protocol

Patients undergo a full dental examination and treatment plan—as with all dentistry. If they have an appropriate diagnosis of Type III or greater periodontal disease, all treatment options are presented to the patient. The initial step of the LANAP protocol, after anesthesia has been administered, is bone sounding around each tooth. The objective is to de-

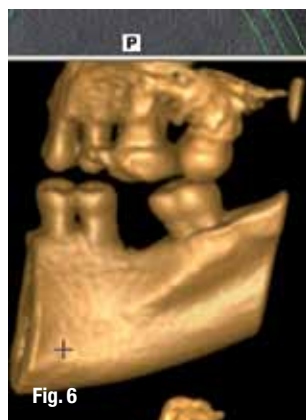


Fig. 6_CBT scan 15 months post-op LANAP.

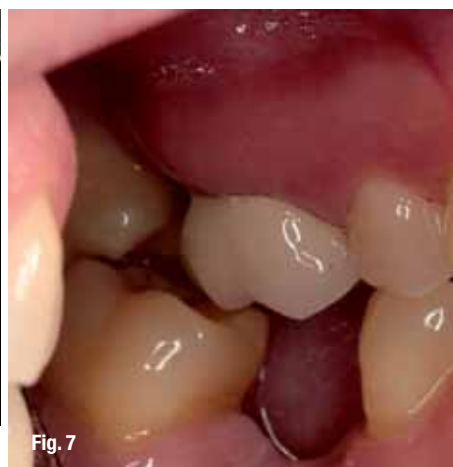

Fig. 7_Preop photograph.

termine areas of osseous defects that cannot be seen radiographically.

Step B

This is the first time the laser is used. The objective of this step is to remove only diseased epithelium, to affect selectively bacteria associated with periodontal disease, to affect the calculus present, and to affect thermolabile toxins. The bacteria that are associated with periodontal diseases are pigmented and are found in the sulcus, within the root surface and within the epithelial cells.

One of the reasons for the predictability of this step is in the selection of a free-running pulsed Nd:YAG laser with a wavelength of 1,064 nm and pulsed in a range of seven different microseconds. The shorter 1,064 nm wavelength was selected for its affinity for melanin or dark pigmentation, unlike the longer wavelengths that are highly absorbed in water and would have a shallow depth of penetration.

This ability to increase the depth of penetration of the laser energy with minimal collateral damage is the reason that the diseased epithelium can be selectively removed without damage to the underlying tissue, leaving intact rete pegs.

The diode lasers are also known for this selective absorption in pigmented tissues, but the free-running, pulsed Nd:YAG lasers differ in their ability to operate at very high peak powers in very short time-frames, which allows the Nd:YAG to have the greater depth of penetration and the lack of collateral damage (Fig. 1).

Step C

This step in the LANAP protocol is straightforward; it is just a matter of using the piezo-scalers to remove the calculus present on the root surfaces. The removal of calculus is believed to be easier after the interaction of the laser energy with the calculus. The first interaction of the laser results in the initial

formation of a mini-flap, thereby further assisting in the removal of calculus because of increased visibility and access to the calculus.

Step D

The next step again utilises the laser. This time the parameters are varied to enhance the ability to form a fibrin clot to close the mini-flap and to disinfect the site again. The formation of the stable fibrin clot is significant, as it is stable for approximately 14 days. The role of the fibrin clot is to keep the sulcus sealed against bacterial infiltration and to prevent the growth of epithelium down into the sulcus.

Other laser wavelengths not only lack the ability to form this stable fibrin clot, but also require repeated treatments to prevent epithelium growth down into the sulcus. The ability to select the laser-tissue interaction specifically is unique to the PerioLase MVP-7 (Millennium Dental Technologies).

Through the use of specific fiber sizes, energy, repetition rates, pulse durations and standardization of the energy at the fiber tip, this protocol can be followed in a predictable and reproducible manner. The high standard of training that each LANAP doctor receives also contributes to the predictability of this protocol and to its safety.

Patients often present with different tissue types along with different degrees of disease. One of the purposes of the hands-on training is learning to recognize these differences and how to change the laser parameters accordingly so that the desired laser-tissue interactions are achieved (Fig. 2).

Step E

The fifth step in LANAP is the compression of the fibrin clot to enhance the healing process. Because laser wounds heal by secondary intention, closer approximation enhances the healing time.

Step F

Following the compression and stabilisation of the clot, the last step of LANAP is refining the occlusion. Occlusion has been considered a greater co-factor in the progression of periodontal disease than smoking. In order to minimize this role, extensive adjustments are made to the dentition.

The patients are then followed for nine to 12 months with routine supra-gingival cleanings and occlusal refinements. No sub-gingival restorative or periodontal probing is done during this time. Only during the final post-operative visit is a periodontal probing done.

The results that are seen from LANAP treatment are very similar to the following cases, where new bone fill can be seen in vertical osseous defects. The bone fill ranges from simple proximal defects to the more complex furcation defects. The hallmark of

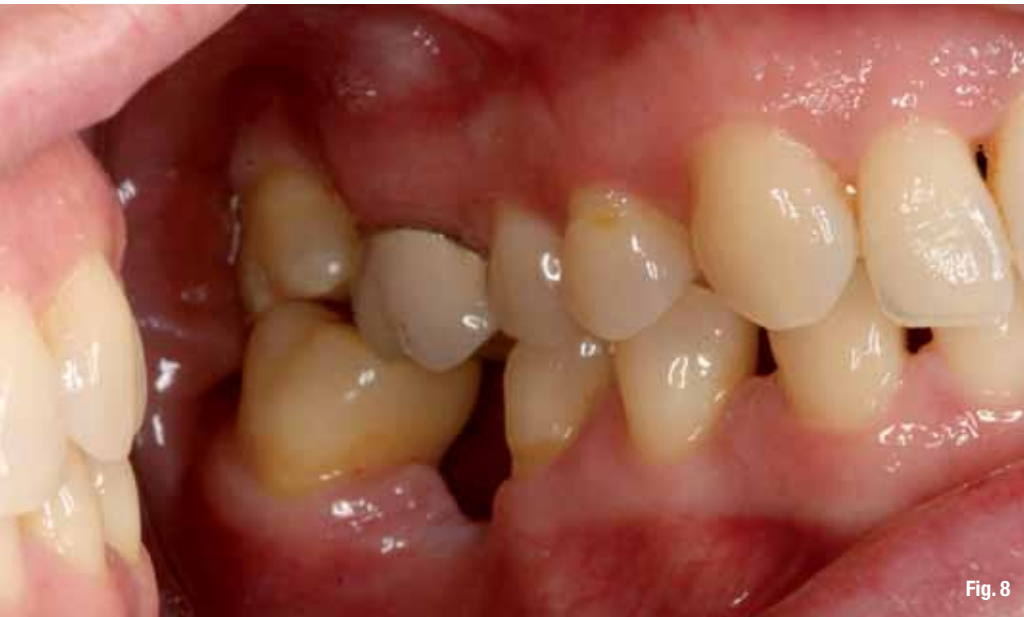

Fig. 8

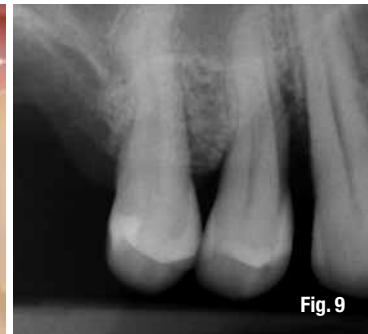

Fig. 9

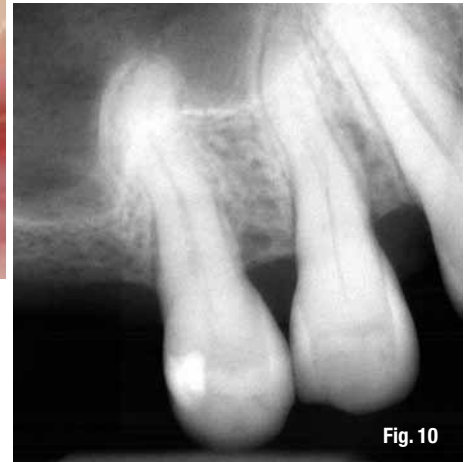

Fig. 10

LANAP is pocket reduction, new tissue attachment and a lack of tissue recession.

_LANAP case No. 1

The patient in this case was a 40-year-old female patient with a history of lupus, rheumatoid arthritis and Sjögren's syndrome. She was also a smoker. There was generalised deep pocketing as seen in her periodontal charting (Fig. 3).

The extent of the osseous defect is shown on the lingual view of the right quadrant preoperative CBT scan (Fig. 4). The initial post-LANAP evaluation was done at 15 months. Post-operative probing is shown in Figure 5.

The CBT from the lingual view of the right quadrant at 15 months post-operatively is shown in Figure 6. The change in the osseous defects is apparent. Minimal to no recession is shown in the preoperative clinical photograph in Figure 7 and the post-operative in Figure 8.

_LANAP case No. 2

The patient in this case was a 59-year-old male patient, with Type 1 diabetes and a smoker. His periodontal pocketing was 7 mm on the mesial second premolar. The preoperative X-ray is shown in Figure 9 and the 36-month post-LANAP X-ray in Figure 10. The 7 mm pocket had been stable and maintained at 3 mm for the last 36 months.

The LANAP protocol will be 22 years old this year. It is coming of age. It has stood the test of time. There are over 1,000 trained clinicians applying LANAP. They have all been standardized. The uniqueness of the protocol is that whether the doctor is new to LANAP or a veteran "LANAP'er," his results are similar.

During its early stages, early adopters accepted LANAP with anecdotal evidence alone, which was reinforced by the individual successes seen clinically. It was further validated by Dr. Ray Yukna's histological studies in 2003.

As the LANAP multicentre clinical studies move to completion, it would be reasonable to expect to see LANAP become the conventional manner or the standard for the treatment of periodontal disease. It is a very simple but eloquent protocol, one in which the patient has no to minimal discomfort and treatment acceptance is high.

Fig. 8_Post-op photograph.

Fig. 9_Preop X-ray.

Fig. 10_Post-LANAP X-ray at 36 months.

_about the author

laser



David Kimmel is a general dentist with a private practice that specializes in laser dentistry and facial enhancements. He holds a mastership from the World Clinical Laser Institute and is a certified instructor for the Institute for Advanced Laser Dentistry that teaches the LANAP protocol. He is also a faculty member for the American Academy of Facial Esthetics and is a

diplomat with American Board of Aesthetic Medicine. You may reach Kimmel at dkimmel@mac.com, (727) 862 8513 or www.floridacenterforlaserdentistry.com.

Editorial note: This article first appeared in the international magazine of laser dentistry, Vol. 3, No. 3, 2011.