


CAD/CAM

international magazine of digital dentistry

1 2011



| case report

Guided implantation without conventional impressions

| practice management

Six steps to a chartless practice

| industry report

Tizian CAD/CAM—No more one-way streets

IPS e.max[®]

**“THAT’S ALL
I NEED!”**

Galip Gürel, Dentist, Turkey.

Many different indications and many different materials to choose from – this scenario is a thing of the past. The IPS e.max system allows you to solve all your all-ceramic cases, from thin veneers to 12-unit bridges. Dental professionals all over the world are delighted.

all ceramic
all you need



www.ivoclarvivadent.com

Ivoclar Vivadent AG

Bendererstr. 2 | FL-9494 Schaan | Principality of Liechtenstein | Tel.: +423 / 235 35 35 | Fax: +423 / 235 33 60

ivoclar
vivadent[®]
passion vision innovation

Dear Reader,

Dental CAD/CAM technology has recently undergone enormous development. At the moment, it is the most innovative segment in dentistry and will again be the focal point of this year's International Dental Show (IDS), where plenty of manufacturers are going to showcase new systems and CAD/CAM solutions. While dental technology was the primary focus in the past, developers are now also looking at the manner in which these technologies can be applied to the dental practice. Digital impressions play a key role in this process. Manufacturers are currently making large investments in this technology and are thus able to constantly introduce new innovations. In this particular field—handheld systems for precise 3-D surface measurements—dentistry is the forerunner of all other engineering sciences, a fact that acknowledges the pioneer achievement of these developments.

While there was a level of caution with regard to the accuracy of full jaw scans, new clinical studies and trials confirm that intra-oral, 3-D systems now produce results that are almost comparable to conventional impression methods. In addition, handling and integration into the practice workflow have been developed to such a degree that these systems can now be used for the treatment of dental patients. Further examples are functional diagnostics with virtual articulators, implant treatment planning through the combination of DVT data and intra-oral scans that allow for chairside production of surgical guides, as well as facial scans serving as a base for a secure prosthetic planning.

However, CAD/CAM technology is not limited to the fabrication of dental restorations. Computerised dentistry is now also influencing other fields in dentistry, such as diagnostics, 3-D assessment and digital storage. Owing to these developments, complex approaches have become simplified and can better be integrated into the daily practice—all for the benefit of the patient. As a result of these new developments, which offer completely new opportunities for the daily workflow of the dental practice, dentists will have to become acquainted with these new technologies. Only well-educated dentists and dental technicians are able to assess the differences between the available systems and technologies. Just as studying material science enables confident handling of different materials, the basics of computerised dentistry must find their way into the dental curriculum. The upcoming IDS will prove that the time is ripe!

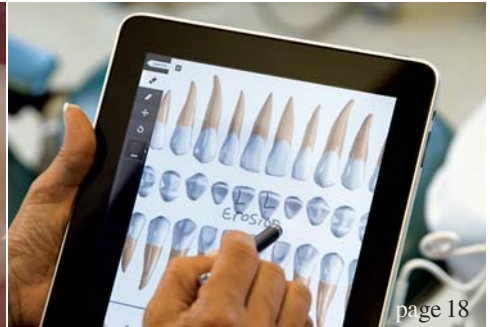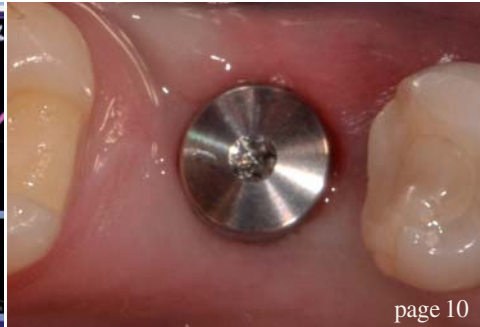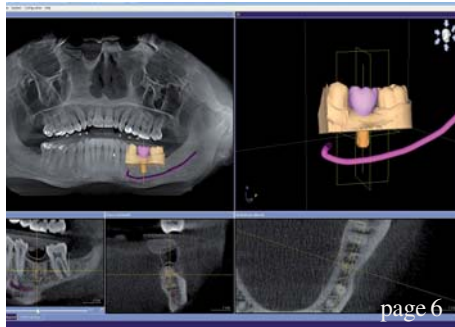
Yours faithfully,



Prof Albert Mehl
Center of Dental Medicine
University of Zurich



Prof Albert Mehl



| editorial

03 **Dear Reader**
| Prof Albert Mehl, Guest Editor

| opinion

06 **Safety-first implant therapy**
| Dr Neal S. Patel & Dr Jay B. Reznick

08 **25 years of proven clinical performance**
| Dr Dennis J. Fasbinder

| case report

10 **Guided implant placement** without conventional impressions
| Dr Jan-Frederik Güth *et al.*

| practice management

14 **Six steps to a chartless practice**
| Dr Lorne Lavigne

| news

18 **iPad in business: Advancing digital dentistry**
| Apple Inc.

| feature

20 An interview with **Hermann Loos**

| industry report

24 **For a perfect fit—CAD/CAM bar restoration on XiVE implants**
| Björn Roland & Dr Peter Gehrke

30 **From the patient's perspective: Design, implementation and prosthetics**
| Dr Götz Grebe & Dr Melanie Grebe

38 **Computer-aided crown design**
| Dr Andreas Bindl

40 **No more one-way streets**
| Thomas Dürr

| industry news

42 **ZENOTEC easy—Cost effective and professional**
| WELAND

43 **Sensible Dental** gets its **IPS e.max** on!
| Sensible Dental

44 **3Shape** releases **Dental System 2010**
| 3Shape

45 **R-SI-LINE METAL-BITE—Perfect bite registration**
| R-dental

46 **NewTom VGi** adds variable **FOV** feature
| ImageWorks

47 **White Peaks** Dental Systems
| White Peaks

| meetings

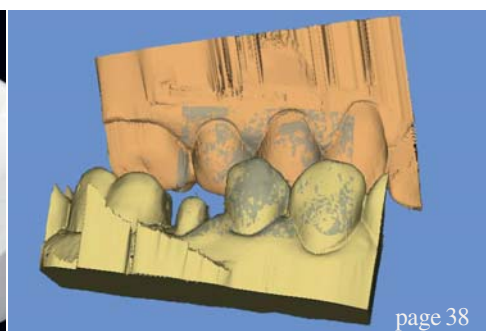
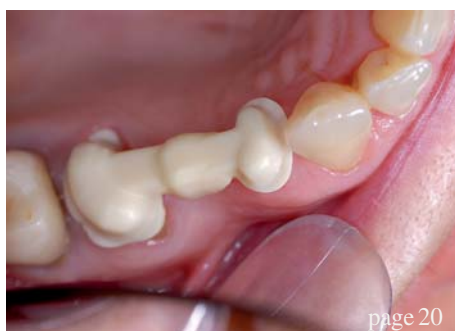
48 **International Events**

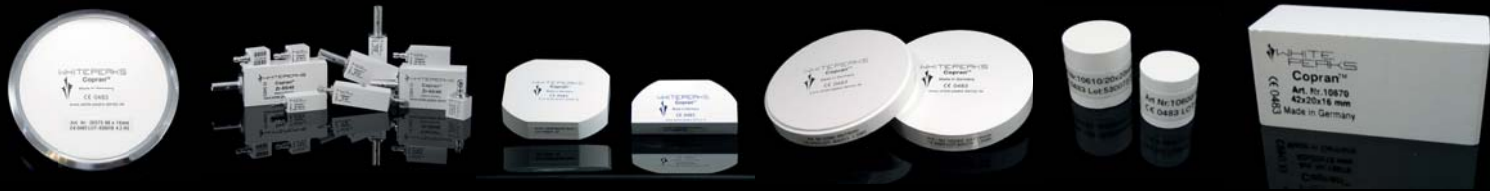| about the publisher

49 | submission guidelines
50 | imprint



Cover image courtesy of Schütz Dental GmbH, www.schuetz-dental.de.





WHITE PEAKS

DENTAL SYSTEMS

White Peaks Dental Systems

your specialist for zirconium blanks – Made in Germany – exclusively made from raw materials of Tosoh – Japan.

Zirconium colouring liquids in 16 classic shades, chrome-cobalt, titanium, C€-certified PMMA blanks, PMMA and wax blanks, Calidia CAD/CAM milling systems, free CAM software and scanners.

We are certified to the highest standards of C€, US-FDA and DIN ISO 13485



34. Internationale Dental-Schau
34th International Dental Show
COLOGNE, 22. –26.3.2011

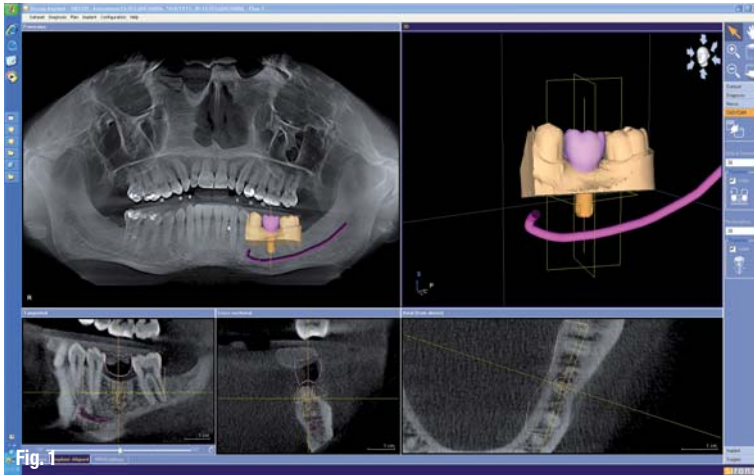
Besuchen Sie uns!
Visit us!
Hall: 11.1 / Aisle: A
Stand: 059

White Peaks Dental Systems GmbH & Co. KG,
Langeheide 9, D-45239 Essen, Germany
www.white-peaks-dental.com
info@white-peaks-dental.com



Safety-first implant therapy

Authors_ Dr Neal S. Patel & Dr Jay B. Reznick, USA



and the dentist. In some cases, patients do not return after being referred. In addition, the diagnostic results are sometimes delayed and the reports are not directly assigned to the X-ray images. Referrals to external radiologists tend to disrupt the patient counselling process. Experience has shown that patients rate the expertise of a dental practice more highly when all services come from a single source and when the dentist is directly involved in the diagnosis of the X-rays. The higher costs of a CBCT image compared with a conventional panoramic X-ray can easily be justified by the clear diagnostic and therapeutic benefits. A convincing argument is that a CBCT contains 300 MB of information, compared with only 5 MB in the case of a digital panoramic X-ray.

Fig. 1_3-D-scan of GALILEOS with imported CEREC crown.

_Cone-beam computerised tomography (CBCT) systems number amongst the most advanced imaging devices that are currently available on the market. The insight into the third dimension simplifies diagnostic procedures, enhances treatment safety and reduces radiation doses for patients. In addition, there are convincing forensic arguments in favour of CBCT. With the aid of 3-D CBCT images, users can interpret the clinical situation with much greater accuracy. They can evaluate the optimum drilling angles for various perspectives (sagittal, coronal, axial) and generate transversal slices and panoramic images. Compared with conventional CTs, CBCT systems are less sensitive to metal artefacts. Thanks to the availability of 3-D imaging, dentists are in a better position to assess the risks of treating certain cases in-house. In addition, CBCT users can create digital networks with their colleagues and advertise their services to referring dentists.

An important reason for purchasing a CBCT system is the time and effort involved in referring patients to external radiologists, both for the patient

Implant planning using GALILEOS and CEREC reduces the number of appointments. Less laboratory work is required. In most cases, it is not necessary to produce waxed-up prosthetic reconstructions. The combination of digital imaging and CAD generates all the necessary information for the dental laboratory, thus ensuring transparent working procedures. The decisive factor is that the integration of GALILEOS and CEREC streamlines the dentist's workflow and leads to reliable clinical results.

_Enhanced clinical reliability...

A very useful feature of the GALILEOS system is the built-in implant database, which contains the dimensional data of various commonly used endosseous posts (Astra, Straumann, BIOMET 3i, Bicon, BioHorizons and Z-Look). By combining the GALILEOS image, the clinical CEREC scan and the virtual superstructure design, the user can dispense with a prosthetic wax-up model (Fig. 1). Instead, a template is used that is easily fixated in the patient's mouth (Fig. 2). The prosthetic planning is carried out fully

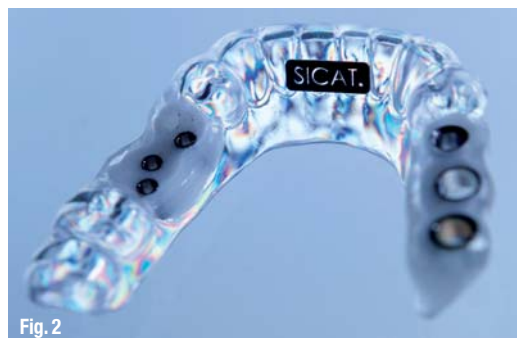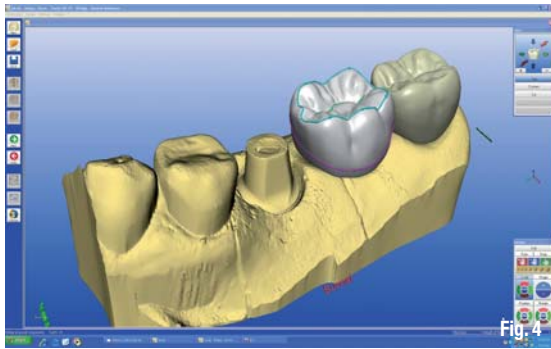


Fig. 2

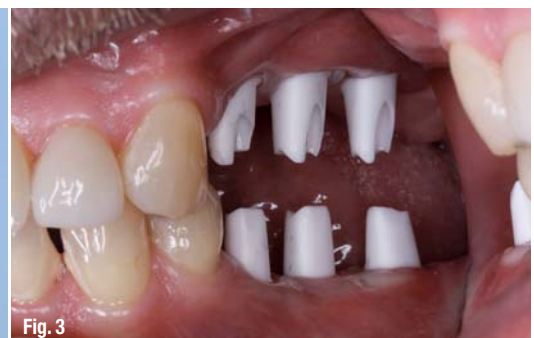
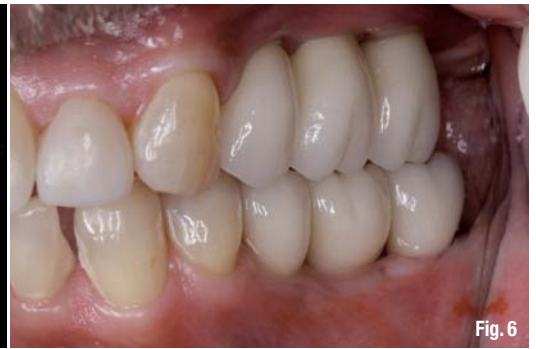
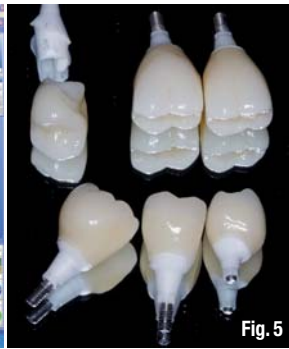Fig. 3

Fig. 2_SICAT surgery guide.
Fig. 3_Inserted ZrO₂ abutments.



digitally by using the CEREC software. Thereafter, the prosthetic planning data is imported into the CBCT scan, eliminating both the need to create an X-ray template and to form a barium-sulphate prosthetic model. This leads to results that are more precise. Moreover, since no barium sulphate is used, the CBCT image is of good quality. The positions of the endosseous drill holes are determined by means of plastic surgery guides (SICAT/Sirona). Minimally invasive flapless implantation eliminates the need for the elevation of the mucoperiosteal flap. This not only minimises surgical trauma, but also permits the immediate placement of the restoration on the implant.

...and less laboratory work

The ability to import the CEREC data into the CBCT image significantly streamlines the implant planning workflow. The interaction between GALILEOS and CEREC means that only two appointments are required, at an interval of five to seven days. Thanks to the surgery guide, the invasive surgical insertion of the endosseous post takes only 15 minutes, resulting in greater precision and reduced stress. Using the conventional method (that is, without a CBCT scan and surgery guide) each implant requires up to 45 minutes and is accompanied by greater risks.

Thus far, custom-made angled abutments with individual emergence profiles have often been required in order to compensate for divergences in the insertion angles between the implants and the superstructures. Thanks to the integrated implant planning process, it is now possible to deploy competitively priced, industrially prefabricated abutments (Fig. 3). The precise planning of the angulation in the CBCT image and the guided drilling process ensure a better fit between the endosseous post and the superstructure. If required, specially shaped abutments can be created out of zirconium oxide (ZrO₂) using the inLab system.

As a rule, the implants are luted directly to single-tooth implants. In order to protect the gingiva, over-pressed luting residues must be carefully removed. Following the attachment of the abutment and the

closure of the screw access, it is advisable to place a retraction cord in order to expose the tissue and the abutment margin. The abutment is then conditioned with titanium powder in preparation for acquiring the intra-oral impression using the CEREC AC and designing the final implant crown (Fig. 4). The crown is then automatically milled to anatomical dimensions out of a lithium disilicate (LS₂) block (IPS e.max CAD, Ivoclar Vivadent). The try-in should be performed prior to crystallisation. This is followed by crystallisation, polishing/glazing and luting to the abutment (Fig. 5). If stringent aesthetic requirements have to be fulfilled (for example, in the anterior region) the LS₂ crown can be cut back and then individually veneered (Fig. 6).

Fig. 4 Screenshot of CAD construction for implant crowns.
Fig. 5 LS₂ crowns adhesively luted to the abutments.
Fig. 6 Implants with supra-structures *in situ*.

_Conclusion

To a significant extent, GALILEOS and CEREC simplify implant planning and superstructure fabrication. The clinical outcomes are predictable. Compared with conventional methods, treatment is much faster. The 3-D images and the virtual prosthetic proposal play a valuable role in patient counselling. In addition, there is an increased likelihood that the patient will accept the plausibility of the proposed treatment and give his or her consent more quickly.

_about the authors CAD/CAM



Dr Neal S. Patel operates a dental practice in Powell, Ohio. He is a CEREC user, as well as an Advanced Trainer for the GALILEOS CBCT system.



Dr Jay B. Reznick runs a dental practice in Tarzana, California. He specialises in implantology, as well as tooth and skin transplants.

25 years of proven clinical performance

Author_Dr Dennis J. Fasbinder, USA

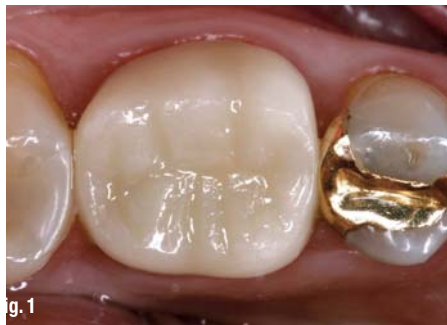

Fig. 1 LS₂ crowns after the two-year recall visit.

In 1985, Prof Werner Mörmann, Dr Marco Brandestini and their team laid the foundations for a new treatment system consisting of optical impression-taking, CAD and numerically controlled milling. This new concept motivated large numbers of clinicians and prompted them to carry out their own follow-up investigations. Today, CEREC is one of the most closely scrutinised dental procedures, a fact reflected in more than 250 clinical studies and approximately 6,500 longitudinal studies of restorations.

Long-term observations indicate that adhesively bonded restorations fabricated using the first versions of the CEREC system (CEREC 1 and 2) achieved higher survival probability rates (according to Kaplan–Meier) than conventional layered ceramic restorations. CEREC restorations with service times in excess of 20 years still display a degree of clinical excellence, which is normally attributed to metal-based restorations. On the basis of this extensive long-term experience, there are convincing reasons for recommending CEREC-fabricated inlays, onlays, partial crowns, veneers, anterior crowns and posterior crowns as an alternative to conventional metal-based restorations.

Immediate treatment stabilises enamel

The goal was to deploy CAD/CAM technology to create immediate all-ceramic restorations chairside without the need for temporaries. Clinical experience has demonstrated that provisionally restored inlay cavities have a significant, negative influence on the integrity of the enamel. In the course of chewing simulations, cracks occurred in the oral and vestibular enamel surfaces. In addition, spalling was observed at the enamel margins. Such defects did not occur in cavities that had been treated immediately using chairside CEREC inlays. The conclusion was clear: the immediate treatment of the tooth cavity with chairside inlays and the elimination of the need for a temporary restoration reduce the risk of enamel cracking and marginal spalling. The micromechanical bond between the ceramic inlay and the hard tooth

tissue stabilises the cavity walls. In combination with the adhesive bond, the stabilising effect of the immediate CEREC restoration on the residual tooth obviously offsets the consequences of wider adhesive gaps, as evidenced in long-term clinical findings.

High-strength CEREC crowns

So far, long-term investigations have concentrated almost exclusively on CEREC crowns made of feldspar ceramic materials. At the School of Dentistry, University of Michigan, we set out to investigate the material suitability of lithium disilicate (LS₂, IPS e.max CAD, Ivoclar Vivadent) for full contour, monolithic crowns. Our aim was to utilise the enhanced flexural strength of LS₂ (360–400 MPa) in order to withstand the chewing forces in the premolar and molar regions. The full crown preparation included 2.0 mm functional cusp reduction, 1.5 mm occlusal reduction in the central fissure in combination with rounded shoulders and axial reduction of 1.2 mm. Using the CEREC 3 system, 62 crowns were created for 43 patients and then placed with the aid of dual-cure luting cement. There was a small degree of sensitivity reported in the first week post-operatively. This had subsided by the third week and there were no reports of sensitivity at the one- or two-year recall evaluation. After two years of clinical service, there were no clinically identified cases of crown fracture or surface chipping. Clinical monitoring revealed a positive long-term survival prognosis. Although two years *in situ* is a relatively short period of time, the survival rates are on par with those obtained in similar studies of ceramic crowns (Fig. 1).

about the author

CAD/CAM

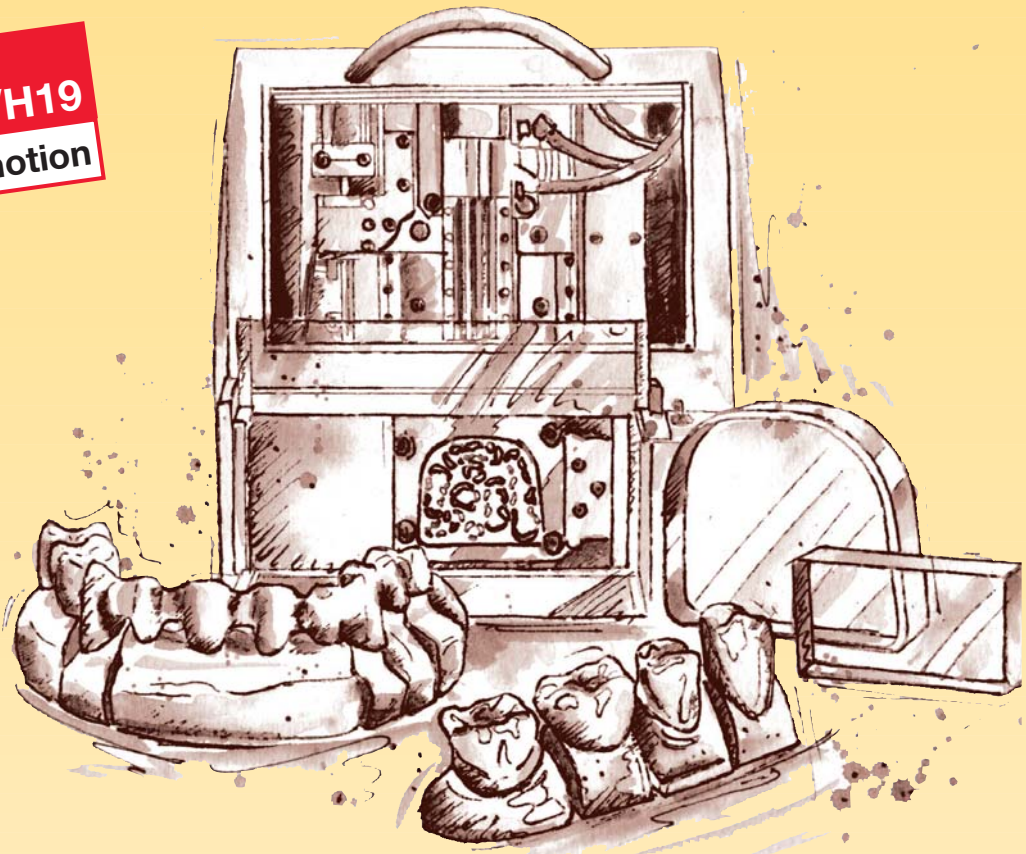



Dr Dennis J. Fasbinder

is Clinical Professor in the Department of Cariology, Restorative Sciences and Endodontics at the University of Michigan.

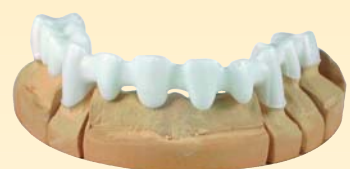
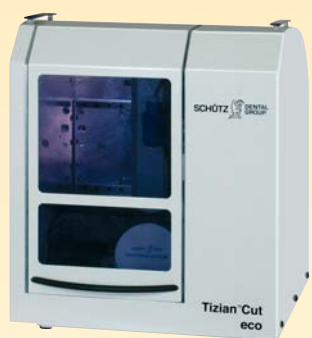
IDS hall 10.1
booth G10/H19
Visit us for special promotion



CAD/CAM - The right solution for you

Smaller, faster, better



Tizian™ Scan 102

- highly precise scan results
- works with virtual articulator

Tizian™ Creativ RT

- fast & easy CAD
- abutment designer
- exporting open STL data

Tizian™ Cut Eco plus

- 4 axes milling
- „Jäger” spindle

For more information, please visit our homepage
www.schuetz-dental.de
or request our catalog!



German Quality