

implants

international magazine of oral implantology

3²⁰¹⁰



| **research**

Timing of dental implant loading

| **case report**

Piezoelectric repositioning of the inferior alveolar nerve

| **meetings**

1st Hvar International Dental Congress



SAVE CELLS

NEW EMS SWISS INSTRUMENTS SURGERY – SAVING TISSUE WITH NEW INNOVATIONS IN IMPLANT DENTISTRY

The inventor of the Original Piezon Method has won another battle against the destruction of tissue when dental implants are performed. The magic word is dual cooling – instrument cooling from the inside and outside together with simultaneous debris evacuation and efficient surgical preparations in the maxilla.

COOLING HEALS

A unique spiral design and internal irrigation prevent the instrument's temperature from rising during the surgical procedure. These features combine effectively to promote excellent regeneration of the bone tissue.

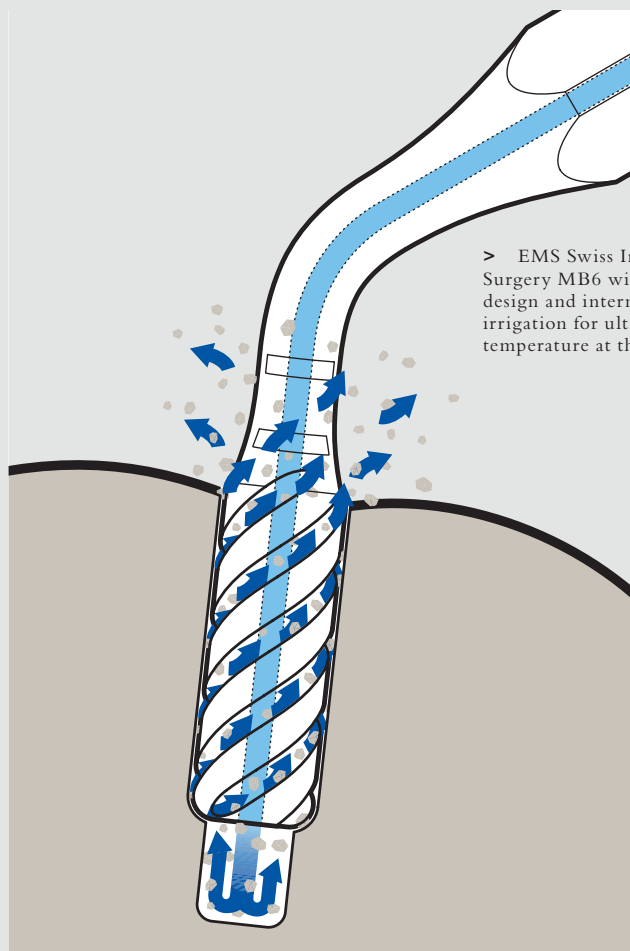
EMS Swiss Instruments Surgery MB4, MB5 and MB6 are diamond-coated cylindrical instruments for secondary surgical preparation (MB4, MB5) and final osteotomy (MB6). A spiral design combined with innovative dual cooling makes these instruments unique in implant dentistry.

CONTROL SAVES

Effective instrument control fosters atraumatic implant preparation and minimizes any potential damage to the bone tissue.

PRECISION REASSURES

Selective cutting represents virtually no risk of damage to soft tissue



> EMS Swiss Instrument Surgery MB6 with unique spiral design and internal instrument irrigation for ultralow temperature at the operative site

(membranes, nerves, blood vessels, etc.). An optimum view of the operative site and minimal bleeding thanks to cavitation (hemostatic effect!) further enhance efficacy.

The new EMS Swiss Instruments Surgery stand for unequaled Swiss precision and innovation for the

benefit of dental practitioners and patients alike – the very philosophy embraced by EMS.

For more information >
www.ems-swissquality.com



Celebrating 40 Years of DGZI in Berlin



Dr med dent Roland Hille

“Nobody could have imagined in 1970 what a success story oral implantology would turn out to be, when seven dentists, headed by Prof Dr Hans L Grafelmann, a dentist from Bremen, founded DGZI. In spite of various negative opinions, mainly from universities, this then-adventurous therapy was established in Germany against the mainstream, thanks to a great deal of perseverance and conviction, an incredible drive and much operative skill. There were a growing number of colleagues who were fascinated by the possibility of fixing dental prostheses on implanted new dental roots, a process which could give patients the feeling of no longer being handicapped.

40 years ago the obligatory tooth conserving methods were incomparable to current means and methods. Thus many patients, especially those with edentulous jaws, could achieve a completely new quality of life courtesy of intraosseous or subperiosteal implants. Let us remember: At that time, we did not have any bone substitutes, membranes etc. at our disposal, all of which are considered absolutely standard today. For the past four decades oral implantology has greatly influenced dental rehabilitation measures, and has without question become the most innovative discipline in dento-maxillo-facial medicine in the last 25 years.

On September 24, 1982, the DGZMK (German Association for Dento-Maxillo-Facial Medicine) approved implantology as a new method for use. Oral implantology also became scientifically in vogue, when universities intensified their research activities, and industrial companies sensed a new market with adequate financial resources.

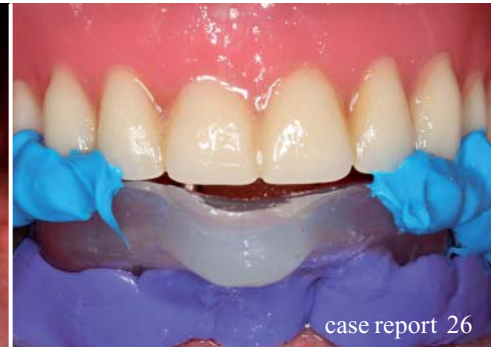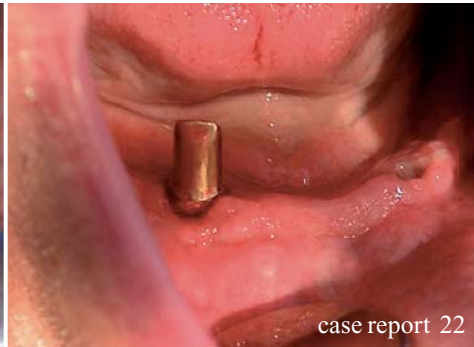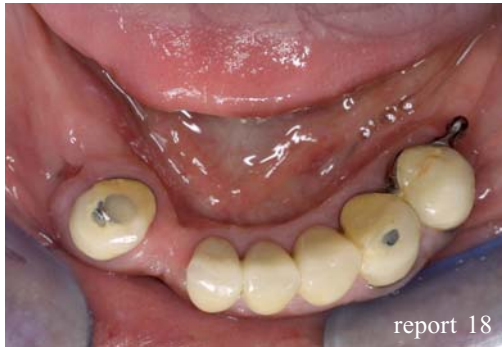In the beginning scientific journals referred to implantology as “the red light district in dental medicine”, but nowadays there is no doubt about the important role which this subdiscipline plays in dentistry. Patients actively request this therapy, and any colleagues who underestimate the importance of implantology for the success and future for their own dental practices will be left behind.

DGZI has achieved significant accomplishments in education and advanced training, as up until now university education has not attached that much value to implantology. A postgraduate structured educational program has existed since 1998, which almost 1,500 colleagues have participated in and have learned from implantology specialists and university professors about the state of the art in implantology. Patients increasingly ask for treatment by a “DGZI Specialist in Implantology”, because such specialists often have much more operative skills than those colleagues who obtained a masters degree.

40 years of DGZI is truly a great milestone in Europe's oldest scientific implantological association, an association which also enjoys an extraordinarily good reputation nationally and internationally. The Consensus Conference for Implantology congratulates DGZI heartily and wishes all its members much success and an exciting future in oral implantology.

I hope to see you on the occasion of our anniversary congress on October 1 and 2 in Berlin.

Dr med dent Roland Hille
President of the Consensus Conference for Implantology



| editorial

- 03 Celebrating **40 Years of DGZI** in Berlin
| Dr Roland Hille

| research

- 06 **Timing** of dental implant loading
| Dr Marius Hary Silvasan

| report

- 18 Lateralization of the **inferior alveolar nerve**
| Dr Bernd Quantius

| case report

- 22 **Piezoelectric repositioning** of the inferior alveolar nerve
| Dr Burghard Peter
- 26 **Success** without using cement
| Dr Christoph Thiemann, Friedrich Schotsch

| study

- 28 **Comparing** various implant designs and surfaces
| Dr Roy Leshem, David Leshem

| meetings

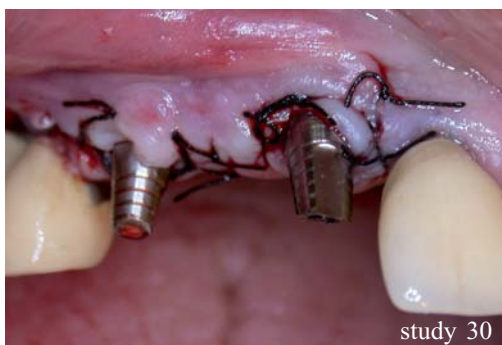- 34 **International** events 2010/2011
- 36 **1st Hvar** International Dental Congress
- 38 **EAO** Congress—Glasgow 2010
- 40 **Osteology** in Cannes
| Dr Birgit Wenz
- 42 **3rd International CAMLOG** Congress

| news

- 44 **Manufacturer** news
- 48 **Congratulations** and **Happy Birthday** to all DGZI-members around the world

| about the publisher

- 49 | submission guidelines
- 50 | imprint



NobelActive™

A new direction for implants.

Dual-function prosthetic connection.

Built-in platform shifting.

Bone-condensing property.

High initial stability, even in compromised bone situations.

Adjustable implant orientation for optimal final placement.



10 YEARS WITH
TIUNITE® SURFACE
New data confirm
long-term stability.

NobelActive equally satisfies surgical and restorative clinical goals. NobelActive thread design progressively condenses bone with each turn during insertion, which is designed to enhance initial stability. The sharp apex and cutting blades allow surgical clinicians to adjust implant orientation for optimal positioning of the

prosthetic connection. Restorative clinicians benefit by a versatile and secure internal conical prosthetic connection with built-in platform shifting upon which they can produce excellent esthetic results. Based on customer feedback and market demands for NobelActive, the product assortment has been expanded – dental professionals

will now enjoy even greater flexibility in prosthetic and implant selection. Nobel Biocare is the world leader in innovative and evidence-based dental solutions. For more information, visit our website

www.nobelbiocare.com

Timing of dental implant loading

A Literature Review

Author_Dr Marius Hary Silvasan, Romania

_Osseointegration is the process by which living bone attaches to the artificial surface of an implant by the formation of bony tissue without growth of fibrous tissue at the bone-implant interface.

_Introduction

Osseointegration is a highly dynamic process, which does not only address the formation of bone onto an implant surface after it has been placed, but it also addresses the remodelling or maintenance of bone during the life of the implant.

The long term success of an implant treatment is theoretically determined by factors related to the pa-

tient, the implant components and the treating clinicians.¹ Before the introduction of the Prof. Brånemark protocol, dental implants were commonly loaded at placement because immediate bone stimulation was considered to avoid crestal bone loss (Fig.1).² The clinician is often faced with the challenge of identifying the successful osseointegration of implant. Clinical success is often determined by a lack of mobility and ability of the implant to resist functional loading.³

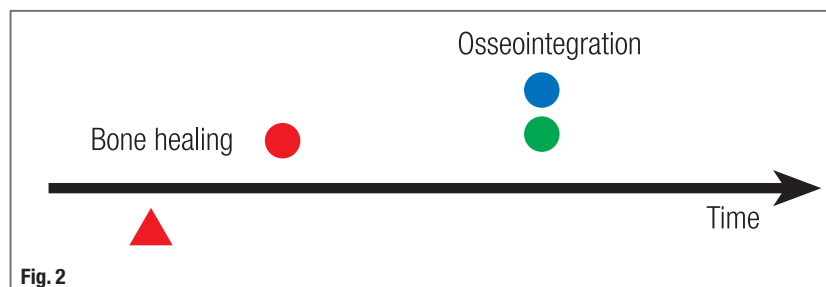
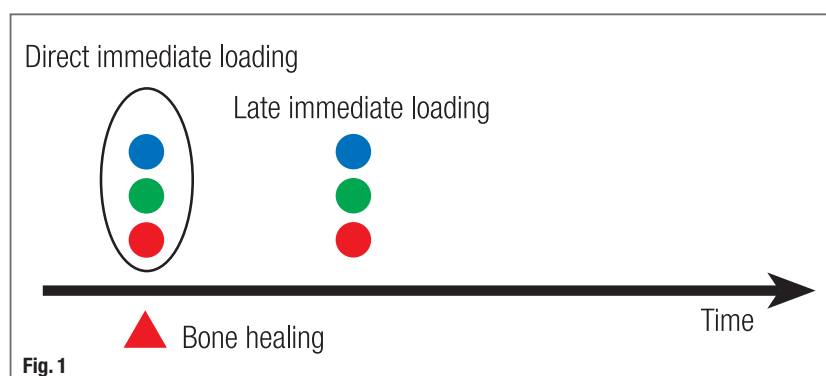
Radiographically, bone should appear to be closely apposed to the implant surface. The current achievable resolution obtained in medical imaging, however, is about 10 times less than what is required to observe a soft tissue cell. Therefore, radiographic assessment alone is unsuitable to determine with certainty if a soft tissue layer is present. When an implant is exposed to excessive micromotion at the bone-implant interface during healing, fibrous tissue encapsulation of the implant rather than osseointegration may occur. Conventional implant protocols have been based on the achievement of primary stability and prolonged non-loaded healing periods (Fig. 2).⁴

That was achieved by a two stage technique and an unloaded healing period of three to six months. Delayed implant loading was empirically based on the belief that the transfer of any micromotion to the implant surface during healing would result in fibrous encapsulation rather than osseointegration. A perceived psychological, economical and functional advantage of shortened treatment periods has encouraged clinicians to challenge this convention with immediate temporization (Fig. 3) and/or the early and immediate loading of dental implants.

The relative merits of these shortened loading protocols will be discussed with respect to their biologi-

Fig. 1 Direct loading at placement and delayed loading after bone healing.

Fig. 2 Conventional implant protocol without any loading performing the prosthetic in part after bone healing (e.g. Brånemark protocol).



cal implication, the current evidence based literature and the factors that might influence their outcomes. There is a growing body of published literature supporting reduced implant loading times. Abutment connection and placement of a restoration in occlusion with the opposing dentition of an implant at the time of surgery or within 48 hours of placement is referred to as "immediate loading". The functional restoration of an implant from 48 hours up to 3 months after placement has been defined as "early loading".⁵ Both the immediate and early functional loading of implants before lamellar bone formation carry an inherent biological risk. Shortened loading protocols may expose the healing bone to implant interface to mechanical overload as described in Wolffs Law and Frosts Mechanostat theory (Fig. 4).

Interfacial micromotion above the biological threshold can result in the subsequent loss of implant stability. Rough titanium surfaces offer better implant anchorage in bone and more rapid bone deposition.⁶ The general applicability of these principles will be considered as to their biological implications, the current evidence base and the factors that influence their results.

Materials and Methods

Clinical reports on dental implants found in major scientific journals and through searching in PUB MED, QUINTESSENZ and MED-LINE, have served as the basis for this review. The following search terms, alone or in combination, were used: implant loading, immediate loading, early loading, delayed loading. After screening the titles and abstracts for possible relevance, they were ordered in full text. We also screened reference list of publications and relevant systematic reviews. To minimise bias, only RCTs of osseointegrated dental implants were considered. To be included, RCTs had to compare the same osseointegrated implants loaded at different times for a period of at least 12 months of loading.

For the purpose of this review immediate loading was defined as an implant put in function within 48 hours after its placement; early loading as those implants put in function from 48 hours up to 3 months after placement, and conventional loading as those implants put in function between 3 to 6 months after insertion. Implant mobility and removal of stable implants dictated by progressive marginal bone loss or infection have been assessed. Implant mobility of individual implants could be assessed manually or with devices such as Periostest® (Siemens, Munich, Germany) or Resonance frequency—Analysis—Osstell® (Integration diagnostics, Göteborg, Sweden). In our search we aimed at including randomized controlled trials. Most clinical reports were on a few implant sys-

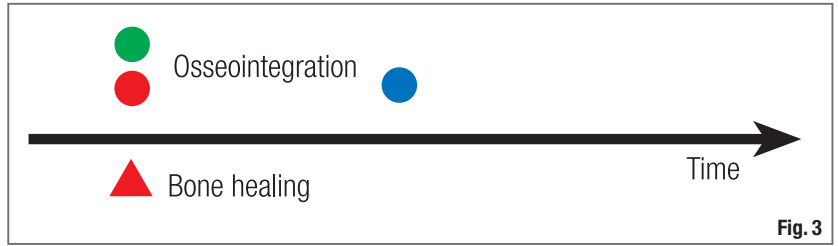


Fig. 3

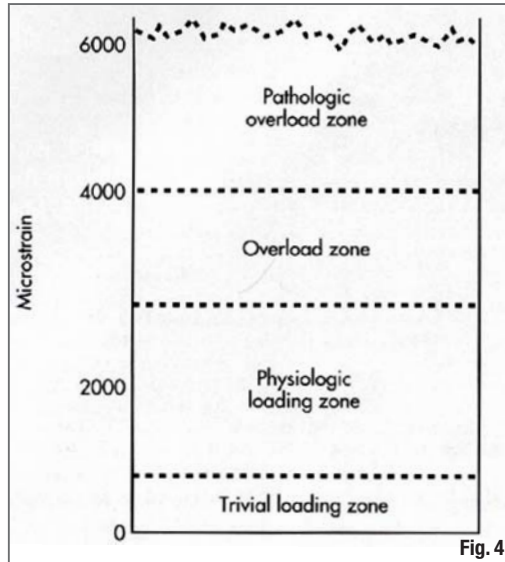


Fig. 4

Fig. 3_Immediate temporization and delayed loading.

Fig.4_Loading zones acc. to H. M. Frost

tems only and threaded commercially pure titanium implants ad modum Brånemark dominated the literature. The quality assessment of the included trials was undertaken independently. The following quality criteria were examined:

Allocation concealment was recorded as adequate (A), unclear (B), or inadequate (C), as described elsewhere [Higgins, Green S. Handbook for systematic reviews of interventions].

Allocation concealment was considered adequate if it was centralized (e.g. Allocation by a central office unaware of subject characteristics). If randomization was pharmacy controlled; if prenumbered or coded identical containers were administered serially to participants.

A score of A was recorded if there was a clear explanation for a withdrawals or dropouts in each treatment group or if there were no dropouts. If clear explanation for any dropouts were given, the risk of bias of the assessment of reasons for dropping out was evaluated. A "strong scientific basis" is required as well. A score of B was recorded if clear explanations for any dropouts or withdrawals were not provided. Articles or authors that stated that allocation concealment procedures were implemented but did not provide details on how this was accomplished were coded as unclear. A score of C was recorded if there

were "insufficient scientific basis" or any procedure that was entirely transparent before allocation, such as an open list of random numbers. Hence, after a thorough reading of the studies included in this review, one of these scores has been qualified according to accuracy and the underlying scientific bases.

Results

In 2002, a consensus meeting was convened within the World Congress organized by the Spanish Board of Implantology in Barcelona.⁵ There was an agreement on terminology for the timing of loading (immediate, early, delayed) and for the implant loading (occlusal loading and nonocclusal loading). According to this consensus meeting the following terminology was described:

Immediate loading

The prosthesis is attached to the implants the same day the implants are placed

Early loading

The prosthesis is attached at a second procedure, earlier than the conventional healing period of 3 to 6 months. The time of loading is started after some days/weeks.

Delayed loading

The prosthesis is attached at a second procedure after a conventional healing period of 3 to 6 months.

Occlusal loading

The crown/bridge is in contact with the opposing dentition in centric occlusion.

Nonocclusal loading

The crown/bridge is not in contact in centric occlusion with the opposing dentition in natural jaw position.

The available literature demonstrates the possibility of achieving good results with different protocols, especially with immediate loading protocol, at least in good-quality bone, which supports the idea that these concepts may serve as a viable option in implant dentistry. However, the prerequisites for achieving and maintaining acceptable results and the limitations of immediate/early loading are not fully known. Moreover, the terminology used in these protocols is confusing since the difference between different protocols is not well defined, and publication titles can therefore be very misleading. Of 26 potential studies, 7 have been excluded because of insufficient patient selection data or prosthesis loading longer than one day (immediate loading), not corresponding to the Barcelona consensus, and 5 have been excluded since the follow up was shorter than 12 months. Fourteen

studies have been introduced in this review, the conclusions having been discussed on their basis.

The majority of the studies considered in this review registered a relatively short follow up. In 6 studies the follow up covered a period longer than 24 months.

Daniel Sullivan, Giampaolo Vicenzi, Sylvan Feldman performed a multicenter study: the performance of Osseotite implants after an 1 stage surgery and abbreviated healing period of 2 months in 10 private practice centers. 142 patients, partially or completely edentulous, enrolled in this early loading study, received 526 implants, 65.4 % in mandible and 34.6 % in maxilla. Implants were loaded after a healing period of about two months. The distribution of the prosthesis types included 118 single tooth restoration (118 implants), 134 short-span prosthesis (327 implants) and 16 long-span restoration (81 implants).

Eight of the eleven implant failures occurred during nonsubmerged healing prior to prosthetic loading. Provisional restoration was placed at 2.1 ± 0.5 months, at which time implants were evaluated for mobility, gingival health and radiolucency. The cumulative success rate of these 526 implants was 97.9 % at 5 years.

These results suggest that success can be expected with Osseotite implants after a nonsubmerged reduced healing period of two months in this patient population.⁷

Par-Ölov Östman, Mats Hellman, Lars Sennerby evaluated in a prospective clinical study the radiographic and clinical outcome of immediately loading implants in the partial edentulous mandible over a 4 year follow up period.


96 patients were evaluated and 77 patients who met the inclusion criteria were included. A total of 111 fixed partial dentures supported by 257 Brånemark System implants (77 turned and 180 Ti Unite implants) was delivered. Four (1.16 %) of the 257 implants did not osseointegrate after 4 years. Three turned implants (3.9 %) and one oxidized implant (0.6 %) failed after 4 to 13 months. Immediate loading of implants with firm primary stability in partially edentulous areas of the mandible appears to be a viable procedure with predictable outcome.⁸

Richard P. Kinsel, Mindy Liss evaluated in a retrospective study the effects of implants dimensions, surface treatment, location in the dental arch, numbers of supporting implant abutments, surgical technique, and generally recognized risk factors on the survival of a series of single stage Straumann dental

CONNECT YOUR COMPETENCIES

STRAUMANN® CARES® GUIDED SURGERY – GLOBAL EXCELLENCE MEETS LOCAL EXPERTISE

- **Local template production:** surgical templates with verified fit just in time from your local dental lab
 - **User friendly – open software system:** offers you large flexibility and easy usage
- **Customized cost model:** benefit from suitable price models for your personal business requirements



Please contact us at **0041 (0)61 965 1111**. More information on www.straumann.com

COMMITTED TO
SIMPLY DOING MORE
FOR DENTAL PROFESSIONALS