

DENTAL TRIBUNE

The World's Dental Newspaper · U.S. Edition

DEC. 1-7, 2008

www.dental-tribune.com

VOL. 3, No. 43

'Current treatment methods in periodontology are not sufficient'

An interview with Prof. Rutger G. Persson, University of Bern, Switzerland

By Daniel Zimmermann, Dental Tribune International

After many years of research on periodontal treatment modalities involving small-scale studies, randomised controlled clinical trials are now allowing revisions of previous concepts in periodontal diagnosis and treatment approaches. The introduction of dental implant replacement has also introduced new therapeutic challenges. In light of new evidence on one side and periodontal infections inflammation on the other side, a potential risk for severe systemic diseases (i.e., acute coronary syndrome, and preterm birth) requires new approaches to periodontal diagnosis and therapy strategies. Dental Tribune International spoke with Prof. Rutger G. Persson, University of Bern, Switzerland, about these strategies and how they could be implemented.



Prof. Persson presenting at this year's FDI World Dental Congress in Stockholm, Photo: DTI.

Daniel Zimmermann: The link between periodontal and systemic diseases is currently the focus of much discussion. How has knowledge of this link influenced the field of periodontology?

Prof. Rutger G. Persson: In the 1980s, a Finnish group first conducted research on the link between periodontitis and cardiovascular diseases. Later, follow-up studies were

conducted by the University of North Carolina at Chapel Hill.

In 1997, it was common knowledge that patients with diabetes mellitus tended to suffer from periodontal disease, but we did not know much about how periodontitis influenced diabetes. There were also interesting new studies on periodontitis and its relation to preterm births and cardiovascular diseases.

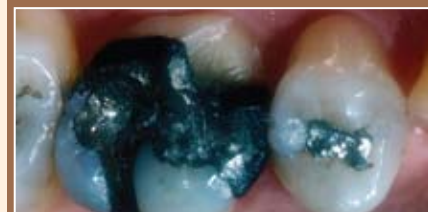Before 1820, it was also known that apical infections were linked to rheumatism (focal infections), but this changed at the beginning of World War II because suddenly everybody claimed the link did not exist. Thereafter, the topic was taboo. Now interest is slowly returning, not in terms of focal infection teaching, but in terms of knowledge of microbial conditions in relation to inflammation reaction in periodontitis.

Are you referring to biofilm?

Yes. Periodontitis isn't a simple
See CURRENT, Page 4

Inside this week

Cosmetic Tribune:
Dr. Ronald D. Jackson



Examine six of the possible reasons why many prominent clinicians feel that inlays and onlays (of any color) are underutilized while crowns are overutilized. Do the reasons withstand the glare of scrutiny? **Page 17**

Hygiene Tribune:
Carol Southard

In part 3 of 4 on tobacco cessation, Southard discusses the use of pharmacotherapy. The goal of cessation pharmacotherapy is to alleviate or diminish the symptoms of withdrawal. **Page 21**

Emergency dental implant procedures

By Drs. Nicholas Caplanis and Jaime Lozada

Patients often present to the office with unscheduled emergency conditions that require immediate tooth removal.

These situations have become

increasingly complex to deal with given the myriad available treatment options, which impact the treatment approach and methodology of both tooth extraction as well as provisionalization.¹

See EMERGENCY, Page 5

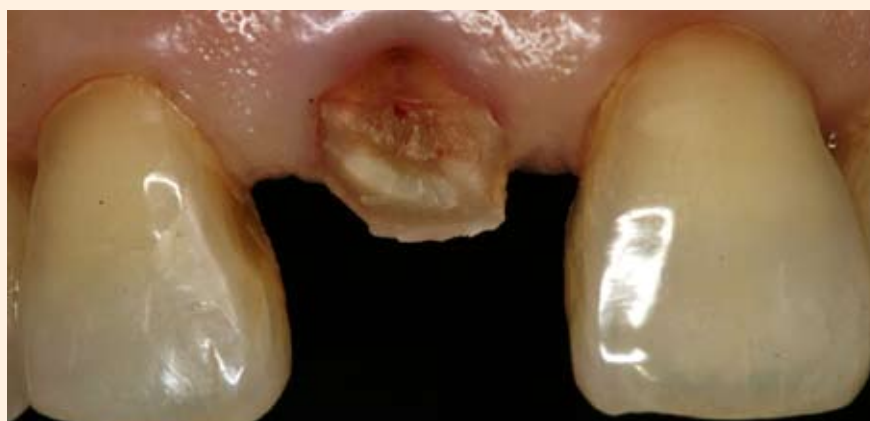

Fig. 1a: Emergency presentation of unrestorable crown and root fracture of tooth #8.

AD

Think different about flowables ...
... because Grandio Flow is different!

Grandio Flow



80% filled Nano Hybrid Composite that flows
The wear of a universal hybrid
The filler degree of a universal hybrid
The low shrinkage of a universal hybrid

...but it flows!

More info and free sample
at www.vocoamerica.com



available
in caps or
syringes

www.vocoamerica.com · info@voco.com

VOCO

Call toll-free 1-888-658-2584

creative in research

PRSR STD
U.S. Postage
PAID
Permit # 506
Mechanicsburg, PA

Researchers caution that tooth loss may increase risk of chronic kidney disease in U.S. adults

Study published in the Journal of Periodontology suggests that effects of untreated periodontal disease may be linked to chronic kidney disease

According to the National Kidney Foundation, one out of nine Americans suffers from chronic kidney disease (CKD), and millions more are at risk. A debilitating disease, CKD can affect blood pressure and bone health, and can eventually lead to heart disease or kidney failure.

A recent study published in the Journal of Periodontology (JOP), the official publication of the American Academy of Periodontology (AAP), suggests that edentulous adults may be more likely to have CKD than dentate adults. In the study, conducted at Case Western Reserve University, edentulism was found to be significantly associated with CKD, indicating that oral care may play a role in reducing the prevalence of chronic kidney disease in the U.S. population.

The study examined the kidney

function and periodontal health indicators, including dentate status, of 4,053 U.S. adults 40 years of age and older. After adjusting for recognized risk factors of CKD such as age, race/ethnicity and smoking status, the results revealed that participants who lost all their teeth were more likely to have CKD than patients who had maintained their natural dentition.

"The rationale for examining edentulous adults in this study is to observe the long-term effects of periodontal disease on the presence of chronic kidney disease," states study author Monica Fisher, PhD, DDS, MPH. "Periodontal disease is a leading cause of tooth loss in adults; therefore edentulism is considered to be a marker of past periodontal disease in the study's participants."

While additional research is needed to fully understand why tooth loss is associated with a higher prevalence of CKD, the destructive nature of chronic inflammation may play a role. Both periodontal disease and

chronic kidney disease are considered inflammatory conditions, and previous research has suggested that inflammation may be the common link between these diseases. Since untreated periodontal disease can ultimately lead to tooth loss, edentulous patients may have been exposed to chronic oral inflammation.

According to David Cochran, DDS, president of the AAP and professor and chair of the Department of Periodontics at the University of Texas Health Science Center at San Antonio, treating periodontal disease can do a lot more than save your natural teeth. "Researchers have long known that gum disease is related to other adverse health conditions, and now we can consider chronic kidney disease to be one of them. It is exciting to think that by controlling periodontal disease and therefore helping to preserve natural dentition, the incidence and progression of CKD may be reduced," Cochran says.

Periodontists recommend regular brushing and flossing and routine visits to a dental professional in order to maintain comprehensive oral health. If gum disease develops, consulting a periodontist is an effective way to determine the most appropriate course of treatment.


Members of the public who wish to learn more about gum disease, locate a periodontist or find out if they are at risk for periodontal disease are being invited to visit perio.org or call (800) FLOSS-EM [(800)-356-7736].

About the American Academy of Periodontology

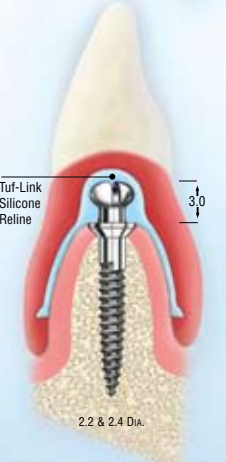
The American Academy of Periodontology is an 8,000-member association of dental professionals specializing in the prevention, diagnosis and treatment of diseases affecting the gums and supporting structures of the teeth, and in the placement and maintenance of dental implants. Periodontics is one of nine dental specialties recognized by the American Dental Association.

(Source: AAP)

AD



HANDS-ON WORKSHOP




Narrow Body Implants to Stabilize, Cushion and Retain Lower Dentures

Without the use of: Housings O-Rings, Or Adhesives

Participate in the real-time procedure, installing Atlas® implants on a hard model. Retrofit the lab-made aesthetic denture and reline it with the Tuf-Link™ silicone material.

All steps and instruments are precisely the same as used in your office. Participants keep the model for staff training and patient education.




2008 Workshop Schedule	
Dec 12	Anaheim, CA
Dec 15	Las Vegas, NV
Jan 9	Salt Lake City, UT
Jan 12	New Orleans, LA
Jan 21	Atlanta, GA
Feb 4	Memphis, TN
Feb 6	Scottsdale, AZ
Feb 13	Washington DC
Feb 16	Hartford, CT

Accreditation:
4 credits will be awarded upon completion of the course

**FDA APPROVED
FOR LONG TERM USE**

To register or for more information call Dentatus

Dentatus USA, Ltd.
1-800-323-3136
www.dentatus.com



© 2008 Dentatus USA, Ltd. • Patents Pending

DENTAL TRIBUNE

The World's Dental Newspaper - US Edition

Publisher

Torsten Oemus
t.oemus@dtamerica.com

President

Eric Seid
e.seid@dtamerica.com

Group Editor

Robin Goodman
r.goodman@dtamerica.com

Editor in Chief Dental Tribune

Dr. David L. Hoexter
d.hoexter@dtamerica.com

Managing Editor Endo Tribune

Fred Michmershuizen
f.michmershuizen@dtamerica.com

Managing Editor Implant Tribune

Sierra Rendon
s.rendon@dtamerica.com

Managing Editor Ortho Tribune

Kristine Colker
k.colker@dtamerica.com

Product & Account Manager

Mark Eisen
m.eisen@dtamerica.com

Marketing Manager

Anna Wlodarczyk
a.wlodarczyk@dtamerica.com

Sales & Marketing Assistant

Lorrie Young
l.young@dtamerica.com

C.E. Manager

Julia E. Wehkamp
E-mail: j.wehkamp@dtamerica.com

Art Director

Yodit Tesfaye Walker
y.tesfaye@dtamerica.com

Dental Tribune America, LLC
215 West 35th Street, Suite 801
New York, NY 10001
Tel.: (212) 244-7181
Fax: (212) 244-7185



Published by Dental Tribune America
© 2008, Dental Tribune America, LLC.
All rights reserved.

Dental Tribune strives to maintain utmost accuracy in its news and clinical reports. If you find a factual error or content that requires clarification, please contact Group Editor Robin Goodman, r.goodman@dtamerica.com. Dental Tribune cannot assume responsibility for the validity of product claims or for typographical errors. The publisher also does not assume responsibility for product names or statements made by advertisers. Opinions expressed by authors are their own and may not reflect those of Dental Tribune America.

Editorial Board

Dr. Joel Berg
Dr. L. Stephen Buchanan
Dr. Arnaldo Castellucci
Dr. Gorden Christensen
Dr. Rella Christensen
Dr. William Dickerson
Hugh Doherty
Dr. James Doundoulakis
Dr. David Garber
Dr. Fay Goldstep
Dr. Howard Glazer
Dr. Harold Heymann
Dr. Karl Leinfelder
Dr. Roger Levin
Dr. Carl E. Misch
Dr. Dan Nathanson
Dr. Chester Redhead
Dr. Irwin Smigel
Dr. Jon Suzuki
Dr. Dennis Tartakow
Dr. Dan Ward

Tell us what you think!

Do you have general comments or criticism you would like to share? Is there a particular topic you would like to see more articles about? Let us know by e-mailing us at feedback@dtamerica.com. If you would like to make any change to your subscription (name, address or to opt out) please send us an e-mail at database@dtamerica.com and be sure to include which publication you are referring to. Also, please note that subscription changes can take up to 6 weeks to process.



**FINANCIAL PLANNING IS NOT JUST
“INVESTMENT PLANNING”.**

RG CAPITAL
INVESTMENT ADVISORY SERVICES

*“In today’s volatile
stock market environment...
dentists are looking for
predictability.”*

Robert S. Graham, RFC, CFM
Certified Financial Manager
President/CEO

*RG Wealth Management Advisors review your practice and
practice tax strategies searching for opportunities... so you
will have the potential to invest more.*

RG CAPITAL

INVESTMENT ADVISORY SERVICES

**RG CAPITAL TAKES A SMARTPLAN
APPROACH TO WEALTH MANAGEMENT.**

- **SMART GROWTH**
- **COST EFFICIENT INVESTING**
- **TAX AVOIDANCE STRATEGIES**
- **INVESTING IN TURBULENT TIMES**
- **DEFINING YOUR VISION AND GOALS**
- **CUSTOM RETIREMENT PLAN DESIGN**
- **FINDING CLARITY FOR YOUR FINANCIAL FUTURE**

1-800-274-4599

rgcapital.net
info@rgcapital.net

RG CAPITAL
INVESTMENT ADVISORY SERVICES

PH 480 612 6400
FAX 480 612 6401

4800 N. Scottsdale Rd.

Suite 2400

Scottsdale, AZ 85251

Registered Principal offering securities through AIG Financial Advisors, Inc. member FINRA/SIPC and a registered broker-dealer not affiliated with RG Capital. Advisory Services offered through RG Capital Investment Advisory Services.

CURRENT

From Page 1

infection with inflammation. It has communities of microorganisms, which raises interest in terms of inflammation reaction and the microbial burden in fields like cardiology and obstetrics. This means we all have a common interest in the aetiological factors.

What information does current research give us about the microbiological interactions in biofilm?

One first has to understand that this is not simply about a small group of bacteria, but perhaps about the total microbial burden and the immune reaction to this burden. For example, *Streptococci* are early coloniser bacteria that might play a role in other diseases. In the field of periodontology, we haven't paid much attention to this thus far.

Do you see a need for improved cooperation between dentistry and medical science?

I already work with cardiologists and gynecologists at the University of Seattle and with physicians from Sweden and Bern in Switzerland because as a dentist, I have microbiological information they may not

have. You see, there is close cooperation in the fields of periodontology, immunology and social behavior.

Despite this cooperation, we may be too late in some cases. Periodontal treatment of a 70-year-old patient will yield no improvement, but we might be able to treat 30-year-old patients with the help of a special diet and improved oral hygiene, or with antimicrobial and anti-inflammatory treatment methods that influence cardiovascular conditions.

I also see a lot of potential in cross-sectional intervention studies. In these studies we observe healthy and sick patients and examine their dental conditions and the way in which these conditions and other medical conditions change because of treatment.

Can you give an example?

One could look at epidemiological studies of Jönköping County (a province in Sweden), conducted from the 1970s until today. In 1970, almost 80 percent of the county's residents had some form of periodontitis, and a rather small number, about 15 percent, suffered from severe periodontal disease. The first group of people do not have periodontitis nowadays, which indicates a significant change over the last 30 years. However, the group

with severe periodontitis has not changed.

Why is that?

In my opinion, because of the Swedish health care system. Patients with periodontal disease underwent treatment, but in the group with severe periodontitis, these methods were not successful.

Current methods in periodontology are not sufficient in my opinion. Mechanical treatments, such as scaling and root planing, are not able to remove bacteria in patients that already have symptoms of disease. It could be that these treatments do the opposite, and cause coronary embolism. In addition, there is immune reaction.

There are two studies, conducted in Austria and the United Kingdom, that observed blood circulation in the arms and found that the level of a certain protein increased shortly after periodontal treatment (between 2 mg/l and 15-20 mg/l). The levels decreased after a while, but they did not return to normal. Therefore, the treatment did not result in a reduction of inflammation factors and thus wasn't successful in my opinion. One cannot expect to treat patients with risk of cardiovascular disease or preterm birth successfully because the studies show that the risks basically remain the same.

We generally need more knowledge of the relationship between and the role of microorganisms and immune defence systems. In addition, there are socioeconomic and genetic factors that we cannot influence at all. My hope is that politicians put more effort into supporting joint academic research between dentistry and medical science.

Is there a lack of support for such research?

I think there are enough funds available for medical research, but it is very difficult for dentistry to compete with medical science in that respect because it is a smaller discipline. But improved cooperation between medical science and dentistry could reduce the risk of preterm births and cardiovascular diseases.

Another interesting aspect is the relation between tooth implants and periodontal inflammation or the so-called peri-implantitis.

Implants are very interesting as a replacement for natural teeth, but we do not know much about the mechanisms between peri-implantitis and systematic diseases. We do know that *Staphylococcus aureus*, for example, sticks on titanium inside biofilm, and causes inflammation, which was proved in medical studies involving titanium prosthetics in hand and joint surgery.

In my opinion, because natural teeth and implants are not the same, conditions for the colonisation of bacteria on implant surfaces are different from those of teeth. It is also much more difficult to clean an implant. The problem is that the industry propagates very high suc-

cess rates of their products, which is too short-sighted in my opinion.

Why?

In Sweden, for example, all joint implants have to be officially registered. Therefore, one knows exactly how many have been implanted, and how many of those were successful. In dentistry, such a list does not exist, and we therefore do not know how many implants have been successful thus far.

In addition, it must be noted that it takes 20 years for natural teeth to develop periodontitis. The first implants are about 20 to 30 years old, and only now can one see how they have developed. At first, only patients without risk of peri-implantitis received implants; yet, all dentists worldwide can place implants, even if he or she is not qualified. There are certainly ulterior motives involved here, and it is apparent that some patients shouldn't have received implants at all. There is much potential for mechanical and technical failure. But how does one separate incorrectly treated patients from patients that suffer from infections, inflammation and pathogenesis? In this case, analysis was not very accurate.

This issue will continue to be of concern to dentistry. What can be done?

In Bern, we have been using the same implant system for years. About 1,000 implants were placed in the last 10 years, so we have a follow-up time ranging from five to seven years. After such a period, one can conclude how successful treatment was through microbial, ethnological, clinical or socioeconomic studies that determine the success of a treatment.

Multiple center studies could also help to identify the different mechanisms, and help us choose patients with minimal risk or no risk at all of implant failure. Then we might be able to find methods to treat peri-implantitis. I believe we also have to consider antibiotics and anti-inflammatory compounds. Cleaning implants with hand instruments and toothbrushes at home isn't enough.

What role can the industry play?

This is a very interesting question. I recently discussed this with a colleague from Stockholm, and we both agreed that fluoride toothpaste, developed mainly by the industry and not by universities, was the biggest development in the 1980s and 1990s. This example shows that research conducted by the industry can be very successful.

Personally, I see no problem in this because implant companies make a lot of money and should be responsible for putting some of it back into research institutes, instead of constantly developing new implant systems. This could lead to a better understanding of the mechanisms of successful implants and implants that fail. It will be up to governments and health authorities to introduce control mechanisms for these processes.

AD

**Academy of Osseointegration
Annual Meeting**

February 26-28, 2009
San Diego Convention Center

San Diego

Highlights include:

- Opening Symposium: "A New Wave in Implant Therapy: Is there a New Gold Standard? Current Clinical Controversies"
- Round Table Clinics
- Limited Attendance Lectures
- Two Track Program (Surgical & Restorative)
- Commercial Exhibits
- Failure Festival
- Dental Hygiene/Assistant Program
- Laboratory Technician Program

osseo.org

ADAC-E-R-P

EMERGENCY

From Page 1

Unrestorable crown and root fractures are often ideal clinical scenarios for immediate implant placement given the frequent lack of overt infection and alveolar bone damage, which is often associated with other emergency conditions such as endodontic and periodontal abscesses. Failure to perform immediate implant placement or site preservation during the emergency visit often leads to a loss of alveolar bone, which greatly impacts dental implant treatment success. When comparing the excellent long-term success rates of implants with the guarded long-term prognosis of a badly fractured tooth requiring endodontic treatment, crown lengthening surgery, and a post and core buildup, extraction and site preservation or immediate implant placement is frequently the ideal treatment approach.

A clinical study of 534 fractured teeth reported a 20 percent failure rate when conventional therapy was performed, specifically, endodontic treatment, post and core buildup and a tooth-supported crown.² Immediate implant placement following an emergency extraction should therefore be an integral part of emergency treatment.

Strategies to manage the extraction defect have been previously published providing algorithms to help guide implant treatment procedures, including immediate implant placement following tooth extraction.⁵ Guidelines for predictable immediate provisionalization of immediate implant have also been previously established.⁴

A one-year prospective study reported a 100 percent implant success rate and also suggested improved esthetic outcomes are achieved following this approach when compared to extraction alone without implant placement.⁵ The ability to quickly and effectively treat these emergency scenarios improves patient satisfaction, facilitates patient management and is a tremendous clinical service.

Therefore, the dental office and team should be well-equipped, or referral guidelines be effectively established, to allow for efficient and predictable dental implant placement during these types of emergency appointments. The following two clinical case reports describe a simple and effective process to treat hopelessly fractured teeth using dental implants and either a bonded restoration as a provisional or a provisional placed immediately on the implant.

Patient 1

A 65-year-old Asian female presents for a new patient emergency exam with an oblique crown and root fracture affecting her maxillary right central incisor. The fracture occurred spontaneously while

See EMERGENCY, Page 6

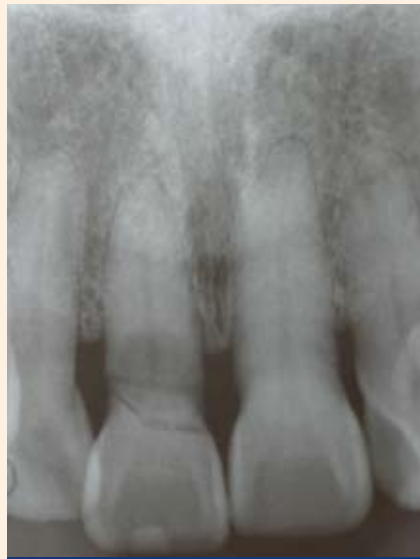

Fig. 1b: Radiograph of oblique crown and root fracture tooth #8.

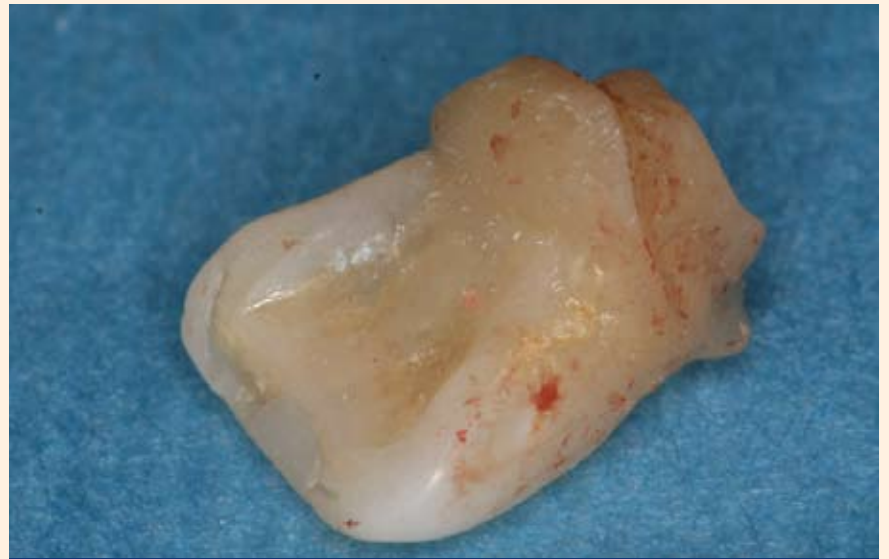

Fig. 1c: Intact clinical crown to be used as bonded provisional.

AD

Powerful prescriptions for bruxing and snoring



Your bruxing patients will prefer the extra comfort of the combination hard/soft bite splint.

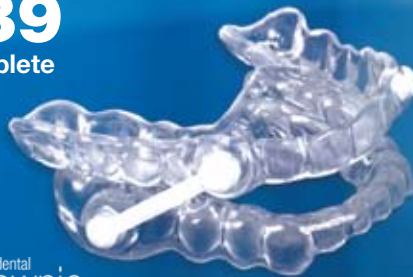Comfort H/S
Bite Splints™



\$59
per hard/soft splint

Silent Nite®
Anti-Snoring Appliance

\$89
complete



Glidewell Laboratories voted best service/labs for "Removable" 2007 Dental Townie Choice Awards®

For more info & nationwide pick-up

888.786.2177

www.glidewell-lab.com



Successfully treating snoring not only improves restful sleep, it enhances vitality and improves quality of life.

GLIDEWELL LABORATORIES
Serving Dentists Since 1970

EMERGENCY

From Page 5

eating, involved the entire facial surface of the tooth and extended to the alveolar crest (Figs. 1a, 1b). The clinical crown exhibited severe mobility and was painful upon palpation and percussion. The prognosis was poor and extraction was advised.

Treatment options to replace the tooth were discussed and included a fixed partial denture as well as an implant supported crown. Given the excellent condition of the adjacent teeth as well as the patient's prior history of having successful dental implant-supported restorations, she elected to have an implant placed.

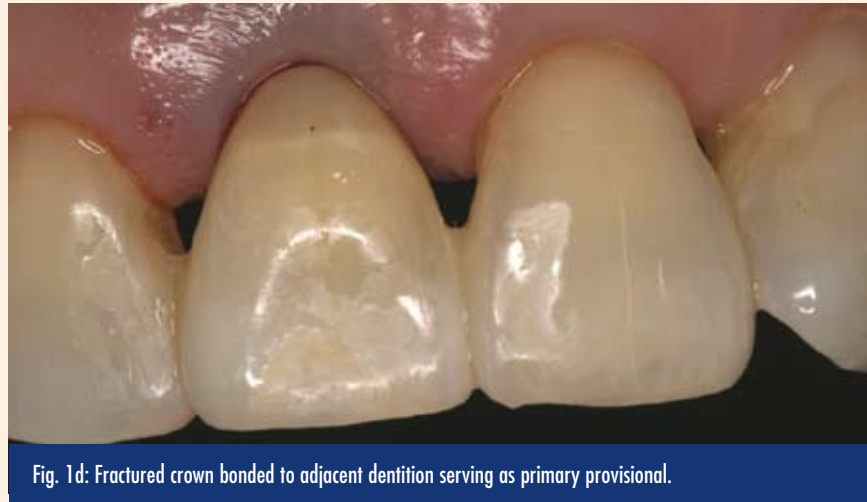

Fig. 1d: Fractured crown bonded to adjacent dentition serving as primary provisional.

The crown portion of the tooth was easily removed and, given its excellent condition, was retained to be used as a bonded provisional (Fig. 1c). The tooth root was extracted atraumatically without

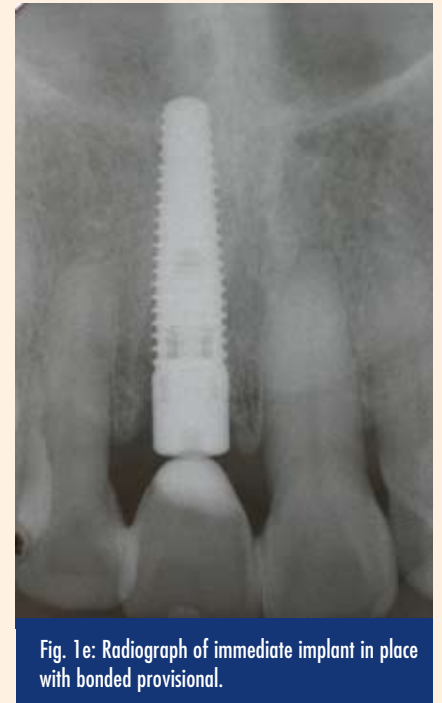

Fig. 1e: Radiograph of immediate implant in place with bonded provisional.

AD

flap elevation and the socket debrided, irrigated and evaluated with a periodontal probe. The extraction defect had minor horizontal bone loss associated with a reduced periodontium secondary to a prior history of periodontitis, but the adjacent socket walls including the buccal crest were otherwise intact. Therefore the defect appeared amenable for immediate implant placement.

A 4.5-by-16 mm Replace® Select implant (Nobel Biocare™) was placed and utilized the entire length of the alveolus and engaged the nasal floor, in order to achieve effective primary stability (Fig. 1e). After implant placement, the residual socket defect was grafted with a composite anorganic bovine bone matrix (Bio-Oss® Osteohealth®) and a demineralized cortical bone allograft (OraGraft® LifeNet®). Composite was bonded to the fractured surface of the clinical crown in order to develop an ovate surface to maintain soft tissue esthetics. The modified clinical crown was then bonded to the adjacent teeth and served as a primary provisional restoration (Fig. 1d). The patient was then referred back to her restorative dentist the next day to fabricate an immediate provisional supported by the implant. The emergency appointment including the extraction, placement of the implant, grafting of the residual socket defect and bonding of the primary provisional restoration took approximately one hour of clinical time.

Patient 2

A 35-year-old female presented at the emergency clinic of Loma Linda University School of Dentistry and was immediately referred to the Center for Implant Dentistry. She complained of trauma to her maxillary anterior dentition after an alleged assault, a "blow to the face," two days previously. Upon examination: the maxillary left central incisor was partially fractured at mid root and exhibited grade III mobility (Fig. 2a). The left lateral incisor was tender to percussion

Swiss Bien-Air 2008 4th Quarter Specials

SPECIAL OFFER N°1



Buy 1 Optima MX and 2 attachments 1:5 L and get 1 FO attachment 1:1 FREE

Retail Price \$7,157
Package Price \$4,291
SAVE \$2,866

SPECIAL OFFER N°2



Buy 1 Digipad MX int and 2 attachments 1:5 L and get 1 FO attachment 1:1 FREE

Retail Price \$7,157
Package Price \$4,291
SAVE \$2,866

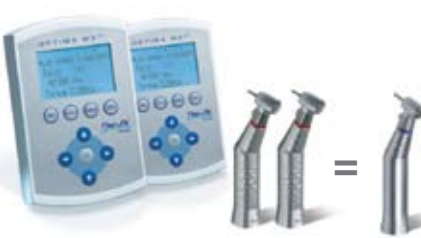SPECIAL OFFER N°3



Buy 2 Optima MX and 2 attachments 1:5 L and get 2 FO attachment 1:1 FREE

Retail Price \$11,686
Package Price \$6,611
SAVE \$5,075

SPECIAL OFFER N°4



Buy 2 Digipad MX int and 2 attachments 1:5 L and get 2 FO attachment 1:1 FREE

Retail Price \$11,686
Package Price \$6,611
SAVE \$5,075

HIGHSPEED AIR SPECIAL



Buy 3 BORA and get 1 FREE

Retail Price \$5,816
Package Price \$3,207
SAVE \$2,609

ELECTRIC ATTACHMENTS



Buy 2 1:5L and 2 1:1L attachments, Get 1 1:5L attachment FREE

Retail Price \$6,480
Package Price \$3,690
SAVE \$2,790

Promotion valid for orders taken at trade shows and must be purchased through authorized distributors only. Offers are valid from October 1, 2008 to December 31, 2008

For more information on products, please visit our website: www.bienair.com

Bien-Air USA, Inc. Tel. 1-800-433-BIEN
Irvine CA 92606 Fax 949-477-6051



REF2500255 EDITION: 06.08

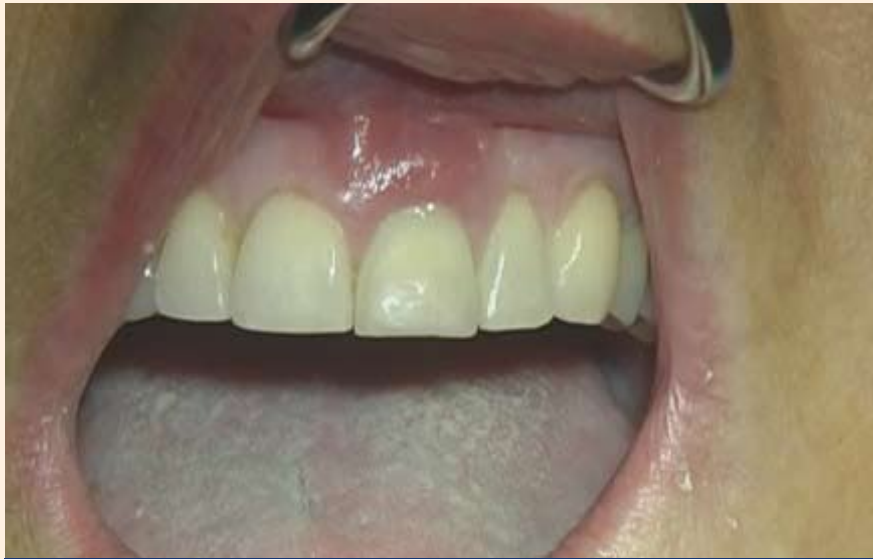

Fig. 2a: Trauma to the maxillary left central incisor with horizontal root fracture.

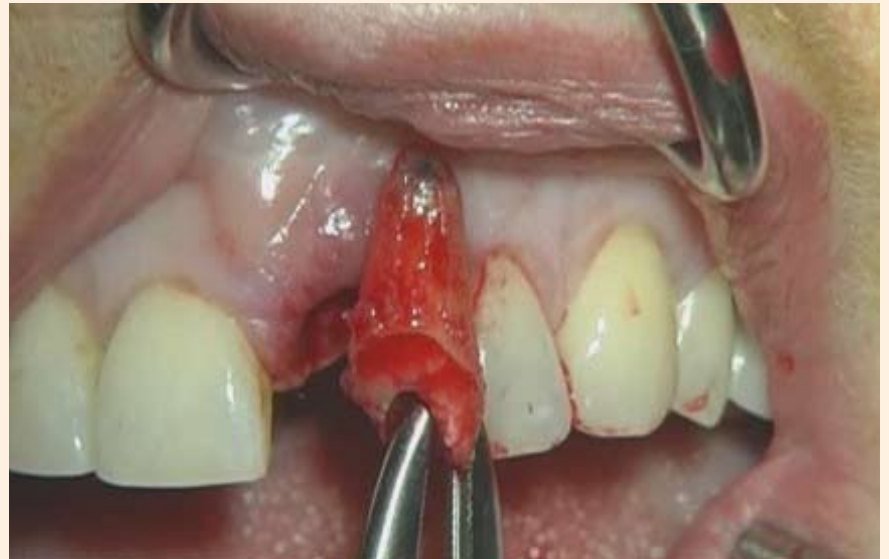

Fig. 2b: Periosteal elevator and forceps extraction of fractured root.

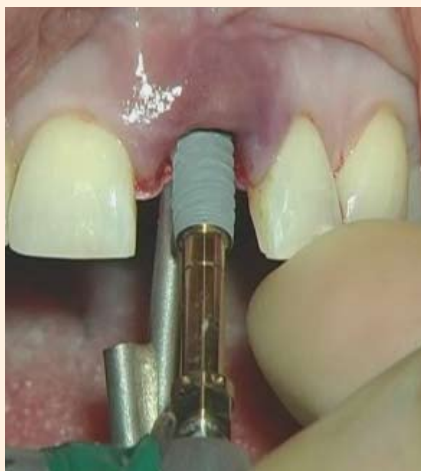

Fig. 2c: Immediate implant is placed achieving excellent primary stability.

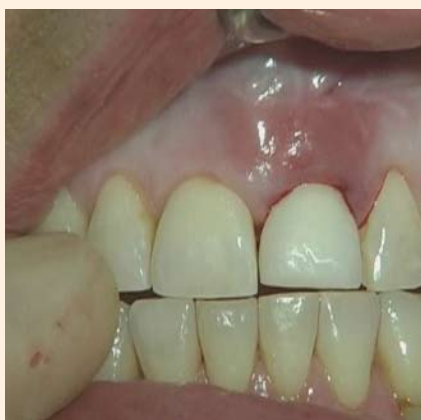

Fig. 2d: An immediate acrylic restoration is used as a provisional.

and exhibited grade 1 mobility, but it recorded a negative response with ethyl chloride and electronic pulp testing.

The patient was then scheduled to undergo an emergency procedure at the clinic consisting of atraumatic extraction of the affected tooth and immediate implant placement with immediate provisionalization. The fractured tooth was extracted and the remaining root fracture was removed utilizing a periosteal instrument (Fig. 2b). The alveolus was curetted and no bone fenestration was noted.

A Nobel Active dental implant was used to replace the extracted tooth (Fig. 2c). The osteotomy was performed palatal to the alveolus in order to obtain maximum stabilization for the implant.

See EMERGENCY, Page 8

AD

Best Taste... Guaranteed!

Guess whose dentist didn't use new ClearShield™ fluoride varnish?

Goes on clear. . . clearly tastes better!

New Kolorz ClearShield 5% Sodium Fluoride Varnish goes on clear, with no embarrassing yellow discoloration. And its great watermelon flavor, developed by gourmet food-industry professionals, makes treatment a picnic for kids!

- **Guaranteed to taste better than any other fluoride varnish, or your money back!**
- Sealed single dose package includes easy-to-use applicator and mixing well
- Excellent consistency ensures complete coverage
- Maximum fluoride formula
- No Saccharine or Aspartame, only natural sweeteners
- Contains Xylitol
- Gluten free

OTHER BRANDS

WITH CLEARSHIELD

No ugly, yellow teeth with ClearShield!

- ClearShield™ Fluoride Varnish
- Prophylaxis Paste
- Topical Anesthetic Gel
- Sixty Second Fluoride Foam and Gel
- Neutral Fluoride Foam

Get a FREE sample package of ClearShield!

To order, go to www.zenithdental.com/clearshield, call 1-800-662-6383, or complete coupon and mail or fax.

Name _____

Address _____

City _____ State _____ Zip _____

Phone _____ Fax _____

Email _____

All fields must be completed to receive free product. ZenithDental

Mail coupon to Kolorz ClearShield Offer, 242 South Dean Street, Englewood, NJ 07631, or fax to 201.894.0213. Offer ends 12/31/08. Offer limited to 3 per dental office. Offer code: DTRIBCS

EMERGENCY

From Page 7

The implant was seated at 35 nc stability, which made the clinical situation viable for immediate provisionalization. A prefabricated abutment was placed and hand torqued to provide the support for the acrylic resin restoration. The provisional crown was then relieved from all occlusal contacts (Fig. 2d). Intraoperative radiographs revealed adequate position of the implant in relation to the adjacent dentition and bone implant level.

The emergency dental implant procedure should be considered a viable and often preferable treatment approach to treat emergency

situations that ultimately lead to tooth loss such as root fractures. When appropriate, immediate provisionalization or bonding of the fractured crown can be used as a provisional restoration.

References

1. Iasella JM et.al. Ridge preservation with freeze-dried bone allograft and a collagen membrane compared to extraction alone for implant site development: A clinical and histologic study in humans. *J. Periodontol* 2003 74(7): 990-9.
2. Cvek M, Tsilingaridis G, Andreasen JO. Survival of 534 incisors after intra-alveolar root fracture in patients aged 7-17 years. *Dent Traumatol*. 2008 Aug; 24(4):379-87.
3. Caplanis N, Kan J, Lozada JL. Extraction defect assessment, classification and management. *Journal of the California Dental Association*. 2005; 33(11): 853-863.
4. Wöhrle PS. Single-tooth replacement in the aesthetic zone with immediate provisionalization: fourteen consecutive case reports. *Pract Periodont Aesthet Dent*. 1998 Nov-Dec; 10(9):1107-14.
5. Kan JY, Rungcharassaeng K, Lozada J. Immediate placement and provisionalization of maxillary anterior single implants: 1-year prospective study. *Int J Oral Maxillofac Implants*. 2003 Jan-Feb; 18(1):31-9.

About the authors



Dr. Nick Caplanis is an assistant professor and part-time faculty member within the graduate program in implant dentistry at Loma Linda University School of Dentistry. Caplanis has a unique background with formal residency training in the inter-related fields of implant surgery, prosthodontics and periodontics. He is board certified and a diplomate of both the American Board of Periodontology and the American Board of Oral Implantology and is a fellow of the American Academy of Implant Dentistry. He was the general meeting chairman for the 57th annual meeting of the AAID, held in San Diego from Oct. 29-Nov. 1. Caplanis maintains a full-time private practice limited to periodontics and dental implant surgery, in Mission Viejo, Calif.



Dr. Jaime Lozada is the director of the graduate program in implant dentistry and a professor at Loma Linda University School of Dentistry. Lozada has been involved with implant dentistry for more than 20 years. He completed his residency in implant dentistry in 1987 and his graduate prosthodontics certificate in 1997. Lozada has trained hundreds of residents and fellows in the latest techniques in oral implant surgery and prosthodontics. Lozada is a fellow and current president of the American Academy of Implant Dentistry and a diplomate of the American Board of Implant Dentistry. He is well-published and lectures nationally and internationally on implant dentistry and maintains a faculty practice limited to implant dentistry and prosthodontics at the Loma Linda University School of Dentistry.

AD

The Whole Kit and Caboodle

On display at www.photomed.net - 24/7

Canon



The whole kit and caboodle. Everything, and all of it. That describes PhotoMed. We've got everything you need for clinical photography. PhotoMed clinical camera systems feature the best digital camera equipment available. Shown above are the PhotoMed/Canon G10 and the Canon 50D. We also feature clinical systems built around Canon's Rebel XS, Rebel XSi, EOS 40D and (soon) the 5D Mark II. Go to photomed.net for full info on each of these cameras.

We know that no one likes to spend time reading thick user manuals so your camera is delivered assembled, set and tested along with our concise custom instructions. And we include unlimited phone support and loan equipment if needed.

PhotoMed carries all of the accessories you may need: intraoral mirrors, retractors, Contrasters, printers, clinical photography books/training cds (*Dr. Chris Orr's new interactive dental photography CD is a great way to train your staff*) and recreational lenses from Sigma (*the new 18-200 DC OS lens is a nice choice*). Visit our website. Give us a call. Come see us at a dental meeting (*there's a complete list of upcoming meetings at: www.photomed.net*). We know you'll like us.



www.photomed.net • 800.998.7765

Mention the "kit and caboodle ad" when you order for some extra kit!

PhotoMed
INTERNATIONAL

Distinguished speakers highlight 34th Yankee Dental Congress, Jan. 28 through Feb. 1, 2009

Come Aboard is the theme of the 34th annual Yankee Dental Congress® (YDC), New England's largest dental meeting, which will be held Jan. 28 through Feb. 1, 2009, at the Boston Convention and Exhibition Center (BCEC).

The YDC is the fifth largest dental meeting in the country and is sponsored by the Massachusetts Dental Society, in cooperation with the Connecticut, Maine, New Hampshire, Rhode Island and Vermont dental associations. The estimated 30,000 dental professionals expected to attend the convention in Boston next year will not only discover YDC 34 to be educational, fun and informative, but also filled with entertaining events, top-notch speakers, 500-plus exhibitors and more than 450 education courses from which to choose.

On Thursday, the Big Apple Circus *Circus To Go!* will entertain and delight with acrobats, jugglers, clowns and wirewalkers. Have lunch with author Dennis Lehane, best-selling author of *Mystic River* and *Gone Baby Gone*. Friday evening, the YDC presents the first-ever Comedy Night, starring comedians Frank Caliendo and Kathleen Madigan.

YDC 34 highlights by day

Thursday, Jan. 29, 2009

The Scottsdale Center for Dentistry will offer attendees an integrated approach to achieving excellence that incorporates every aspect of success, including patient care, clinical excellence and business profitability. Featuring Drs. Gordon Christensen, George Bailey, Terence Donovan, Edward McLaren and Jon Suzuki.

Team Development Day: Real World Communications Made Easy is designed specifically for the dental auxiliaries attending the YDC. This day of practical sessions with the Coaching Center will build clinical knowledge and strengthen team relationships. In this participatory program you will learn the basic skills of effective communication with colleagues and patients.

Dr. Joe Camp, an adjunct professor in the department of endodontics at the University of North Carolina School of Dentistry, will present "Mechanical Instrumentation of Root Canals" and "Endodontic Diagnosis."

Dr. John Sorenson, a diplomate of the American Board of Prosthodontics and founder of the Pacific Dental Institute, will discuss "Optimizing Esthetic Outcomes in Implant Prosthodontics."

Dr. George Priest, a diplomate of

the American Board of Prosthodontics, will present "Young Patients and Implant Esthetics."

Dr. Terry Tanaka, a clinical professor of graduate prosthodontics at the University of Southern California School of Dentistry, will offer a talk on "Problem Solving for Fixed, Removable and Implant Procedures."

Dr. Jeffrey Wood, president of the California Society of Pediatric Dentistry and professor and chair of the department of pediatric dentistry at the University of the Pacific, will present "Space Maintenance in the Primary and Mixed Dentitions."

Dr. Rhonda Savage, past president of the Washington State Dental Association and current CEO of Linda L. Miles and Associates, will discuss "Communication and Teamwork."

Gary Zelesky, who has been presenting to audiences around the world for over 25 years as a life and team coach for business professionals, dentists and teams, will speak on "The Passion-Centered Practice" and "Naked in Paradise."

Dr. Theresa Gonzales, a diplomate of the American Academy of Oral and Maxillofacial Pathology and a professor at the Naval Postgraduate Dental School, will present "Conducting a Head-and-Neck Examination" and "Redefining Dentistry's Role in Forensics."

Dr. Uche Odiatu, a clinical instructor at the University of Toronto, a certified trainer, and a wellness author, and Kary Odiatu, an NCSA Certified trainer, wellness author and a Ms. Fitness Universe, will speak on how to "Raise a Happy, Healthy Family."

Friday, January 30, 2009

Loretta LaRoche, founder of The Human Potential Inc. and consultant to Fortune 500 companies, has starred in four PBS specials and teaches audiences to beat the odds with humor, wisdom and patience. She will present the personal development seminar "How to Prevent Hardening of the Attitude."

Dr. L. Stephen Buchanan, a diplomate of the American Board of Endodontics and an assistant clinical professor at the University of Southern California School of Dentistry, will discuss "The Art of Endodontics."

Dr. Gordon Christensen, the dean of the Scottsdale Center for Dentistry, director of Practical Clinic Courses and a senior consultant for Clinicians Report, will talk on "New Aspects of Dentistry for 2009."

Dr. Ronald Jackson, the director of the advanced adhesive esthetic dentistry and anterior direct resin programs at the Las Vegas Institute for Advanced Dental Studies, will present "The Art of Direct Resin."

Dr. Roger Levin, a world-renowned consultant, speaker and author, and the founder, CEO and president of the Levin Group, will discuss "Eight Secrets of Highly Successful Practices" and "Double Your Production and Profit."

Robin Wright, PhD, a nationally recognized communications expert and president of Wright Communications, will speak on "Team Up for Treatment Acceptance" and "Tough Questions, Great Answers."

Jerome Groopman, MD, the chief of the division of experimental medicine at Beth Israel Deaconess Medical Center and professor at Harvard Medical School, will discuss "How Clinicians Think."


Pamela Smith, RD, a nutritionist, culinary consultant and best-selling author of *Live Well, Food for Life*, *The Energy Edge*, and *Take Charge of the Change*, will present "Energy for Life!" and "When Hormones Go Haywire: A Course for Men AND Women."

Dr. Stanley Malamed, a diplomate of the American Board of Dental Anesthesiology and professor of anesthesia and medicine at the University of Southern California, will offer a talk on "Local Anesthetics: Dentistry's Most Important Drugs" and "Update on Local Anesthetic Techniques."

Jill Rethman, RDH, a visiting clinical instructor at the University of Pittsburgh School of Dental Medicine and editorial director for *Dimensions of Dental Hygiene*, will discuss "Determining Risk, Redefining Treatment" and "An Update in Periodontics — What Every Office

See **DISTINGUISHED**, Page 11

AD




10

LECTURE PRESENTATIONS

With slides and corresponding surgical broadcasts

Chris Church, MD • Philip Boyne, DMD • Hil Tatum Jr, DDS
Thomas Taylor, DDS • Robert B. Summers, DMD
Steve Wallace, DDS • Craig Misch, DDS • Howard Chasolen, DMD
Ole T. Jensen, DDS • Bozena Wrobel, MD
Meeting Chairman: Nicholas Caplanis, DMD, MS



*Plus shipping and handling
While supplies last


"Going Live! Focus on the Sinus" demonstrated contemporary sinus augmentation techniques used in the reconstruction of the deficient posterior maxilla in preparation for dental implants.

Some of the world's most respected speakers on sinus augmentation were assembled for this exciting and innovative 2-1/2 day conference in Newport Beach, California, sponsored by the American Academy of Implant Dentistry's Western District.

Surgical procedures were performed concurrently at Loma Linda University directed by Dr. Jaime Lozada.

These live surgical broadcasts demonstrate the various sinus augmentation techniques and complement the lecture presentations.

This special edition 4 DVD collection includes 10 lectures combined with slides and 4 surgical demonstrations.



\$295⁰⁰ Please call the American Academy of Implant Dentistry to order at:
1-312-335-1550
or online at www.aaid.com

"Just like being in the OR"