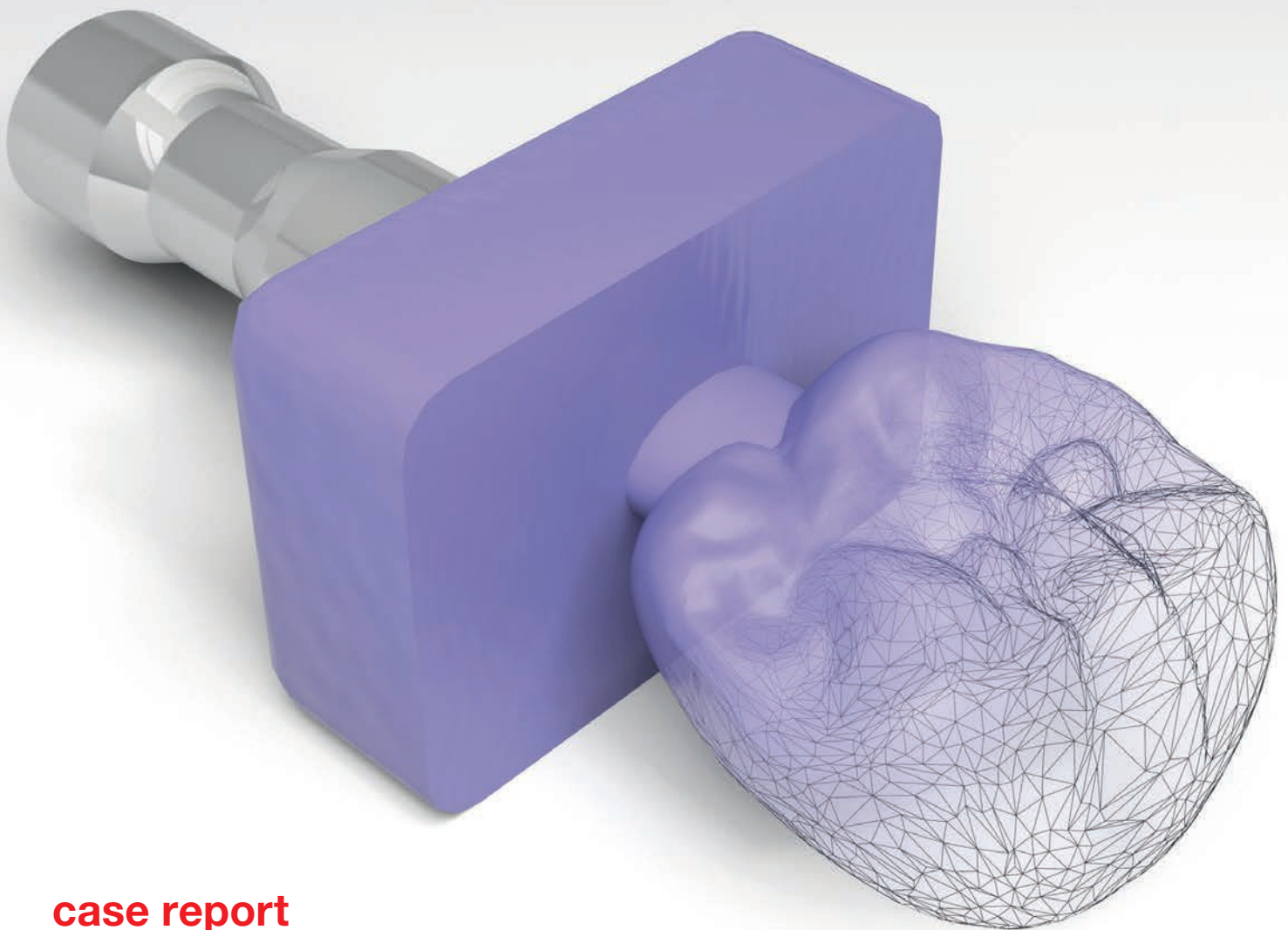


digital

international magazine of digital dentistry



case report

Dental Anatomical Combinations—
smile design harmony

trends & applications

Full-arch implant considerations—
Innovations in the digital workflow with the iJIG

practice management

Ten guiding principles as we recover from COVID-19


IT'S SIMPLE
WHEN YOU
HAVE ALL THE
OPTIONS



MIS® | C1

THE CONNECTION FOR PREDICTABLE BIOLOGY. **MAKE IT SIMPLE**

The MIS C1 conical connection implant system offers uncompromising accuracy, with high initial and biological stability and a safe, yet simple, procedure. A consistent concave emergence profile of the C1 prosthetic components improves soft tissue esthetic results. Learn more about the C1 implant and MIS at: www.mis-implants.com



Dr Scott D. Ganz

Editor-in-Chief



Our new world

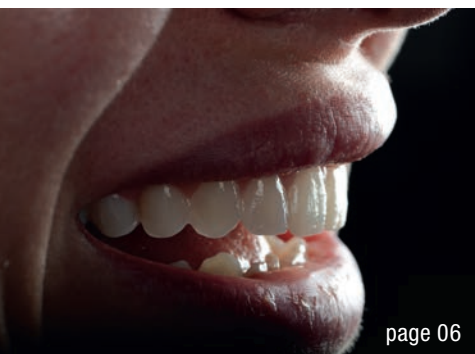In January, it appeared that the new year would start off very promising: 2020 was to be a great year of innovation, learning and prosperity in the dental industry. It was during that month that many of us became aware of something happening in China, an evolving epidemic caused by a new coronavirus strain. We were still going to events, travelling around the globe and busy in our practice of dentistry. In January, I had the honour of presenting at a major meeting in Istanbul in Turkey, where we were still shaking hands, hugging and sitting shoulder to shoulder listening to our colleagues present their work from the podium. At the end of January, the International Digital Days inaugural meeting was held in Paris in France—a wonderful and successful venue, plenty of vendors and products demonstrated, high-level presentations delivered by speakers from many different parts of the globe, and hands-on workshops too! There were also dinners with our colleagues, friends and corporate partners all in close proximity within the crowded restaurants. We went on planes, trains and automobiles; it was part of our everyday world. And then Europe started to notice that the virus was spreading.

In the US, one of our largest dental meetings, the Chicago Dental Society Midwinter Meeting, was held in late February, and there were thousands of participants at the various associated meetings located all around the heart of the windy city, one of which was a highlight for me: LMT LAB DAY, where digital is a major focus of an event held always at the Hyatt hotel. After long daily sessions, the bars were full at night, as were the great restaurants of Chicago. Then our world suddenly changed and came to a screeching halt.

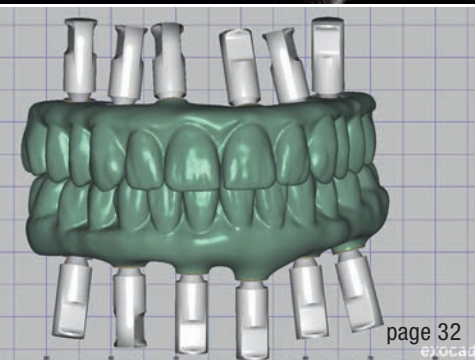
Within a few weeks, the McCormick Place convention centre in Chicago was transformed from one of the largest event halls in the US to a hospital to care for people ill with COVID-19. The same happened to the Javits Center in New York City and many others in the US and around the globe. The dental industry has been hard hit owing to our constant exposure to aerosols generated from intra-oral procedures. However, we in the dental industry are resilient, resourceful and innovative. Brilliant minds set to work immediately to help with the lack of certain supplies crucial to containing the spread of the virus, using the technology that we know so well, digital. We should be so proud of our industry for its ingenuity in producing 3D-printed face mask frames to help seal off the face from exposure, in response to the severe shortage of personal protective equipment, even offering free STL files for downloading, and 3D-printed nasopharyngeal test swabs, which are needed to collect samples, designed by clinicians and laboratory technicians fluent in CAD software. There are innovative designs for 3D-printed face masks with snap-on HEPA filters or specially fabricated suction devices to reduce exposure to aerosols.

Our new normal has redefined countries, cities, states, towns and populations across the globe. We will come out of this better and stronger. We are seeing an entirely new aspect of the power of technology and the new digital workflow that we rely on today and highlight in our publication. Stay safe, stay strong, stay healthy and keep innovating!

Respectfully,
Dr Scott D. Ganz
Editor-in-Chief



page 06



page 32



page 40

Cover image:
MStockPic/Shutterstock.com



editorial

Our new world 03
Dr Scott D. Ganz

case report

The art of a personalised smile design 06
Drs Galip Gürel, Dimitar Filtchev, Georgi Iliev, Braulio Paolucci & Adriano Schayder

Dental Anatomical Combinations—smile design harmony based on facial configuration 16
Giuseppe Romeo

Immediate implant placement and restoration in fractured central incisor with external root resorption 22
Drs Eirik Aasland Salvesen & Ida Koll-Frafjord

Implantation in a case of severely reduced interproximal width of the alveolar ridge in the anterior upper jaw 28
Dr Henrik-Christian Holloy

trends & applications

Full-arch implant surgical and restorative considerations 32
Drs Scott Ganz & Isaac Tawil

interview

IPS Implants Preprosthetics is a “useful addition for a specific patient group” 40
An interview with Prof. Gellrich and Dr Rahlf, Hannover Medical School, Germany

A new solution in the field of digital workflows 42
An interview with Adrian Hunn, CEO of Dentalpoint, Germany

manufacturer news 46

meetings

Embracing the challenge of taking IDEM digital 48

Virtual Nobel Biocare Global Symposium breaks registration record 50

practice management

Practice strategies in the age of corona 52
Dr Anna Maria Yiannikos

Ten guiding principles as we recover from lockdown and the COVID-19 pandemic 54
Chris Barrow

about the publisher

submission guidelines 56

international imprint 58

MAESTRO 3D

Innovative solutions for dental applications

www.maestro3d.com



2 x 5.0 MEGAPIXEL

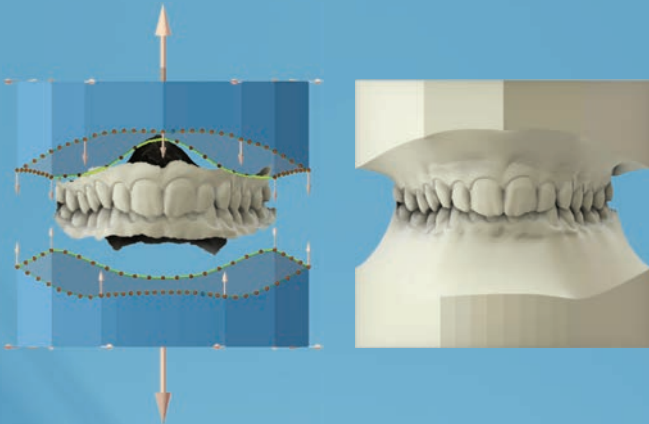
Plug & Play 

Smart Impression Scanning

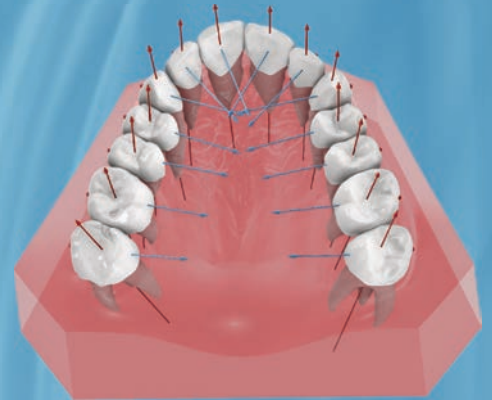
Accuracy less than 8 micron

Texture Superimposition

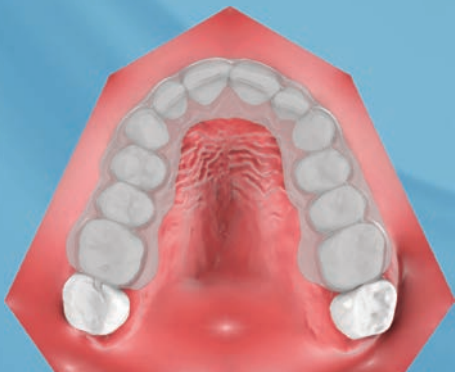
Study Models



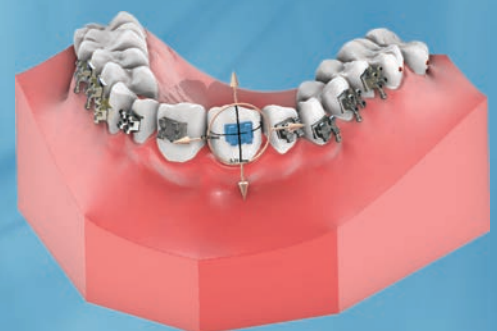Virtual Setup



Clear Aligner



Indirect Bonding



The art of a personalised smile design

Dr Galip Gürel, Turkey; Drs Dimitar Filtchev & Georgi Iliev, Bulgaria; Dr Braulio Paolucci & Adriano Schayder, Brazil

Introduction

Aesthetics has become one of the most important outcomes of dental treatments. Regardless of the complexity of the case, patients are seeking better-looking smiles. For many years, we, as dentists or laboratory technicians, have been using all the basic aesthetic rules in order to properly create a smile design. These rules should be fundamental to the design. At the end of the treatment, the patients should feel happy. If one can evoke this feeling with a smile design, both the dentist and the patient will be satisfied giving and receiving more than standard, well-aligned teeth. However, the final aesthetic results may often fail to meet the patient's expectations, owing to a disharmony between the smile design and the patient's identity. Patients' demands and the level of information needed have driven the profession to question itself regarding the customization of smile designs, which if ignored may lead to dissatisfaction with the aesthetic outcome, even though all the aesthetic principles and rules which tend to establish standards have been taken into account.

The mock-up

Visualisation of the smile design will have a great impact on the patient's understanding of the rest of the treatment. It is much more powerful than only verbally explaining what will be done. Prior to initiating any treatment, it is necessary to visualise the desired outcome. It then becomes possible to formulate the steps required to achieve this result.

Mock-ups facilitate significant improvement in communicating with the patient by showing him or her the potential final outcome of the treatment and allowing an easy comparison of the pre- and postoperative situations, and mock-ups allow the clinician to be able to check the functional aspects. Whether it is a case of worn dentition that requires altering the vertical dimension or just a straightforward veneer case, the aesthetic plane of occlusion and function will be based on the length—incisal edge position—and position of the an-

terior teeth. It is very difficult to convey the envisioned final length of the central incisors to the patient just by adding composite to the incisal edges of the central incisors; thus, the patient needs to see the whole smile, including the length and position of the posterior teeth. There are different ways to make the mock-up. It can be created directly in the patient's mouth or indirectly either through a wax-up or by using digital tools.

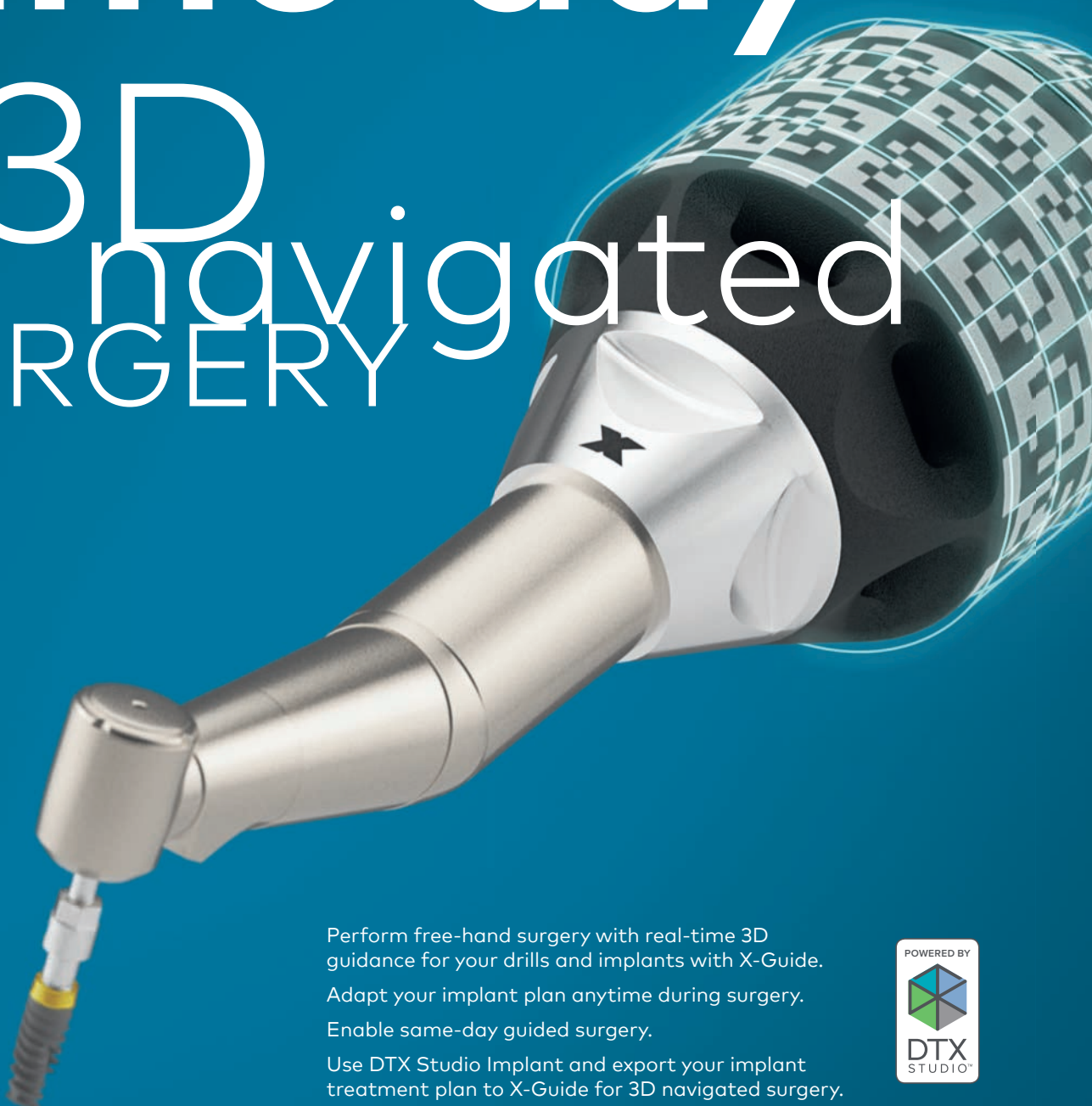
The personalised smile design

Every human being is unique and special and the design of his or her smile should reflect his or her personality. Shape, texture, colour and combination of teeth convey direct messages, and when it comes to creating smile designs, dentists must consider the unity of the whole, which means bringing the biology, structure, function and aesthetics together with a fifth element, personality. Personality is the quintessential part here, because the other four elements are traditionally laid to balance it like a keystone. Through the large number of smile design elements, such as incisal edge, dominance of central incisors, tooth axis and shape, as well as subelements such as morphological details of each tooth, it is possible to establish, based on the dental scientific literature, which should be determined by the facial typology and which could visually represent the unique personality of each patient, beyond his or her personal preferences and expression of his or her will.

Visual language

Each type of line or shape has a specific emotional meaning.¹ Lines represent the most basic elements of visual language. Horizontal lines, because they conform to gravity, express stability, passivity and calmness, while vertical lines represent the movement of the point against gravity, expressing strength and power, just as inclined lines arouse the sensation of instability, tendency to movement and dynamism. Curved lines are associated with delicacy, sensuality and the feminine gender.²

Same-day 3D navigated SURGERY



Perform free-hand surgery with real-time 3D guidance for your drills and implants with X-Guide.

Adapt your implant plan anytime during surgery.

Enable same-day guided surgery.

Use DTX Studio Implant and export your implant treatment plan to X-Guide for 3D navigated surgery.



nobelbiocare.com/x-guide

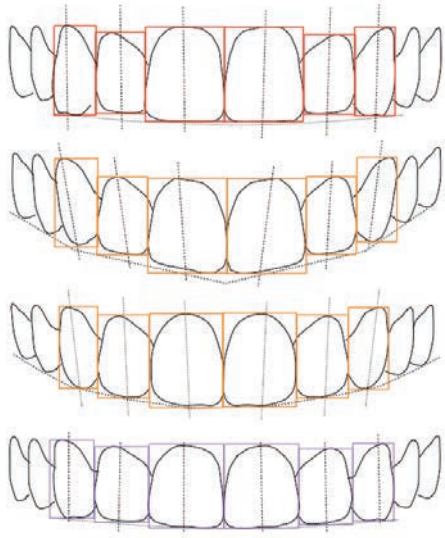
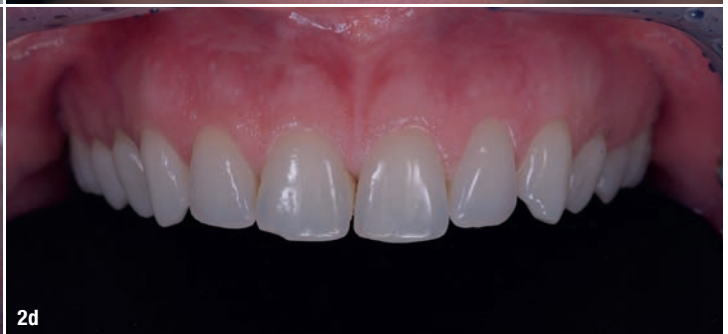
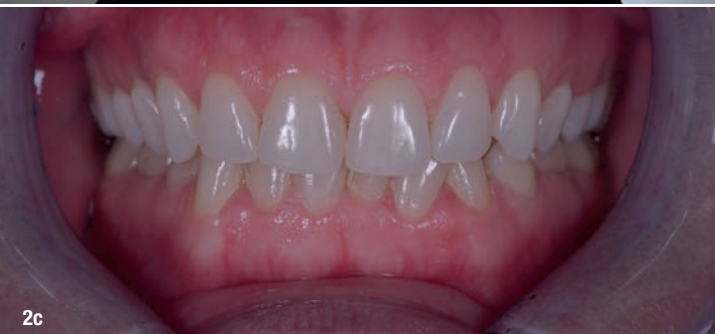
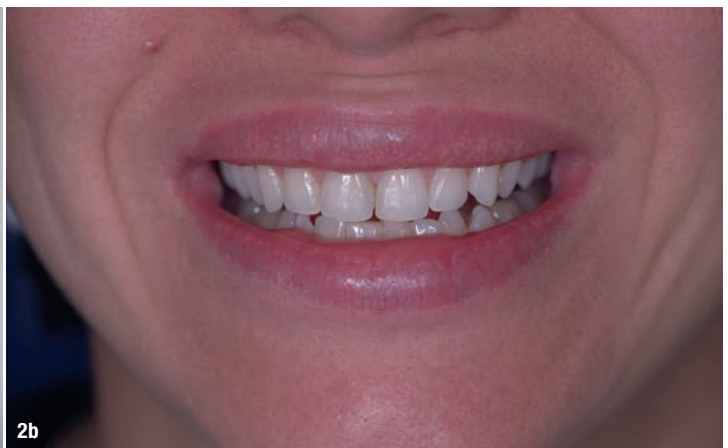Fig. 1: When the dentist first evaluates a new patient with aesthetic concerns, many critical factors may be overlooked. The verbal information exchange should be translated into a visual representation in order to aid in understanding what the final expectations should be at the end of the treatment, for the patient and the dentist. The basic means of this communication starts with a 3D preview of the design in the patient's mouth (APT: Aesthetic Pre-evaluative Temporaries) even before the rest of the treatment is planned. No matter what clinical difficulties a dentist will face and how problems will technically be solved, if the patient does not like the final aesthetic outcome, the treatment will be considered a failure.

The combination of lines generates the most basic forms, transferring to them their own expressions. Thus, the vertical rectangle expresses strength by the predominance of the vertical element on the horizontal, the triangle dynamism, the oval delicacy, the square stability and immobility with the balance between its vertical element and horizontal one. These basic shapes can be observed in the facial contour as well as in the incisors' shapes and 3D configuration of the dental arrangement, thus the incisal silhouette.

The visual language knowledge applied to the main expressive elements of smile design, such as dental shape, incisal edge, interdental ratio or dominance of central incisors, and 3D positioning of the teeth in the arch, determines four smile design types with primary expression (Fig. 1):

- Strong: composed mainly of rectangular dental shapes, strong dominance of the central incisors and canines over the lateral incisors (radial symmetry), as well as plane incisal edge and rectilinear 3D dental positioning on the arch from an occlusal view.
- Dynamic: triangular or trapezoidal dental shapes, standard dominance, inclined incisal edge and angled 3D dental positioning on the arch.
- Delicate: oval dental shapes, medium dominance, curved incisal edge and standard 3D dental positioning.



Figs. 2a-d: The aim of this aesthetic treatment was to enhance the patient's smile. However, additional to all the aesthetic smile design basics, the facial analysis and the personality of the patient should be reflected in this design, in order to create the most natural, minimally invasive, personalised smile design.

- Calm or stable: smoothly rounded square dental shapes, weak dominance (current symmetry), horizontal incisal edge and 3D rectilinear or standard dental positioning on the arch.

Case presentation

The patient had short teeth and was not happy with the narrow buccal corridors and the yellowish colour of her teeth (Figs. 2a–d).

Aesthetic analysis and Rebel Simplicity

Aesthetic design can be challenging for dentists. Rebel (Visagismile) is a recent digital previsualisation technique that allows the clinician to:

- efficiently design the new smile;
- improve the communication between the dental team members involved in the treatment;
- obtain better communication and achieve better patient motivation; and
- visualise the final aesthetic result even before the treatment is started.

3D Rebel smile design plays an important role in the entire treatment planning and will guide the actual clinical treatment. This approach makes it possible to share the treatment plan among team members and to create a 3D visualisation of the case in the patient's mouth. The digital project will be tested and approved even before starting the actual treatment. Accordingly, it will allow the dentist to present the treatment solution.

The Rebel workflow

Rebel offers probably the simplest steps for transferring all the necessary information to the Rebel digital laboratory.

These are the three mandatory steps:

1. a single mock-up on a central incisor to be digitally scanned;
2. a full-face photographic protocol; and
3. a simple questionnaire.

Single central incisor mock-up and intra-oral digital scanning

A composite mock-up is performed on one (or two) of the central incisors in order to identify the incisal edge position vertically and the position of the facial surface buccolingually (Fig. 3). This is no different from creating any direct mock-up; however, the greatest advantage of creating this mock-up for Rebel is that the dentist does not need to concern himself or herself with the perfect design of this mock-up, meaning that he or she does not need to choose the shape of

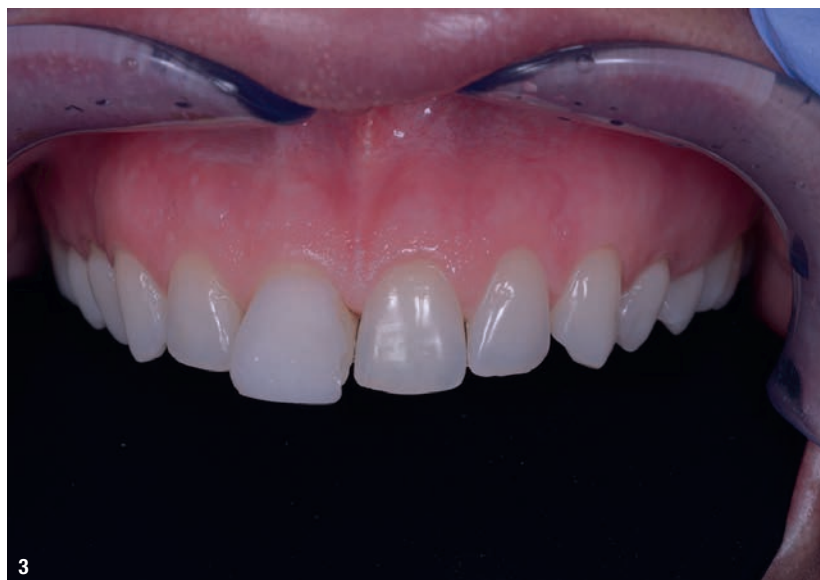

Fig. 3: Once the mock-up on the central incisor has been completed, it should be digitally scanned. It can be scanned with any intraoral scanner that can produce an STL file. Most intra-oral scanners convert the 3D scan into an STL file automatically. However, if the dentist does not have an intra-oral scanner in the dental practice, an analog impression of the upper jaw (preferably with the direct mock-up done on the central incisors) is taken and sent to the nearest dental laboratory that owns a scanner (laboratories that work with a CAD/CAM machine will have a digital scanner). The dental technician can digitalise this impression for the dentist and upload the STL file to Rebel, in order to complete the order via a provided link.

the tooth (square, triangular, rounded, etc.), the angulations of the axes of the teeth, surface texture, etc. These details of the smile design will be provided by the Rebel artificial intelligence-based software, according to the facial analysis and the personality of the patient. Therefore, this will allow any dentist at any level to start working with mock-ups and end up with high-level wax-ups.

If the dentist does not wish to make a mock-up, then he or she can alternatively write down the additional length that would be needed to be added to the central incisors vertically, and the volume on the facial aspect (e.g., 0.3mm thicker facially). In that case, the dentist can easily relate the existing length of the teeth to the upper lip position with the help of a periodontal probe. This information should be noted (the additional length that is needed to be added to the central incisors vertically and the volume on the facial aspect e.g., 0.3mm thicker facially) and included in the file that will be sent to Rebel.

Full-face photographic protocol

The software requires five full-face photographs for facial analysis and classification of the patient and for relation of the 3D intra-oral digital scan to the facial