

# DENTAL TRIBUNE

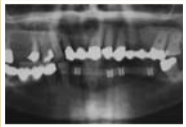
The World's Dental Newspaper • Pakistan Edition



PUBLISHED IN PAKISTAN

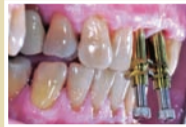www.dental-tribune.com.pk

MAY, 2017 - Issue No. 03 Vol.4



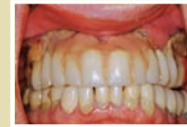*Guided Bone  
Regeneration using  
NeoGen ...*

*CLINICAL IMPLANTOLOGY* ▶ Page 6



*The synthesis of  
aesthetics, health  
and structural ...*

*CLINICAL IMPLANTOLOGY* ▶ Page 8



*Considerations for  
Long Term Success  
Implants ...*

*CLINICAL IMPLANTOLOGY* ▶ Page 12

## WOHD 2017 marks National Tooth-brushing record

*DT Pakistan Report*

**K**ARACHI - World Oral Health Day (WOHD) celebrated yearly on March 20th to create awareness about the oral health by promoting worldwide awareness of the issues and the importance of looking after oral hygiene to everyone old and young. □

2017 World Oral Health Day where Dental Tribune in collaboration with Shield Corporation and Pakistan Dental Association launched a nationwide campaign to create awareness about oral health diseases. The campaign supported by FDI, JPDA, DTI, APDF and many

2000 people to brush together amid much fanfare. □

Campaign like these help in identifying problems in a timely manner. In Pakistan the incidence of Oral Cancer is the third biggest cancer and needs urgent attention. □

Dental tribune which has



According to reports Oral diseases affect 90% of the world's population in their lifetime, many of which can be prevented with increased governmental, health association and society support and funding for prevention, detection and treatment programs. Live Mouth Smart - the theme of

partner associations and the local event sponsor Shield Corporation turned out to be a huge success. □

Baqai Medical University, Community Dentistry, stole the show by setting a National Tooth Brushing Record in collaboration with Dental Tribune and Shield Corporation gathering more than

spearheaded and initiated the World Oral Health Day in Pakistan with its sponsor Shield Corporation since 2010 has been working tirelessly to create oral health awareness throughout Pakistan with continued support from dental institutions where OPDs are free to mark the day.

### NID HOSTS NISHTAR DENTAL CONFERENCE

## *Bridging the gap between research and practice*

*DT Pakistan Report*

**T**he Nishtar Dental Conference 2017 was recently held in Nishtar Institute of Dentistry (NID) Multan. The theme of the conference was "Bridging the gap between research and practice". The conference was formally inaugurated by the chief guest Mr. Bilal Ahmed Butt, Deputy Commissioner Multan. The patron-in-chief was Prof Dr Riaz Ahmed Warraich, renowned maxillofacial surgeon and Principal NID, Multan. Patron was Prof. Dr. Pervaiz Iqbal. Organizing secretary was Dr. Waqas Ahmed, Fellow Royal College of Surgeons; and the guest of honour was Mr. Rana Saleem, provincial health manager for Govt. of Punjab, and currently deputed as DC Bahawalpur. □

In his address the chief guest Mr. Bilal Ahmed Butt appreciated the professional commitment of the dental faculty of Pakistan who participated in the conference from far and wide. He also congratulated the organizers for arranging such a beneficial event. Earlier, Patron-in-chief Dr. Riaz Ahmed Warraich said that opportunities



*Continued on Page 15*

## EXCIDA 2017 - 57th exhibition and congress of IDA

*DT Pakistan Report*

**K**ARACHI - The 57th exhibition and congress of Iranian dental association (EXCIDA 57) will be convened in Tehran on 14-18 May 2017. EXCIDA is the most established dental congress and exhibition and the leading continuing dental education provider for the Iranian dental professionals. It gains prominence every passing year with its particular objective to enhance the scientific knowledge and practice of dentistry. The theme of 2107 congress is declaration of oral health rights (Persian collaboration) which describes the efforts in education, prevention and treatment of government and private sector of Iranian dental community and will bring world class speakers and dental professionals across the globe to offer a comprehensive and extensive program with workshops and 10000 square meter exhibition.

## *Dentistry 13,000 Years Ago Was Not So Easy*

*Monitoring Desk*

**I**TALY - Humans have always taken dental care seriously and even in Ice age Europe, 13,000 years ago, people are finding ways on how to fix tooth cavities. However, the downside to this is that people back then would have suffered horrendously painful surgeries as they drill out cavities and fill it up with anything ranging from vegetable fiber to beeswax to gold fillings. □

Archeological news on Discovery Magazine reported the discovery of dental work on a 13,000-year-old tooth in Northern Italy revealing primitive attempt to fill up cavities. The tooth shows signs of being drilled by a crude equipment, which one can only imagine the pain one endures. The specimen discovered in Italy was from a person who died during the ice age, with teeth drilled and filled with hair and bitumen or tar. It would be quite an experience to be under the hands of a primitive doctor as he grinds on one's molar without any pain reliever whatsoever. □

According to an article published by the  
*Continued on Page 15*

# FDI prepares for congress in Madrid, breaks abstract submission record

DT International

**M**ADRID, SPAIN - From 29 August to 1 September, the FDI World Dental Federation is hosting its Annual World Dental Congress (AWDC) in Madrid. Visitors will be able to attend lectures given by prominent international speakers on the latest advances related to dentistry and oral health. In addition, they will have the opportunity to attend the accompanying exhibition and hands-on sessions according to their preferences. With over 1,000 abstracts from 46 countries submitted-more than ever before-a new record has been set even before the event has begun. □

The abstracts received for 486 posters and 534 oral presentations exceeded by far the number submitted for all previous AWDCs. The abstracts were submitted by dental professionals from 46 countries for the various categories according to their topic: 151 on general dentistry, 170 addressing preventative dentistry, 462 concerning dental treatment and restorative dentistry, and 237 about oral surgery, medicine and cancer. All of the accepted abstracts will be published in a special issue of the International Dental Journal, the official journal of the FDI World

Dental Federation. □

According to Dr Óscar Castro, President of Consejo General de Colegios de Odontólogos y Estomatólogos de España (the Spanish dental association) and chairperson of the 2017 AWDC organising committee, "The number of abstracts received reflects the magnitude of the forthcoming FDI congress, which will be the largest dental event of the year." □



With the participation of distinguished dental professionals from all over the world, the event will be an international showcase of the research and clinical work of leading experts and will give attendees the opportunity to exchange opinions with more than 10,000 other visitors.

The congress in Madrid will offer the opportunity to interact with well-known international speakers during the Meet the Expert sessions. The scheduled eight subject areas to be covered are periodontics and implantology (Drs Karl Ludwig Ackermann and Stefan Fickl, Germany); prosthodontics (Prof.

Matthias Kern, Germany); cariology (Dr Amid Ismail, US); anaesthesia (Prof. Stanley F. Malamed, US); treatment planning and patient assessment (Dr Nikos Mattheos, China); dental materials (Prof. Junji Tagami, Japan); temporomandibular joint dysfunction syndrome, the temporomandibular joint and occlusion (Prof. Jens Christoph Türp, Switzerland); and orthodontics (Dr

Javier de la Cruz Pérez, Spain). The scientific programme will feature 47 expert speakers from 24 countries and cover nearly 30 major areas and topics of concern to today's dental and oral health practitioners. The parallel Spanish programme will cover 28 lectures in 12 fields of dentistry, including public health, dental materials, periodontics and restorative dentistry, by 26 speakers. □

In addition, the event will offer a social programme, including Spanish Night, which will be held on 30 August at the Plaza de Toros de Las Ventas, one of the architectural highlights of the city of Madrid. On the following evening, the gala dinner will be hosted in the historic Galería de Cristal, a prestigious venue for international banquets and events. □

The FDI Madrid 2017 App, with a detailed congress programme and exhibitor list, will be available soon.

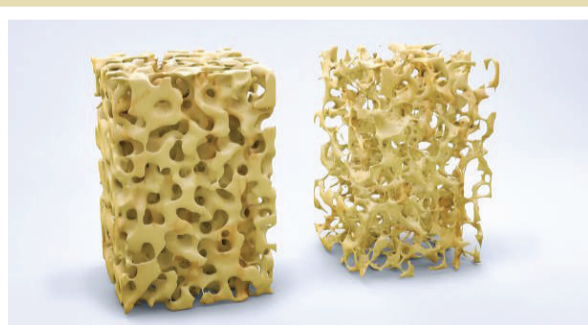
## Osteoporosis: Resolvable magnesium implants may promote bone formation

DT International

**M**ALMÖ, SWEDEN - According to new research from Sweden, a groundbreaking method for stimulating bone formation around implants could soon be available. In testing the cellular and molecular effects of magnesium-based implants in the early healing stages of implant integration, the researchers found that the release of magnesium promoted rapid bone formation and the activation of osteogenic signals near implants placed in osteoporotic bone.

"We observed that the implant material disappeared, having formed calcium and phosphate, which are similar to bone structure," lead researcher and doctoral student Silvia Galli from Malmö University's Faculty of Odontology told public broadcaster Sveriges Radio. By using magnesium-based implants that dissolve completely over time instead of titanium ones, osseointegration in osteoporotic patients thus might be enhanced. □

The use of magnesium-based implants could be a potential method for restoring skulls after facial fractures through promoting new bone tissue formation as the implant dissolves over time. According to Galli, the amount of metal used in the implants is so insignificant that it leaves the body without a trace of the traumatic event having taken place and without any side-effects for the kidneys, or the need for a second surgical procedure to



Healthy vs. osteoporotic bone structure. Magnesium implants that dissolve over time may enhance bone formation in patients with impaired bone healing, such as people suffering from osteoporosis, research indicates.

remove the implant, for example. □

Thus far, the method has only been tested in animal models and will need more research before proceeding with clinical tests on human patients, Prof. Lars Magnus Bjursten from Lund University emphasised in the radio interview. However, he said that it is important to always look for alternatives, particularly in orthopaedics, and magnesium seems to be a useful material. □

Whether the method could potentially assist osseointegration around dental implants was not addressed in the current research project.

### DENTAL TRIBUNE

The World's Dental Newspaper - Pakistan Edition

#### Publisher/CEO

Syed Hashim A. Hasan □  
hashim@dental-tribune.com.pk

**Editor Clinical Research:** Dr. Inayatullah Padhiar

**Editors Research & Public Health**  
Prof. Dr. Ayyaz Ali Khan

**Editor - Online:** Haseeb Uddin

**Associate Editor:** Dr Amna Nayyar

**Designing & Layout:** Sh. M. Sadiq Ali

#### Dental Tribune Pakistan

3rd floor, Mahmood Centre, BC-11, Block-9  
Clifton, Karachi, Pakistan.  
Tel.: +92 21 35378440-2 | Fax: +92 21 35836940  
www.dental-tribune.com.pk  
info@dental-tribune.com.pk

Dental Tribune Pakistan cannot assume responsibility for the validity of product claims or for typographical errors. The publisher also does not assume responsibility for product names or statements made by advertisers. Opinions expressed by authors are their own and may not reflect of **Dental Tribune Pakistan**.

#### International Imprint

Group Editor □ □ **Daniel Zimmermann** □  
newsroom@dental-tribune.com □  
Tel.: +44 161 112 1830

Clinical Editors □

**Magda Wojtkiewicz**

**Nathalie Schüller**

Online Editor/Social Media Manager

**Claudia Duschek**

Editors □

**Kristin Hübner**

**Yvonne Bachmann**

Managing Editor & Head of □ **Marc Chalupsky**

DTI Communication Services

Junior PR Editor □

**Brendan Day**

**Julia Maciejek**

Copy Editors □

**Hans Motschmann**

**Sabrina Raaff**

Publisher/President/CEO □

**Torsten R. Oemus**

Chief Financial Officer □

**Dan Wunderlich**

Chief Technology Officer □

**Serban Veres**

Business Development Manager

**Claudia Salwiczek-Majonek** □

Project Manager Online □

**Tom Carvalho**

Junior Project Manager Online □

**Hannes Kuschick**

E-Learning Manager □

**Lars Hoffmann**

Education Director Tribune CME □

**Christiane Ferret**

Event Services/Project Manager **Sarah Schubert**

Tribune CME & CROIXTURE

Marketing Services □

**Nadine Dehmel**

Sales Services □

**Nicole André**

Accounting Services □

**Anja Maywald**

**Karen Hamatschek**

**Manuela Hunger**

Media Sales Managers □

**Antje Kahnt** (International)

**Barbora Solarova** (Eastern Europe)

**Hélène Carpentier** (Western Europe)

**Maria Kaiser** (North America)

**Matthias Diessner** (Key Accounts)

**Melissa Brown** (International) □

**Peter Witteczek** (Asia Pacific)

**Weridiana Mageswki** (Latin America)

Executive Producer □

**Gernot Meyer**

Advertising Disposition □

**Marius Mezger**

#### Dental Tribune International

Holbeinstr. 29, 04229 Leipzig, Germany

Tel.: +49 341 48 474 302 | Fax: +49 341 48 474 173

info@dental-tribune.com | www.dental-tribune.com

#### Regional Offices

##### Asia Pacific

Dental Tribune Asia Pacific Limited

c/o Yonto Risio Communications Ltd.

Room 1406, Rightful Centre

12 Tak Hing Street, Jordan, Kowloon, Hong Kong

Tel.: +852 3113 6177 | Fax: +852 3113 6199

##### The Americas

Tribune America, LLC

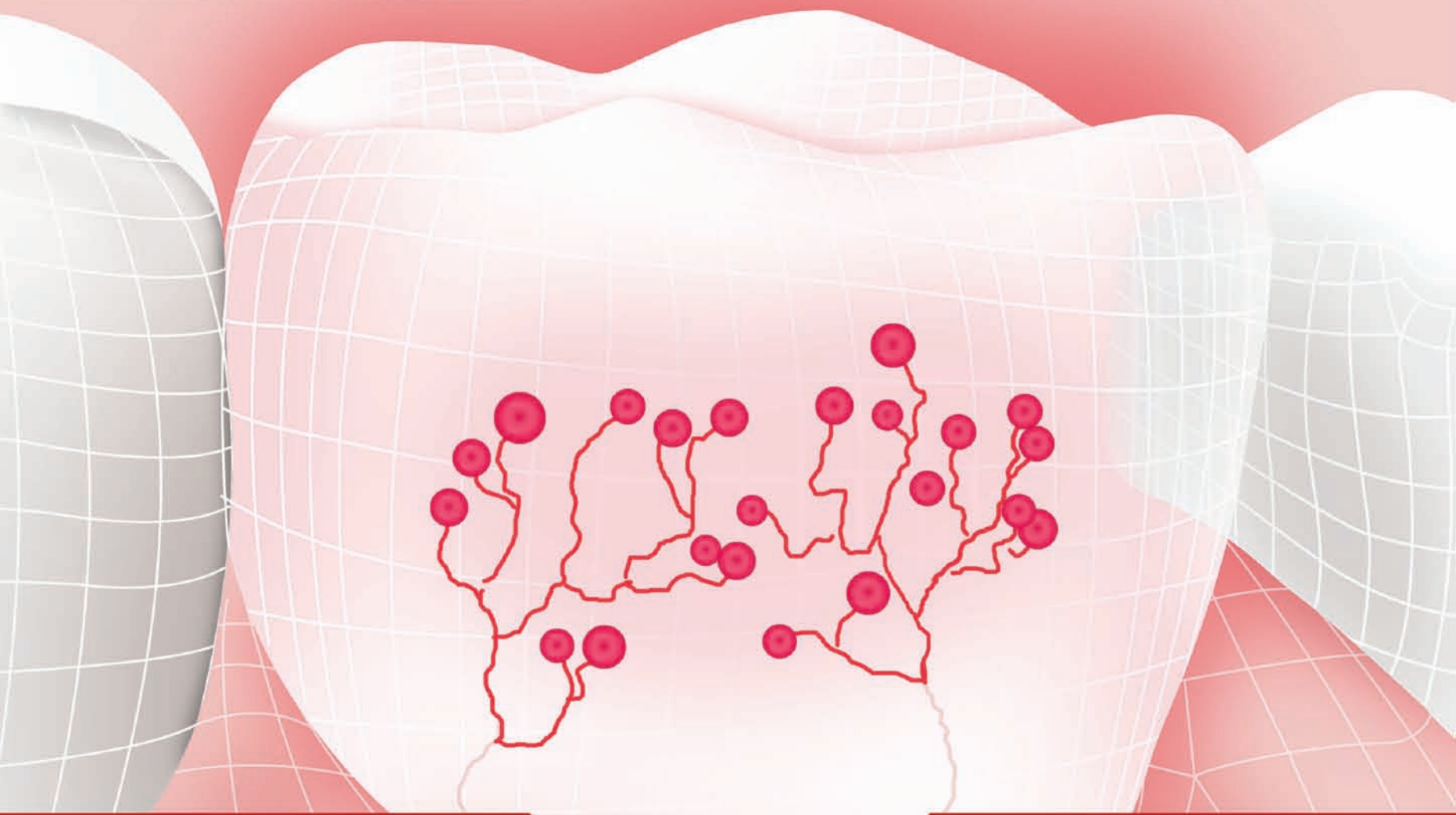
116 West 23rd Street, Ste. 500, New York, N.Y.

10011, USA

Tel.: +1 212 244 7181 | Fax: +1 212 244 7185

**Colgate**

**Sensitive Pro-Relief™**



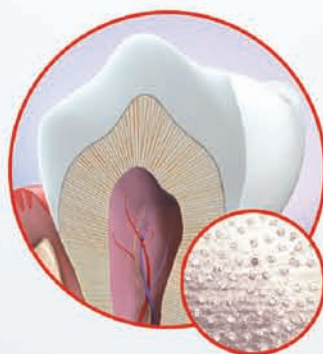
**REPAIR**  
THE CAUSE

**PREVENT**  
PAIN RETURNING

# THERE'S A BETTER WAY TO TREAT SENSITIVE TEETH. ^

## REPAIR

Forms a calcium-rich layer and helps repair<sup>†</sup> sensitive areas of teeth for instant and superior relief<sup>^, 1-3</sup>



## PREVENT

Regular use helps strengthen gums and provides lasting protection to prevent further tooth sensitivity



**Colgate®**

**PAKISTAN'S #1 SENSITIVITY TOOTHPASTE RECOMMENDED BY DENTISTS\***

\*Based on Professional Dentists Tracking Study - IPSOS Pakistan Nov 2015

^ vs. toothpastes with 5% potassium nitrate. For instant relief, apply directly to the sensitive tooth and gently massage for 1 minute.  
Reference: 1. Li Y et al. J Clin Dent. 2011; 22(Spec Iss):113-120. 2. Nathoo S et al. J Clin Dent 2009; 20 (Spec Iss):123-130. 3. Ayad F et al. J Clin Dent. 2009; 20 (Spec Iss): 10-16.

# A personal experience of RECIPROC blue in endodontic practice

By Marc Chalupsky

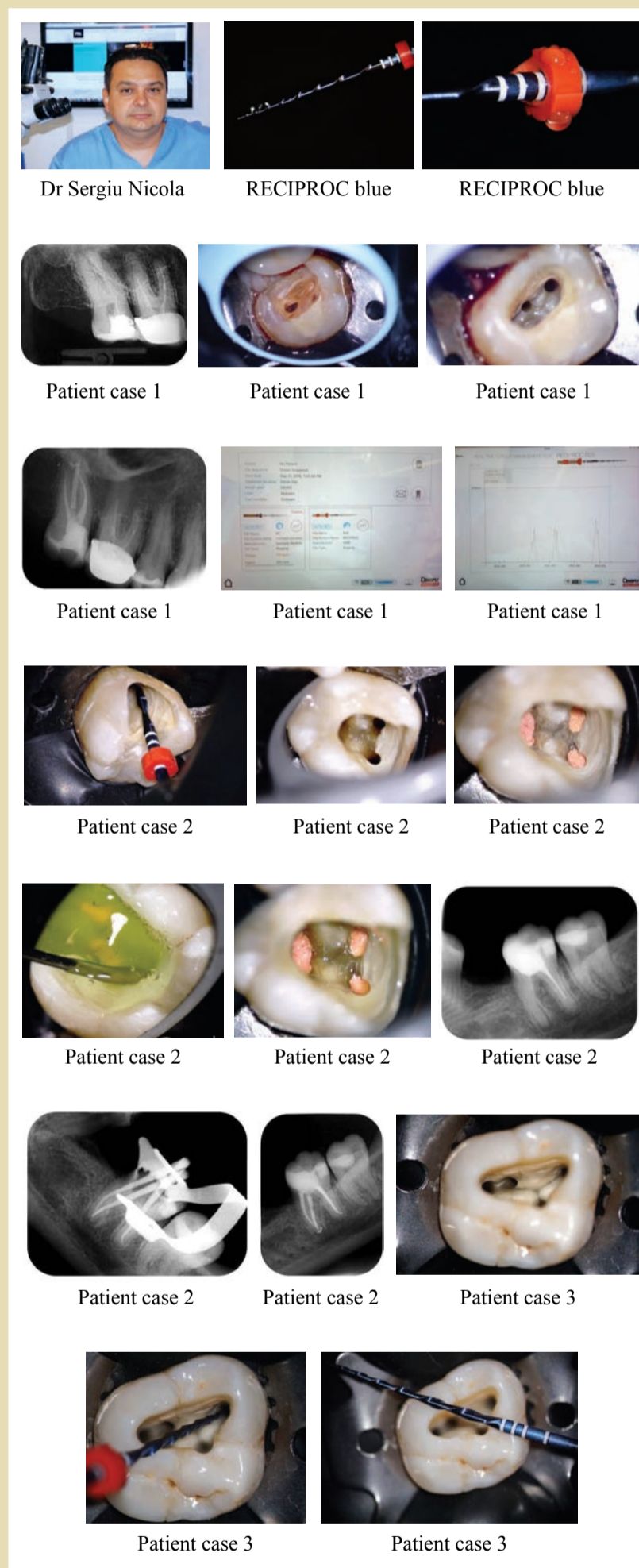
One of the worst things that can happen during a root canal procedure is an instrument breaking. The curvature of particular root canals makes using stiff endodontic files impossible and creates unwanted complications. With its newly released line of RECIPROC blue files, VDW has made a breakthrough in endodontics. Owing to a revolutionary production process, RECIPROC blue files are more flexible and less fracture-prone than any other files. Dental Tribune International spoke with Dr Sergiu Nicola, a leading endodontist based in Bucharest in Romania, about his experiences with using the RECIPROC blue file.

**Dr Nicola, you run an established practice limited to endodontics in Bucharest. Could you please introduce yourself and tell us more about your daily cases?** □

I graduated from the Faculty of Dentistry of the Carol Davila University of Medicine and Pharmacy in Bucharest in 2003 before receiving a Master of Endodontics in 2008. I have limited my practice to endodontics since 2006, and I mostly deal with non-surgical root canal retreatments.

**Many of your colleagues continue to perform conventional preparation, while you have been working with rotary and reciprocating instruments, as well as endodontic motors. Why did you switch, and what would you tell colleagues who have not yet switched?** □

Well, with the large volume of cases in my office, I soon discovered that I should use rotary preparation instead of manually shaping the root canals. Rotary preparation is a great deal faster and allows me to focus on other important things, like increasing the irrigation. My experience with reciprocating instruments began in 2008, prompted by an article published by Dr Ghassan Yared regarding canal preparation with only one NiTi instrument. Seeing Dr Yared's root canal treatments performed with only the F2 ProTaper, often without a glide path, moving in a reciprocating motion helped me understand that using a file in a reciprocating motion enhances its ability. Soon thereafter, several studies showed that a reciprocating file was more resistant to fracture than classically rotating files. The only drawback was that the only motor available for reciprocating instruments was a brushed motor and I personally destroyed a number of them. But, in 2011, VDW launched the RECIPROC file and a new motor—the VDW RECIPROC motor—that was a



brushless motor, virtually eliminating wear and tear. I was probably the first person to buy the motor in Romania.

**What files are most suitable for narrow invisible canals and medium to wide visible canals?** □

The minimum diameter in an MB2

canal, which is the most challenging one to prepare, is about 0.15 mm at 1 mm short of working length. This means that it is difficult to bypass coronal interferences in order to reach the working length. The calcified canals are only calcified at the point

of entry, usually to a depth of 1–2 mm. Armed with this knowledge, I use a pre-flare introductory file, a ProTaper to quickly eliminate coronal interferences and go through the primary calcifications, then RECIPROC. However, I often start negotiating the calcified canals directly with RECIPROC, even though it appears to be too thick a file to be used in a narrow thin canal. The ability of the file to self-centre and its stiffness are very helpful. With the new RECIPROC blue, the file is more flexible than ever before and the need for other super-elastic files is diminished.

**What combination of instruments from preparation to obturation do you usually prefer?** □

I use an S1 ProTaper for quickly eliminating coronal interferences and then a R25. Most of the time, I reach the working length in a couple of minutes, which allows more time for irrigating.

Could you tell us more about some of the cases in which you have used RECIPROC blue?

In vital and necrotic cases, I use RECIPROC blue, but I still start with the old R25 in retreatments, since it is a little bit stiffer and I can apply more pressure when working out the old root canal fillings. For example, a great way to remove the plastic carriers is to forcefully push the R25 into them, as it shreds the carrier quite quickly.

**What should one pay attention to when preparing irregular shaped canals with RECIPROC blue?** □

When I deal with a severely curved canal or with a double curvature, after each insertion of the RECIPROC file, I usually scout 2–3 mm ahead with either a manual or a rotary narrow file. This is because RECIPROC files, being so active and fast, have a tendency to generate a great deal of debris. In narrow or multiple curvature canals, this can sometimes block the canal.

**Would you recommend RECIPROC blue to your colleagues?** □

First of all, I would recommend switching to reciprocation instead of rotary use of files. Reciprocation offers a whole new world in the mechanical preparation of the main root canals. It is safer, faster and most likely cheaper, since there are fewer files involved. If dentists want to try a reciprocating system, why not start directly with the best system currently available on the market in my opinion—VDW RECIPROC and VDW RECIPROC blue? And I say this without having any financial interest whatsoever. - DT

**SENSODYNE®**



**RAPID ACTION**  
& LONG LASTING PROTECTION

**CLINICALLY PROVEN SENSITIVITY RELIEF.  
WORKS IN 60 SECONDS\***



\*when used as directed on pack

GSK is committed to the effective collection and management of human safety information relating to our products and we encourage healthcare professionals to report adverse events to us on +92 (21) 111-475-725 or [pk\\_pharmasafety@gsk.com](mailto:pk_pharmasafety@gsk.com)

FMCG - 04/14 - 161

# Guided Bone Regeneration using NeoGen Ti-Reinforced Membranes: Case Reports

By Neoss Ltd, Cases & Dr Norbert Hassfurther

Membranes are used in Guided Bone Regeneration (GBR) to aid in the regenerative healing of bone defects. The membrane is surgically placed under the oral mucosa. It stops the soft tissue from growing into the defect and creates space for complete fill of the defect with regenerated bone.

In many cases where substantial bone regeneration is required, such as vertical bone augmentation, a titanium-reinforced non-resorbable membrane is required to achieve predictable results.

NeoGen Ti-reinforced Membrane is a new generation of non-resorbable titanium-reinforced membrane combining the handling and tissue interactions of expanded PTFE with the enhanced barrier function offered by dense PTFE. The membrane has a three-layer design. The outer, soft tissue friendly, PTFE layer has a tight texture that is impermeable to bacteria; the middle layer is a strong and highly shapeable titanium mesh that retains its shape throughout the healing period; and the inner PTFE layer has an expanded texture that enables predictable hard tissue integration.

This combination results in a membrane that is easy to handle and protects the augmentation site in a predictable manner.

This article describes three cases of GBR using a Ti-reinforced PTFE membrane and simultaneously placed dental implants without the use of bone substitutes.

## Case 1

### Vertical ridge augmentation of severely resorbed mandible

A 52 year old male was referred to the clinic with a severely resorbed anterior mandible due to a failed bone graft after removal of a large cyst (Figure 1). Pre-treatment radiographic assessment (Figure 2) showed that the bone height was inadequate to properly house implants. It was decided to perform a vertical ridge augmentation using NeoGen™ Ti-Reinforced Membrane and simultaneous placement of Neoss ProActive Straight Implants.

A full thickness flap with releasing incisions was opened and four Neoss ProActive Straight implants were placed; two anterior and two posterior. The vertical defect between the two anterior implants was 5-6 mm

(Figure 3). Autogenous bone cylinders (3.4 x 4-5 mm) were harvested from the oblique line of the mandible in the molar region and placed between the two anterior implants to accelerate regeneration and to act as space fillers. A NeoGen™ Ti-Reinforced Membrane Large was trimmed, shaped, and fitted at the surgical site and secured buccally with two tacks (Figure 4). A stable membrane configuration was achieved using the implants as tent posts (Figure 5). Stress free flap closure was achieved by releasing the periosteum on the buccal side. The soft tissue healing was uneventful (Figure 6).

After 4-5 months, second stage surgery was performed. A mid-crestal incision was used to lift a flap and expose the membrane. The membrane was removed, excess bone removed and PEEK healing abutments were connected to the implants. As seen in figure 7, the implants were totally enclosed in newly formed bone, and the ridge had been regenerated to the desired height.

## Case 2

### Regeneration of an extremely narrow ridge

A 19 year old female presented with

two congenitally missing teeth in the premolar area of the upper jaw, resulting in a very narrow atrophic ridge, with inadequate bone width to properly house implants (Figure 8). The treatment plan included regeneration of the ridge using NeoGen™ Ti-Reinforced Membrane and simultaneously placed Neoss ProActive Straight Implants.

A full thickness flap was opened, osteotomies were prepared on the palatal aspect of the ridge, and two Neoss ProActive Straight implants were placed. Both implant sites had fenestrations on the buccal side (Figure 9) and palatal dehiscences (Figure 10). A NeoGen™ Ti-Reinforced Membrane Medium was trimmed, shaped, and fitted at the implant site. Autogenous bone chips collected during drilling of the implant osteotomies were used to fill the palatal dehiscence (Figure 11). No material was used to fill the buccal fenestration, the strength of the mesh created the space for bone regeneration. The membrane was secured with two tacks buccally (Figure 12). Flap closure was achieved, and the soft tissue healing was uneventful (Figure 13).

After 7 months, second stage surgery

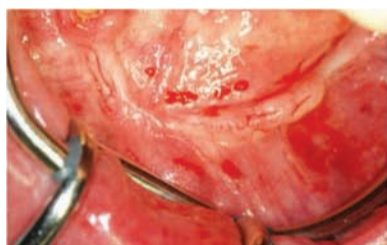


Fig 1

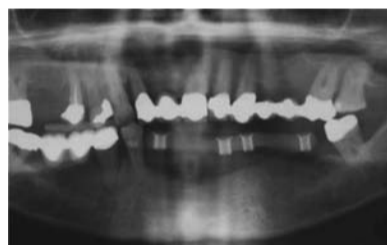

Fig 2

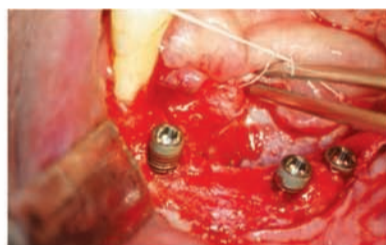


Fig 3

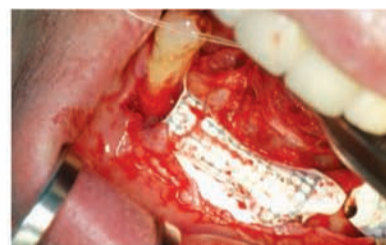

Fig 4

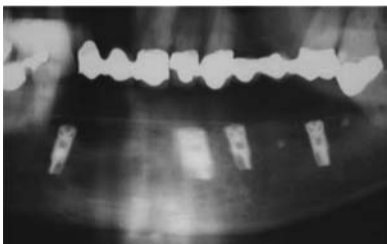


Fig 5

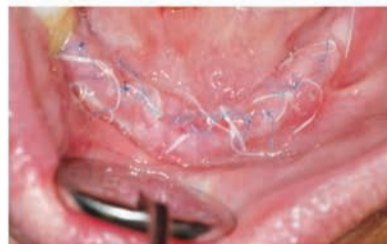


Fig 6

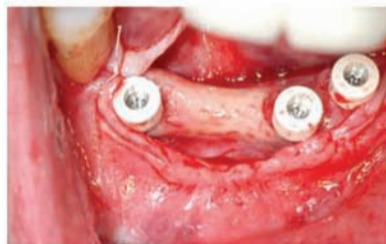


Fig 7

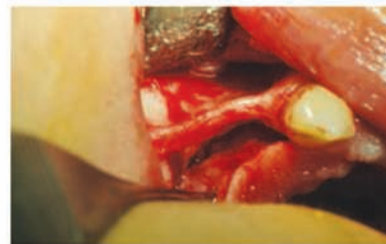

Fig 8

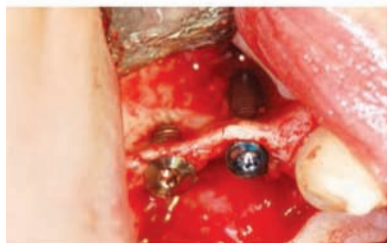

Fig 9

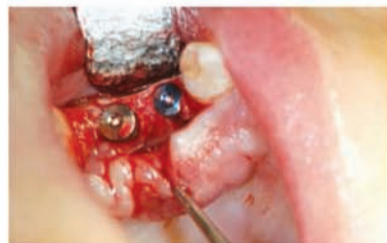

Fig 10

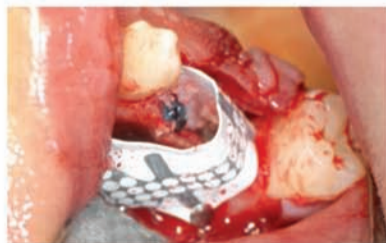

Fig 11

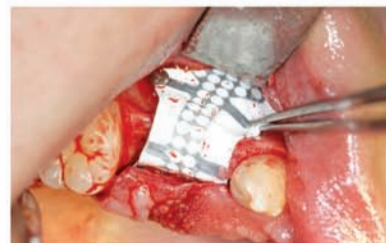

Fig 12

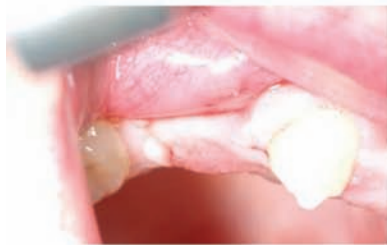

Fig 13

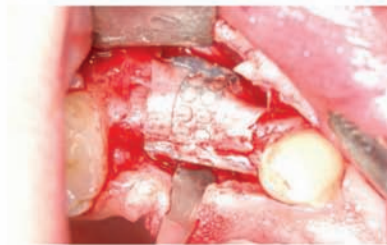

Fig 14

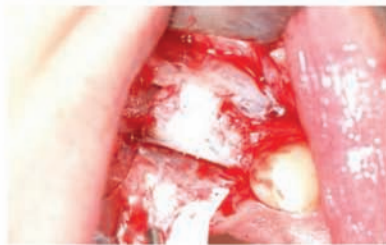

Fig 15

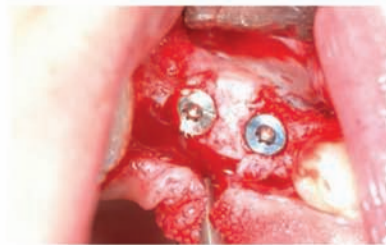

Fig 16

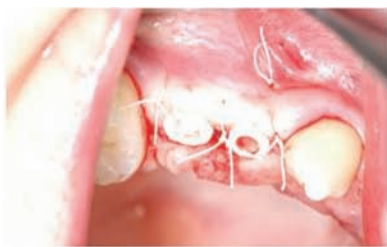

Fig 17

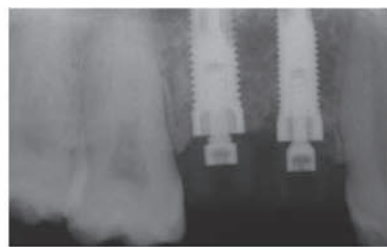

Fig 18

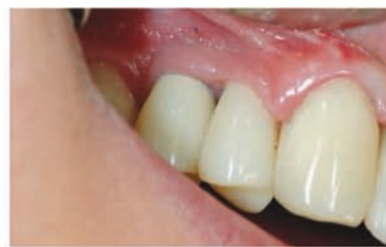

Fig 19

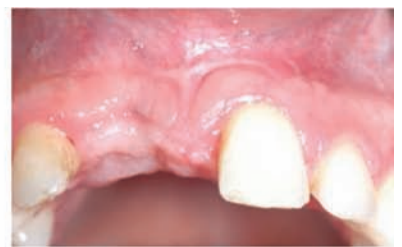

Fig 20

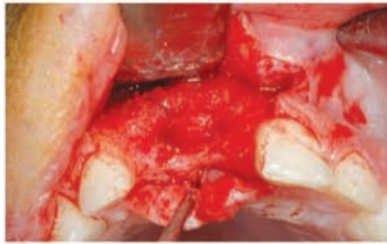

Fig 21

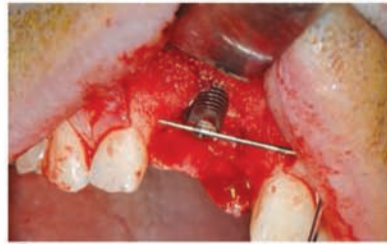

Fig 22

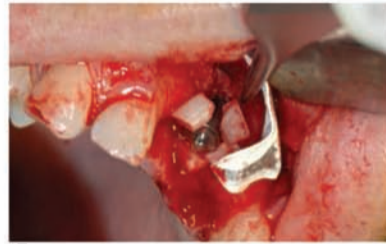


Fig 23

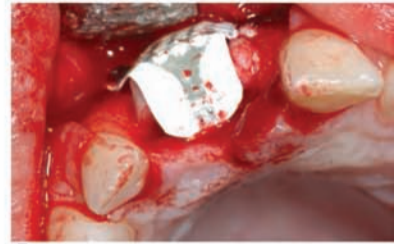

Fig 24

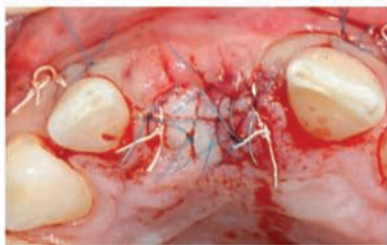

Fig 25

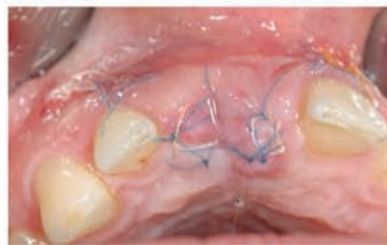

Fig 26

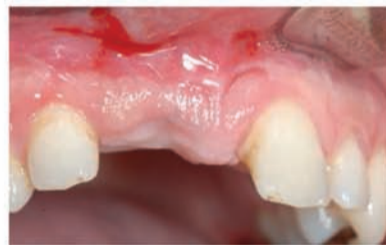

Fig 27

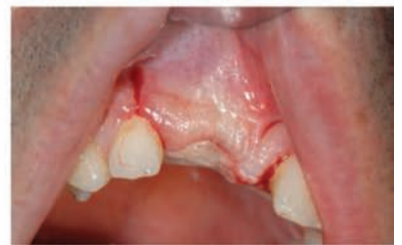

Fig 28

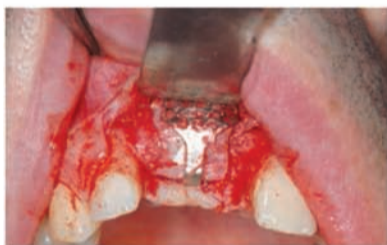

Fig 29

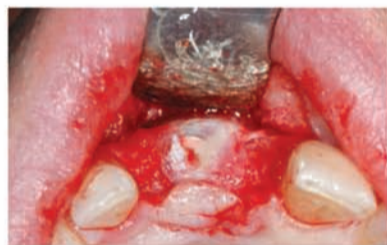

Fig 30

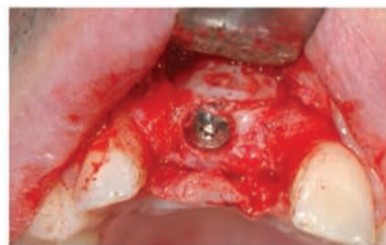

Fig 31

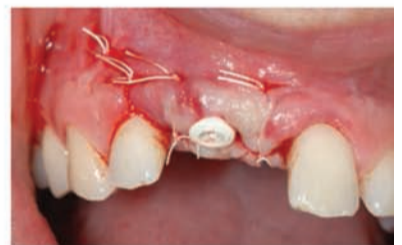

Fig 32

was performed. A mid-crestal incision with releasing incisions was used to lift a flap and expose the membrane (Figure 14). The titanium mesh kept the membrane shape stable for the entire healing period. Removal of the membrane revealed that the whole volume enclosed by the membrane had been

regenerated with new bone and a new wide ridge had been created (Figure 15). Excess bone on top of the cover screws was removed (Figure 16). PEEK healing abutments were connected to the implants and the flap was closed (Figure 17). Radiographic assessment confirmed bone regeneration around the implants (Figure 18). After 3 months of soft tissue healing (10 months after membrane placement) the implants were temporary restored (Figure 19).

### Case 3 Vertical ridge augmentation in the esthetic zone

A 40 year old patient presented with a missing central incisor and a resorbed ridge (Figure 20). It was planned to perform a vertical ridge augmentation with NeoGen™ Ti-Reinforced Membrane - Medium Interproximal and simultaneous implant placement of Neoss ProActive Straight implant. □

A full thickness flap with releasing incisions was opened, revealing a

large vertical defect (Figure 21). A Ne-oss ProActive Straight implant was placed an 8 mm vertical defect (Figure 22). Autogenous bone cylinders (3.4 x 4-5 mm) were harvested from the oblique line of the mandible in the molar region and placed around the implant to accelerate regeneration and to act as space fillers (Figure 23). A Neogen™ Ti-Reinforced Membrane Medium Interproximal was trimmed, shaped, and fitted at the surgical site and secured buccally with two tacks (Figure 24). Stress free flap closure was achieved by releasing the periosteum on the buccal side (Figure 25). The soft tissue healing was uneventful (Figure 26-27). □

After 6 months, second stage surgery was performed. A mid-crestal incision with releasing incisions was used (Figure 28). The flap was lifted to expose the membrane (Figure 29). The soft tissue can easily be separated from the membrane after healing. The membrane was removed. Newly formed bone fills the entire space created by the membrane (Figure 30). Excess bone on top of the cover screw was removed to get access to the implant (Figure 31). A PEEK healing abutment was connected to the implants and the flap was closed (Figure 32). Radiograph taken directly after abutment connection shows

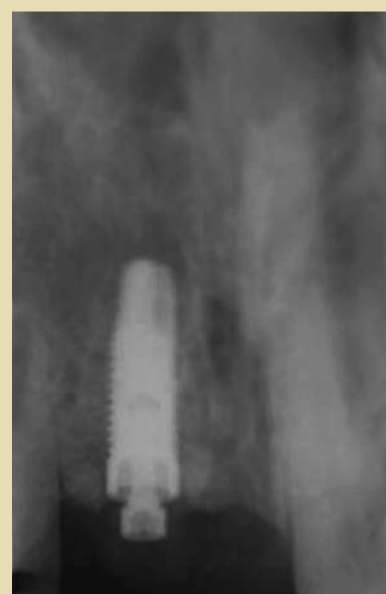

Fig 33

that bone has been successfully regenerated up to the level of the implant platform (Figure 33).

#### Conclusion

The cases show that vertical ridge augmentation and horizontal ridge widening with optimal bone fill can be achieved in a predictable manner when performing GBR using the NeoGen Ti-Reinforced Membrane.

#### Dr Norbert Hassfurth

MD, DDS, Dr. med. (PhD), Oral and Maxillofacial Surgeon, Germany. Norbert Hassfurth qualified and was licensed to practice medicine in 1982 at the Justus-Liebig University

in Giessen, Germany. In 1985 he completed his training and qualified to practice dentistry. He completed his Specialist degree in Oral and Maxillofacial Surgery in 1991 and was appointed as Senior Physician at the Department of Oral and Maxillofacial Surgery at the University of Giessen, Germany. In 1994 he established his own private practice in Wetttenberg, Germany where his main focus is in the area of dental implantology and bone grafting. He has lectured throughout Europe on his bone grafting techniques. - DT

*There are two things in life that a sage must preserve at every sacrifice, the coats of his stomach and the enamel of his teeth. Some evils admit of consolations, but there are no comforters for dyspepsia and the toothache.*

~Henry Lytton Bulwer

# The synthesis of aesthetics, health and structural stability - The advantages of using the Angulated Screw Channel (ASC) abutment system

By Dr Chandur Wadhvani, USA

There are many reasons why cement-retained implant restorations gained popularity over the last few years, which can be attributed to aesthetics, ease of use and familiarity with cementation techniques. However, Pauletto, Gapski and others reported that cement excess was problematic; then Wilson's study established a positive relationship between excess residual cement and peri-implantitis. □

Surveys on cements used for implant restorations indicated a diversity in material selection, application technique and volume. This suggested a lack of conformity and understanding of cement usage within the dental profession. To overcome the cement problem, it became evident that improved understanding was required for cement material selection, abutment design and the determination of cement margin depths. Even with the very best intentions, however, residual excess cement can lead to disease, affecting the health of the implant/tissue interface and remains a dominant risk factor. □

The association of residual excess cement and periimplantitis has resulted in the need to re-examine alternatives such as the screw-retained implant crown. For many implant systems, the ability to use a screw-retained implant restoration is limited to regions where the screw access channel emerges in an aesthetically 'safe' site.

Usually the anterior maxilla and mandible present the greatest challenges, as the long axis of the implant often projects through the proposed incisal edge or even facial to the final restoration (Fig. 2a). Occasionally, when the surgeon places the implant in a compromised site—or the implant is inappropriately placed—the traditional screw-retained implant restoration may seem to provide more of a challenge than a solution (Fig. 2b). □

Angulated Screw Channel saves the day. An innovative solution to the off-axial implant is the Angulated Screw Channel (ASC) abutment system developed by Nobel Biocare (Fig. 3). With the ability to alter the screw channel up to 25 degrees, it eliminates the need for cementation in the vast majority of cases like these. The ASC provides for an active synthesis of health, aesthetics, and excellent structural and mechanical abutment joint stability.

## Health □

With use of the ASC abutment system, cement extrusion into the fragile peri-implant soft tissues is eliminated. The ASC puts an end to the onslaught of cement fluid pressure and unset chemicals from the cement material. It also gets rid of the potential for foreign bodies being pushed around the implant site, which can jeopardise implant health (Fig. 4). In addition, the use of zirconia abutment superstructures in combination with titanium bases provides optimised materials for biocompatibility and health.

## Aesthetics □

With the ASC, the screw access channel can be projected away from high-aesthetic-risk areas and placed appropriately at a variety of different angulations. CAD/CAM design enables the restorations to be efficiently designed and quickly manufactured at Nobel Biocare's production facilities (Fig. 5). Milled zirconia is highly aesthetic,



Fig. 1: Failed, removed implant, cement extrusion is noted on multiple threads.

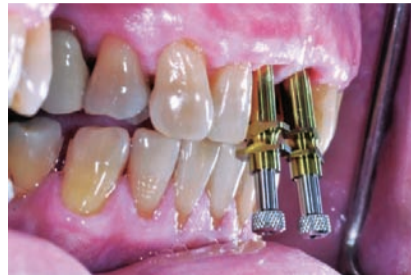

Fig. 2a: The anterior teeth present a challenge to the screw-retained restoration unless an Angulated Screw Channel (ASC) abutment is used.

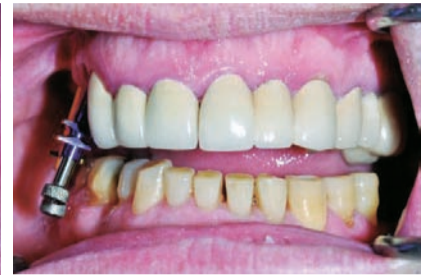

Fig. 2b: In cases where the surgical placement is less than ideal, the ASC may help limit further compromise to the site.

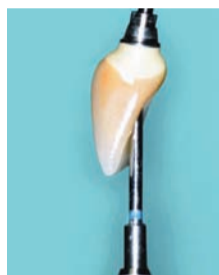

Fig. 3: The ASC shows the angle redirection of the screw access channel.

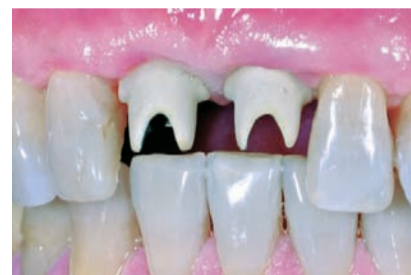

Fig. 4a: Even with shallow margins and minimal cement (a), the elimination of cement extrusion still presents a clinical challenge (b).

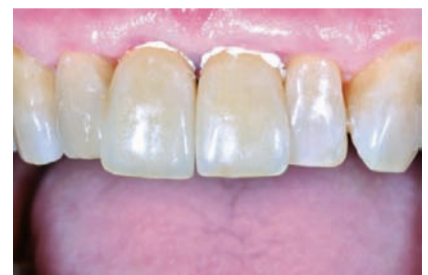

Fig. 4b: Even with shallow margins and minimal cement (a), the elimination of cement extrusion still presents a clinical challenge (b).

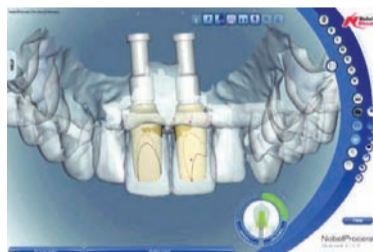

Fig. 5: The Nobel Biocare CAD/CAM software allows ideal screw access site to be planned, then machine fabricated.

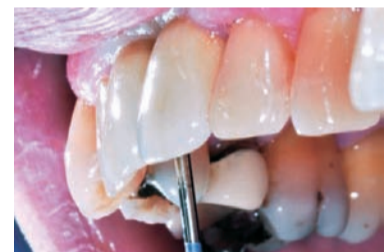

Fig. 6a: The screw access from Figure 2a has been redirected using the ASC abutment and crown (a & b), producing a pleasing natural appearance thanks to a screw-retained implant restoration (c).

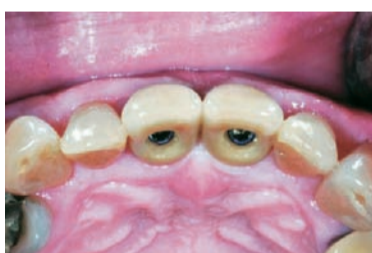

Fig. 6b: The screw access from Figure 2a has been redirected using the ASC abutment and crown (a & b), producing a pleasing natural appearance thanks to a screw-retained implant restoration (c).

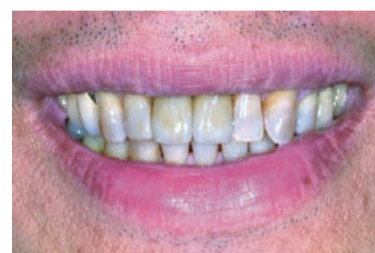

Fig. 6c: The screw access from Figure 2a has been redirected using the ASC abutment and crown (a & b), producing a pleasing natural appearance thanks to a screw-retained implant restoration (c).

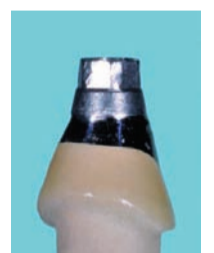

Fig. 7: An actual case: Note cast abutment has been damaged through routine laboratory procedures.

thus especially useful at the soft tissue emergence site.

## Mechanical stability □

CAD/CAM utilisation (Fig. 6a–c) allows for optimized screw access site planning, and the machining of components provides a precise, dedicated connection, optimised for the implant-abutment joint. □

As with all implant-to-abutment connections, the optimised passive fit results when these surfaces are in intimate contact and forces are distributed universally. Casting abutments cannot always provide an even connection with joint contact, as they are often inadvertently damaged through cleaning and polishing, which alters the consequent fit (Fig. 7). When this occurs, the joint connection may fail, with screw loosening or even failure of the implants as a result.

## Structural components □

Titanium alloy abutment bases provide the most accurate fit with machining tolerances readily

controlled. Abrasive wear, i.e. the release of titanium metal into the peri-implant tissues from the inside of the implant, is not an issue. The zirconia abutment, with its well-designed circumferential wall strength, is held through the abutment screw, optimising the ceramic's ability to withstand forces that have been seen to fracture non-titanium base abutments.

## Conclusion □

The benefits of the ASC abutment system are numerous, reflecting a multiple symbiosis of engineering ingenuity and biocompatible materials, and allowing for the combination of good aesthetics and excellent health. □

Attending IDS? Learn more about NobelProcera ASC solutions at the Nobel Biocare booth in Hall 10.1.

*Acknowledgement: The author wishes to acknowledge and personally thank the following dental laboratories for their assistance with this material: Avots Dental laboratory, Nakanishi dental laboratory and Myron Choi. - DT*





GRAND CEVAHIR CONVENTION CENTER 27-29 OCT. 2017  
ISTANBUL

# a beautiful day for dentistry



*Istanbul welcomes dental professionals*  
**GREATIST**



CONGRESS  
EXHIBITION  
SYMPOSIUMS  
COURSES  
WORKSHOPS

INFO & REGISTRATION  
[www.greatist.pro](http://www.greatist.pro)



**DiSSiAD**  
TURKISH DENTAL BUSINESSMEN ASSOCIATION

**dti** Dental  
Tribune  
International