

# IMPLANT TRIBUNE

The World's Dental Implant Newspaper · U.S. Edition

JULY 2009

www.implant-tribune.com

VOL. 4, No. 7



**AAP headed for Boston**  
Clinicians, companies  
convene on Pacific coast

►Page 9B



**Materialise in Monterey**  
Clinicians, companies  
convene on Pacific coast

►Page 11B



**Want success?**  
Here are the 7 questions  
you need to ask yourself

►Page 14B

## ICOI headed to Vancouver

The International Congress of Oral Implantologists will host its World Congress XXVI from Aug. 20-22 at the Vancouver Convention Centre in Vancouver, Canada.

Here is just a small sampling of speakers and topics to be featured at this event:

- Dr. Lyndon Cooper: "Dental Implant Function and Occlusion – Risk and Benefit"
- Dr. Scott D. Ganz: "The Impact of Digital Dentistry on Prosthetic Paradigms"
- Dr. Jack Krauser: "Guided Implant Surgery – The Good, The Bad and The Ugly"
- Dr. Edwin A. McGlumphy: "How Fast Can We Go? Ohio State Implant Clinical Trials: What We Have Learned About Early and Immediate Loading"

For more information about the event, see [www.icoi.org](http://www.icoi.org), where you can register online and learn more information about schedule and hotels. **IT**

(Source: ICOI)

→ **IT** page 4B

## Stem cells may improve the adaptability of dental implants

A procedure using stem cells may provide a more thorough regeneration of periodontal tissue around dental implants, according to a new report published in the Journal of Oral Implantology.

Dental implants closely resemble natural teeth, but an implant's ability to react to patient growth, pressure from chewing and future orthodontic work is diminished if it is not surrounded by sufficient periodontal tissue. In this study, the authors engineered this periodontal tissue in

a fresh socket of a goat animal model.

Each of five goats was fitted with two titanium implants immediately after tooth removal. A poly DL-Lactide-co-Glycolide scaffold was fitted around each implant, but the control received only the scaffolding. The experimental implant received scaffolding seeded with bone marrow-derived mesenchymal stem cells (BMDSCs). All implant sites showed some level of tissue development at 10 days after the opera-

tion. At one month after, the control side showed no signs of tissue development, whereas the experimental side had developed cementum, bone and periodontal ligament, the three tissues required for regeneration of periodontal tissue.

Past studies have demonstrated positive results with BMDSCs in periodontal defects around natural teeth. Others have shown promising results without BMDSCs, using pro-

→ **IT** page 2B

## Miniscrews: a focal point in practice

Part two in a six-part series

By Dr. Björn Ludwig, Dr. Bettina Glasl, Dr. Thomas Lietz and Prof. Jörg A. Lisson

### Basic information on the insertion of miniscrews

#### Preparing for insertion

The insertion of a miniscrew is a very simple and rapid therapeutic measure. Although there are several methods that will yield good results, successful insertion requires adherence to a few import-

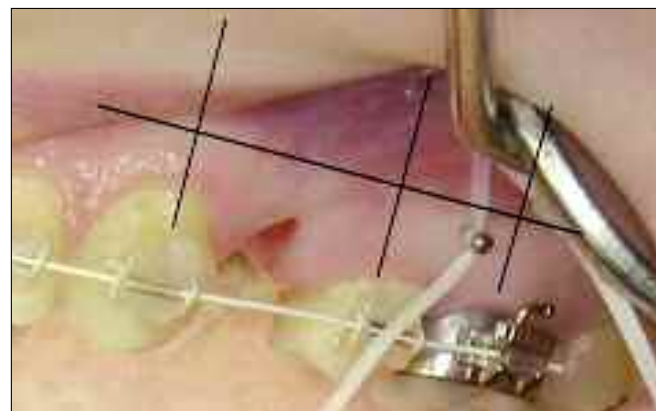

Fig. 1: X-ray positioning aid (X-ray pin, FORESTADENT) shown in situ in relation to the adjoining tooth axes.

AD

## INDUSTRY TRENDS

### Avoiding the pitfalls of implants with 3-D imaging

By Terry Myers, DDS

Once only a solution for the rich and famous, dental implants have become a popular option for people across all economic categories. Along with the popularization of this procedure, while implants were usually delegated to specialists, technology, such as in-office cone-beam

scans and digital imaging allow general practitioners to offer this type of service while also avoiding the pitfalls that result from a lack of precise information.

Research illustrates both the growing popularity of implants and the increasing desire of general den-

→ **IT** page 2B

**Dental Collab**  
FIRST MONTH FREE  
CODE: ITDC09

CREATE,  
SHARE,  
COLLABORATE.

Connect your treatment workspaces with dental professionals invited to join your private network from around the globe.

[www.DentalCollab.com](http://www.DentalCollab.com)

← II page 1B

tists to provide their patients with this procedure. A recent survey cites that 19 percent of general dentists have placed implants for three years or less. Many practitioners want to add this procedure as a response to requests from their patients. The study also showed that 77 percent of general practitioners said the number of patient inquiries about implants in their practice has increased during the last three years.

For the general dentist, the proper technology can reduce stress and expand the comfort zone, as well as increase the safety and comfort of the patient during implant planning and surgery.

A successful implant surgery is dependent upon many details, a majority of which are hidden beneath the gingiva. A 2-D X-ray or pan cannot discern certain anatomical conditions of the dentition that may determine the direction and scope of the treatment plan. Without a 3-D scan, the dentist needs to devise several "just-in-case" options, to provide for the various possible scenarios taking place under the gum tissue. While this may seem to you like "covering all bases," it may decrease the patient's confidence in your diagnostic ability.

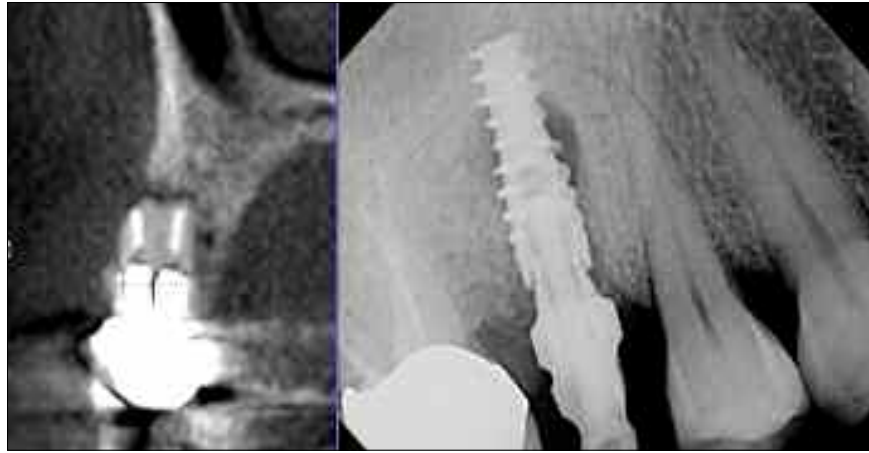
A comfortable and positive experience will determine whether you retain a loyal patient or get bad press among his/her friends.

Beginning an implant without a 3-D scan is like trying to navigate through a dark room without a flashlight. You are sure to bump into something that will stop your progress. A 2-D pan alone cannot clearly establish the dimensional shape of the bone. Without the exact measurements of the width and height of the bone provided by the cone-beam image, it is likely that you may flap back the tissue only to find insufficient bone to support an implant. The patient ends up with pain, stitches, and an additional appointment to complete the next stage.

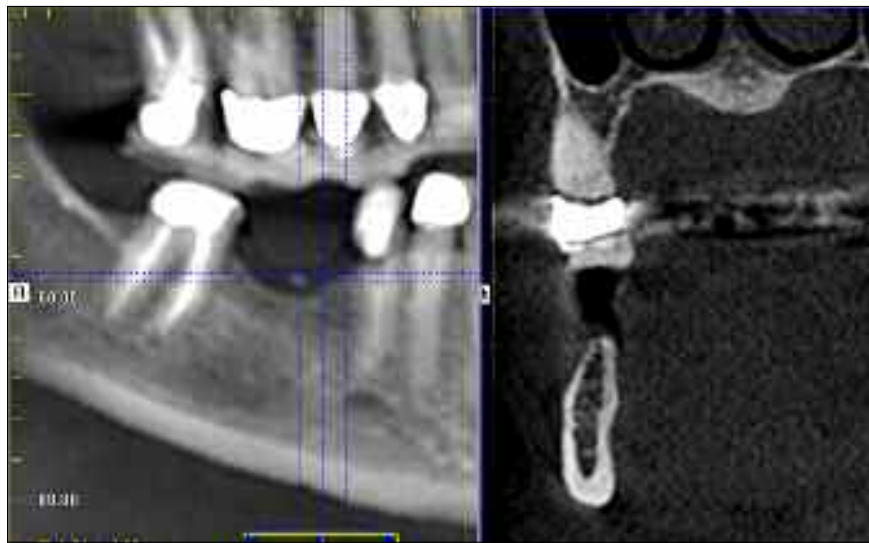Besides the amount of bone, the 3-D scan avoids other possible obstacles to a successful implant. The ability to view abnormalities of the roots, the tooth's proximity to adjacent teeth, supernumerary teeth and the proximity to the nerves and sinus provides valuable insight, avoiding surprises once the surgery is underway.

The cone-beam scan improves patient communication, avoiding misunderstandings and improving patient acceptance. Back to the survey scene, more than 98 percent of those surveyed were involved in patient education on implants. Education is easy with a 3-D image. The dentist can point out the possible trouble spots on the 3-D model, slicing, rotating, enlarging and exploring the patient's dental anatomy from all angles.

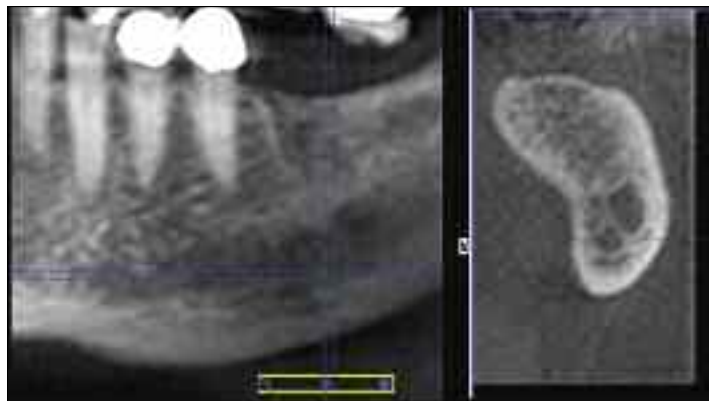
Whether you are a general dentist or a specialist, no one wants the stress of a possible failed implant, or



Severe buccal destruction easily detected on a 3-D cross-section from Cone Beam (GXCB-500), and successful implant placement verified by a digital X-ray (DEXIS).



3-D reveals narrow ridges and provides precise measurements for safer placement.



The undercut mandible as seen in 3-D prior to surgery.

a disappointed patient.

In conjunction with 3-D imaging, many surgical guides are available that provide even more direction during the surgery, and 2-D digital images taken during the surgery can offer a quick check of drill lengths and placements.

While success in any surgical endeavor cannot be totally guaran-

teed, having all of the facts beforehand does stack the odds in your favor. With cone-beam technology, general dentists can keep their existing patients in-house, attract new patients and expand their dental horizons. There's no need to do surgery in the dark because 3-D imaging is available to shed light on all the pertinent facts. II

## II About the author

Dr. Terry Myers completed his residency in advanced general dentistry and served as an instructor in the advanced education in general dentistry residency program and as director of the faculty practice at the University of Missouri-Kansas City School of Dentistry. He is a fellow in the Academy of General Dentistry and a member of the Acade-



my of Cosmetic Dentistry and the Dental Sleep Disorder Society. Myers is on the board of directors at Research Belton Foundation and is a participating provider for the dental care program to improve children's dental care. His private practice, where he utilizes the Gendex GXCB-500 and DEXIS, is in Belton, Mo. Myers can be reached by e-mail at [office@keystone-dentistry.com](mailto:office@keystone-dentistry.com).

## IMPLANT TRIBUNE

The World's Newspaper of Implantology · U.S. Edition

### Publisher

Torsten Oemus  
[t.oemus@dtamerica.com](mailto:t.oemus@dtamerica.com)

### President & CEO

Peter Witteczek  
[p.witteczek@dtamerica.com](mailto:p.witteczek@dtamerica.com)

### Chief Operating Officer

Eric Seid  
[e.seid@dtamerica.com](mailto:e.seid@dtamerica.com)

### Group Editor & Designer

Robin Goodman  
[r.goodman@dtamerica.com](mailto:r.goodman@dtamerica.com)

### Editor in Chief

Sascha A. Jovanovic, DDS, MS  
[sascha@jovanoviconline.com](mailto:sascha@jovanoviconline.com)

### Managing Editor/Designer

Sierra Rendon  
[s.rendon@dtamerica.com](mailto:s.rendon@dtamerica.com)

### Managing Editor/Designer

Ortho Tribune & Show Dailies  
Kristine Colker  
[k.colker@dtamerica.com](mailto:k.colker@dtamerica.com)

### Online Editor

Fred Michmershuizen  
[f.michmershuizen@dtamerica.com](mailto:f.michmershuizen@dtamerica.com)

### Account Manager

Humberto Estrada  
[h.estrada@dtamerica.com](mailto:h.estrada@dtamerica.com)

### Marketing Manager

Anna Wlodarczyk  
[a.wlodarczyk@dtamerica.com](mailto:a.wlodarczyk@dtamerica.com)

### Marketing & Sales Assistant

Lorrie Young  
[l.young@dtamerica.com](mailto:l.young@dtamerica.com)

### C.E. Manager

Julia Wehkamp  
[j.wehkamp@dtamerica.com](mailto:j.wehkamp@dtamerica.com)

Dental Tribune America, LLC  
213 West 35th Street, Suite 801  
New York, NY 10001  
Phone: (212) 244-7181, Fax: (212) 244-7185



Published by Dental Tribune America

© 2009, Dental Tribune International GmbH. All rights reserved.

Dental Tribune makes every effort to report clinical information and manufacturer's product news accurately, but cannot assume responsibility for the validity of product claims, or for typographical errors. The publishers also do not assume responsibility for product names or claims, or statements made by advertisers. Opinions expressed by authors are their own and may not reflect those of Dental Tribune International.

← II page 1B

genitor cells from the remaining ligament in certain limited situations. But unlike past studies, this report demonstrates that using BMDSCs can ensure a more thorough, adaptable regeneration of periodontal tissue with titanium implants.

To read the entire article, titled "Experimental Formation of Periodontal Structure Around Titanium Implants Utilizing Bone Marrow Mesenchymal Stem Cells: A Pilot Study," visit: [www.allenpress.com/pdf/ORIM-35-3-106.pdf](http://www.allenpress.com/pdf/ORIM-35-3-106.pdf). II

OSTEOGENESIS

OSTEOINDUCTION

OSTEOCONDUCTION

**Osteocele®**

# The Future Is Now.

## A Bone Matrix Product Containing Stem Cells.

### The Properties of Autograft without Associated Risks

The proprietary processing technology that produces Osteocele® results in a viable bone matrix product that preserves the native stem cells found in marrow rich bone. It is the only product available today that has the desired beneficial properties of autograft - osteoconduction, osteoinduction and osteogenesis - and that allows surgeons to provide their patients with optimal bone growth conditions without the added risk and cost of a secondary procedure.

### Low Immunogenicity

Mesenchymal stem cells are IMMUNE-PRIVILEGED cells that do not stimulate a cellular immune response. Osteocele does not activate T cell proliferation, as shown *in vitro* from Mixed Lymphocyte Reaction (MLR) testing.

### Histologic Evidence

Positive clinical use of Osteocele since 2005 demonstrates bone-forming ability. Histology from a human sinus augmentation study using Osteocele shows substantial vital bone content at 16 weeks, with very low residual graft material.<sup>1</sup>

### Bone Formation

Stem cells contained in Osteocele are capable of differentiating into bone cells. Every lot of Osteocele is tested for bone forming potential.

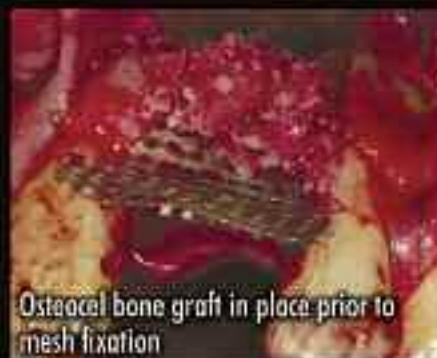### Viable Cell Content

The osteogenic potential arises from the stem cells in Osteocele. Following processing of marrow-rich bone, release testing demonstrates osteogenic potential according to the following criteria:

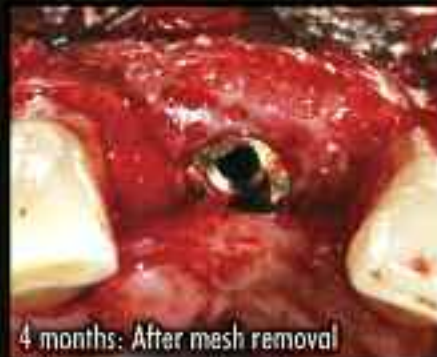- Rich supply of stem cells: Greater than 50,000 cells/cc
- Viability: Greater than 70% cell viability
- Positive osteogenesis: *In vitro* cell culture assay



Before: exposed implant



Osteocele bone graft in place prior to mesh fixation



4 months: After mesh removal

Ridge Augmentation clinical case.

<sup>1</sup> Histologic Evaluation of a Stem Cell Based Sinus Augmentation Procedure: A Case Series. — McAllister, Haghghat, Gonshor. — Journal of Perio., April 2009

 For more information  
or to place an order call **800.441.3100**
**www.acesurgical.com**

ACE Surgical Supply Company, Inc. • 1034 Pease Street, Woburn, MA 02151

## ADVANCED TISSUE GRAFTING 2-DAY HANDS-ON CADAVER WORKSHOP

BOSTON • October 2009

LAS VEGAS • December 2009

 For more details or to register go to  
[www.acesurgical.com/cadaver.html](http://www.acesurgical.com/cadaver.html)

Limited Availability

Last 2 Courses Sold Out! Reserve Your Space by Registering Today.

← II page 1B

ant principles. The following text details those insertion steps that offer a high degree of safety for both patient and dentist (see *checklist for insertion on page 8*). It should be noted that this information is generalised and must be adapted to individual circumstances.

*General notes on insertion*

Accurate pre-operative planning is a basic requirement for successful treatment with miniscrews. Such planning includes a comprehensive anamnesis and an accurate assessment of the findings. It is essential that the treatment be thoroughly explained to the patient.

Proper hygiene must be ensured throughout the entire operation.

Both the dental chair and the treatment process must be prepared with this in mind. During the insertion of a miniscrew, adherence to all hygiene measures required for an invasive procedure, such as a sterile work environment and gloves, must be ensured.

All instruments required for insertion must be checked for completeness, functionality and sterility. The patient may rinse with a disinfectant solution, or a suitable disinfectant can be locally applied. The patient should then be positioned to ensure a clear view of the operational area and ergonomically facilitate insertion for the treating dentist.

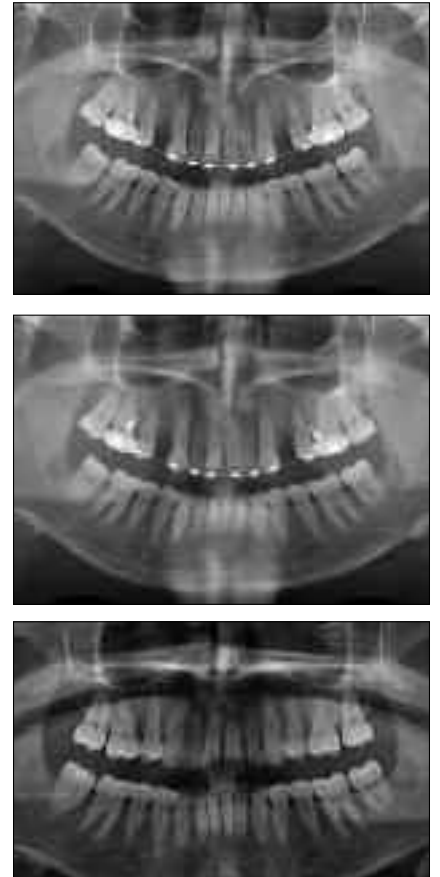
*Pre-operative planning*

To function correctly, a miniscrew requires firm anchorage in the bone (primary stability) and the

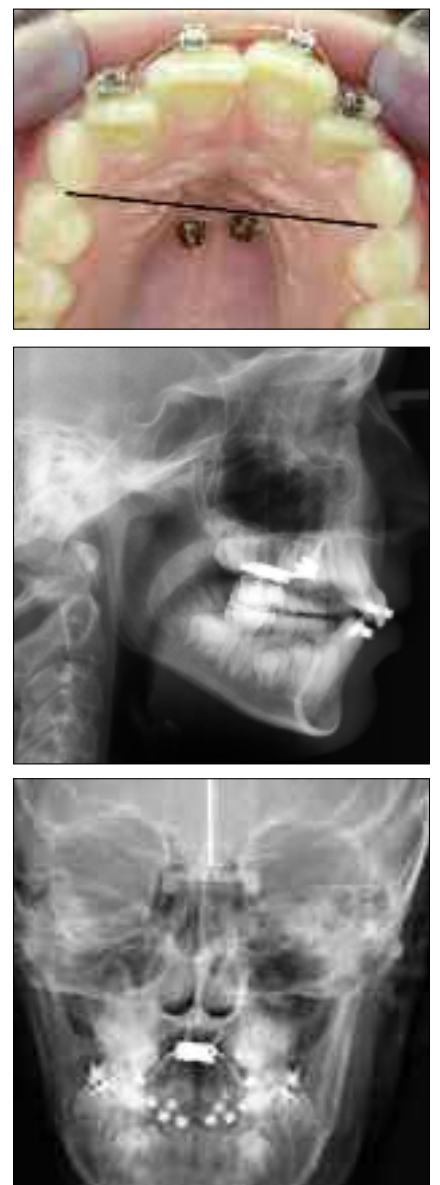
positioning of its head in the denser gingival tissue (gingiva alveolaris). The selection of the insertion site must take clinical and para-clinical findings into account (X-ray image, model), as well as the goal of the treatment and the resulting orthodontic appliance. For interradicular insertion, a bone thickness of at least 0.5 mm around the miniscrew is required. This means that for a miniscrew with — for many reasons — an optimal diameter of 1.6 mm, the roots must be at least 2.6 mm from each other. Thus, the bone status and the longitudinal axis of the insertion site must be carefully evaluated.

Basic information regarding this is obtained by carrying out measure-

→ II page 6B



*Figs. 2a–c: The top image shows the initial situation. An X-ray pin was inserted into the first and second quadrants of the upper jaw (in the 6–5 region) to check the bone site, followed by the miniscrew. Both screws were inserted in a manner that is clinically safe, but the X-ray images show damage to the adjoining root in the right-hand quadrant, indicating a false-positive initial interpretation of the situation.*



*Figs. 3a–c: The clinical image shows two miniscrews inserted into the palate in the safe zone to the distal side of the transversal line linking the two canines. The FRS and the PA image confirm the bone support in the insertion region.*

AD

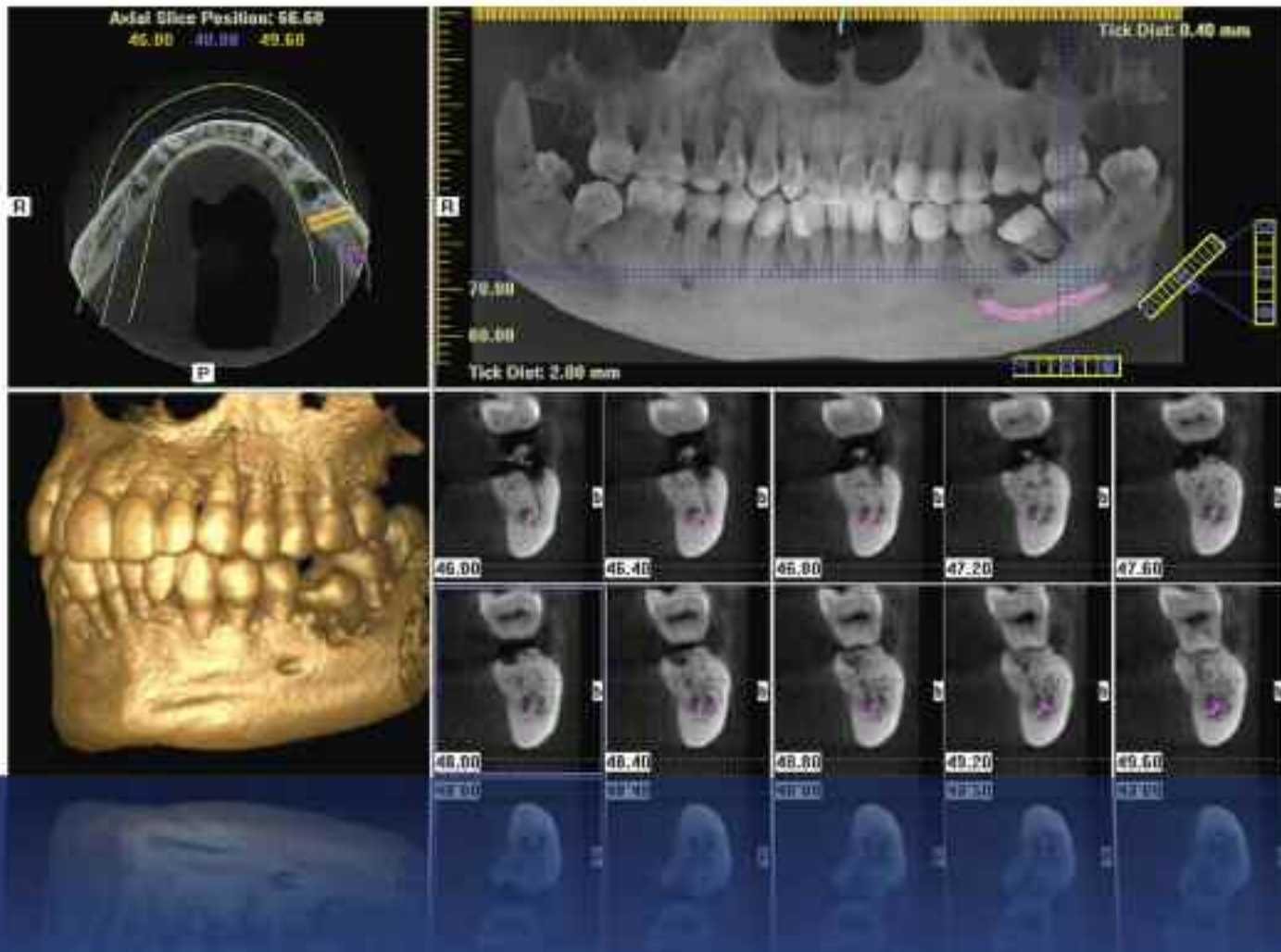
AAID AMERICAN ACADEMY OF IMPLANT DENTISTRY  
58TH ANNUAL MEETING  
**NEW OPPORTUNITIES  
IN IMPLANT DENTISTRY**  
NEW ORLEANS  
NOVEMBER 11–15, 2009

**THIS CASE-BASED CONFERENCE  
IS ONE OF THE BEST VALUES IN  
IMPLANT DENTISTRY.**

- Obtain up to 24 hours of comprehensive unbiased CE
- Interact one-on-one with the world-class presenters
- Take home clinically practical information you can use immediately
- Discover the latest products and services in implant dentistry

WWW.AAID2009.COM

# Discover A New Dimension Of Predictability, Precision, And Affordability



**GX CB-500**  
POWERED BY i-CAT

New dimensions of diagnostic capability with remarkable affordability...only from Gendex.

Experience more advanced anatomical views by capturing 3-D images right in your office. Achieve accurate, immediate assessments with the GXCB-500®, powered by i-CAT®. This breakthrough, Cone Beam 3-D imaging technology is now incorporated into a system featuring ground-breaking affordability.

Provide reassurance through considerable radiation reductions, in comparison to traditional CT scans. Build patient confidence in treatment plans with a clear diagnosis. Best of all, this evolution in imaging is easily implemented! The GXCB-500 is a technological plus for both patients and practices.

- ☐ Cone Beam 3-D Imaging Systems
- ☐ Panoramic X-ray Systems
- ☐ Intraoral X-ray Systems
- ☐ Digital Intraoral Sensors
- ☐ Digital X-ray Phosphor Plates
- ☐ Intraoral Cameras
- ☐ Imaging Software

Gendex Dental Systems  
www.gendex.com  
Call toll-free: 1-888-275-5286

**GENDEX**  
Imaging Excellence Since 1893



Figs. 4a and 4b: Injection pen with needle and anaesthetic cartridge, and injection of anaesthetic.



Figs. 5a and 5b: Superficial anaesthetic device in pen form with cartridge, and application of superficial anaesthetic.

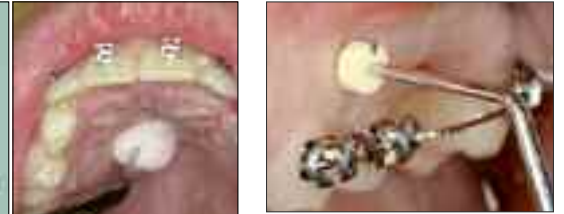

Fig. 6: Measuring the thickness of the mucous membrane in the direction of insertion. (Photo: Dr. Pohl)

### ← II page 4B

ments on the model. It often helps to mark the vertical axis of the teeth and the progression of the mucogingival line on the model, based on the clinical and radiological findings. This will allow for an improved assessment of the spatial

circumstances in combination with the X-ray image. To assist the accurate determination of the insertion site, X-ray aids (Fig. 1) are available.

Although their use facilitates the selection of the insertion site, they cannot replace other diagnostic measures. This is because, depending on the positioning of the X-ray tube, object, film, and/or sensor, all

types of X-ray devices and images may yield some optical distortion. Interpretation of images can thus lead to false-negative or false-positive results (Figs. 2a–c).

Therefore, the placement of a miniscrew should always be based on the clinical findings. If a miniscrew is to be inserted into an area in which there is no risk of damage to roots, nerves or blood vessels

(e.g., into the palate just behind the transverse line linking the two canines), the position of the screw may be freely chosen (Figs. 3a–c).

### Anaesthetic

During the interradicular insertion of a miniscrew, the sensitivity of the periodontal tissue of the adjoining teeth should be retained. For this reason, the following two procedures are recommended:

- a low-dose injection of approximately 0.5 ml anaesthetic (Figs. 4a and 4b); and
- the induction of superficial anaesthesia of the mucous membrane at the insertion site, for which a topical anaesthetic gel is suitable (Figs. 5a and 5b). No general anaesthetic is ever required for this procedure.

### Choice of screw

#### Measuring the thickness of the mucous membrane (optional)

A pointed rubber sensor with an attached rubber ring is used to measure the thickness of the gingival tissue in the direction of insertion (Fig. 6).

This information may be useful when determining the final length of the screw and possibly when inserting the miniscrew.

When choosing the length, the bone repository and the thickness of the mucous membrane in the direction of insertion play a role; in the retromolar section of the lower jaw and in the palate, the thickness of the mucous membrane is often more than 2 mm.

The part of the miniscrew inside the bone must be at least as long as the part outside the bone. The various dimensions must be taken into account.

The thickness of the bone in the direction of insertion determines the required length of the miniscrew:

- bone thickness > 10 mm: miniscrews with a length of up to 10 mm are to be used;
- bone thickness < 10 mm and > 7 mm: miniscrews with a length of 8 mm or 6 mm are to be used; and
- bone thickness < 6 mm: miniscrews cannot be used.

The following guidelines aid in selecting the length:

- in the buccal region of the upper jaw: 8 mm or 10 mm;
- in the palatal region (depending on the region): 6, 8 or 10 mm; and
- in the lower jaw: usually 6 mm or 8 mm.

AD

# VANCOUVER, CANADA

August 20-22, 2009 ♦ Vancouver Convention Centre

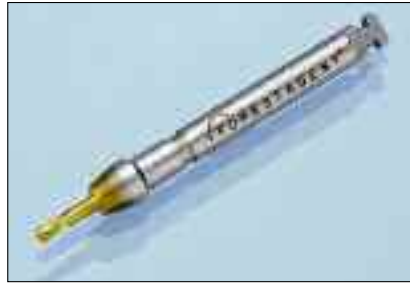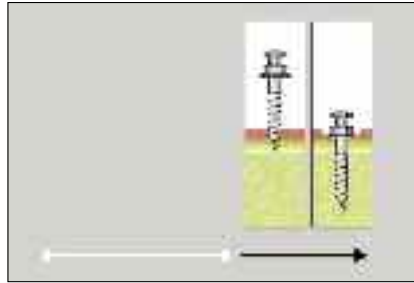
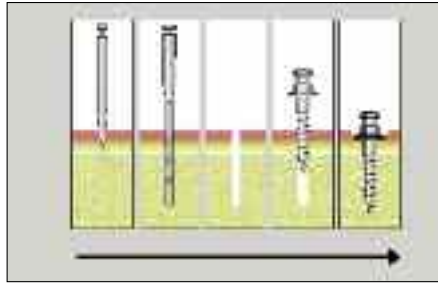
## ICOI World Congress XXVI

### 12<sup>th</sup> Annual IPS Symposium and

### 12<sup>th</sup> Congress of the Asia Pacific Section

For more information please contact the ICOI Central Office  
at (973) 783-6300 or visit our website at [www.icoi.org](http://www.icoi.org)

Sponsored by:



Figs. 7a and 7b: Diagrams showing the thread mechanisms: self-cutting and self-tapping.

Figs. 8a and 8b: Pre-drill with a 4 mm long blade and limit stop: Drill (FORESTADENT) and tomas-drill SD (DENTAURUM).

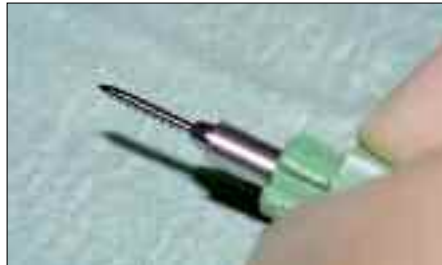

Fig. 9: Sterile miniscrew supplied in pin-holder (tomas-pin, DENTAURUM).



Figs. 10a-d: Preparation of the work rack and removal of the blades.

**Determination of the type of thread**

Self-cutting miniscrews require pre-drilling (also known as pilot drilling) appropriate to the length and diameter of the screw, as well as to the quality of the bone.

A self-tapping miniscrew will find its own way into the bone and requires no pre-drilling (Figs. 7a and 7b).

Bone is more or less elastic

depending on site, age and structure. However, the screw diameter, the thickness of the cortical bone, and the hardness of the bone at the insertion site limit the extent to which this method can be used.

Without pre-drilling, the bone will be strongly compressed during insertion and thus suffer related tension stress.

This may result in the cracking of

the bone around the insertion site.

When the screw is screwed into the bone, it is subjected to high loads. Depending on the bone quality, the resistance against insertion and the continuity of the rotational movement, high torsional forces can result.

In regions with thick cortical bone and a much looser bone structure (e.g. the upper jaw), the use of

self-tapping screws is recommended.

In regions where the cortical bone is thick and the bone structure is dense (e.g., the anterior lower jaw), both self-cutting and self-tapping screws may be used, in each case following perforation of the compact bone.

→ **II** page 8B

AD

## Benex® - Control Professional

Root Extraction Systems associated with DENTEX



Art. No. BE001230001

- Safe and simple extraction of roots
- Maximal protection of the tooth socket
- Possibility of drilling even if minute root fragments or foreign bodies are present in the root
- Possibility of drilling independently of anatomic root canal



MEISINGER

GERMANY / US



**Meisinger USA, L.L.C.**  
 7442 South Tucson Way • Suite 130 • Centennial • Colorado 80112 • USA  
 Tel.: +1 (303) 268-5400 • Fax: +1 (303) 268-5407 • E-Mail: info@meisingerusa.com  
 www.meisingerusa.com • www.bone-management.com • www.occlusalrouter.com

← II page 7B

### Transgingival penetration

The miniscrew must penetrate through gingival tissue, which must thus be perforated during insertion. Two methods are used for the perforation of the gingival tissue:

- excision of the gingival tissue; or
- direct insertion of the screw through the gingival tissue.

There are currently no published studies that investigate the effect of these two methods on postoperative problems, histological effects and/or the loss rate of miniscrews.

### Preparation of the bone site

Protection of the bone is an important aspect. Insertion without pre-drilling results in tensional stress within the bone, which may lead to postoperative complications. Particularly in the case of crestally placed screws, bone displacement may result in a severe expansion of the periosteum. The thickness of the cortical bone, especially in the lower jaw, can have a significant effect on the torque of the screw. To ensure that the screw is not overloaded during insertion, the compact bone of the anterior lower jaw should be perforated by pre-drilling, as mentioned earlier. Pre-drilling should be done at a maximum of 1,500 rpm<sup>-1</sup>, using a short pilot drill and water-cooling to reduce the risk of damaging the root (Figs. 8a and 8b).

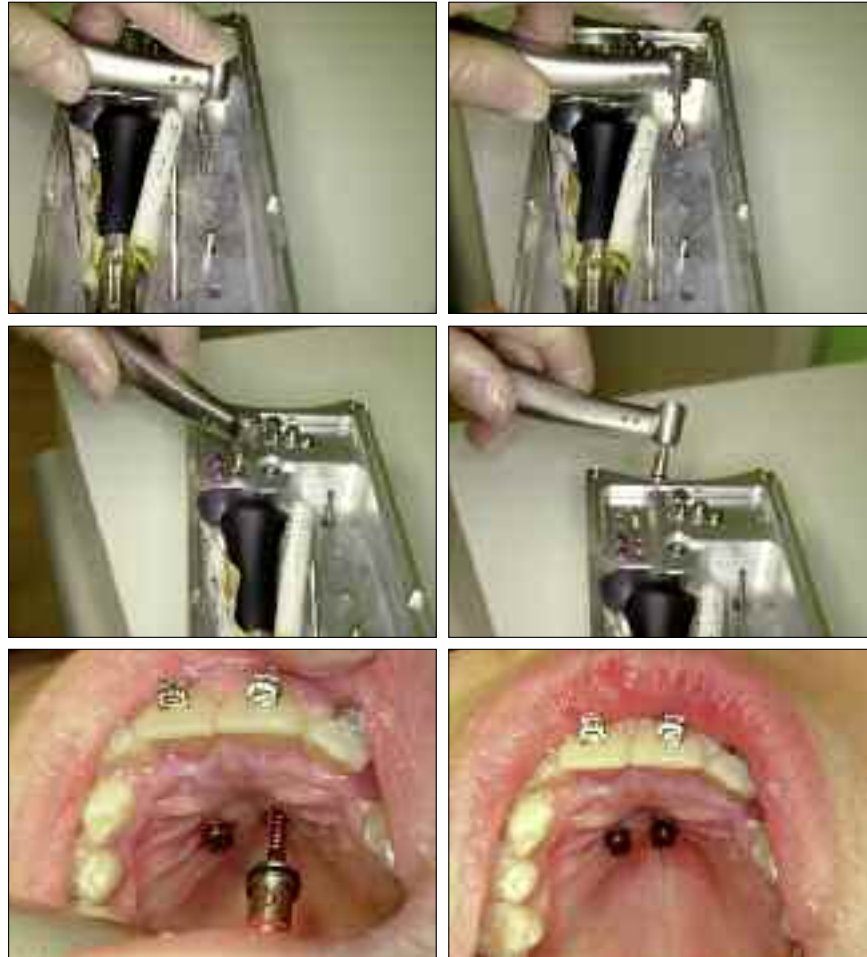### Insertion of the miniscrew

The miniscrew must be removed from its sterile packaging (Fig. 9) or the work rack (Figs. 10a–d) without contamination. The thread of the screw may not be touched. The screw should be inserted at a constant rotational speed (at approximately 30 rpm<sup>-1</sup>) and with as uniform a torque as possible.

#### Manual insertion

Manufacturers supply various screwdrivers and blades in several lengths for the manual insertion of the screws. Because of their dimensions, long blades pose the risk of attaining a very high torque during insertion.

Thus, insertion must be carried out carefully to avoid breaking the miniscrew. Torque ratchets are available for use with some systems (e.g.,



Figs. 2.11a–f: Preparation of the instruments and insertion of two miniscrews into the palate by machine.

tomas, DENTAURUM; and LOMAS, Mondeal), which provide a certain amount of control over the insertion torque.

#### Machine insertion

Machine insertion requires a surgical treatment unit (the torque of which can be controlled) or at least a low-rpm dual green handpiece. Accurate setting of the torque and the number of rotations is required; the rotation rate should not exceed 30 rpm<sup>-1</sup>, and the torque must be restricted to the maximum load limit of the screw.

Machine insertion helps to achieve a consistent torque during insertion but means that the operator loses perception of the bone. During manual insertion, it is possible to perceive the interaction between the screw and the bone by tactile senses. Insertion by machine is shown in Figures 11a–f.

#### Attaching the orthodontic linking elements

As no healing phase is required, load may be placed on the miniscrew

immediately after insertion. The selected linking element must be prepared accordingly and attached to the head of the screw (Fig. 12).

To avoid damage to the teeth to be moved, the load on the linking element should be between 0.5 and 2 N (about 50 and 200 g).

#### Basic postoperative care

The healing of the gingival tissue and hygiene status after insertion must be regularly reviewed during the entire time that the miniscrew remains in place. The patient must be informed that any manipulation of the screw head with the fingers, tongue, lips, and/or cheeks should be avoided, otherwise the screw may be prematurely lost.

### Removal of the miniscrew

A miniscrew can be removed under local anaesthetic. After the linking elements have been removed, the miniscrew may be removed with the same tools used for insertion. The resulting wound requires no special care and usually heals within a short time. II

### Checklist for insertion

#### Pre-operative planning and preparation:

- planning documentation (X-ray, situational models);
- marking of the muco-gingival line and tooth axes on the model;
- determining the site of insertion;
- sterilisation of the instruments and preparation of the workstation.

#### Anaesthetic and assessment of the insertion site:

- anaesthetic;
- use of X-ray aids;
- control image.

#### Selection of the screw:

- measuring of the thickness of the mucous membrane (optional);
- determination of the length;
- determination of the type of screw.

#### Transgingival penetration:

- excision of the mucous membrane or perforation with the screw.

#### Preparation of the bone site:

- optional marking of the bone; and
- perforation of the cortical bone or deep pilot drilling, depending on the type of screw.

#### Insertion of the miniscrew:

- manually or by machine.

#### Start of orthodontic measures:

- attaching and fixing of the linking elements.

#### Postoperative care:

- notes on care and behaviour;
- check-up dates.

#### Removal of the miniscrew:

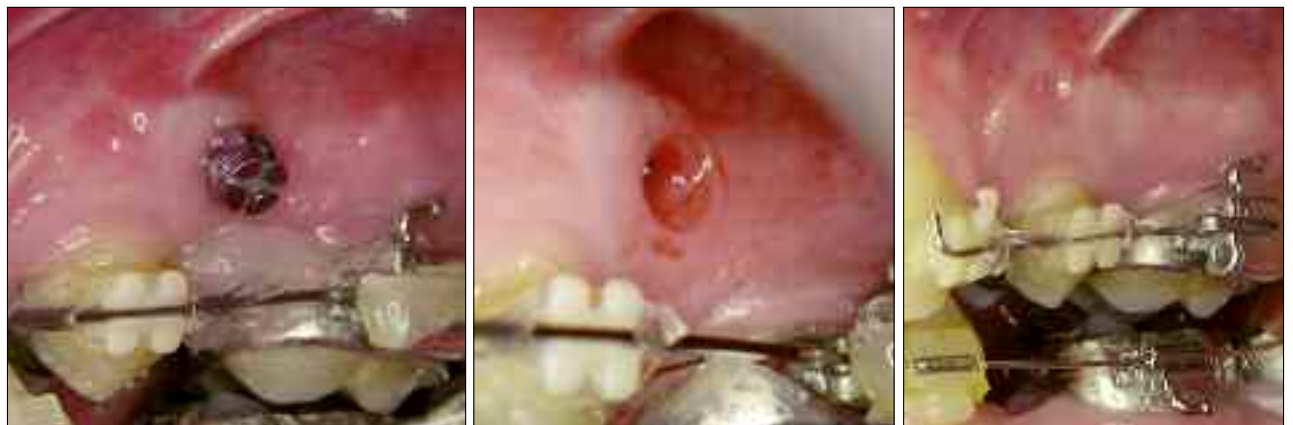
- removal of the linking elements;
- removal of the miniscrew.

### Contact information

Dr. Björn Ludwig  
Am Bahnhof 54  
56841 Traben-Trarbach  
Germany  
Tel.: +49 65 41 81 83 81  
Fax: +49 65 41 81 83 94  
E-mail: bludwig@  
kieferorthopaedie-mosel.de

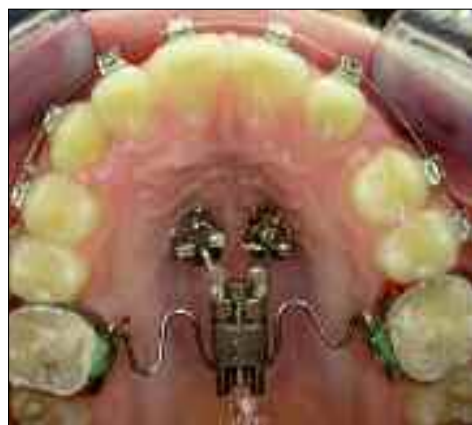

Fig. 12: Linking of the miniscrew to the orthodontic appliance.



Figs. 13a–c: Miniscrew in place, after removal, and following a four-week healing period.



**UPCOMING WEBINARS**

**DT STUDY CLUB**

**ADAC-E-R-P**

World Class Obturation for General Dentists  
 Dr. David Clark  
 Wednesday, July 29, 2009, 7-8:15 a.m. EST  
 The implant era has raised the bar for endodontics as new tools and techniques allow for the next level of endodontic excellence. But can endodontics be effectively evaluated? Don't let it last as long as implants!  
 En Th 95  
 REGISTER ON WWW.DTSTUDYCLUB.COM

YouTube ... The Video Granddaddy of Social Media (Part 6 of 6)  
 Mary Kay Miller  
 Thursday, August 6, 2009, 1-2:30 p.m. EST  
 YouTube is the No. 1 video networking site on the Internet today. Learn the dos and don'ts when using YouTube to promote your practice.  
 Pm Th 95  
 REGISTER ON WWW.DTSTUDYCLUB.COM

DTSC Online Masters, featuring the Roots Summit and the Implants Summit  
 Various speakers  
 Saturday, Aug. 8, 2009, 10 a.m.-5:30 p.m. EST  
 A full day of Webinars covering various topics in endodontics and implantology, taught by opinion leaders in the industry.  
 En Im 7h FREE  
 REGISTER ON WWW.DTSTUDYCLUB.COM

Ortho Tribune Study Club Launch - Online C.E. Festival  
 Various speakers  
 Saturday, Aug. 15, 2009, 10 a.m.-5:30 p.m. EST  
 The DTSC will be launched with a full day of interactive Webinars covering various topics in orthodontics taught by opinion leaders in the industry.  
 Or 7h FREE  
 REGISTER ON WWW.DTSTUDYCLUB.COM

Getting Started in Digital Imaging  
 Various speakers  
 Saturday, Aug. 29, 2009, 10 a.m.-1:30 p.m. EST  
 Through a succession of focused Webinars, leading specialists provide a general overview. Each lecture will provide an introduction to the technology, products and practice management impact of digital imaging.  
 Or 7h FREE  
 REGISTER ON WWW.DTSTUDYCLUB.COM

Getting Started in Lasers  
 Various speakers  
 Saturday, Sept. 5, 2009, 10 a.m.-1:30 p.m. EST  
 Through a succession of focused Webinars, leading specialists provide a general overview. Each lecture will provide an introduction to the technology, products and practice management impact of laser dentistry.  
 Or 7h FREE  
 REGISTER ON WWW.DTSTUDYCLUB.COM

BECOME A FREE MEMBER  
 WWW.DTSTUDYCLUB.COM

# AAP to host meeting in Boston

The American Academy of Periodontology (AAP) will host its 95th Annual Meeting in Boston, Mass., from Sept. 12-15 at the new Boston Convention and Exhibition Center. Attendee registration is now open, and dental professionals from all specialties are encouraged to register to learn about the latest advancements in periodontology. More than 5,000 dental professionals and participating vendors are expected to attend.

The four-day meeting will include a variety of educational and scientific sessions in seven distinct program tracks, covering topics such as dental implants, periodontal-systemic relationships, practice development and management, and regeneration and tissue engineering. Traditional contin-

uing education courses, as well as hands-on workshops and clinical technique showcases will be offered. In total, more than 50 educational and scientific sessions will be offered.

Of particular note is this year's Opening Ceremony, which will officially kick off the meeting on Sept. 12 with welcome remarks from the 2009 AAP President, David Cochran, DDS, PhD. The academy is also pleased to announce Paul M. Ridker, MD, as the opening ceremony's keynote speaker. Ridker is a leading researcher in inflammation and cardiovascular disease, and was an important contributor to the recent joint consensus paper on cardiovascular disease and periodontal disease published by The American Journal of Cardiology and

the Journal of Periodontology.

"This is an exciting time in periodontics, so I am thrilled to invite the dental community to join us in Boston," Cochran said. "It has become critical that all dental professionals understand the connection between periodontal disease and other chronic diseases of aging, such as cardiovascular disease, and especially the role inflammation plays in this connection. Our 2009 Annual Meeting offers an exciting and informative forum to learn about these important advances."

For more information or to register for the Annual Meeting, visit [www.perio.org/meetings](http://www.perio.org/meetings) or call (312) 575-5216 or send an e-mail to [angela@perio.org](mailto:angela@perio.org). **IT**

AD



## NobelActive™

Taking a new direction in implants.

**Dual-function prosthetic connection**

**Bone-condensing property**

**Adjustable implant orientation for optimal final placement**



**Built-in Platform Shifting™**

**High initial stability, even in compromised bone situations**

**10 YEARS WITH TITANITE® SURFACE**  
 New data confirm long-term stability.

NobelActive equally satisfies surgical and restorative clinical goals. NobelActive thread design progressively condenses bone with each turn during insertion, which is designed to enhance initial stability. The sharp apex and cutting blades allow surgical clinicians to adjust implant orientation for optimal positioning of the prosthetic connec-

tion. Restorative clinicians benefit by a versatile and secure internal conical prosthetic connection with built-in Platform Shifting upon which they can produce excellent esthetic results. Based on customer feedback and market demands for NobelActive, the product assortment has been expanded - dental professionals will now enjoy even greater

flexibility in prosthetic and implant selection. Nobel Biocare is the world leader in innovative evidence-based dental solutions. For more information, contact a Nobel Biocare Representative at 800 322 5601 or visit our website, [www.nobelbiocare.com/nobel-active](http://www.nobelbiocare.com/nobel-active)

Nobel Biocare USA, LLC, 22715 San Francis Parkway, Yorba Linda, CA 92587, Phone 714 262 4500; Toll free 800 322 5601. Tech. support 800 735 2500; Fax 714 262 9022.  
 Nobel Biocare Canada, Inc. 8152 Leslie Street, Unit 101, Richmond Hill, ON L4B 4N1; Phone 905 762 2070; Toll free 800 322 5294; Fax 905 889 4243.  
 © Nobel Biocare 2009. All rights reserved. [www.nobelbiocare.com](http://www.nobelbiocare.com)