

CAD/CAM

international magazine of dental laboratories

interview

Advantages
of a digital workflow

industry report

New paradigm
in aesthetic restoration

education

CAD/CAM can be
an incredible teaching tool

Your formula for quality dentures

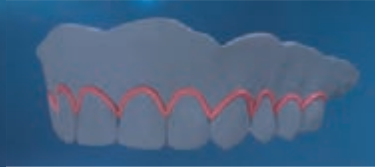V-Print



dentbase

+

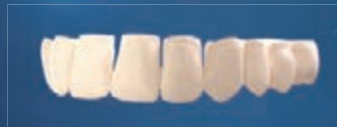CediTEC



Adhesive

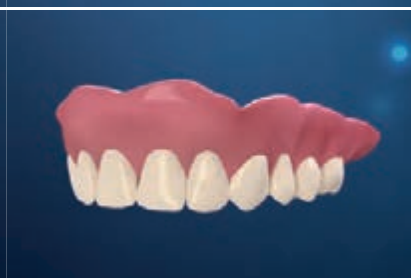+

CediTEC



Denture Teeth

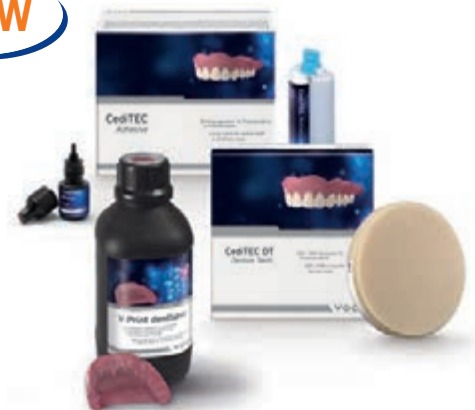=



CAD / CAM SOLUTION FOR PERMANENT DENTURES

- **V-Print dentbase: 3D printing material for the fabrication of denture bases**
 - Precise, custom-fit & quickly reproducible – for long-term highly comfortable wear
 - Saves time during polishing – thanks to printed surface
 - Universal – compatible with commercially available resin materials and composites
- **CediTEC: Luting material for denture teeth in denture bases**
 - Pinpoint and economical application – directly from the mixing tip
 - Clean & efficient dosing – thanks to practical cartridge
- **CediTEC DT: CAD / CAM composite for denture teeth**
 - Individual, high-quality & aesthetic – for perfect results
 - Compatible with all commercially available composites – for further customising
 - Saves time and expense – can be reproduced quickly at any time

NEW



Magda Wojtkiewicz

Managing Editor



Dear readers,

I have the great pleasure of introducing our new **CAD/CAM** *international magazine of dental laboratories*, which aims to be one of the primary sources of information for dental laboratory owners and dental technicians. This is the first publication in Dental Tribune International's portfolio focused mostly on dental technicians and their needs.

In the era of rapid changes and transition from a conventional to a digital workflow in dental offices and laboratories, it is crucial to stay updated with the latest technologies. Nowadays, dental technicians need to be more involved in what dentists are doing. Whether managing an in-house laboratory working intimately with the dentist and patient or owning a larger laboratory organisation and consulting over the phone or in person, the dental technician's role is now, more than ever, that of an integral partner with the dentist to achieve the best results for the patient.

As the role of the dental technician continues to change, so too does the need to acquire specific knowledge and skills. Dental technicians need to broaden their knowledge. Owing to omnipresent digital technology, many technicians are involved in treatment planning and

procedures such as guided surgery, implantology and full-mouth rehabilitation. Digital technology has helped to break down the separation of dental offices and dental laboratories by involving technicians in all aspects of the dental treatment workflow.

This rapid change in the dental field will continue and will have an increasing impact on the industry and its structure. Soon, CAD/CAM will be supporting every single department within the laboratory and digital technology will create even more collaboration with dentists.

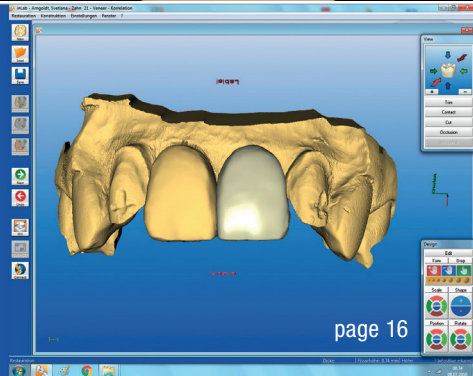
Inside this issue of **CAD/CAM**, you will find articles about advantages of the digital workflow, computer-aided treatment planning, matching the CBCT scan and virtual wax-up, the latest CAD/CAM software developments and much more. I hope you will find our magazine informative and that it will encourage you to continue to learn about and embrace the digital reality.

Sincerely,

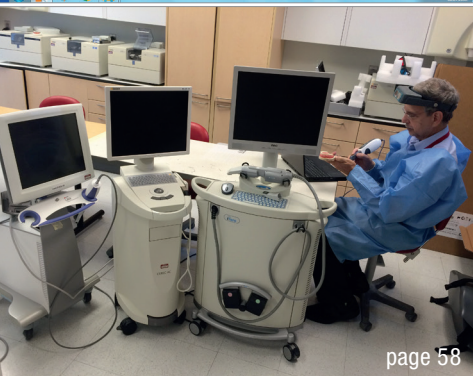Magda Wojtkiewicz
Managing Editor



page 08



page 16



page 58

Cover image courtesy of sunlight19/Shutterstock.com



editorial

Dear **readers** 03
Magda Wojtkiewicz

interview

Advantages of a **digital workflow** 06
An interview with Germen Versteeg

industry report

New paradigm in aesthetic restoration 08
Francesco Ferretti & Dr Marco Nicastro

Mill, polish, seat! Indirect procedures in the **dental workflow** 12
Dr Johannes Beiter

Anterior restoration with **CAD/CAM veneers** 16
made of VITABLOCS TriLuxe forte
Dr David Jäger, Dr Martin Hammer & Carmen Scheibling

The complete digital implant workflow 20
Drs Kirill Kostin, Mikhail Erohin, Oleg Ponomarev & Maxim Kozhevnikov

case report

Matching of CBCT and virtual wax-up 24
for single-tooth replacement of a central incisor
Dr Jakob Zwaan & Vito Minutolo

Computer-aided, template-guided immediate implant placement 36
and loading in the mandible
Dr Thomas Spielau, Uli Hauschild & Dr Joannis Katsoulis

special

Making a **perfect ceramic crown** 44
on a **titanium abutment** in the aesthetic zone
Patrick Rutten

manufacturer news 50

industry

“We are in the forefront of CAD/CAM software development” 48
An interview with Tillmann Steinbrecher

“Excellence made easy” through speed, user **friendliness and precision** 56
An interview with Dr Alexander Völcker

education

CAD/CAM can be an incredible **teaching tool** 58
An interview with Dr Gary Hack

about the publisher

submission guidelines 60

international imprint 62

MAESTRO 3D

Innovative solutions for dental applications

www.maestro3d.com



2 x 5.0 MEGAPIXEL

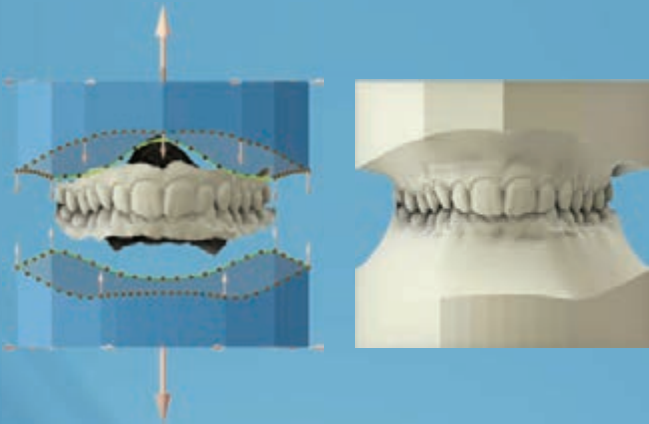
Plug & Play 

Smart Impression Scanning

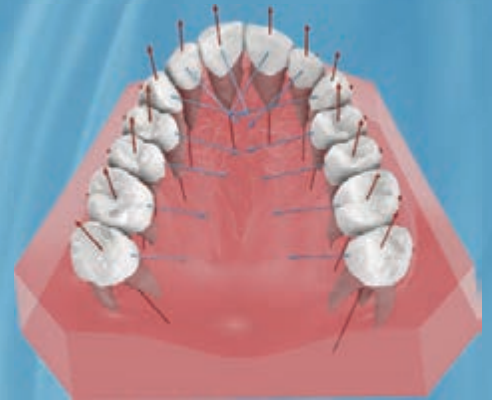
Accuracy less than 8 micron

Texture Superimposition

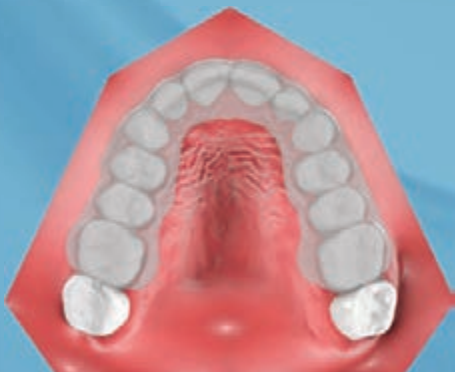
Study Models



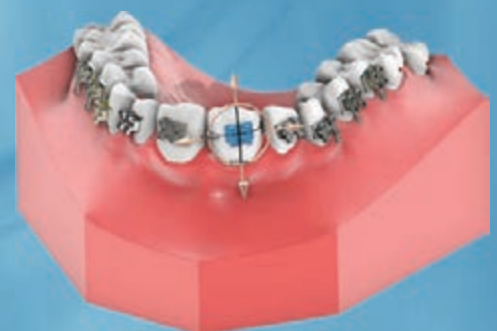Virtual Setup



Clear Aligner



Indirect Bonding



Advantages of a digital workflow

An interview with Germen Versteeg, DTL Mediaan founder. By Brendan Day, DTI



Germen Versteeg

Germen Versteeg is the founder of DTL Mediaan, a dental laboratory in Heerhugowaard in the Netherlands. In this interview, he talks about the advantages of having adopted a digital workflow in his laboratory and the advice he has for other laboratories that are planning to do the same.

Mr Versteeg, could you tell us a little bit about yourself.

I'm a denturist and the owner of DTL Mediaan. We work with a team of eight dental technicians, and as a completely digital dental lab, we provide all kinds of services—implant cases, dental crowns and bridges, dentures, orthodontic solutions, and more.

Do you find that a digital workflow saves time compared with an analogue workflow?

Yes, it can take a lot of time to produce something with an analogue workflow. For example, it would take up to one whole working day to produce a set of dentures from beginning to end. Since going digital, we have saved a lot of time and can now make a set of dentures in 2 to 2.5 hours.

We can achieve a really high standard of quality because of the accuracy of 3Shape's scanners. At every step of the workflow, we can refer to the design or the manufacturing process, and we can reproduce or conduct a correction for any case.

What percentage of your cases use intra-oral scans?

About 30 to 40 per cent of our cases involve intra-oral scans, which is also a big benefit of working digitally.

What has your experience using the 3Shape Dental System been like?

Our experience with the 3Shape Dental System has been really great. There are a lot of automated and guided workflows in the software, but you also have the possibility of being creative in your approach. For example, we can use a 2D or 3D image in the software for the design in such a way that we are able to copy the patient's dentition and transfer it to the dentures.

When you become familiar with the system and get to know the ideas behind it, you will be amazed at what you can do with this powerful software.

Has going digital led to an increase in productivity for DTL Mediaan?

Yes, we really are more productive. Our labour costs were around 50 per cent of our total costs when we were an analogue-focused lab. Now, thanks to the 3Shape Dental System, our labour costs have dropped down to 20 per cent of our total costs.

What advice do you have for dental labs planning to go digital?

My advice for dental labs that want to begin working according to a digital workflow is that they should go fully digital and start implementing it immediately.

[DIGITAL]

3 series/7 series

Seamless communication from
scan to production.



PRECISE

Latest generation
Blue Laser Illumina-
tion system for high
scan accuracy and
resolution



VALIDATED

Proven and
established scan-
ning and CAD pro-
cesses with CARES®
Visual software



SIMPLE

Fully integrated
CARES® Visual
software for digital
design and direct
data transfer



FLEXIBLE

Milling at central
milling center or
in-lab, open to im-
porting/exporting
STL files

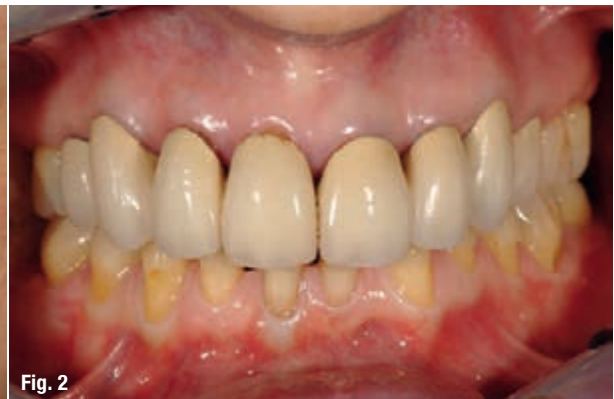
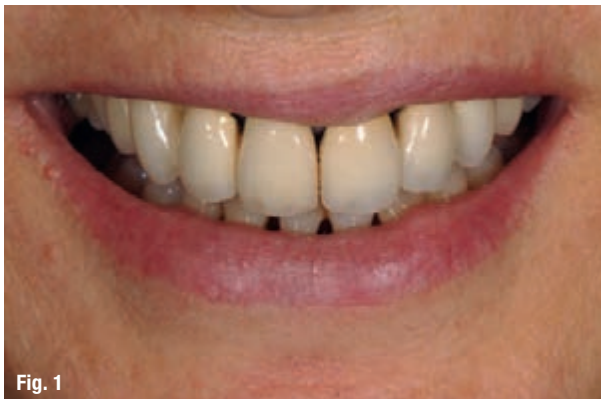
For further information contact your local Straumann®
representative or visit www.straumann.com.

A0010/en/E/00 02/20

New paradigm in aesthetic restoration

Francesco Ferretti & Dr Marco Nicastrò, Italy



This article presents a case of aesthetic restoration of anterior teeth using KATANA Zirconia Ultra Translucent Multi Layered (UTML; Kuraray Noritake Dental) complete anatomical crowns, with vestibular stratification, and the biologically oriented preparation technique (BOPT).

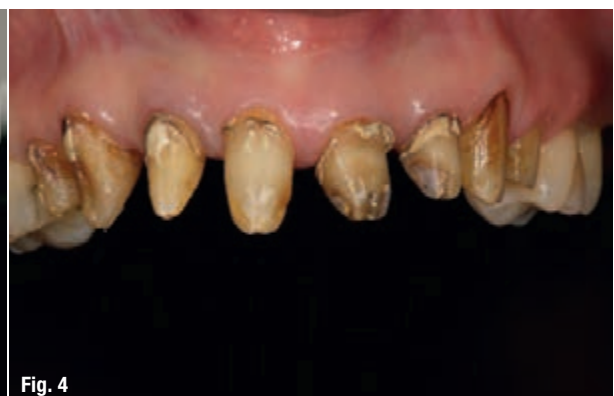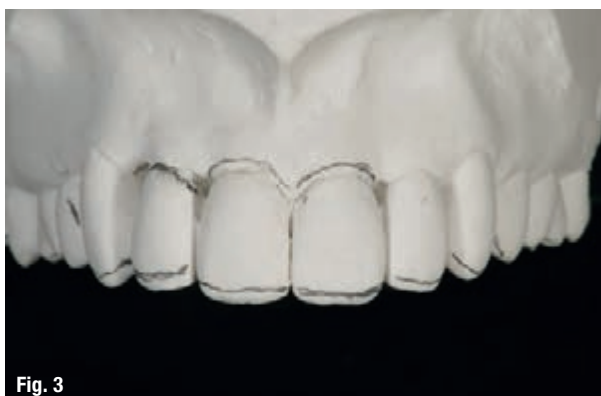The patient requested a solution for an aesthetic problem due to the unnatural look of her old restorations and black triangles from a past history of periodontitis. The resulting retraction of the tissue had left the margins of the prostheses clearly visible, and the loss of the papilla peaks, together with the numerous black spaces between the crowns, required a complex therapeutic approach (Fig. 1).

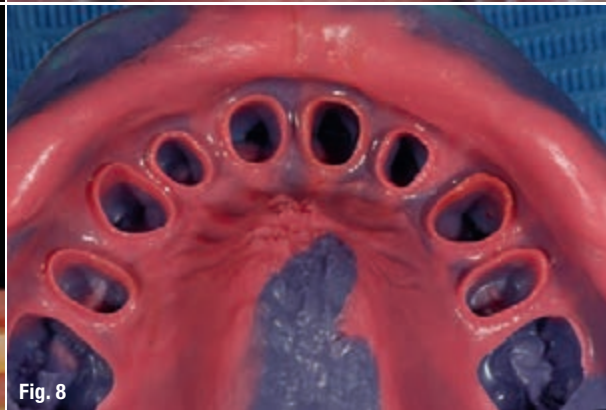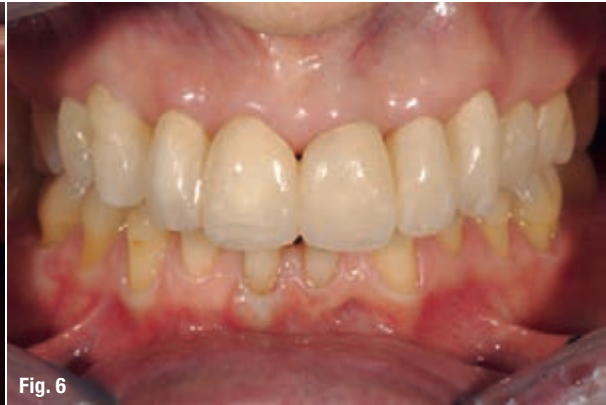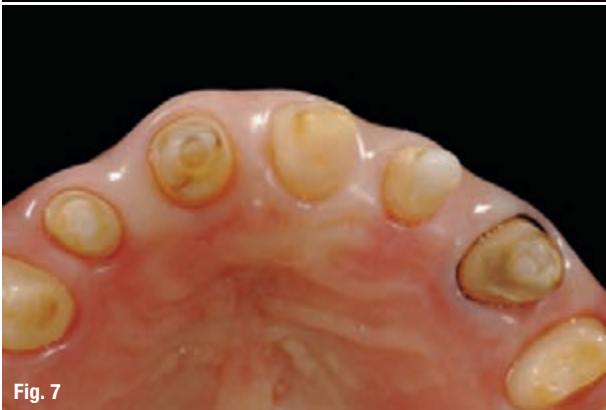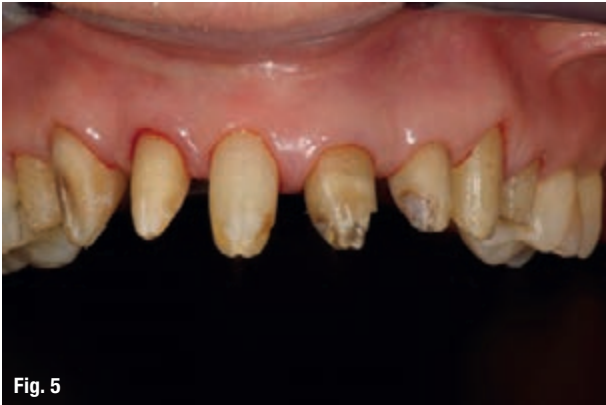The treatment plan for the periodontal problems consisted of a non-surgical approach, with scaling and root

planing, and the replacement of the old fixed prostheses to recondition the marginal tissue and facilitate the restoration of a new, aesthetically pleasing gingival architecture (Fig. 2).

From a functional point of view, we decided to reduce the deep frontal bite to restore a correct overjet–overbite ratio. This reduction was also important from an aesthetic point of view, as it allowed us to shape the teeth correctly (Fig. 3).

We usually remove old prostheses before beginning a periodontal treatment and make a provisional restoration to create an environment in which the soft tissue can heal. If we have to work beyond the cemento-enamel junction, we prefer a vertical preparation for abutments, and the purpose of the provisional restoration





is to condition the marginal tissue using the BOPT by Dr Ignazio Loi (Fig. 4).

For the BOPT, the vertical preparation of the abutment has a finishing line that extends into the gingival sulcus. The temporary conditioning of the tissue induced by the provisional prosthesis allows us to modify the level of the gingival parabolas to a certain extent (Fig. 5).

Healing of the tissue one month after the initial periodontal treatment was significant (Fig. 6). The role of the provisional restoration, appropriately realigned, is crucial for obtaining healthy soft tissue around future restorations. The conditioning of the tissue was achieved by means of the provisional restoration, which modified the level and shape of the marginal tissue. Once filled with correctly

fitted crowns, the interproximal spaces would be further reduced after the definitive restoration.

The correct management of the provisional restoration is crucial for the healing of the tissue. The placement of a provisional restoration before the periodontal therapy allowed us to create the right environment for complete healing. At the same time, the vertical preparation allowed us to gradually condition the marginal gingival tissue by shortening or lengthening the provisional restoration as necessary (Fig. 7).

One of the advantages of a vertical preparation is that taking the final impression is easy, because the absence of a horizontal finishing line greatly simplifies the procedure (Fig. 8). However, the BOPT also requires the taking of an

