

# ORTHO TRIBUNE

The World's Orthodontic Newspaper • U.S. Edition

MAY 2010

www.ortho-tribune.com

VOL. 5, No. 5



**AAO in photos**  
The people & products  
that stole the show

►Pages 10 & 11



**An ortho star**  
Why the Carriere System  
is like nothing else

►Page 14



**Let's go to Vegas!**  
OrthoVOICE gears up  
for September meeting

►Page 22



The exhibit hall floor, as seen from above, during the AAO. (Photos/Kristine Colker, Managing Editor)

*AAO annual session  
offers products, prizes,  
presentations & more*

By Kristine Colker, Managing Editor

If you came to Washington, D.C., for the 110th annual session of the American Association of Orthodontists with a “things to buy” list or a “topics to learn more about” list, chances are you were in luck.

With more than 300 companies showing off their products and services in the exhibit hall and four days filled with courses, hands-on workshops and even a couple live procedures, there was more than enough to keep any orthodontist or staff member busy from morning to evening.

Take the exhibit hall and the array of merchandise on display. There were all the basics — brackets, wires, retainers, digital imaging

→OT page 12

## Miniscrews — a focal point in practice

*Part 2 of 6: Basic  
information on the  
insertion of miniscrews*

By Dr. Björn Ludwig, Dr. Bettina Glasl,  
Dr. Thomas Lietz and Prof. Jörg A. Lisson

The insertion of a miniscrew is a very simple and rapid therapeutic measure. Although there are several methods that will yield good results, successful insertion requires adherence to a few important principles. The following text details those insertion steps that offer a high degree of safety for both patient and clinician (see checklist for insertion on page 5). It should be noted that this information is generalised and must be adapted to individual circumstances.

General notes on insertion  
Accurate pre-operative planning is a basic requirement for

→OT page 4

AD

WELCOME  
OrthoVOICE  
2K10

MOTIVATE  
CHALLENGE  
CONNECT

September 16-18, 2010

planet hollywood  
RESORT & CASINO • LAS VEGAS

For a new generation of orthodontists who are passionately making their mark on our profession!  
REGISTER TODAY AT: [www.orthoVOICE.com](http://www.orthoVOICE.com)

PRSRST STD  
U.S. Postage  
PAID  
Permit # 306  
Mechanicsburg, PA

Dental Tribune America  
213 West 35th Street  
Suite #801  
New York, NY 10001



# Has the 'golden-age' of orthodontics left the building?

By Dennis J. Tartakow, DMD, MEd, PhD,  
Editor in Chief



There once was a time when an orthodontist was required to learn how pinch-lapping bands, spot-welding brackets, bend loops, hooks and first-, second- and third-order bends in wires as well as various auxiliary appliances work. Diagnosis included drawing our own cephalometric X-rays and trimming our own diagnostic casts — putting the “plaster-on-the-table” as the saying goes.

What has happened to change history? Are we better educated with greater expertise to serve the public, or are we restrained by the many technological advancements?

For those who were privileged to have known or were taught by some of the great orthodontists of the past, you know how truly special it was. We were trained to provide services to the patient without any help from specialty companies.

Today, clinicians have the luxury of sending out X-rays and casts — we don't even have to bend wires any more with the current trends of out-of-the-box treatment.

At some point, we must ask ourselves whether or not (a) technology is inhibiting or enhancing progress, (b) patients are better served or merely recipients of technology, and (c) our brains are still allowing us to function as diagnosticians or are we simply office traffic-cops

directing the flow of services provided in and out of the office from outside help?

The underpinnings of patient care and dignity are emphasized by the importance of delivering quality services. It may be easy imagining how failure to achieve standards of excellence might be a reflection of a culture derived from poor training and fast-lane skills; they are often traced to economics and well-embedded in personal gains rather than providing the best services for patients.

Although patients are unaware of these issues and typically impressed with having the latest or best-of-the-best, technologically advanced care, are they really better served or are we delusional? Difficulties are sometimes encountered in finding high-dependency treatment results from the so-called “advanced technological improvements.”

High-dependency treatment relates to the close proximity of observed results; low-dependency treatment occurs when accompanied by ignorance and is unrecognizable when we have no means of comparison or assessment. Issues of dignity and privacy may be compromised in order to give priority to the seriousness of the patient's care, especially in today's modern society.

Our decisions about patient care are often influenced by media and sales representatives rather than by our own sophisticated intelligence. It is sometimes difficult to find the accommodation appropriate to a specific patient's needs, health and safety. The question is, “Will delusion become implanted in the legacy of orthodontics?”

Decisions to maximize efficiency can be a double-edged sword, and we must be careful about what we wish for, as modernization may become our Achilles heel.

Although the process of patient care being delivered with dignity and privacy is in a sensitive environment, these are issues not confined to the delivery of care, particu-

larly when the decision is to provide the “best” care; it also relates to management decisions for personal gains or advantage.

There is no question that technology cannot be ignored, but neither can it stand in the way of care or progress. However, appropriate application of standards for dignity, privacy and excellence to our patients should be aimed at avoiding gimmicks or attention-grabbers and confined to what we know in our hearts is righteous.

Suggesting that it is exceptional for an orthodontist to have an attitude problem or lack the necessary training regarding issues of patient dignity and privacy is not intended, and neither is it implied that the problem lies with teachers who have failed to acknowledge deficiencies in the fabric of the environment in which care is being offered.

However, it is incumbent upon educators not to be in denial of the structural inadequacies of technology, but rather to encourage individual thinking that is appropriate to achieve patient care with the supreme quality.

Hopefully the present “golden-age” of orthodontics does not have a tarnished halo, and care for our patients is held first and foremost in our minds as well as our hearts. **OT**

## OT Corrections

*Ortho Tribune* strives to maintain the utmost accuracy in its news and clinical reports. If you find a factual error or content that requires clarification, please report the details to Managing Editor Kristine Colker at [k.colker@dental-tribune.com](mailto:k.colker@dental-tribune.com).

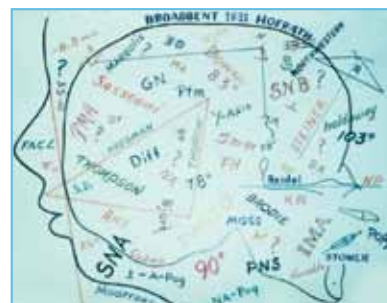


Image courtesy of Dr. Earl Broker.

Member Publication  
**AADE**  
American Association  
of Dental Editors

## ORTHO TRIBUNE

The World's Orthodontic Newspaper - U.S. Edition

### Publisher & Chairman

Torsten Oemus, [t.oemus@dental-tribune.com](mailto:t.oemus@dental-tribune.com)

### Vice President Global Sales

Peter Witteczek  
[p.witteczek@dental-tribune.com](mailto:p.witteczek@dental-tribune.com)

### Chief Operating Officer

Eric Seid, [e.seid@dental-tribune.com](mailto:e.seid@dental-tribune.com)

### Group Editor & Designer

Robin Goodman  
[r.goodman@dental-tribune.com](mailto:r.goodman@dental-tribune.com)

### Editor in Chief Ortho Tribune

Prof. Dennis Tartakow  
[d.tartakow@dental-tribune.com](mailto:d.tartakow@dental-tribune.com)

### International Editor Ortho Tribune

Dr. Reiner Oemus  
[r.oemus@dental-tribune.com](mailto:r.oemus@dental-tribune.com)

### Managing Editor/Designer Ortho Tribune & Show Dailies

Kristine Colker, [k.colker@dental-tribune.com](mailto:k.colker@dental-tribune.com)

### Managing Editor/Designer Implant & Endo Tribunes

Sierra Rendon, [s.rendon@dental-tribune.com](mailto:s.rendon@dental-tribune.com)

### Online Editor

Fred Michmershuizen  
[f.michmershuizen@dental-tribune.com](mailto:f.michmershuizen@dental-tribune.com)

### Product & Account Manager

Humberto Estrada  
[h.estrada@dental-tribune.com](mailto:h.estrada@dental-tribune.com)

### Product & Account Manager

Mark Eisen, [m.eisen@dental-tribune.com](mailto:m.eisen@dental-tribune.com)

### Product & Account Manager

Gregg Willinger  
[g.willinger@dental-tribune.com](mailto:g.willinger@dental-tribune.com)

### Marketing Manager

Anna Wlodarczyk  
[a.wlodarczyk@dental-tribune.com](mailto:a.wlodarczyk@dental-tribune.com)

### Marketing & Sales Assistant

Lorrie Young, [l.young@dental-tribune.com](mailto:l.young@dental-tribune.com)

### C.E. Manager

Julia Wehkamp  
[j.wehkamp@dental-tribune.com](mailto:j.wehkamp@dental-tribune.com)

Dental Tribune America, LLC

213 West 35<sup>th</sup> Street, Suite 801

New York, NY 10001

Phone: (212) 244-7181, Fax: (212) 244-7185



Published by Dental Tribune America

© 2010, Dental Tribune International GmbH  
All rights reserved.

Dental Tribune makes every effort to report clinical information and manufacturer's product news accurately, but cannot assume responsibility for the validity of product claims, or for typographical errors. The publishers also do not assume responsibility for product names or claims, or statements made by advertisers. Opinions expressed by authors are their own and may not reflect those of Dental Tribune International.

## OT Editorial Advisory Board

Jay Bowman, DMD, MSD

(Journalism & Education)

Robert Boyd, DDS, MEd

(Periodontics & Education)

Earl Broker, DDS

(T.M.D. & Orofacial Pain)

Tarek El-Baily, BDS, MS, MS, PhD

(Research, Bioengineering & Education)

Donald Giddon, DMD, PhD

(Psychology & Education)

Donald Machen, DMD, MSD, MD, JD, MBA

(Medicine, Law & Business)

James Mah, DDS, MSc, MRCD, DMSc

(Craniofacial Imaging & Education)

Richard Masella, DMD (Education)

Malcolm Meister, DDS, MSM, JD

(Law & Education)

Harold Middleberg, DDS

(Practice Management)

Elliott Moskowitz, DDS, MSD

(Journalism & Education)

James Mulick, DDS, MSD

(Craniofacial Research & Education)

Ravindra Nanda, BDS, MDS, PhD

(Biomechanics & Education)

Edward O'Neil, MD (Internal Medicine)

Donald Picard, DDS, MS (Accounting)

Howard Sacks, DMD (Orthodontics)

Glenn Sameshima, DDS, PhD

(Research & Education)

Daniel Sarya, DDS, MPH (Public Health)

Keith Sherwood, DDS (Oral Surgery)

James Souers, DDS (Orthodontics)

Gregg Tartakow, DMD (Orthodontics)

& Ortho Tribune Associate Editor

**Tell us  
what  
you  
think!**

Do you have general comments or criticism you would like to share? Is there a particular topic you would like to see more articles about? Let us know by e-mailing us at [feedback@dental-tribune.com](mailto:feedback@dental-tribune.com). If you would like to make any change to your subscription (name, address or to opt out) please send us an e-mail at [database@dental-tribune.com](mailto:database@dental-tribune.com) and be sure to include which publication you are referring to. Also, please note that subscription changes can take up to 6 weeks to process.



# Video puts focus on pediatric dental disease

By Fred Michmershuizen, Online Editor

To help raise awareness of the fight against pediatric dental disease, National Children's Oral Health Foundation: America's Toothfairy (NCOHF) has released a public service announcement video as part of a continued effort against the No. 1 chronic childhood illness in the United States.

The video — "America's Toothfairy: Transforming Children's Lives" — was produced to educate the general public about the prevalence of pediatric dental disease and highlight the measures that NCOHF nonprofit affiliate health-care facilities are taking to provide underserved children nationwide with compassionate, comprehensive oral health care.

"Millions of children are suffering in silence from oral pain so severe that it impacts their ability to eat, sleep and learn on a daily basis," said Fern Ingber, NCOHF president and CEO.

"With access to basic preventive care and simple educational tools, pediatric dental disease is completely preventable. We hope this film will create a robust public dialogue surrounding our country's oral health epidemic and encourage increased support for nonprofit health-care centers that work tirelessly on limited resources to eliminate this disease from future generations."

Two dental health-care professionals offer their comments in the video.

"Dental caries is still very much a disease; in fact, it is the most common chronic disease in childhood," says Dr. J. Timothy Wright, professor and chair of pediatric dentistry at the University of North Carolina School of Medicine.

"Oral health is one of the leading causes of children not being in school."

Dr. Rocio Quinonez, clinical associate professor at the University of North Carolina School of Dentistry, says, "We as a profession certainly share the same mission as the NCOHF, and that is to get to kids early enough so that we can not only prevent disease but change the trajectory of oral health and general health outcome."

"America's Toothfairy: Transforming Children's Lives" was produced by Emulsion Arts Film Production Co. with funding from DENTSPLY International, a dedicated NCOHF underwriter.

The video may be viewed on the Ortho Tribune website's media

center, located at [mediacenter.ortho-tribune.com](http://mediacenter.ortho-tribune.com). [OT](#)

*Children who have received care thanks to the efforts of the National Children's Oral Health Foundation: America's Toothfairy are featured in a new video. (Photo/Provided by NCOHF)*



AD

## Satisfy the growing demand for early treatment

**Malocclusion in children is more prevalent than dental caries.**  
With the high demand from parents for early treatment now approaching, it is vital to learn how to arm yourself with the most cost effective treatment.

**Take your practice to the next level.**

Did you know 3 out of 4 children have a malocclusion. Detection and evaluation needs to be more than, "You are going to need braces in the future".

Parents want to know what can be done about their child's malocclusion both now and in the future. **What are the options?** Earlier treatment is now a viable option handled by the general Dentist.

*"Early treatment may prevent more serious problems from developing and/or make treatment at a later age shorter and less complicated. Early treatment may also achieve results that are not possible once the face and jaws have stopped growing."* [www.aso.org.au](http://www.aso.org.au)

MRC has pioneered the use of myofunctional appliances in the early treatment of malocclusion and orthodontic treatment without braces.

Find out why MRC's comprehensive appliance systems are being used by dentists and orthodontists in over 100 countries. Meet the growing demand from parents for early orthodontic treatment without the need for braces or extractions.

**MYOFUNCTIONAL RESEARCH CO.**  
[www.myoresearch.com](http://www.myoresearch.com)  
**a BETTER way**

**Option 1** Call MRC on 1 866 550 4696 or visit [www.myoresearch.com](http://www.myoresearch.com)

**Option 2** Attend an MRC course explaining the clinical procedures and the profit potential for your practice.

1881 ENO Ortho-Trib 05/10



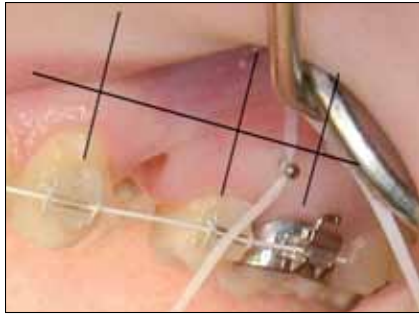


Fig. 1: X-ray positioning aid (X-ray pin, FORESTADENT) shown in situ in relation to the adjoining tooth axes.

← 01 page 1

successful treatment with miniscrews. Such planning includes a comprehensive anamnesis and an accurate assessment of the findings. It is essential that the treatment be thoroughly explained to the patient.

Proper hygiene must be ensured throughout the entire operation. Both the chair and the treatment process must be prepared with this in mind.

During the insertion of a miniscrew, adherence to all hygiene measures required for an invasive procedure, such as a sterile work environment and gloves, must be ensured. All instruments required for insertion must be checked for completeness, functionality and sterility.

The patient may rinse with a disinfectant solution, or a suitable disinfectant can be locally applied. The patient should then be positioned to ensure a clear view of the operational area and ergonomically facilitate insertion for the treating clinician.

### Pre-operative planning

To function correctly, a miniscrew requires firm anchorage in the bone (primary stability) and the positioning of its head in the denser gingival tissue (gingiva alveolaris). The selection of the insertion site must take clinical and para-clinical findings into account (X-ray image, model), as well as the goal of the treatment and the resulting orthodontic appliance.

For interradicular insertion, a bone thickness of at least 0.5 mm around the miniscrew is required. This means that for a miniscrew with an — for many reasons — optimal diameter of 1.6 mm, the roots must be at least 2.6 mm from each other. Thus, the bone status and the longitudinal axis of the insertion site must be carefully evaluated.

Basic information regarding this is obtained by carrying out measurements on the model. It often helps to mark the vertical axis of the teeth and the progression of the muco-gingival line on the model, based on the clinical and radiological findings. This will allow for an improved assessment of the spatial circumstances in combination with the X-ray image.

To assist the accurate determination of the insertion site, X-ray aids (Fig. 1) are available. Although their

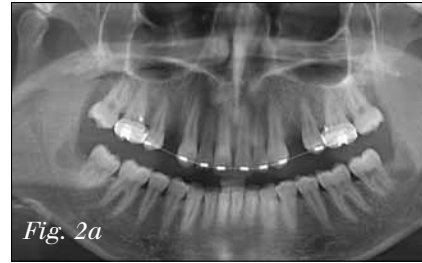

Fig. 2a

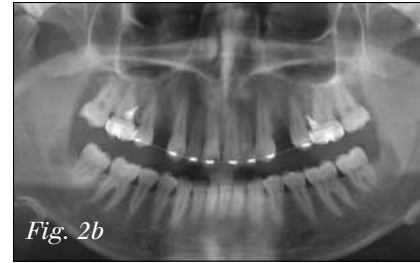


Fig. 2b

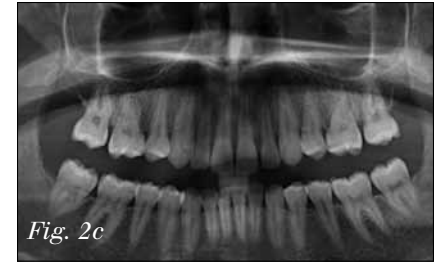


Fig. 2c

Figs. 2a–c: The top image shows the initial situation. An X-ray pin was inserted into the first and second quadrants of the upper jaw (in the 6–5 region) to check the bone site, followed by the miniscrew. Both screws were inserted in a manner that is clinically safe, but the X-ray images show damage to the adjoining root in the right-hand quadrant, indicating a false-positive initial interpretation of the situation.

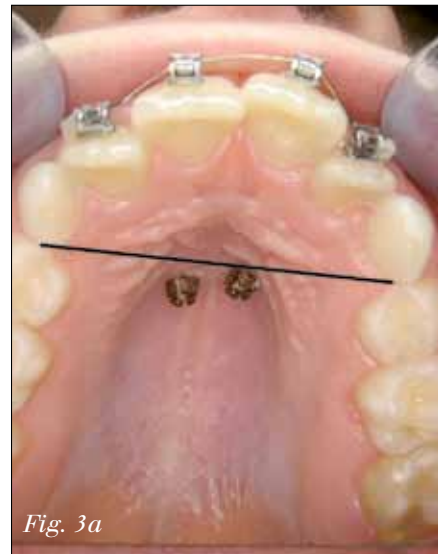

Fig. 3a

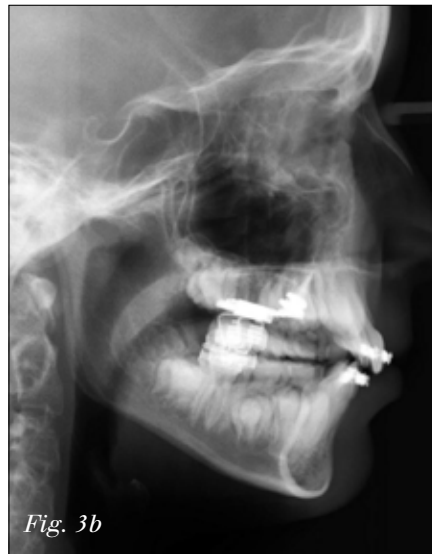

Fig. 3b

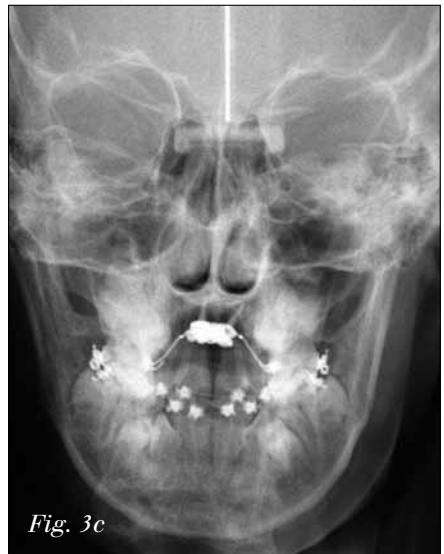

Fig. 3c

Figs. 3a–c: The clinical image shows two miniscrews inserted into the palate in the safe zone to the distal side of the transversal line linking the two canines. The FRS and the PA image confirm the bone support in the insertion region.

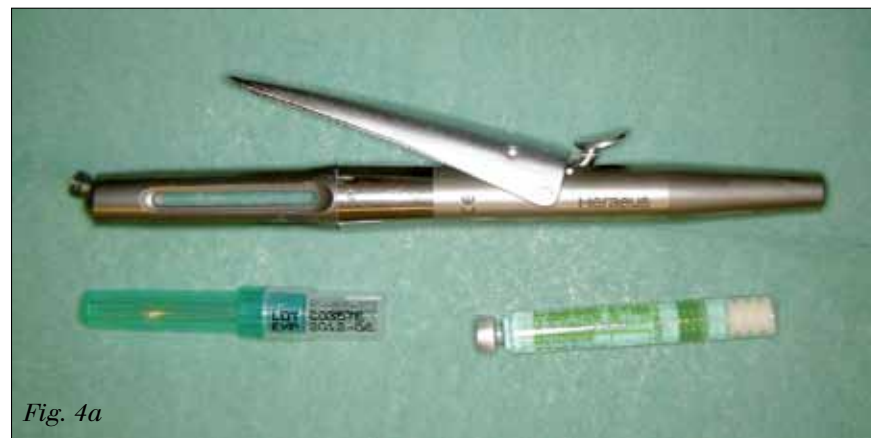

Fig. 4a

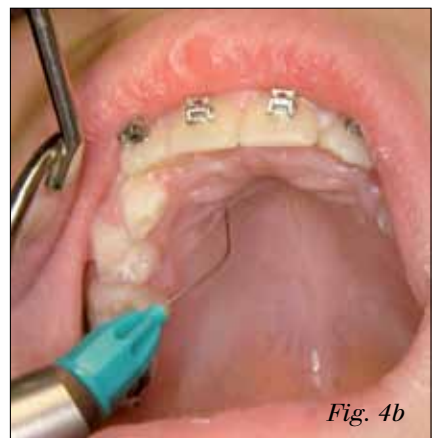

Fig. 4b

Figs. 4a, 4b: Injection pen with needle and anesthetic cartridge and injection of anesthetic.

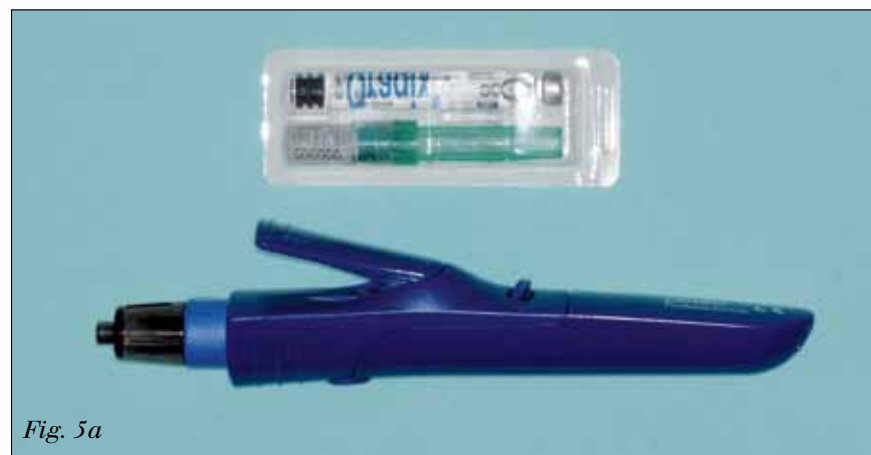

Fig. 5a

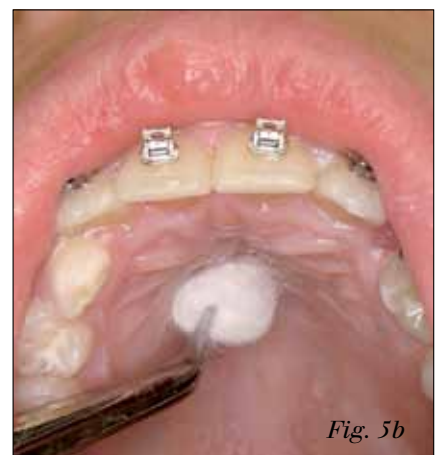

Fig. 5b

Figs. 5a, 5b: Superficial anesthetic device in pen form with cartridge, and application of superficial anesthetic.

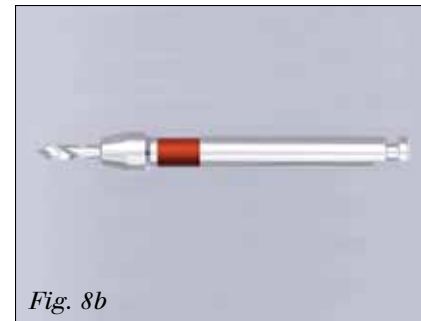
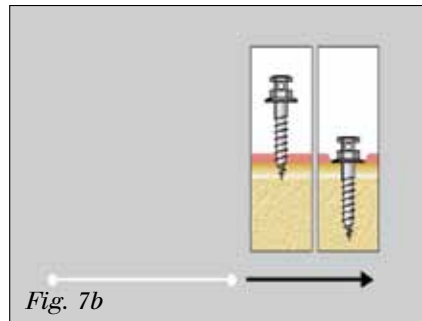
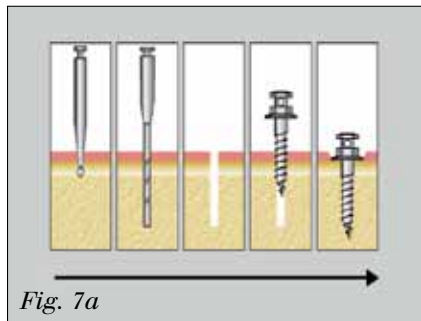
use facilitates the selection of the insertion site, they cannot replace other diagnostic measures.

This is because, depending on the positioning of the X-ray tube, object, film, and/or sensor, all types of X-ray devices and images may yield some optical distortion. Interpretation of images can thus

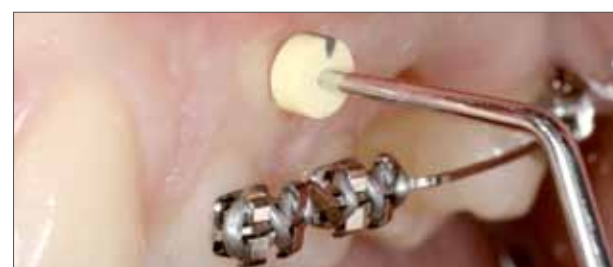

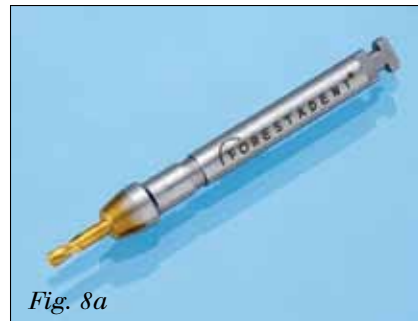Fig. 6: Measuring of the thickness of the mucous membrane in the direction of insertion. (Photo/Dr. Pohl)





Figs. 7a, 7b: Diagrams showing the thread mechanisms: self-cutting and self-tapping.

Figs. 8a, 8b: Pre-drill with a 4 mm long blade and limit stop: Drill (FORESTADENT) and tomas-drill SD (DENTAURUM).

lead to false-negative or false-positive results (Figs. 2a-c).

Therefore, the placement of a miniscrew should always be

based on the clinical findings. If a miniscrew is to be inserted into an area in which there is no risk of damage to roots, nerves or blood vessels (e.g. into the palate just behind the transverse line linking the two canines), the position of the screw may be freely chosen (Figs. 3a-c).

### Anesthetic

During the interradicular insertion of a miniscrew, the sensitivity of the periodontal tissue of the adjoining teeth should be retained. For this reason, the following two procedures are recommended:

- a) a low-dose injection of about 0.5 ml anesthetic (Figs. 4a, b); and

- b) the induction of superficial anesthesia of the mucous membrane at the insertion site, for which a topical anesthetic gel is suitable (Figs. 5a, b). No general anesthetic is ever required for this procedure.

→ OT page 6

## Checklist for insertion

### Pre-operative planning and preparation:

- planning documentation (X-ray, situational models);
- marking of the muco-gingival line and tooth axes on the model, determining the site of insertion; and
- sterilization of the instruments and preparation of the workstation.

### Anesthetic and assessment of the insertion site:

- anesthetic;
- use of X-ray aids; and
- control image.

### Selection of the screw:

- measuring of the thickness of the mucous membrane (optional);
- determination of the length; and
- determination of the type of screw.

### Transgingival penetration:

- excision of the mucous membrane or perforation with the screw.

### Preparation of the bone site:

- optional marking of the bone; and
- perforation of the cortical bone or deep pilot drilling, depending on the type of screw.

### Insertion of the miniscrew:

- manually or by machine.

### Start of orthodontic measures:

- attaching and fixing of the linking elements.

### Post-operative care:

- notes on care and behaviour; and
- check-up dates.

### Removal of the miniscrew:

- removal of the linking elements; and
- removal of the miniscrew.

**JOIN THE REVOLUTION!**

**EDGE**


The future of successful practice management is here.

Get the revolutionary Edge™ to maximize your practice efficiency and profitability. Ortho2 brings you the latest in state-of-the-art management, imaging, and communications software that's supported by an industry-leading customer service team.

<p><b>Leading Edge Technology</b></p> <ul style="list-style-type: none"> <li>• Web-enabled application with offsite data hosting option</li> <li>• Convenient drag-and-drop design</li> <li>• Customizable widget library</li> <li>• Next-generation imaging</li> <li>• PC, Mac, and multi-monitor support</li> </ul>	<p><b>Cutting Edge Efficiency</b></p> <ul style="list-style-type: none"> <li>• Staff "roles" customize available features and views</li> <li>• Workflows auto-sequence tasks</li> <li>• Online patient forms and images</li> <li>• Flexible patient reminders</li> <li>• HR Manager tools</li> </ul>	<p><b>The Edge in Profitability</b></p> <ul style="list-style-type: none"> <li>• Motivational Goal Tracker</li> <li>• Effective Collections Assistant</li> <li>• Powerful Smart Scheduler</li> <li>• Animations for case presentation</li> <li>• Multi-year graphs and trends</li> </ul>
---	--	--

Join the revolution. Take your practice to the Edge today.  
[www.TheEdgeRevolution.com](http://www.TheEdgeRevolution.com)

800. 678. 4644 • [www.ortho2.com](http://www.ortho2.com)

  
**ORTHO2**  
 Practice Complete Management.

Edge, Ortho2, Practice Complete Management, and the Ortho2 logo are trademarks of Ortho Computer Systems, Inc. ©2010 Ortho Computer Systems, Inc. All rights reserved.

AD



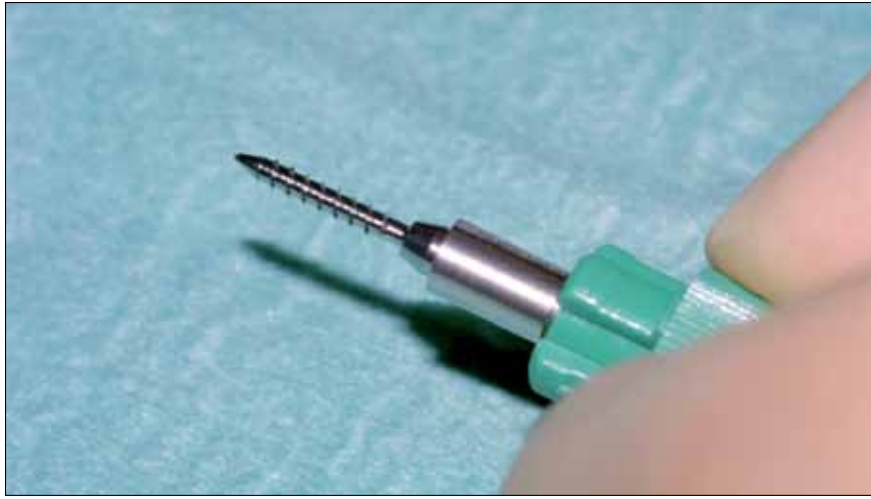

Fig. 9: Sterile miniscrew supplied in pin-holder (tomas-pin, DENTAURUM).

← OT page 5

### Measuring of the thickness of the mucous membrane

A pointed sensor with an attached rubber ring is used to measure the thickness of the gingival tissue in the direction of insertion (Fig. 6). This information may be useful when determining the final length of the screw and possibly when inserting the miniscrew.

When choosing the length, the bone repository and the thickness of the mucous membrane in the direction of insertion play a role; in the retromolar section of the lower jaw and in the palate, the thickness of the mucous membrane is often more than 2 mm.

The part of the miniscrew inside the bone must be at least as long as the part outside the bone. The various dimensions must be taken into account.

The thickness of the bone in the direction of insertion determines the required length of the miniscrew:

- bone thickness greater than 10 mm: miniscrews with a length of up to 10 mm are to be used;
- bone thickness less than 10 mm and greater than 7 mm: miniscrews with a length of 8 mm or 6 mm are to be used; and
- bone thickness less than 6 mm: miniscrews cannot be used.

The following guidelines aid in selecting the length:

- in the buccal region of the upper jaw: 8 mm or 10 mm;
- in the palatal region (depending on the region): 6, 8 or 10 mm; and
- in the lower jaw: usually 6 mm or 8 mm.

### Determination of the type of thread

Self-cutting miniscrews require pre-drilling (also known as pilot drilling) appropriate to the length and diameter of the screw, as well as to the quality of the bone. A self-tapping miniscrew will find its own way into the bone and requires no pre-drilling (Figs. 7a, 7b).

Bone is more or less elastic depending on site, age and structure. However, the screw diameter, the thickness of the cortical bone and the hardness of the bone at the insertion site limit the extent to

which this method can be used.

Without pre-drilling, the bone will be strongly compressed during insertion and thus suffer a related tension stress. This may result in the cracking of the bone around the insertion site.

When the screw is screwed into the bone, it is subjected to high loads. Depending on the bone quality, the resistance against insertion and the continuity of the rotational movement, high torsional forces can result.

In regions with thick cortical bone and a much looser bone structure (e.g. the upper jaw), the use of self-tapping screws is recommended. In regions where the cortical bone is thick and the bone structure is dense (e.g. the anterior lower jaw) both self-cutting and self-tapping screws may be used, in each case following perforation of the compact bone.

### Transgingival penetration

The miniscrew must penetrate through gingival tissue, which must thus be perforated during insertion. Two methods are used for the perforation of the gingival tissue: a) excision of the gingival tissue; or b) direct insertion of the screw through the gingival tissue.


There are currently no published studies that investigate the effect of these two methods on post-operative problems, histological effects and/or the loss rate of miniscrew.

### Preparation of the bone site

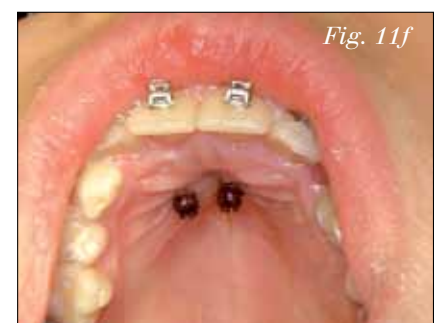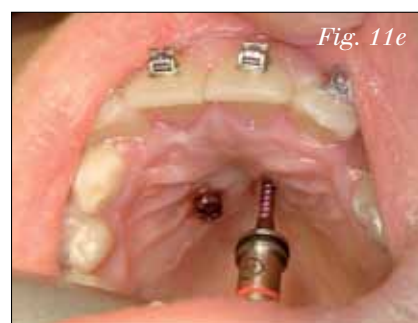Protection of the bone is an important aspect. Insertion without pre-drilling results in tensional stress within the bone, which may lead to post-operative complications.

Particularly in the case of crestally placed screws, bone displacement may result in a severe expansion of the periosteum. The thickness of the cortical bone, especially in the lower jaw, can have a significant effect on the torque of the screw.

To ensure that the screw is not overloaded during insertion, the compact bone of the anterior lower jaw should be perforated by pre-drilling as mentioned earlier. Pre-drilling should be done at a maximum of 1.500 rpm<sup>-1</sup>, using a short pilot drill and water-cooling to reduce the risk of damaging the root (Figs. 8a, 8b).



Figs. 10a–d: Preparation of the work rack and removal of the blades.



Figs. 11a–f: Preparation of the instruments and insertion of two miniscrews into the palate by machine.

### Insertion of the miniscrew

The miniscrew must be removed from its sterile packaging (Fig. 9) or the work rack (Figs. 10a–d) without contamination. The thread of the screw may not be touched. The screw should be inserted at a constant rotational speed (at approximately 30 rpm<sup>-1</sup>) and with as uniform a torque as possible.

### Manual insertion

Manufacturers supply various

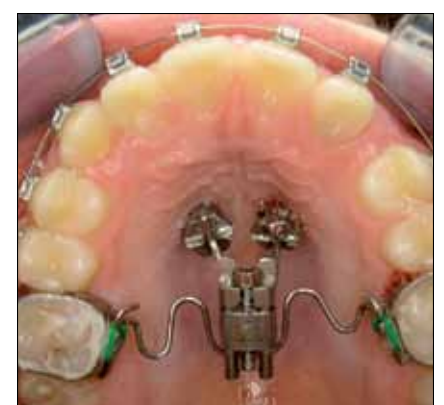

Fig. 12: Linking of the miniscrew to the orthodontic appliance.

→ OT page 8



**“I have seen a remarkable transformation in my patients’ oral health with this program!”**

*—John Kelley, DDS, MS, Fort Worth, TX*



## **Introducing...OrthoEssentials**

The premier program specifically designed to inspire excellent oral hygiene among your patients throughout their treatment...*and beyond*



ortho :)  
essentials  
*wire your world*

To learn more about this exciting program, contact your **Crest Oral-B representative**, visit [www.dentalcare.com/ortho](http://www.dentalcare.com/ortho), or call **1-800-543-2577**.



← 01 page 6

screwdrivers and blades in several lengths for the manual insertion of the screws.

Because of their dimensions, long blades pose the risk of attaining a very high torque during insertion. Thus, insertion must be carried out carefully to avoid breaking the miniscrew.

Torque ratchets are available for use with some systems (e.g. tomas, DENTAURUM; and LOMAS, Mondeal), which provide a certain amount of control over the insertion torque.

### Machine insertion

Machine insertion requires a surgical treatment unit (the torque of which can be controlled) or at least a low-rpm dual-green handpiece.

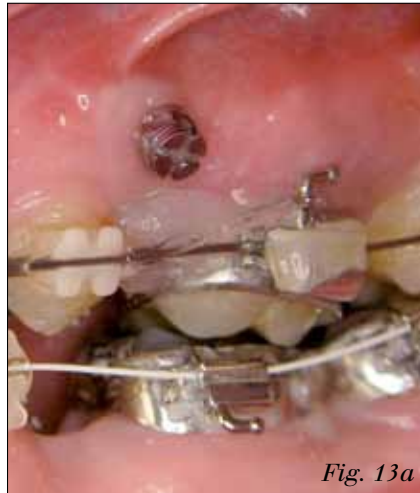

Fig. 13a

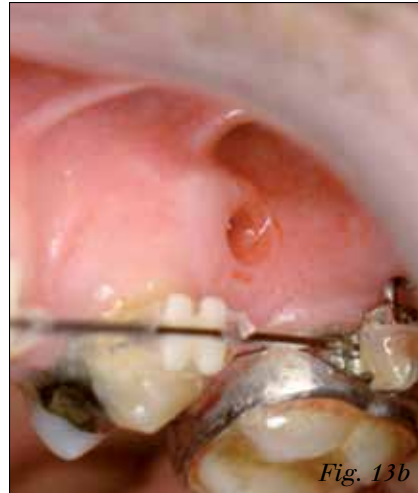

Fig. 13b

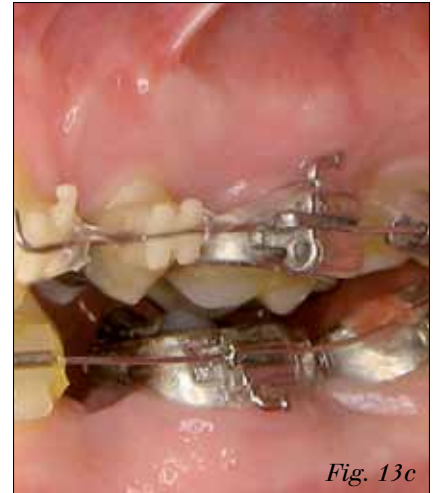

Fig. 13c

Figs. 13a–c: Miniscrew in place, after removal, and following a four-week healing period.

Accurate setting of the torque and the number of rotations is required; the rotation rate should not exceed 30 rpm<sup>-1</sup>, and the torque must be

restricted to the maximum load limit of the screw.

Machine insertion helps to achieve a consistent torque dur-

ing insertion but means that the operator loses perception of the bone. During manual insertion, it is possible to perceive the interaction between the screw and the bone by tactile senses. Insertion by machine is shown in figures 11a–f.

### Attaching the orthodontic linking elements

As no healing phase is required, load may be placed on the miniscrew immediately after insertion. The selected linking element must be prepared accordingly and attached to the head of the screw (Fig. 12). To avoid damage to the teeth to be moved, the load on the linking element should be between 0.5 and 2 N (about 50 and 200 g).

### Basic post-operative care

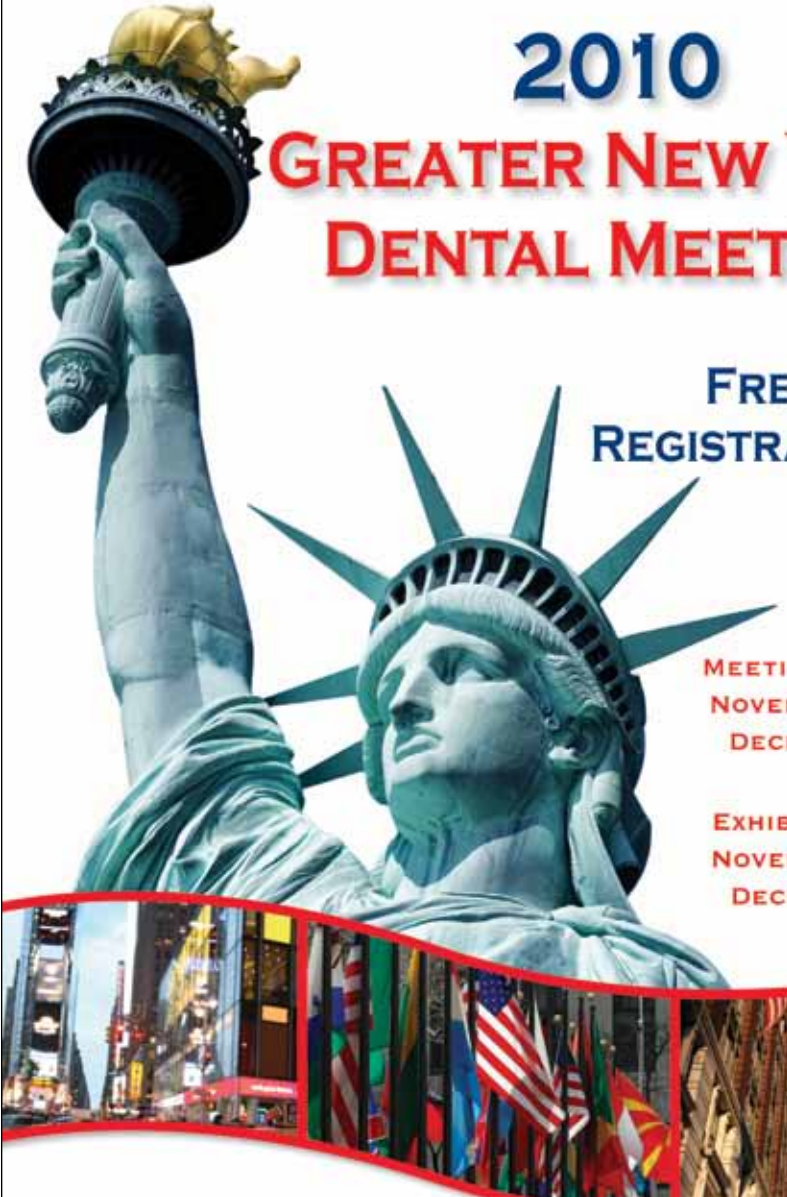
The healing of the gingival tissue and hygiene status after insertion must be regularly reviewed during the entire time the miniscrew remains in place. The patient must be informed that any manipulation of the screw head with the fingers, tongue, lips and/or cheeks should be avoided; otherwise the screw may be prematurely lost.

### Removal of the miniscrew

A miniscrew can be removed under local anesthetic. After the linking elements have been removed, the miniscrew may be removed with the same tools used for insertion. The resulting wound requires no special care and usually heals within a short time. □

*Editorial note: A complete list of references is available from the publisher. This article first appeared in Dental Tribune Asia Pacific, No. 3, 2009. The next edition of Ortho Tribune will feature "Part III — Clinical examples." All photos were provided by the authors.*

AD



## 2010 GREATER NEW YORK DENTAL MEETING

**FREE  
REGISTRATION\***

**MEETING DATES:  
NOVEMBER 26 -  
DECEMBER 1**

**EXHIBIT DATES:  
NOVEMBER 28 -  
DECEMBER 1**

86<sup>th</sup>  
Annual Session

The  
Largest  
Dental  
Convention/  
Exhibition/  
Congress  
in the  
United  
States

\*Free registration  
before November 26

Please send me more information about...

Attending the Greater New York Dental Meeting

Participating as a guest host and receiving free CE

I speak \_\_\_\_\_ and am willing to assist international guests  
enter language


Name \_\_\_\_\_


Address \_\_\_\_\_

City, State, Zip/Country Code \_\_\_\_\_

Telephone \_\_\_\_\_ E-mail \_\_\_\_\_

Fax or mail this to:  
Greater New York Dental Meeting or  
visit our website: [www.gnydm.com](http://www.gnydm.com) for more information.





For More Information:  
Greater New York Dental Meeting™  
570 Seventh Avenue - Suite 800  
New York, NY 10018 USA  
Tel: +1 (212) 398-6922  
Fax: +1 (212) 398-6934  
E-mail: [info@gnydm.com](mailto:info@gnydm.com)  
Website: [www.gnydm.com](http://www.gnydm.com)

### OT Contact

Dr Björn Ludwig  
Am Bahnhof 54  
56841 Traben-Trarbach  
Germany  
Phone: +49 (654) 181-8381  
Fax: +49 (654) 181-8394  
E-mail: [bludwig@kiefnerorthopaedie-mosel.de](mailto:bludwig@kiefnerorthopaedie-mosel.de)



# The new patient experience

By Roger P. Levin, DDS

Case presentation begins with the new patient phone call. Many ortho practices don't realize that.

When evaluating practice systems for new clients, Levin Group consultants are shocked at the number of potential patients/parents who call but never schedule. Every new patient phone call is another opportunity to provide exceptional orthodontic care, increase production and grow the practice.

How would you rate the telephone skills of your front desk team? Average, good or great? If you didn't answer "great," then you could be losing tens of thousands in potential production.

Most ortho practices score two out of 10 in this area but can raise their score to a nine in a matter of weeks with scripting and training.

## First impressions matter!

Get the patient-practice relationship off to a great start by giving your team the verbal skills they need to impress potential patients/parents.

In the age of increased ortho shopping, parents are scrutinizing ortho practices more than ever before. When your front desk team can build value for the orthodontist and the practice, patients/parents are more likely to schedule an appointment and accept recommended treatment.

If front desk staff members sound bored or rushed on the phone, they are sending a message that they have more important things to do. Remember, every new patient/parent who calls the office must be seen as a major opportunity.

Levin Group teaches clients that scripting needs to be in place for

every routine conversation, including the first phone call.

A successful new patient phone call requires scripts, power words, benefits statements and the following steps:

- Answering the phone within two rings
- Thanking the patient/parent for calling
- Asking who referred the patient
- Complimenting the referring individual
- Making the appointment
- Transferring trust by talking about the orthodontist's expertise
- Explaining the confirmation process

- Building value for orthodontic treatment
- Answering questions about aligners and other popular options
- Creating a positive feeling and relationship with the patient/parent
- Explaining tastefully why this is the ortho office of choice
- Restating the appointment date and time
- Asking if there are any other questions that the patient/parent may have

## Conclusion

The new patient call needs to be more of an interpersonal and infor-

mative experience than it is in most offices today. An effective first phone call sets the stage for a long-term practice-patient relationship that leads to increased growth, production and profitability.

*To jumpstart practice growth, experience Dr. Roger Levin's next Total Ortho Success™ Seminar being held June 17-18 in Las Vegas. Ortho Tribune readers are entitled to receive a 20 percent courtesy. To receive this courtesy, call (888) 973-0000 and mention "Ortho Tribune" or e-mail customerservice@levingroup.com with "Ortho Tribune Courtesy" in the subject line.* **OT**

AD

## OT About the author



Dr. Roger P. Levin is chairman and chief executive officer of Levin Group, the leading orthodontic practice management firm. Levin Group provides Total Ortho Success™, the premier comprehensive consulting solution for lifetime success to orthodontists in the United States and around the world. Levin Group may be reached at (888) 973-0000 and [customerservice@levingroup.com](mailto:customerservice@levingroup.com).

**aesthetics**  
Virtually invisible on the tooth

**strength**  
Three times greater fracture resistance than polycrystalline brackets\*

**safety**  
Debonds easily and safely with consistent and predictable bond strength

**confidence**  
Radiance offers patients seeking aesthetic orthodontic treatment a better choice. Made from clear, translucent sapphire. Radiance enhances the patient experience while ensuring bracket integrity and safety for the patient.

Fused alumina particles embedded at the center of each tooth's bonding pad are engineered to release from the tooth within a range that is both safe for the patient, yet secure enough to hold firmly to the tooth throughout treatment.

**radiance**  
... is confidence ...

**AO**  
AMERICAN  
ORTHODONTICS

USA and Canada: 1-800-558-7687 [www.americanortho.com](http://www.americanortho.com) \*Data on file