

# DENTAL TRIBUNE

The World's Dental Newspaper • Asia Pacific Edition



PUBLISHED IN HONG KONG

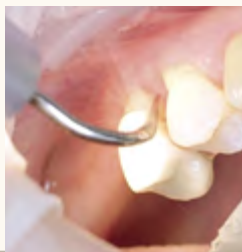www.dental-tribune.asia

VOL. 16, No. 12



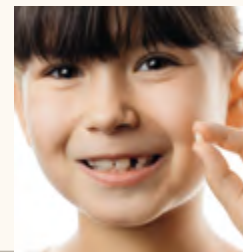## DENTAL FEE SURVEY

Annual dental fee survey conducted by the Australian Dental Association, summarizes the fees charged by its private practice members have remained relatively stable, with only a small increase. ▶ Page 04



## CLINICAL

No Implantology without Periodontology workflow should provide stable tissue prior to implantation through prevention. Patients will be pleased with the successful treatment. ▶ Page 06



## LOST OF FIRST TOOTH

Researchers from the University of Zurich have found that children mostly experience the loss of their primary tooth as something positive.

▶ Page 09

# CAD/CAM-integrated glass fibre post and core restoration improves tooth fracture strength

By DTI

**BEIJING, China:** Researchers from the General Hospital of the Air Force of the Chinese People's Liberation Army in Beijing recently evaluated the fracture resistance properties of maxillary incisors with flared root canals restored with CAD/CAM-integrated glass fibre posts and cores. The study found that this approach achieved improved results compared with conventional treatments.

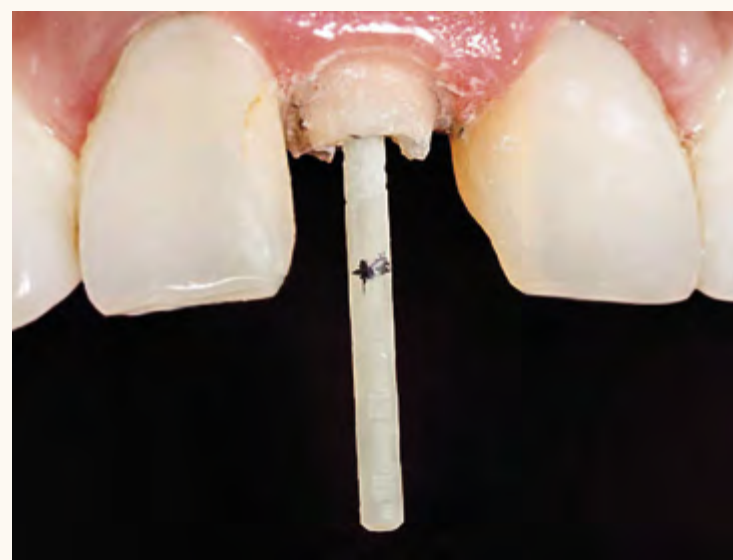The researchers treated 30 prepared flared root canals in vitro and restored these with CAD/CAM-integrated glass fibre posts and cores, prefabricated fibre posts and cast

gold alloy, respectively. After exposure to fatigue loading, each specimen was subjected to static loading until fracture.

The findings showed that the mean fracture strengths of the teeth treated with CAD/CAM-integrated glass fibre posts and cores, and cast gold alloy were significantly higher than those restored with prefabricated fibre posts, whereas no differences were observed between the first two treatments. In addition, repairable fracture modes were mostly observed in teeth treated with CAD/CAM-integrated glass fibre posts

and cores, while irreparable and catastrophic fractures were mainly found in the other teeth. These results demonstrate that, in comparison with conventional treatments, CAD/CAM-integrated glass fibre post and core restoration significantly enhances the fracture resistance of maxillary central incisors with flared root canals.

The study, titled "Fracture behaviors of maxillary central incisors with flared root canals restored with CAD/CAM integrated glass fiber post-and-core", was published online in *Dental Materials Journal* on 1 November 2018 ahead of inclusion in an issue.



A recent study found that placing a CAD/CAM-integrated glass fibre post and core decreases the risk of fracture of an endodontically treated and restored tooth. (Photograph: Lighthunter/Shutterstock)

# New standard to be developed for sterile reprocessing in dental practices

By DTI

**SYDNEY, Australia:** Among the issues arising for small dental practice owners is adhering to regulations that are more applicable to larger institutions such as hospitals. In what the Australian Dental Association (ADA) is calling a "significant advocacy win", Standards Australia has accepted a proposal to develop a new standard for sterile reprocessing of reusable medical devices and surgical instruments.

According to the ADA, it has lobbied for the past few years to

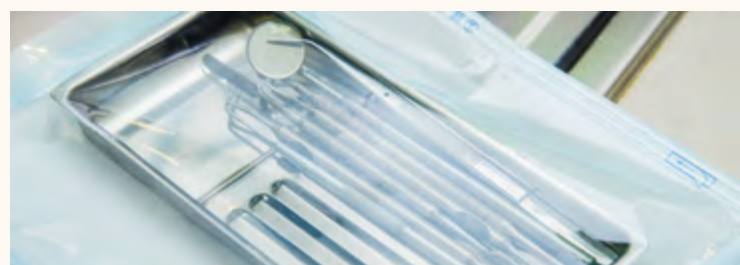prevent Australian and New Zealand Standard (AS/NZS) 4187 from becoming the required standard applicable to small office-based practices. The new standard that will now be developed over the next several years will replace both AS/NZS 4187 and AS/NZS 4815.

The decision follows a discussion on whether there was an ongoing need to maintain two different standards, given the confusion over which standard applied in which setting, or if it would be preferable to move

to a single document that would meet the needs of any situation where sterile reprocessing is required.

In response, newly elected ADA Federal President Dr Carmelo Bonanno praised the decision as an important positive step forward, noting that "AS/NZS 4187 is a standard more applicable to large health care organisations and would have placed unreasonable demands on dental practices which would have resulted in increased costs for patients".

It is envisaged that the single standard will be supported by a set of complementary implementation guides that will explain the application of the standard to particular settings. Throughout the development of the new standard, the ADA will remain closely involved and eventually align its own infection control guidelines to it once ready; however, until then the existing standards remain in place.



The ADA has hailed Standards Australia's decision to implement a new standard for sterile reprocessing in dental practices as a positive step forward. (Photograph: Okrasyuk/Shutterstock)

AD



## Distinguished by innovation

Healthy teeth produce a radiant smile. We strive to achieve this goal on a daily basis. It inspires us to search for innovative, economic and esthetic solutions for direct filling procedures and the fabrication of indirect, fixed or removable restorations, so that you have quality products at your disposal to help people regain a beautiful smile.

www.ivoclarvivadent.com

Ivoclar Vivadent AG  
Benderstr. 2 | FL-9494 Schaan | Liechtenstein | Tel.: +423 / 235 35 35 | Fax: +423 / 235 33 60

ivoclar  
vivadent  
passion vision innovation

# Combination of breast milk and babies' saliva shapes healthy oral microbiome, study suggests

By DTI

**BRISBANE, Australia:** There is much debate of the pros and cons of breast- and bottle-feeding. A research team

from the Queensland University of Technology (QUT), in collaboration with the University of Queensland,

both in Australia, has found that breastfeeding, at least in terms of oral health of the baby, is beneficial.

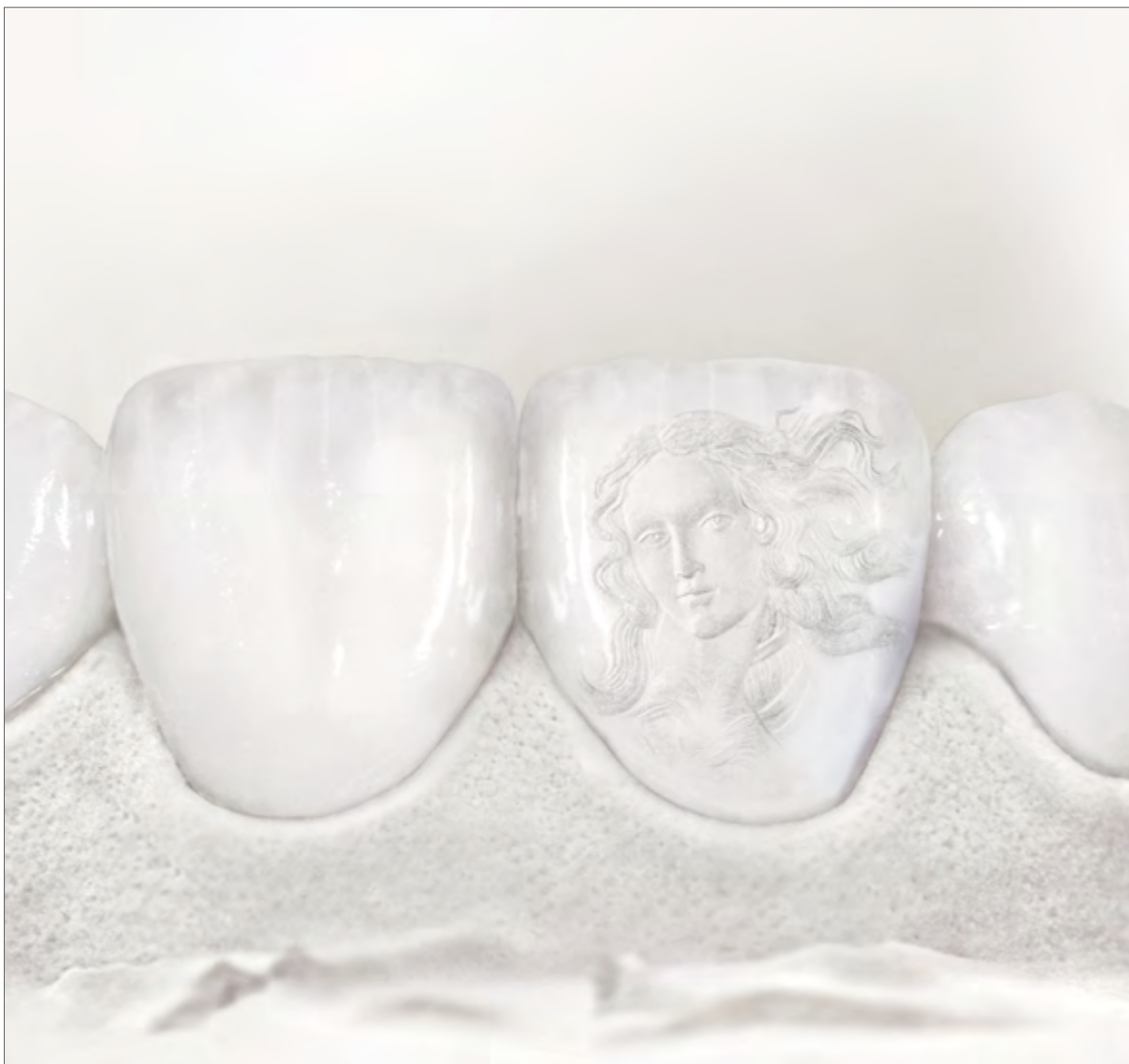According to lead author Dr Emma Sweeney, from the Institute of Health and Biomedical Innova-

tion at QUT, the team's earlier studies had found significant differences in the prevalence of key bacteria in the mouths of breastfed and formula-fed babies and that breastmilk and saliva interactions boost innate immunity by acting in synergy to regulate the oral microbiome of newborn babies.

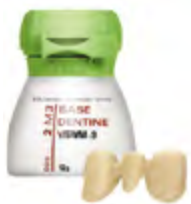AD

## The fast way to esthetic perfection.

The natural fine-structure feldspar veneering ceramic for zirconia frameworks.



3519E



**VITAVM®9**

- Excellent light dynamics and optimum physical properties thanks to the fine-structure ceramic
- Excellent modeling characteristics for fast and accurate application of the ceramic
- Process reliability thanks to long-standing experience

www.vita-zahnfabrik.com  facebook.com/vita.zahnfabrik

VITA – perfect match.

**VITA**



A recent study conducted by the Queensland University of Technology demonstrated that breastfeeding improves the oral immune system of newborns. (Photograph: wong sze yuen/Shutterstock)

For the recent study, a variety of microorganisms were exposed to breastmilk and saliva mixtures. The results showed that inhibited growth of the microorganisms took place immediately and for up to one day regardless of whether the microorganisms were considered pathogenic or commensal in an infant's mouth.

“Our findings suggest that breastmilk is more than a simple source of nutrition for babies because it plays an important role in shaping a healthy oral microbiome,” said Sweeney. “Our previous research found that the interaction of neonatal saliva and breast milk releases antibacterial compounds, including hydrogen peroxide. The release of this chemical compound also activates the lactoperoxidase system, which produces additional compounds that also have antibacterial activity, and these compounds are capable of regulating the growth of microorganisms,” she added.

According to the research team, the composition of a baby's mouth microbiota has an important role in its health and well-being and also has an impact on infections and diseases in babies' early lives.

The study, titled “The effect of breastmilk and saliva combinations on the *in vitro* growth of oral pathogenic and commensal microorganisms”, was published online in *Scientific Reports* on 11 October 2018.



# University of Otago receives NZ\$10 million to aid construction of new dental clinic

By DTI

**DUNEDIN, New Zealand:** As reported by Dental Tribune in September, the University of Otago announced that it would be building a dental teaching facility and patient treatment clinic in South Auckland. In a positive new development, internationally renowned businessman and philanthropist, Graeme Hart and his wife Robyn have announced that they will be donating NZ\$10 million towards the clinic's construction.



Businessman Graeme Hart and his wife Robyn have donated NZ\$10 million to the University of Otago towards the construction of a new dental clinic in South Auckland. (Photograph: Cozine/Shutterstock)

The University of Otago Foundation Trust Chair John Ward said, "this funding will make a significant contribution to the development of a new dental teaching facility, which will not only provide students with diverse practical learning opportunities, but will also provide dental care for the local diverse communities at a highly accessible cost."

The NZ\$28.2 million, two-storey, 32-chair building will be built at the Counties Manukau District Health Board's Super Clinic's site. With 48 final-year dentistry students assigned to the South Auckland clinic at any one time, the clinic will follow the long-standing social contract model that operates successfully in Dunedin, whereby patients receive treatment provided by students under supervision at a very accessible cost.

Hart, who lives in Auckland, was awarded an honorary Doctor of Commerce degree by the university last December in recognition of his contribution to the business sector and for his philanthropy in supporting education and children's health. "We are delighted to be able to assist our university in providing a dental school that will meet the needs of lower socio-economic groups. We are very pleased that the youth and young children of this region will benefit from this facility," Hart commented.

"The University of Otago remains highly committed to providing outstanding education and to contributing to the communities where our campuses are located. The Hart family's donation will allow us to proceed with certainty

on the development of our dental teaching facility in the Counties Manukau region and it will assist

us in making a substantial positive difference to the healthcare and wider wellbeing of residents of New

Zealand's largest city," said University of Otago Vice-Chancellor Harlene Hayne.

The donation is the most significant single donation in the University's near 150-year existence.

AD

## Tetric® N-Line

High-quality composites for esthetic anterior and posterior restorations



One efficient solution  
**for all**  
cavity classes

\* Based on sales figures.

MORE THAN  
**90** MIO  
RESTORATIONS PLACED\*

[www.ivoclarvivadent.com](http://www.ivoclarvivadent.com)

Ivoclar Vivadent AG  
Bendererstr. 2 | 9494 Schaan | Liechtenstein | Tel. +423 235 35 35 | Fax +423 235 33 60

**ivoclar**  
**vivadent**  
passion vision innovation

# Survey of Australian dentists' fees indicates a small increase

By DTI

**SYDNEY, Australia:** Each year, the Australian Dental Association (ADA) conducts a dental fee survey to gain a better understanding of how private practices across the country are billing for their work. According to this year's results, pricing has remained relatively stable, with only a small increase. However, as seen in previous surveys, there were significant variations in the different levels of fees that are charged, both within and between different states.

The survey, conducted by ACA Research, summarises the fees charged by ADA members in private practice as at 1 July 2018. According to the ADA, there were 303 more practitioners who took part this year than last year, with a total of 1,740 valid responses received. The total participants were broken down into 1,454 general practitioners (GPs) and 286 specialist dentists.

The fees charged by GPs remained relatively stable from 1 July 2017 to 30 June 2018 across the 121 items that were surveyed. However, there has been a continuous upward trend over the past five years. In line with the Consumer Price Index, the accumulative year-on-year increase in fees over the previous five years is eight per cent. Additionally, the changes in fees charged by GPs varied across all different service categories, with the highest increase in GP fees was noted for general dental services (1.6 per cent). Periodontics saw a decrease of 4.5 per cent; whereas preventive services and oral surgery went down 0.4 per cent and 0.3 per cent, respectively.

As with previous years' surveys, less than a quarter of GPs reported



The annual survey by the Australian Dental Association to summarise fees charged by its private practice members has indicated that fees have increased slightly. (Photograph: MIND AND I/Shutterstock)

charging an hourly rate for their services. For the 23 per cent who do, the average rate billed was A\$469 an hour, which is a four per cent increase from the previous A\$449 an hour that was reported in 2017. On average, GPs in Western Australia charged the lowest fees, while GPs in Australia Capital Territory (ACT) and Tasmania charged the highest.

The ADA did however warn that due to the small sample sizes in the ACT and Tasmania, these results should be regarded with caution. On average, GPs in Victoria charged the highest mean hourly rate of A\$524, while their counterparts in South Australia charged the lowest mean hourly rate of A\$360. Generally, GPs in the state capitals charged a higher

fee for the same item of service than GPs in the rest of the state.

Approximately 11 per cent of private practice dentists in Australia are specialists. From the 286 specialists surveyed in this year's survey, 29 per cent charged an average hourly rate of A\$632, which increased from A\$539 in the 2017

survey. Specialists in New South Wales charged the highest average hourly rate of A\$684, while specialists in South Australia charged the lowest rate of A\$400. However, these results should be also be regarded with caution, due to the relatively small number of specialists included in the survey results, according to the ADA.

AD



**AEEDC 2019**  
05.- 07. 02. 2019  
Dubai/ UAE  
Booth: 7F17

## PROMEDICA

Highest quality made in Germany





**Self-curing calcium hydroxide paste**

- For indirect pulp capping and linings under dental filling materials
- Sufficient working time in combination with a short setting time in the mouth
- Bacteriostatic
- Antimicrobial effect due to a high pH-value
- Contains 26% calcium hydroxide
- Preservation of vitality due to pulp recovering





**Glass ionomer luting cement**

- High level of adhesion
- Highly biocompatible, low acidity
- Continuous fluoride release
- Precision due to micro- fine film thickness
- Translucency for an aesthetic result

Visit [www.promedica.de](http://www.promedica.de) to see all our products

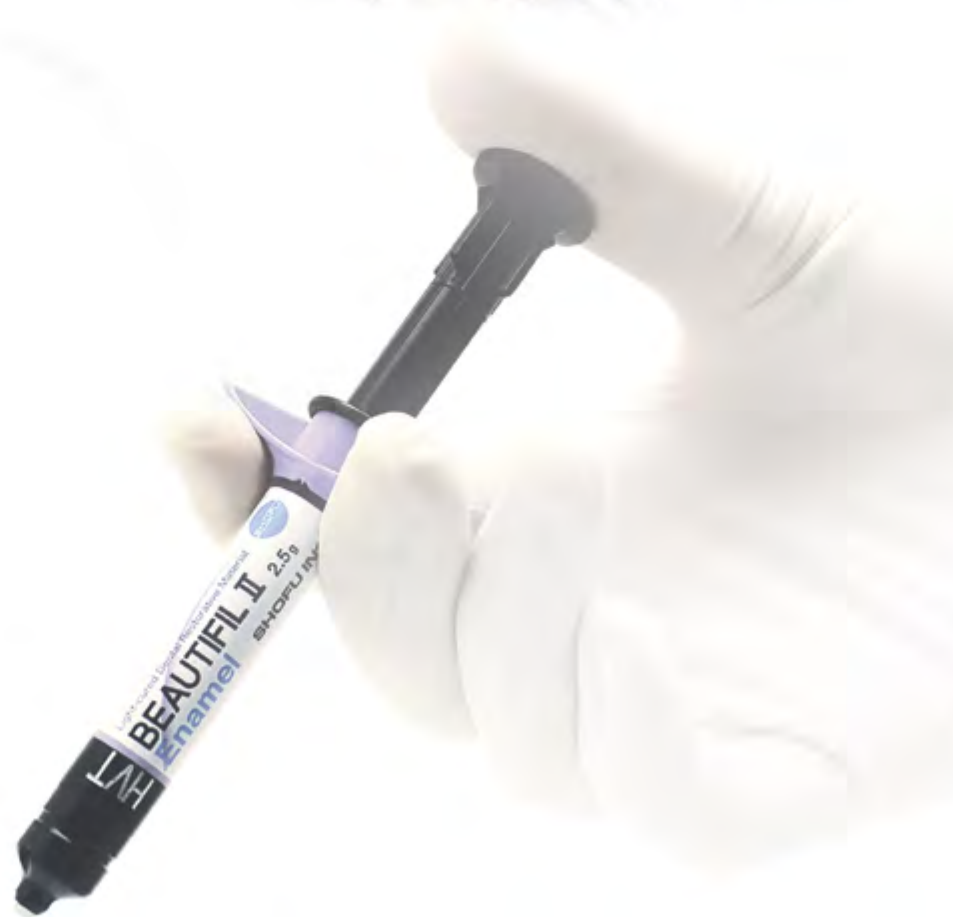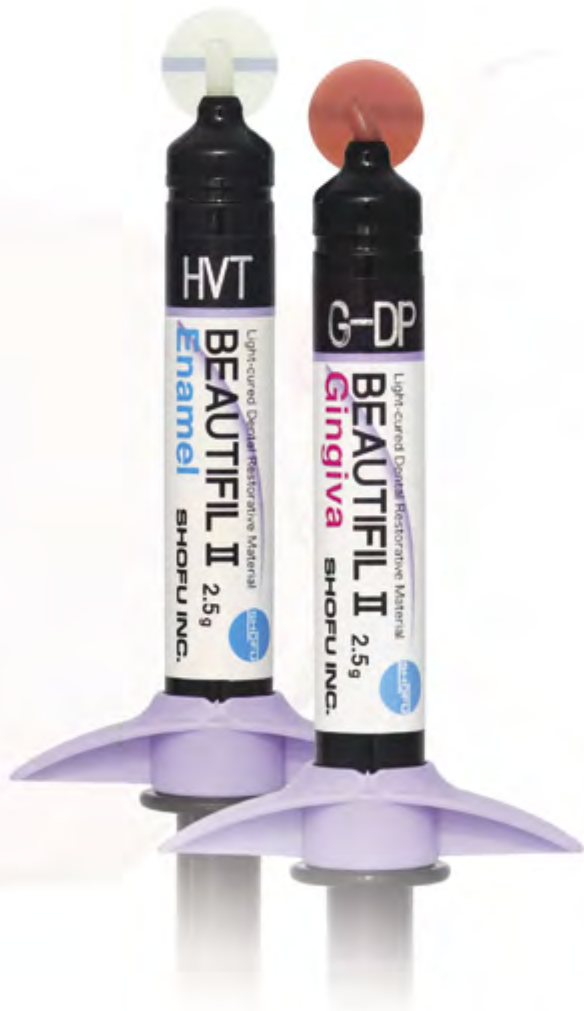**PROMEDICA**

**Dental Material GmbH**  
24537 Neumünster / Germany  
Tel. +49 43 21 / 5 41 73  
Fax +49 43 21 / 5 19 08  
eMail [info@promedica.de](mailto:info@promedica.de)  
Internet [www.promedica.de](http://www.promedica.de)



# PINK and WHITE Aesthetics

Smart Solutions for  
**Challenging  
Restorations**



For more information, simply contact your nearest **Shofu Dealer Today!**



**SHOFU DENTAL ASIA-PACIFIC PTE. LTD.**  
[www.shofu.com.sg](http://www.shofu.com.sg)

Official Partner



Minimally Invasive  
Cosmetic Dentistry



# Implants should only be inserted when periodontal conditions are stable

By Dr Jan H. Koch, Germany

**Biofilm is the most significant cause of inflammatory bone loss around teeth and implants. Diagnostics, biofilm management and, where necessary, treatment help in patients with this problem. The W&H No Implantology without Periodontology workflow should provide stable tissue prior to implantation through prevention, and implant success in the long term through aftercare – something that is advantageous to both the patient and the treatment team.**

Implant treatment can significantly improve quality of life after tooth loss.<sup>1,2</sup> The long-term prognosis is generally good, but biological complications are common.<sup>3</sup> Peri-implantitis and its preliminary stage, mucositis, occur in a substantial proportion of patients.<sup>4</sup> As is the case for periodontitis and gingivitis, oral biofilm is the main cause.<sup>5,6</sup> This microbial biocoenosis can also encourage the development of severe systemic disease in the event of pathological changes, such as endocarditis and inflammatory bowel disease.<sup>7</sup>

The only difference in the microbial flora in periodontitis and peri-implantitis is in the detail.<sup>8</sup> Compared with healthy conditions, the quantity and aggressiveness of the pathogenic microorganisms change in both diseases.<sup>5,6</sup> Bone loss around implants is generally more rapid and leads to more extensive defects than when it occurs around teeth.<sup>9</sup> Accordingly, preventative care is advised even before implant treatment.

## Determining risks and providing periodontal treatment

Periodontitis is a key risk factor for peri-implant inflammation.

This means untreated periodontitis patients have an increased risk of peri-implant inflammation through to implant loss.<sup>10</sup> The risk is also higher when patients who are initially treated are not included in a supportive periodontitis treatment/recall programme.<sup>11</sup>

Leading periodontists therefore recommend carrying out a screening procedure before implant treatment using, for example, the periodontal screening index or periodontal screening and recording.<sup>12</sup> Bleeding on probing and pocket depths are determined at selected positions. An extensive check of the periodontal status should be carried out if the results are abnormal.<sup>13</sup>

Taking a careful medical history, including previous systemic exposure, is also important.<sup>13</sup> This provides important information about increased risk of inflammation, for example in patients with diabetes that is not being optimally managed.<sup>14</sup> Furthermore, patients should be informed of the risks relating to implants.

Where necessary, initial periodontal treatment is carried out. First, professional tooth cleaning establishes healthy gingival conditions. In this procedure, calculus (Fig. 1) and biofilm (Fig. 2) are removed as far as the gingival sulcus. In combination with careful instruction on oral hygiene, this gives the patient the basis for long-term freedom from inflammation.<sup>15</sup>

Removal of subgingival coatings (debridement) is carried out using sonic or ultrasonic devices and special periodontal tips as ini-

tial periodontal treatment (Fig. 3). Manual instruments can also be used. Further surgical and/or regenerative measures may be necessary, depending on the situation.

## Periodontal aftercare for long-term success

In the periodontal aftercare subsequent to implantation, soft (biofilm) and hard coatings are regularly professionally and mechanically removed.<sup>16,17</sup> In the subgingival and supragingival areas, ultrasonic devices are generally used for this (Fig. 4), in combination with manual instruments where necessary. Alternatively, subgingival air polishing can be used in combination with periodontal attachments and powders.<sup>18</sup>

Checking for individual risk factors, such as smoking and diabetes, and working towards a healthy lifestyle are also recommended for a good long-term prognosis after periodontitis treatment.<sup>13,19</sup> If the patient had severe periodontitis before the initial treatment, the recall frequency will be increased accordingly, partially to prevent peri-implant inflammation.<sup>20</sup>

## Proactive implant treatment

If the patient has received good preventative treatment and where necessary has received preliminary periodontal treatment, implant treatment can be planned. A suboptimal implant-supported prosthesis increases the likelihood of biofilm forming.<sup>21</sup> In order to avoid this, the correct implant position, sufficient distances from adjacent teeth and an ideal axial alignment should be considered during the planning phase. A sufficiently sized bone site and soft

tissue that is well supplied with blood are needed for successful implant healing and a good long-term prognosis. Prior or simultaneous augmentation may be needed to achieve this. In contrast to this, the time at which the implant is inserted and the treatment is provided plays a less significant role.<sup>22,23</sup>

In order to support predictable and stable implant treatment, it is also necessary to prepare the implant bed using suitable methods and equipment. This can be achieved using high-performance implantology motors in combination with surgical contra-angle handpieces. Using a low speed and an ample supply of sterile cooling fluid is essential during preparation.<sup>24</sup> Otherwise, the bone can overheat and affect the healing process.

Alternatively, the implant bed can be prepared with piezo-surgical systems, for which special sets of instruments are available.<sup>25</sup> Bone can be worked on in a gentle yet highly effective manner using other special instruments. Indications include alveolar ridge splitting, surgical tooth removal, and the preparation of bone blocks or lateral windows for augmentation.<sup>26</sup> Highly advanced piezo-surgical devices are also minimally invasive in soft tissue.

## Stability measurement and bone surgery

Once the implant has been screwed into its final position, the primary stability can be safely and precisely determined using resonance frequency analysis. The technology is available either separately or as an optional module in an implantology motor. If the ISQ (Im-

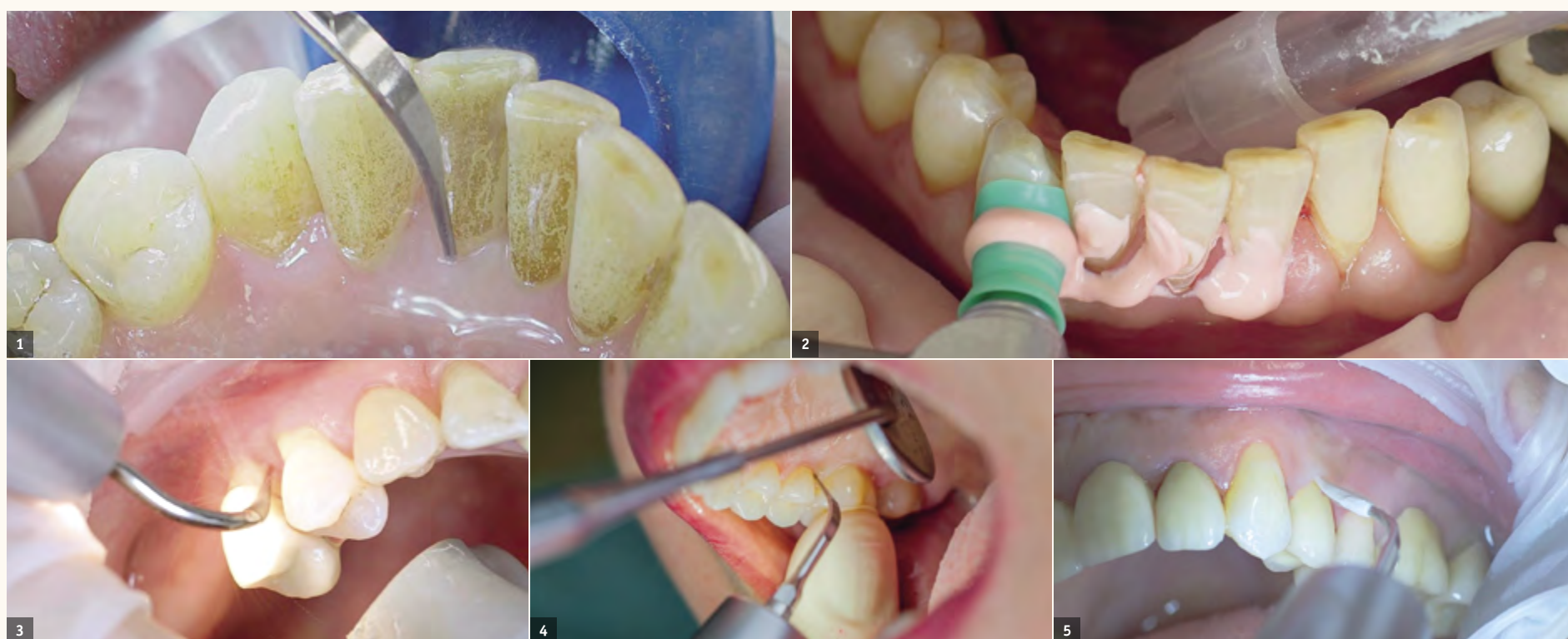plant Stability Quotient) value measured is 66 or higher, early intervention is possible, and if it is over 70, treatment must be provided immediately.<sup>27</sup>

An exposure protocol based on the ISQ value improves the prognosis of treatment. Simply measuring the torque resistance, however, does not provide the same level of clinical safety.<sup>28</sup> If reduced ISQ values are measured after the implant has been inserted, a two-phase protocol is generally chosen. After exposure, a new measurement can then be used to determine whether osseointegration has been successful (secondary stability) and loading will be predictable at this point.<sup>29</sup>

## Hygiene-friendly prostheses

The emergence region should be designed to ensure that it is atraumatic to the tissue for long-lasting implant restorations. The implant-abutment connection, material, surface and emergence profile must be biocompatible and mechanically resilient over the long term. The transgingival components should also be accessible for individual and professional cleaning and for probing.<sup>30</sup>

Definitively integrating abutments or other components at implant level immediately ("one abutment, one time") has also proved to be effective.<sup>30</sup> In combination with good hygiene and correspondingly healthy tissue, this concept can probably be used to achieve a more stable attachment of the implant to the oral cavity than if the components have to be replaced several times - a requirement for peri-implant health.



**Fig. 1:** Calculus removal using an ultrasound (W&H Tigon (+) with a 3U tip) is a key part of professional tooth cleaning. (Photograph: W&H) **Fig. 2:** Rotary cleaning with prophylaxis polishing cups and brushes (W&H Proxeo prophylaxis contra-angle handpiece) ensures smooth surfaces on teeth. It enables patients to check biofilm effectively at home. (Photograph: W&H) **Fig. 3:** If marginal periodontitis is diagnosed, the initial debridement can be carried out very efficiently with an air scaler (sonar technology, W&H Proxeo with 1AP tip). (Photograph: W&H) **Fig. 4:** Ultrasound devices are particularly suitable for UPT, for example in combination with periodontal tips (W&H Tigon (+) with 1P tip). (Photograph: W&H) **Fig. 5:** Implants and suprastructures are routinely cleaned, for example using ultrasound devices and special plastic instruments (W&H Tigon (+) with 1I tip). (Photograph: W&H)

Whether it is with crowns, bridges, partial or complete prostheses, the implant-supported superstructure should be designed so that the patient can maintain it without any difficulty.<sup>20</sup> Additionally, a distance of at least 2 mm between the bone and the mucosal edge of the prosthesis appears to be advised to prevent infection and subsequent bone loss.<sup>31</sup>

#### Peri-implant aftercare

Experts recommend treatment immediately after the initial occurrence of symptoms of inflammation to avoid peri-implant bone loss from the start.<sup>20</sup> Mucositis affects almost half of all implants, and since patients often have several implants, it occurs in a high percentage of patients.<sup>32</sup> The prophylactic or periodontal recall programme established after the implant has been inserted should therefore be continued.<sup>20,33</sup> At-home oral hygiene should be carefully tailored to the new prosthesis and the patient accordingly instructed on this.<sup>34</sup> In combination with professional biofilm management, good preventative efficacy can be achieved in this way.<sup>35</sup>

The risk of peri-implantitis decreases from 43.9 per cent (no recall) to 18.0 per cent if a patient receives a recall appointment carried out carefully each year, in other words by more than half.<sup>36</sup> Ultrasonic systems with special instruments that do not affect the materials are suitable for this, such as those made of PEEK (Fig. 5), or appropriate manual instruments.<sup>37</sup>

#### Mechanically preventing mucositis

As for periodontitis patients, peri-implant recall includes regular screening with a clinical check of both periodontal and peri-implant tissue for symptoms of inflammation, probing and, where necessary, radiographic diagnosis.<sup>9</sup> A frequency of two to four times a year has proved to be effective.<sup>17</sup> Deep probing values and bleeding occur more commonly in patients with peri-implantitis than in those with mucositis; pus secretion only occurs in patients with peri-implantitis.<sup>38</sup>

If a patient has mucositis, professional supragingival and subgingival biofilm removal reduce the risk of the inflammation advancing to peri-implantitis. Local and systemic antibiotics used as supportive measures or air polishing, however, show no additional benefit.<sup>20,39</sup>

#### Treating peri-implantitis

Peri-implant bone loss can develop even if good preventative care is provided, for example if the patient's oral hygiene is not sufficient. Most minimal defects should be treated in a non-surgical manner using peri-implant debridement.<sup>37</sup> Mechanical removal of coatings using suitable ultrasonic systems, supported by Er:YAG lasers, antibacterial photodynamic treatment, air polishing, or treatment with local or systemic antibiotics, where appropriate, has shown promising results.<sup>37</sup>

If closed treatment is no longer possible, the defect must be surgically exposed and carefully decontaminated. This is carried out after flap preparation by removing in-

flamed tissue and cleaning the surface of the implant using, for example, ultrasonic or piezo-surgical systems. Measures designed to regenerate the bone carried out after this procedure have been successful.<sup>40</sup> Special piezosurgical instruments are available for the surgical treatment of periodontal defects.

After treatment, the patient is once again intensively instructed on oral hygiene and made aware of the need for continual recall. If necessary, the frequency can be

selected to be higher than previously in line with periodontal aftercare. If biofilm management is carried out consistently, the implantological results can remain stable for several years even after the periodontitis, mucositis or peri-implantitis has healed.<sup>33,39</sup>

#### No Implantology without Periodontology

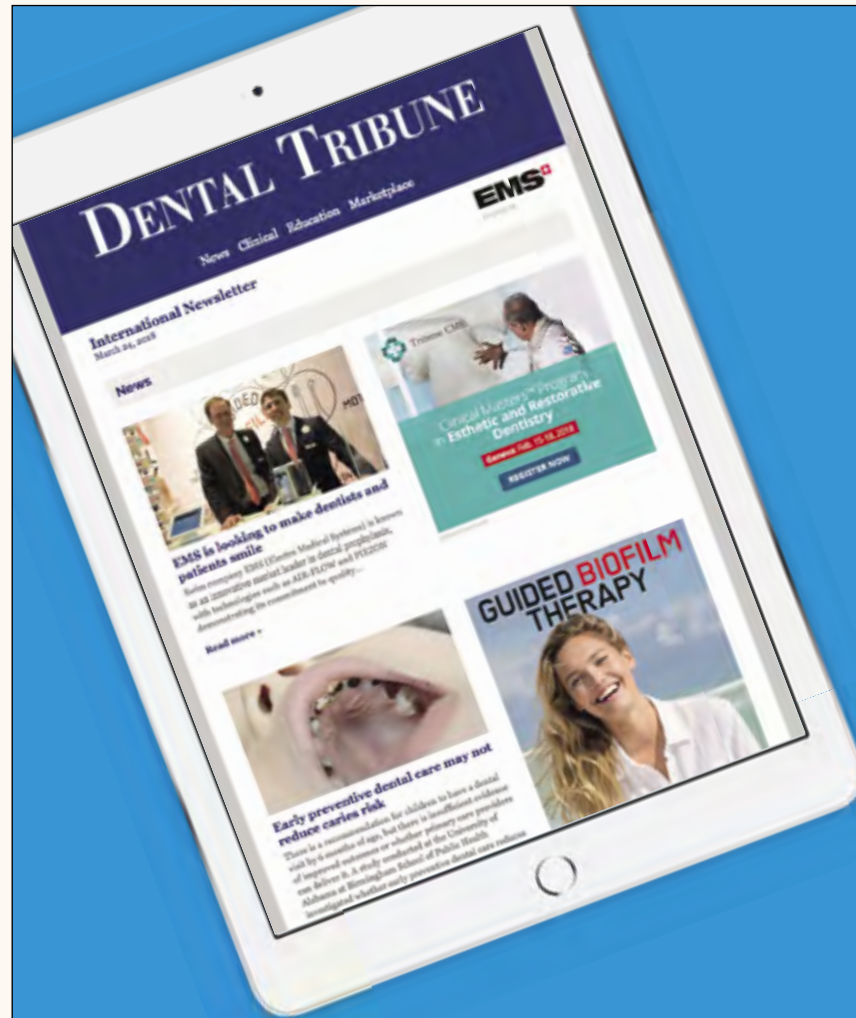Successful implant treatment requires consistent, long-term preventative thinking. In each phase, this includes regular periodontal

and peri-implant screening in combination with individually tailored risk management, oral hygiene training and professional biofilm management where possible for every patient.

Ideally, this preventative workflow should start well before each restorative measure, before periodontitis can develop. It is essential if implant prosthetic treatment is planned or has already been integrated. Patients will be pleased with the long-term success of the treat-

ment and will be pleased to return to a practice or clinic they trust.

**Editorial note:** A list of references and information is available from the publisher by scanning this QR code using your mobile phone. More information can be found at [niwop.wh.com](http://niwop.wh.com).



- regular e-news delivered to your inbox
- individualized content according to your specialty & region
- latest industry developments
- event specials
- exclusive interviews with key opinion leaders
- product information
- clinical cases
- job adverts

# Sign up to the finest e-read in dentistry

[www.dental-tribune.com](http://www.dental-tribune.com)

**dti** Dental  
Tribune  
International

AD



# BDA warns against restricting dental visits to once every two years

By Dental Tribune UK

**STIRLING, UK:** A recent survey conducted by the British Dental Association (BDA) has found that a

Scottish government initiative to potentially extend the time between dental appointments to 24

months has caused concern among Scottish dentists regarding possible delayed diagnosis of oral cancer.

Earlier this year, the Scottish government launched the Oral Health Improvement Plan, which

AD

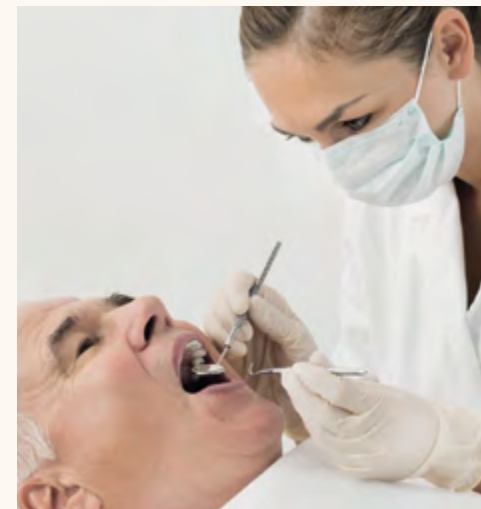


**CROIXTURE**

PROFESSIONAL MEDICAL COUTURE

**NEW COLLECTION**

EXPERIENCE OUR ENTIRE COLLECTION AT [WWW.CROIXTURE.COM](http://WWW.CROIXTURE.COM)



*BDA Scotland has cautioned against attending dental check-ups only once every two years, as it may negatively impact the ability of dentists to detect oral cancers at an early stage. (Photograph: Andrey\_Popov/Shutterstock)*

outlines, among other things, a focus on improving prevention, reducing oral health inequalities, and meeting the needs of an ageing population. Though the BDA welcomed these ambitions, it expressed dismay that the plan recommends that certain patients with good oral health should only attend dental check-ups once every two years. A subsequent BDA survey of Scottish dentists found that 97 per cent of respondents are concerned that these extensions of recall intervals could undermine the detection of oral cancers, which 77 per cent regarded as a major or severe risk.

Scotland has seen a 37 per cent increase in oral cancer deaths over the past decade, and incidence rates are among the highest in Europe. Though it is primarily caused by smoking, excessive alcohol consumption and human papillomavirus infections, oral cancer can also occur in individuals leading generally healthy lifestyles. Given that survival rates for oral cancer improve from 50 per cent to 90 per cent with early detection, regular check-ups are essential.

Dr David Cross, Vice Chair of the BDA's Scottish Council, said: "Dentists are on the front line of a battle against some of the fastest rising cancers in Scotland. Early detection is key, but now risks becoming a casualty of a cost-cutting exercise."

"People in otherwise good health are succumbing to this disease. Telling our 'lower risk' patients to come back in two years will only handicap efforts to meet a growing threat, while putting further pressure on NHS cancer services," he continued.

"Oral cancer now claims three times as many lives in Scotland as car accidents. Rather than chasing quick savings we need to see concrete plans and real investment to help turn the tables on this devastating but preventable disease," Cross advised.

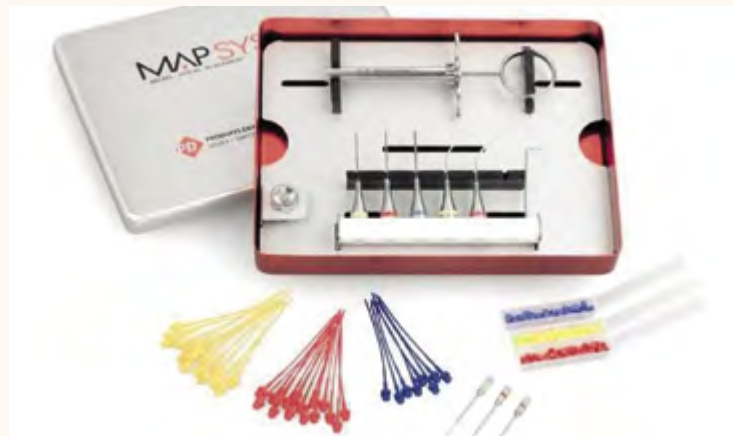

# The MAP System: A versatile tool for endodontic therapy

By DTI

**PARIS, France:** According to Produits Dentaires, its MAP (Micro-Apical Placement) System, provides a unique and efficient method for precisely placing endodontic filling materials by orthograde or retrograde approaches. At the ADF 2018 congress, the company is showcasing the professional system, considered the product of choice for perforation, root-end filling, pulp capping and retro-obturation therapies, Produits Dentaires said.

The MAP System is available in three kits (Intro, Universal and Surgical), which each contain a Swiss-quality stainless-steel sy-



The MAP System provides a unique and efficient method for placing root canal repair materials in orthograde or retrograde obturation. (Photograph: Produits Dentaires)

ringe with a bayonet catch designed for a large range of exchangeable application needles. The respective kits also contain the relevant needles, reusable medical-grade polyoxymethylene plungers, NiTi cleaning curettes for removing material residue inside the needles.

The Classic single-angle needles are designed for precise non-surgical endodontic procedures, while the Surgery triple-angle needles are optimal for surgical endodontic procedures. The NiTi Memory Shape needles can be manually shaped to any required curvature and adjust easily to the shape of the root canal for effective placement of repair

materials. Because the NiTi Memory Shape needles are versatile, they are ideal for orthograde and retrograde therapies.

In combination with PD MTA White, the company's exclusive mineral trioxide aggregate cement developed for placement with the MAP System, dental professionals can achieve durable and predictable outcomes for their patients, Produits Dentaires said.

For more information about Produits Dentaires's products, dental professionals are invited to visit the company's booth (#1S12) at ADF or visit [www.pdsa.ch](http://www.pdsa.ch).

# Majority of children perceive loss of first tooth positively

By DTI

**ZURICH, Switzerland:** Although losing primary teeth can be unsettling and painful for children, an interdisciplinary research group at the University of Zurich (UZH) has now found that children's feelings towards this experience are predominantly positive. The study also established that previous visits to the dentist, as well as parental background and level of education, affect how children experience the loss of their first tooth.

Children generally lose their first primary tooth when they are about 6 years old. This gradual process is probably one of the first biological changes to their own bodies that children experience consciously. The emotions that accompany this milestone are extremely varied, ranging from joy at having finally joined the world of grown-ups to fear about the loss of a body part.

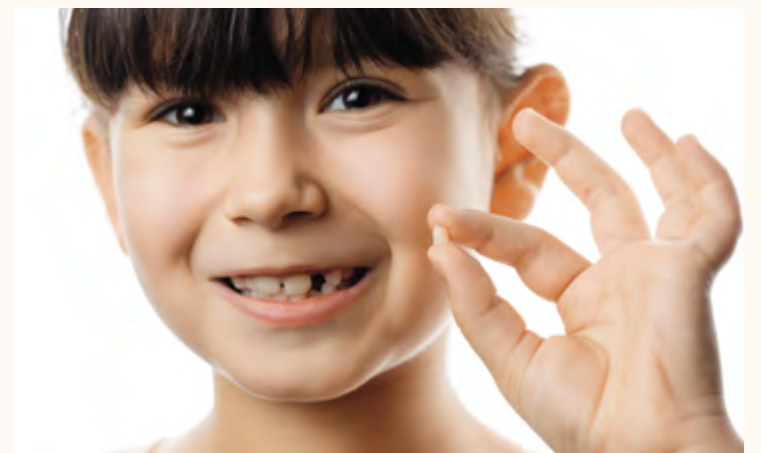An interdisciplinary team of researchers at UZH, in cooperation

with the City of Zurich's school dental services, has examined the feelings that children experience when they lose their first primary tooth and what factors play a role. The scientists surveyed parents of children who had already lost at least one of their primary teeth. Of the nearly 1,300 responses received, around 80 per cent of parents reported positive feelings, while only 20 per cent told of negative emotions.

The researchers found that previous visits to the dentist played a role regarding children's feelings. Those whose previous visits were cavity-related and thus perhaps associated with shame or guilt experienced fewer positive emotions when they lost their first primary tooth. If, however, previous dental appointments were the result of an accident, and thus an abrupt, unexpected and painful event, the loss of the first primary tooth was more likely to be associated with positive emotions. According to

lead author Dr Raphael Patcas, from the Clinic of Orthodontics and Pediatric Dentistry, one possible explanation for this is that primary teeth loosen gradually before falling out—a process that, unlike an accident, unfolds slowly and predictably. This is also supported by the finding that children who experience the loosening of a tooth over an extended period tend to have more positive feelings. The longer the preparation and waiting time, the greater the relief and pride when the tooth finally falls out.

Moreover, the study found that socio-demographic factors are related to children's feelings. For example, children were more likely to have positive feelings such as pride or joy if their parents had a higher level of education and came from non-Western countries. The researchers indicate that cultural differences could be at play here. These include education style and norms that parents pass on to their chil-



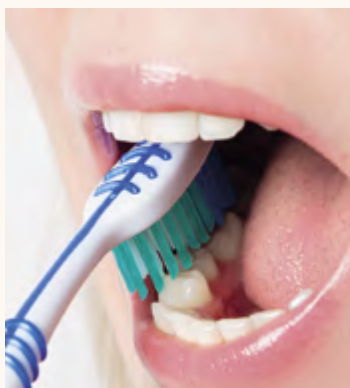Researchers from the University of Zurich have found that children mostly experience the loss of their first primary tooth as something positive. (Photograph: Alexxndr/Shutterstock)

dren, as well as transitioning rituals that accompany the loss of the first baby tooth.

"Our findings suggest that children deliberately process previous experiences concerning their teeth and integrate them in their emotional development," said study co-author Prof. Moritz Daum, from the institute of developmental psychology at the university. This finding is important for dentists and parents alike: "Especially where

cavities are concerned, it's worth communicating with children prudently," added Daum. "This way, emotions in connection with teeth and dentists can be put on the most positive trajectory possible."

The study, titled "Emotions experienced during the shedding of the first primary tooth", was published online on 15 September 2018 in the International Journal of Paediatric Dentistry ahead of inclusion in an issue.



New research suggests that brushing one's teeth less than twice a day for less than 2 minutes at a time may lead to a threefold increase in risk of developing cardiovascular disease. (Photograph: Aleksandr Lupin/Shutterstock)

# New study links poor tooth-brushing habits to heart disease

**CHICAGO, US/LONDON, UK:** A new study presented during the 2018 American Heart Association Scientific Sessions held recently has suggested that brushing one's teeth at least twice a day for at least 2 minutes may reduce one's risk of developing cardiovascular disease.

In response, the Oral Health

Foundation, a leading charity working to combat oral disease in the UK, stressed the importance of taking charge of one's oral health, stating that it can provide benefits that go far beyond the mouth.

"Findings like this may sound slightly scary to hear but it could prove to be just the push we need

to take better care of our oral health," said Dr Nigel Carter, OBE, CEO of the Oral Health Foundation. "This study adds to the growing scientific evidence that this is a strong link between the health of our mouth and that of our body."

"For many years, gum disease has been linked with conditions

like strokes, diabetes, dementia, and pregnancy outcomes. These are all serious conditions that could impact on a person's quality of life," he continued.

"Looking after our mouth should be a priority every day and the benefits of doing so are simply too important to ignore," Carter said.