

CAD/CAM

international magazine of digital dentistry

research

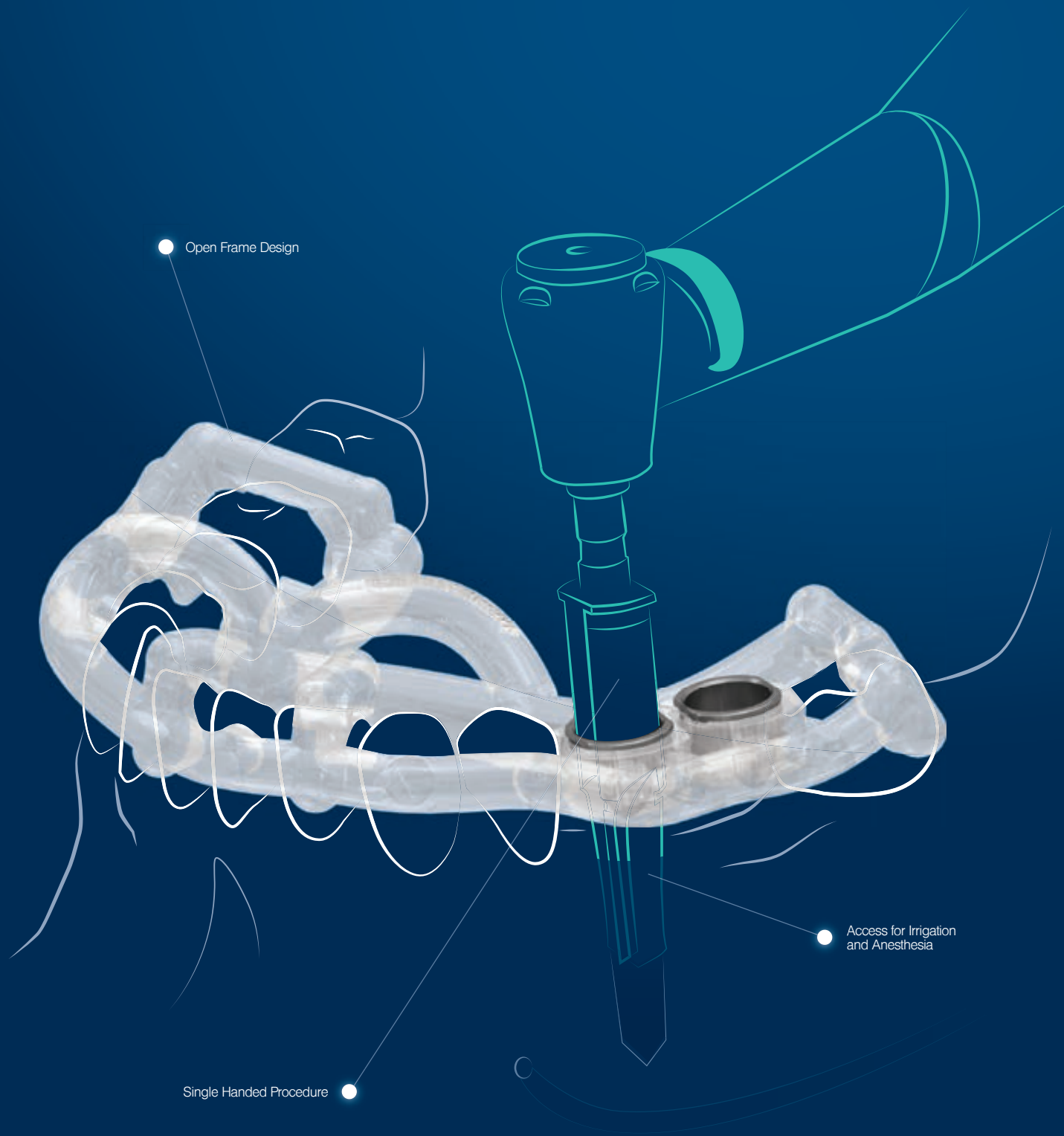
Immediate restoration
in the digital workflow

case report

From digital planning
to the mock-up and final restoration

cone beam supplement

Dynamic navigation
in fully edentulous maxilla



● Open Frame Design

● Access for Irrigation and Anesthesia

● Single Handed Procedure



MAKE IT SIMPLE. WE KNOW HOW!

The innovative design of the MIS MGUIDE and its surgical kits simplifies digital dentistry. The use of CAD/CAM, allows for a prosthetically driven, safe and accurate procedure. To learn more about the MIS MGUIDE, go to www.mis-implants.com

MIS | **MGUIDE**
PART OF THE MCENTER GROUP



Dr Scott D. Ganz

Editor-in-Chief

To merge or not to merge? Is that the question?

Dear Readers,

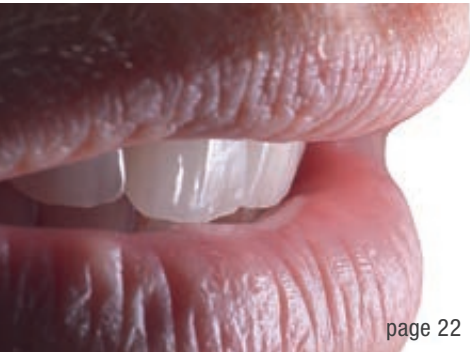The art and science of dentistry has dramatically changed with the advent of digital tools that are currently available for the diagnostic, treatment planning and restorative phases for each patient that we are privileged to treat. While clinicians worldwide predominantly continue to practise as “analogue” dentists, more and more have adopted these technological advances as they understand the benefits of the new digital workflow.

Of course, today in 2018, it is difficult to remain totally within the digital workflow without having some analogue component either in the operatory or in the hands of the dental laboratory technician. Perhaps the workflow starts with the first patient visit, where we can capture the initial clinical presentation with a video or still picture with either a sophisticated camera or our smartphone—all digital. If the patient will require dental implants, crown and bridgework, or porcelain laminate veneers, it is always necessary and desired to capture the pre-existing intraoral condition with either an analogue impression or intraoral digital scan. However, a physical impression or poured stone cast will require conversion to a digital file. This process has become the foundation of our digital universe, via the standard triangulation language or STL file. What happens next is crucial to the ultimate success

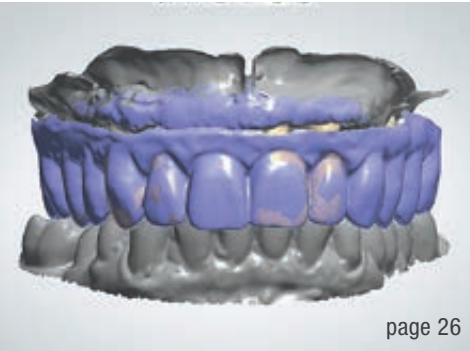of any case: the diagnosis and treatment planning phase through a merging of technology, combining the skill of both the clinician and the dental laboratory technician. It is the correlation of the different data sets with sophisticated software applications that provides the foundation for success.

Currently, we can create an analogue or digital wax-up to analyse and assess and compare the before to the desired after before ever touching the patient with a drill or a scalpel. In order to accomplish this task, we must have the technical knowledge of the software applications that are available today for both the clinician and the laboratory technician. Whether creating a CAD/CAM restoration for a natural tooth preparation or a surgical guide for implant placement, the workflow has forever changed through our digital tools. Therefore, the question of whether to merge or not to merge may be completely transparent to many clinicians, but an essential and necessary part of the digital workflow equation today. It is the goal of this publication to expose our readership to state-of-the-art concepts and applications to enhance the everyday practice of dentistry. Happy New Year to all, and enjoy the articles contributed by expert clinicians from around the globe.

Dr Scott D. Ganz
Editor-in-Chief



page 22



page 26



page 44

Cover image courtesy of MarinaGrigorivna/
www.shutterstock.com



editorial

To merge or not to merge? Is that the question? 03
Dr Scott D. Ganz

opinion

2018—**Changing the way** we communicate 06
Chris Barrow

research

Immediate restoration in the **digital** workflow 08
Drs José Eduardo Maté Sánchez de Val & José Luis Calvo Guirado

case report

Chairside CAD/CAM immediate **restorations** 16
Drs Feng Liu & Xing Liu

From digital planning to the mock-up and final restoration 22
Dr Cyril Gaillard & Jérôme Bellamy

industry report

Digital workflow: From planning to restoration 26
Drs Jan Kielhorn, Siegfried Hoelzer & Björn Roland

Immediate full-arch **restoration** in the maxilla 32
Drs Massimo Frosecchi, Eugenio Longo & Alessandro Certini

cone beam supplement

“Advanced knowledge and a supporting community **via the Internet”** 38

Dynamic navigation in **fully** edentulous **maxilla** 40
Prof. Dr Hakan Uysal & Dr Noyan Başal

feature

“Good design will pay off” 44

business

European Parliament adopts new medical device **regulations** 48

US dental prosthetic **market set to** grow with **digitalisation** 50
Salma Mashkoor & Jeffrey Wong

interview

Non-original abutments are **“a lottery that you cannot win”** 52

“A truly open solution” 54

meetings

International Events 56

about the publisher

submission guidelines 57

international imprint 58



I AM DEMANDING



WINDOWS®
COMPATIBLE



X MIND trium

3D technology that facilitates implant planning with instant volume measurement and bone density assessment

- Evaluate in one click the volume and bone density
- Increase your success rate with a 75µm resolution
- Focus on the region of interest with a wide range of fields of view
- Simplify implant planning with only one software
- Provide more accurate diagnosis thanks to high-detail imaging
- Obtain a full and illustrated report in less than one minute
- Bring a safer therapeutic implementation, less traumatic and less stressful
- Reduce complications related to implant placement
- Allow your patient to visualize the therapeutical recommendation
- Control the dose of X-ray emitted

2018—Changing the way we communicate

Chris Barrow, UK

It is always simultaneously tempting and dangerous to make predictions about the future of dentistry. A recent personal review of the articles I have written over the years revealed that I seem to get things right half the time. The challenge is figuring out which half! So, looking at 2018, what does the landscape look like?

I am conscious that you, dear readers, are an international community and so I will resist the temptation to have a good old-fashioned moan about post-Brexit Britain moving into the Dark Ages while our politicians attempt to leave the EU without leaving it. Or, for that matter, riffs and rants about dictatorial pothead leaders playing dice with our futures to further their own agendas, whether that is in politics, media or sport.

The Internet of things

The smartphone has changed the way we live (Apple-manufactured or otherwise), and the most dominant economic forces on earth are no longer nation economies; they are Google, Microsoft, Amazon, YouTube and Facebook (and let us not forget WeChat—the largest social media platform in China). The figures for the combined revenues of and cash mountains owned by these organisations are mind-boggling, and the way in which those financial reserves are reinvested will have the biggest impact on the world we live in by Christmas this year.

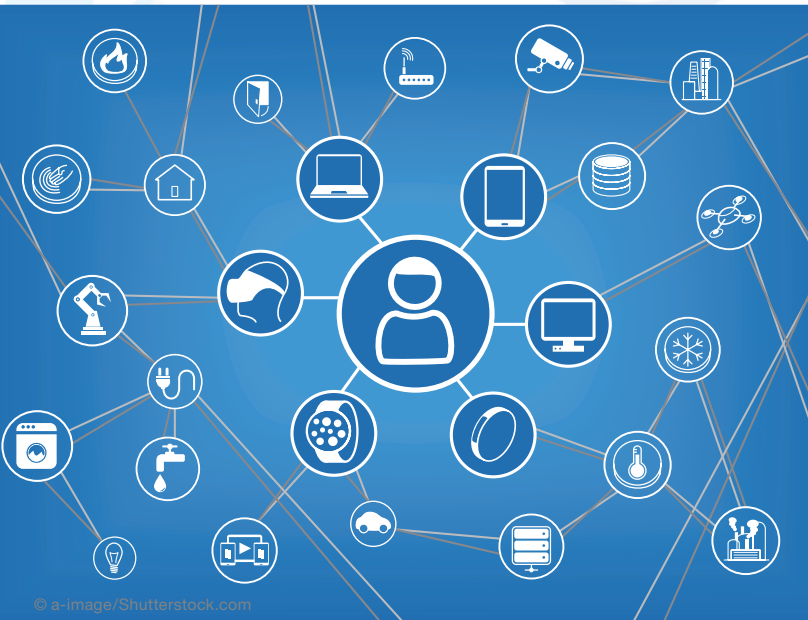I recently returned from a dental lecture tour in India, whose 1.2 billion population has overtaken the US to become the largest nation of Facebook users in the world, with around 250 million Indians checking into their profiles every day. It is hardly surprising that my Delhi hotel was populated by fresh-faced young Americans sporting Facebook employee T-shirts, no doubt building a commercial base to accommodate the demands of this new and expanding audience.

Globally, figures for e-commerce over Christmas 2017 were a record, and as we learn to purchase every conceivable commodity online, the high street trembles, looking at those real estate and staff costs under the watchful eye of their investors and accountants.

There is more to it than just e-commerce though. We are learning to live online, reading, watching, listening, reviewing, commenting, liking and connecting to an extent that our parents could never have imagined. Buying more and more.

India is registering 40 million new smartphones every 12 weeks and is representative of a connective revolution that is gender, age, religion and socio-economically egalitarian—everyone is getting online.

With over 75 per cent of website visits to my clients' dental sites now taking place via smartphones, how your website looks on a desktop no longer mat-



Actually, what I want to talk about is us, you and me, ordinary folk going about our business, pursuing careers, raising families and trying our best to make sense of the world around us. What I want to address is how I think our lives are going to change in the next 12 months, as dental practice owners, managers and team members, but also as members of the public.

ters. How it looks and performs on a smartphone is what counts.

Dentistry is going to have to learn how to communicate with patients online to a greater extent than ever before. I am already seeing tech start-ups looking at the dental space and thinking about how best to keep patients informed of their oral health and how to make their patient experience seamless.

Wearable technology

This brings me to how that communication will take place (between patient and dentist and vice versa) as the year unfolds. The start-ups I mentioned are developing electric toothbrushes that send data back to an application that monitors not just brushing technique but also simple issues around patient health. Data is analysed and then sent back to the patient's smartphone to provide dental health education.

Notwithstanding the issues around the confidentiality of that data and its storage, we are seeing the beginning of wearable tech playing a major role in healthcare generally. E-zines and blogs like those published by Dr Bertalan Meskó (the Medical Futurist) show that progress is exponential. Cue the watch that can feed back dental health information, allowing both patient and dentist to predict problems before they occur.

Getting attention

The science and technology are compelling for early adopters and frightening for laggards. Any debate as to the future of digital dentistry has long since left the late adopters behind, and I am seeing many of my clients racing to keep up with change. However, independent dentistry is a business whose purpose is to solve patients' problems, but whose objective has to be to make an ethical profit, so we cannot ever afford to be distracted from the focus on attracting the right type of new patient and from charging the right price for what we do. These are the challenges that occupy the majority of my time with clients, and the changes I have referenced in the first part of this article have to be embraced in order to survive and prosper in business.

Experts estimate that, as consumers, we are bombarded by up to 5,000 advertising impressions per day, so how do dentists make themselves heard among this noise? In my experience, there is little point in trying to shout loudest by spending money on advertising. The average e-commerce company in the UK now has to invest about £30,000 per month to be heard in the digital marketplace, so a dentist investing £500 per month in search engine optimisation or

Google AdWords is unlikely to succeed. In any event, digital advertising in dentistry often attracts price shoppers and bargain-hunters.

The good news is that social media channels allow us to generate internal digital patient referrals in numbers that could never be foreseen in the old days of word of mouth. Thus, a carefully planned and well-executed social media marketing plan is now an essential component of every practice's overall goals for new patient generation. Facebook, Instagram and YouTube are the marketing domains of 2018.

Prices

The interesting irony here is that digital dentistry, once we have moved from the innovation stage of the adoption cycle, through early adopters to the late majority, will actually have the effect of reducing the cost of providing dental healthcare and treatment. I have clients right now who innovated in digital dentistry and are seeing a consequent improvement in their bottom line profit as costs of sales reduce. That may not sound like great news for laboratory and materials suppliers, but that is the inevitable consequence of technological progress.

I am also realistic enough to agree that little of that cost-saving is being passed on to the patients at the moment. That is because we are still in the early stages of the digital adoption cycle, and the pressure on prices will not occur until much later in that cycle. It is time, indeed, for the innovators to make hay. Prices will stay firm in 2018; costs can reduce.

An interesting year ahead

2018 will see the continued acceleration of the impact that digital communication and commerce will have on our lives. The dental practice of the future will fully embrace not only digital dentistry but also the way in which they connect with their patients online. The smartphone will be the place that happens, until smartphones are replaced by the next generation of wearable devices.

contact



Chris Barrow is the founder of the Coach Barrow consultancy practice. An active consultant, a trainer and a coach to the UK dental profession, he regularly contributes to the dental press and social media and elsewhere online. Barrow can be contacted at coachbarrow@me.com.

Immediate restoration in the digital workflow

Drs José Eduardo Maté Sánchez de Val & José Luis Calvo Guirado, Spain

Endosseous implants have consistently achieved high success rates in partially and completely edentulous patients. Clinicians have therefore begun to offer selected patients immediate and early implant placement options. The long-term success of immediately loaded implants has been investigated in animals^{1,2} and humans,³ with encouraging results. However, most of the studies were performed with implants placed in the anterior mandible, where primary implant stability is easily achieved.

In the anterior maxilla, clinicians seeking to load implants immediately must be concerned not only about achieving adequate implant stability, but also about fulfilling patients' desires for aesthetic results that resemble the natural dentition. To achieve this, it is essential to maintain as much of the bone height around the implant neck as possible, controlling the biologic width.⁴

Bone loss around the implant always occurs when an abutment is connected to a dental implant at the crestal level. It has been demonstrated that the gap between the implant and the abutment has a direct effect on bone loss, regardless of whether the two parts are connected at the time of integration of the implant or later.⁵ This phenomenon occurs whether the implant is loaded or not and appears to be unrelated to the type of implant surface.^{5,6} Hermann et al. demonstrated that crestal bone remodels to a level about 2.0mm apical to the implant-abutment junction (IAJ),^{5,7,8} while Lazzara and Porter reported crestal bone levels about 1.5 to 2mm below the IAJ at one year after restoration.⁹ Tarnow et al. documented a horizontal component that results in 1.3 to 1.4mm of resorption from the IAJ to the bone in a horizontal direction.^{10,11} When the biologic width is in the wake of such osseous changes, the soft-tissue architecture, including the appearance of the papillae, is affected. The interproximal bone influences the interdental papillae by acting as a guidepost for the soft-tissue contours.



Fig. 1: Implants and abutments used (left to right). blueSKY implant, SKY esthetic abutment titanium, SKY elegance abutment.

In addition to several ideas aimed at limiting crestal bone resorption, the concept of platform switching appears to be promising. Platform switching refers to the use of a smaller-diameter abutment on a larger-diameter implant collar. This type of connection shifts the perimeter of the IAJ inward toward the central axis of the implant.^{12,13} The time limitation in implant treatments is an important bias when it comes to planning and developing rehabilitation therapies. In this sense, the inclusion of new materials that allow for immediate loading in a single session without having to replace prosthetic components facilitate optimal results in terms of gingival attachment and minimize peri-implant bone loss after prosthetic abutments have been manipulated. Ceramically reinforced PEEK is of great interest as it allows a single attachment to be retained in place throughout the entire treatment and avoids handling-related overload. Its mechanical and physical properties have been tested in animal experiments and in humans, showing the material to be ideal for one-step Xprotocols.

The physical and mechanical properties of the prosthetic components govern the success of the long-term restoration. Resistance to occlusal loads such as masticatory movements and parafunction should be adequate to allow denture survival. The modulus of elasticity and bending resistance of the material should be adequate to prevent undesirable fractures or micromovements.¹³

Furthermore, components used require a high degree of biocompatibility to prevent the occurrence of abnormal tissue reactions such as initial peri-implant inflammation and mucositis, which may result in more severe complications such as peri-implantitis.¹⁴ Polyetheretherketone (PEEK) is a polymer from the polyaryletherketone family, a relatively newly developed family of high-temperature thermoplastic polymers having of an aromatic backbone interconnected by ketone and functional ether groups.¹ In medicine, PEEK has been found to be an excellent substitute for titanium in orthopaedic appli-

cations^{15,16} and has been used in dental implants, provisional abutments, implant-supported bars, or clamp material in removable dentures.^{17,18} PEEK is biocompatible and has a natural tooth-coloured appearance, unlike metal reconstructions.

Ceramically reinforced PEEK materials were developed to improve the mechanical properties and the colour of dental restorations. One of these materials is BioHPP (bredent medical, Senden, Germany). In abutments, the BioHPP is directly injection-moulded to a titanium base and forms a monolithic hybrid abutment called “elegance” abutment, with a screw seat in titanium for long-term stability plus a resilient body made of ceramically reinforced PEEK.

To shorten procedures and eliminate intermediate prosthetic steps, digital technologies were developed that allow the intraoral scanning of models and attachments with a high degree of precision and reproducibility. Chairside CAD/CAM systems such as CEREC (Sirona) allow direct scanning of the abutments and the realization of immediate crowns. The ceramically reinforced hybrid abutments with a PEEK body and titanium base are easily scannable, yielding restorations of high quality with a good prognosis. Problems caused by removing and reinserting different prosthetic components—such as loss of soft tissue or early marginal bone loss—are reduced or eliminated. This article demonstrates the reliability of the single-session protocol using digital methods for scanning and producing crowns complemented with platform switching and evaluates the peri-implant soft-tissue seal.

Material and methods

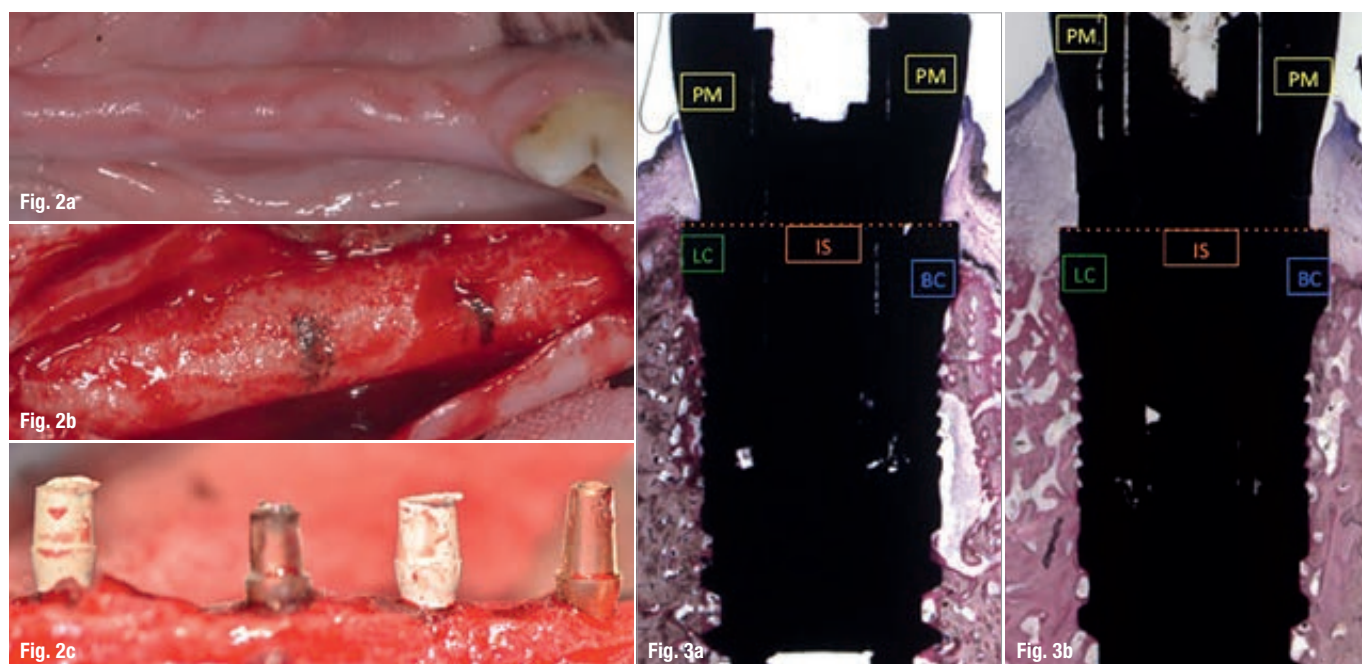
Animal protocol

An animal experiment was conducted to evaluate an implant placement protocol with immediate loading using PEEK and CEREC and to assess the peri-implant soft tissue. Forty-eight blueSKY implants (bredent medical) were placed in healing bone. Thirty-two SKY elegance abutments (bredent medical) were used in the test group and sixteen titanium abutments in the control group (Fig. 1).

A randomization scheme was generated using the website www.randomization.com. The Ethics Committee for Animal Research of the University of Murcia, Spain, approved the study protocol, which followed the guidelines established by Directive 2010/63/EU on the protection of animals used for scientific purposes. Six American Foxhound dogs approximately one year of age, each weighing approximately 13–15 kg, were used in the study.

Day 0 (first stage)

The animals were pre-anaesthetized and taken to the operating theatre where, at the earliest opportunity, an intravenous catheter was inserted into the cephalic vein and propofol was infused at the rate of 0.4 mg/kg/min as a slow constant-rate infusion. Conventional dental infiltration anaesthesia was administered at the surgical sites. Premolar and molar extractions (P2, P3, P4, M1) were performed in both mandibular quadrants of each dog.



Figs. 2a–c: Animal study protocol with immediate loading. **Figs. 3a & b:** Linear measurements (in mm): peri-implant mucosa (PM), buccal bone crest (BC), lingual bone crest (LC), top of the implant shoulder (IS), bone crest (BC), distance from the implant shoulder at buccal bone crest (IS-BC), distance from the implant shoulder at lingual bone crest (IS-LC).