

DENTAL TRIBUNE

The World's Dental Newspaper • Pakistan Edition



PUBLISHED IN PAKISTAN

www.dental-tribune.com.pk

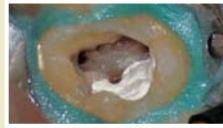
SEPTEMBER, 2019 - Issue No. 05 Vol.6



Grab any opportunity, learn, and prove yourself: Dr Sameer

INTERVIEW

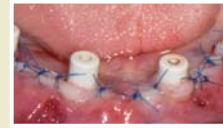► Page 6



Use of 3D technology in the diagnosis and treatment of...

CLINICAL ENDODONTIC

► Page 8



Straumann Pro Arch concept with fully guided implant

CLINICAL IMPLANTOLOGY

► Page 9

1st UHS IDC

UHS unveils game-changing international dental congress



Photos: DT Pakistan

By Dr Hira M. Khan

LAHORE - October 5th marked the final day of the 1st UHS International Dental Conference (IDC) organized at the Convention Center, Expo Center Lahore, under the auspices of University of Health Sciences. The congress welcomed over 2,300 participants from all over the country. 30 international speakers graced the event. Over 150 companies showcased their products at the 5th DTMA Trade Exhibition

on UHS's platform. The opening ceremony was embellished with the top dignitaries of the country, as well as the dental world. The Chief Guest for the occasion was the honourable President of the Islamic Republic of Pakistan, Dr Arif-ur-Rehman Alvi. Punjab Health Minister and Patron Conference, Dr Yasmin Rashid, also graced the event. Foreign delegates from Turkey, Palestine, Egypt, Jordan, Saudi Arabia, Sri Lanka, Canada, UK, China, Thailand, Brunei Darussalam, and Brazil,

participated in the 1st UHS IDC. With an announcement, the Master of Ceremony Dr Saima Chaudhary commenced day-one's proceedings, which was marked by recitation from the Holy Qur'an. Dr Arif Alvi officially inaugurated the 1st UHS International Dental Conference. Later in his address, Dr Arif Alvi stressed on prevention as the number one strategy against oral diseases and, therefore, the need of the hour. He further said, "90% of oral diseases are preventable, and so
Continued on Page 15

SIOHS introduces integrated curriculum

By H. Hasan

KARACHI - Sindh Institute of Oral Health Sciences (SIOHS), Jinnah Sindh Medical University (JSMU), is committed to modernizing dental education in Pakistan and, therefore, has introduced integrated curriculum, case-based learning and problem based

Image: DT Pakistan



learning in their institute. These academic innovations include structured teaching in all basic and clinical sciences departments. Active participation of students in these programs is also encouraged. The new changes in the curriculum is the brainchild of Prof Kefi Iqbal the Dean of SIOHS and head of the department.

The curriculum includes the course topic, further comprising elaborate lecture topics and learning objectives, which facilitates in providing better focus to the learning graduates; there
Continued on Page 15

ADA FDI World Dental Congress '19 concludes in San Francisco

DT Pakistan Report

The 107th edition of FDI World Dental Congress that welcomed over 30,000 participants from all over the globe came to its conclusion on September 10th, 2019, in San Francisco, USA. The congress was hosted in collaboration with ADA at the Moscone Center, where it commenced on September 4th.

The attendees learned about various skills, and groundbreaking researches and innovations in Dentistry through

workshops, seminars and the World Dental Congress exhibition. They were also offered the opportunity to network with leaders of global dentistry.

Dr Saima Butt, a member of Pakistan Dental Association (PDA), as well as FDI National Liaison Officer in Pakistan, represented the country on the international platform, where she also contested for the science committee.

NLOs of the Asia Pacific Region participated in the Congress under the Chairmanship of Dr Awab Alvi,



Photo: DT Pakistan

a renowned dentist in Pakistan and son of the President of the Islamic Republic of Pakistan Dr Arif Alvi. FDI President Dr Kathryn Kell, in her concluding statement, thanked all the delegates and members, for allowing her the opportunity to serve. Dr Kell acknowledged that the two years of her presidency had been very exciting, memorable and rewarding, not only for her but the FDI community as a whole.

Dr Gerhard Seeberger, the new

president of the FDI World Dental Federation (2019-20), said that during his term as president, he wants to guarantee dignity: dignity for dentistry as a medical profession at the service of the people; dignity for people and patients; and, finally, dignity for FDI and its members with the latter will be conferred to only those dentists if they tirelessly engaged for the betterment of the global society. Dr Seeberger continued that his priorities
Continued on Page 15

SHCC forms IRB to promote research

DT Pakistan Report

KARACHI - The Sindh Healthcare Commission (SHCC) has established its Institutional Research Board (IRB) with the aim to review the research projects for scientific and ethical values and promote responsible research culture for health in the Sindh province.

The IRB will also facilitate researchers by reviewing research projects and ensuring that the rights and welfare of human subjects are being protected. The IRB welcomes research projects of experienced as well as amateur researchers willing to initiate research in the areas of healthcare subjects, especially in Sindh. The main emphasis will be



Image: DT Pakistan

given on issues such as infection prevention and control, injection safety, and other health-related topics.

The SHCC will utilize such research projects focused on creating an impact on healthcare quality improvement in Sindh and presenting solutions for improvement in areas of

healthcare service delivery.

The SHCC has notified members of the IRB including Dr Rafique Khanani, Chairman, Dr Faiza Erum Bhutto, Coordinator, Dr Tasneem Ahmed, Member, Dr Nazir Khan, Member, Dr Sharaf Ali Shah, Member, Justice Sabir Chippa, Member, Dr Najia Mansoor, Member,

Dr Ayaz Mustafa, Member, and Ms Sameen Zaidi, Member.

The team from the Directorate of Clinical Governance and Training also attended the three-day workshop (TOT) on Patient Safety Friendly Health Initiative organized by the World Health Organization (WHO) in Karachi.

Prof Tariq Javed sheds light on the intricacies of Periodontal Surgery

KARACHI - In its effort to promote dental education, the Altamash Institute of Dental Medicine recently organized a lecture on periodontal surgery. The renowned Prof Tariq Javed, Professor of Periodontics from the Carolina Institute, USA, conducted the lecture in which he discussed various periodontium related surgeries that support restorative and prosthodontic treatments such as prosthodontics ridge augmentation and smile enhancement. He also performed surgery during the session as part of a live demonstration.

At the end of the session, house officers, students, and faculty members engaged in a question and answer session with the Professor. Dr Hasnain gave his vote of thanks and appreciated Prof Javed's efforts towards providing awareness concerning healthy practices. He also thanked the students and faculty for being a part of the session. **-PR**



Photos: DT Pakistan

Prof Ghani wins membership of renowned UK Charity

In recognition of his extraordinary contributions towards facilitating the use of evidence based medicine (EBM), Prof. Dr Fazal Ghani, Head of Department of Prosthodontics and Dean Postgraduate Dental Sciences, Peshawar Dental College, Peshawar has earned the right to Cochrane Collaboration Membership. Cochrane Collaboration is a UK registered Charity with its office in Central London. Cochrane has 11,000 members and over 68,000 supporters coming from more than 130 countries, worldwide. Cochrane volunteers and contributors are researchers, health professionals, patients, care-givers, and people passionate about improving health

outcomes for everyone, everywhere. The Cochrane global independent network gathers and summarizes the best evidence from research and to make it easily accessible to help all including healthcare providers, policy makers and healthcare consumers make informed choices about treatment. Cochrane has been doing this for 25 years.

The benefits of being a Cochrane Collaboration Member include;

1. Voting right in Cochrane elections and helping to shape its future policies and plans.
2. Tracking and gaining recognition for his contributions, and using his particular skills and interests most effectively.

3. Continuing to build his skills and expertise as an active contributor to Cochrane's work.

4. Receiving information and updates targeted to his skills, interests, and training needs.

As an active Cochrane Collaboration Member, Dr Ghani will commit to adhering to Cochrane's principles, as well as confirming that he is not currently employed by a medical device manufacturer or pharmaceutical company. Cochrane's strength lies in the people who make up their community. **-PR**



DENTAL TRIBUNE

The World's Dental Newspaper - Pakistan Edition

Publisher/CEO

Syed Hashim A. Hasan

hashim@dental-tribune.com.pk

Editor Clinical Research

Dr. Inayatullah Padhiar

Editors Research & Public Health

Prof. Dr. Ayyaz Ali Khan

Editor - Online

Haseeb Uddin

Designing & Layout

Sheikh M. Sadiq Ali

Dental Tribune Pakistan

3rd floor, Mahmood Centre, BC-11, Block-9, Clifton, Karachi, Pakistan.

Tel.: +92 21 35378440-2

Fax: +92 21 35836940

www.dental-tribune.com.pk

info@dental-tribune.com.pk

Dental Tribune Pakistan cannot assume responsibility for the validity of product claims or for typographical errors. The publisher also does not assume responsibility for product names or statements made by advertisers. Opinions expressed by authors are their own and may not reflect of **Dental Tribune Pakistan**.

International Office/Headquarters

Publisher/Chief Executive Officer

Torsten R. Oemus

Director of Content

Claudia Duschek

Dental Tribune International GmbH

Holbeinstr. 29, 04229 Leipzig, Germany

Tel.: +49 341 48 474 302

Fax: +49 341 48 474 173

General requests:

info@dental-tribune.com

Sales requests:

mediasales@dental-tribune.com

www.dental-tribune.com


Editorial material translated and reprinted in this issue from Dental Tribune International, Germany is copyrighted by Dental Tribune International GmbH. All rights are reserved. Published with the permission of Dental Tribune International GmbH, Holbeinstr. 29, 04229 Leipzig, Germany. Reproduction in any manner in any language, in whole or in part, without the prior written permission of Dental Tribune International GmbH is expressly prohibited. Dental Tribune is a trademark of Dental Tribune International GmbH.

©2019, Dental Tribune International GmbH.

All rights reserved. Dental Tribune International GmbH makes every effort to report clinical information and manufacturers' product news accurately, but cannot assume responsibility for the validity of product claims, or for typographical errors. The publishers also do not assume responsibility for product names, claims, or statements made by advertisers. Opinions expressed by authors are their own and may not reflect those of Dental Tribune International GmbH.

How can you provide **more comfort** to your sensitivity patients?

Apply the superior science of **Colgate® Sensitive Pro-Relief™** Toothpaste for **superior** sensitivity relief*



Instant[†] relief in office
48.9%¹ reduction in sensitivity after prophylaxis[‡]

"Is it supposed to be sensitive?"
—Real Patient[¶]



Lasting[§] relief at home
90.1%¹ reduction in sensitivity after 2 weeks[‡]

"Even when I drink cold water, it is much better."—Real Patient[¶]



Their satisfaction will speak for itself.^{¶1}

*Vs conventional sensitive toothpastes containing 5% potassium nitrate (equivalent to 2% potassium ion).

[†]For instant relief, apply directly to the sensitive tooth with fingertip and gently massage for 1 minute.

[‡]Air blast hypersensitivity test in a clinical study after 1 application and after 2 weeks.

[§]Lasting relief with continued 2x daily brushing.

[¶]In the same study, testimonials were recorded from real patients after treatment with Colgate® Sensitive Pro-Relief™.

References: 1. Ayad F, Ayad N, Vazquez J, et al. *Am J Dent* 2018.

Colgate®



Photo: DT Pakistan

Dr Irfan Qureshi's Comprehensive Implantology Course

KARACHI - Renowned Implantologist Dr Irfan Qureshi recently conducted a two-day course on Comprehensive Implantology. The course was designed for general dental practitioners and dental students that desired to enhance their clinical knowledge and skills in Implant Dentistry.

The course outlined the basics of implantology, applied anatomy, diagnosis and treatment planning, bone physiology, sinus augmentation, socket management, and digital workflow, all followed by live surgical demonstration and hands-on workshop. Day 1 of the course started off with the participants introducing themselves, followed by a detailed and in-depth lecture delivered by Dr Qureshi. Before diving into the course outline, he acquainted himself with all the candidates by having candid conversations and speaking on motivational subjects, expertly easing the students into the educational aspect of class.

The highlights of Day 2 comprised several case presentations, live dental implant demonstration and a hands-on workshop, all guided and supervised by Dr Irfan Qureshi and his associates. **-PR**

Lecture on Laser Dentistry at AIDM

KARACHI - Altamash Institute of Dental Medicine (AIDM) recently organized a lecture on Laser Dentistry in an effort to promote continuing dental education. Renowned dentist Dr Talat Qadri, from the Karolinska Institute, conducted the lecture. He discussed the topics of dental pain and practice of laser dentistry in detail. He also presented some of his past cases.



At the end of the session, final year students and faculty of AIDM were invited to raise



Photo: DT Pakistan

questions, which were expertly answered by Dr Talat.

Dr Hasnain also gave his vote of thanks to Dr Talat and appreciated his efforts for providing awareness for better

practices. He also thanked the students and dental faculty for being a part of the session. **-PR**

Career counseling workshop at IADSR

LAHORE - Keeping in view the importance of making the right career choice, a workshop was held at the Institute of Advanced Dental Sciences and Research (IADSR). The event was facilitated by National Coordinator of IADSR and Dean of Dentistry at Azra Naheed Medical & Dental College Prof Ayaz Ali Khan, Dr M Sohaib Nawaz, Dr M Haseeb, and Dr M Ahmad Javaid.

The participants were counseled on postgraduate degrees after BDS and how to set up your local qualification at an international level. Facilitators also guided participants on the opening of private practices and answered their queries as well. Particular emphasis was given to those who wish to pursue dentistry in Canada. The session concluded with an aim to continue such endeavors in the future as well. **-PR**



Photo: DT Pakistan



Photo: DT Pakistan

– Pediatric dentistry hands-on

A two-day workshop on pediatric dentistry was recently conducted at the Institute of Advanced Dental Sciences and Research (IADSR). It was held as a part of the IADSR's 8th Professional Diploma in Advanced General Dentistry (PDAGD). The workshop was unique and distinctive in such a way that for the first time a dedicated two-day workshop was held on pediatric dentistry to provide an opportunity for the participants to learn under the supervision of highly professional and esteemed facilitators.

Professor Dr Amjad H Wyne, Professor of Pediatric Dentistry at the King Saud University College of Dentistry, Riyadh, and Dr Arham Nawaz Chohan, Professor of Pediatric Dentistry at CMH, Lahore, facilitated the workshop. Prof Wyne discussed examination and treatment planning in pediatric dental patients in detail, along with the advantages and disadvantages of working without a plan. He also taught the principles and factors that are to be considered in treatment planning, the role of antibiotics in children, as well as behavioral management techniques. Pulp therapy in the primary dentition from clinical diagnosis to the treatment procedures were discussed with the students as well.

Posterior stainless steel crown and anterior strip crown was performed by the participants



Photo: DT Pakistan

on typodont under the supervision of Professors. The facilitators solved queries concerning the common complications that were faced by the participants during procedures.

Prof Arham Chohan further explained pulp therapy in young permanent teeth and trauma to primary and permanent teeth in the interactive session. He also discussed the iatrogenic cases in pediatric dentistry and elaborated the role of radiography in the primary dentition. Prof Arham taught apexogenesis, apexification, and space management in children, complications of pulpotomy in primary molars, reattachment of fractured tooth fragment, MTA pulpotomy, and local anesthesia in children. The workshop was concluded by notching its desired learning outcomes. **-PR**



Photo: DT Pakistan

new

SENSODYNE



REPAIR & PROTECT

ACTUALLY
HELPS REPAIR
SENSITIVE TEETH*

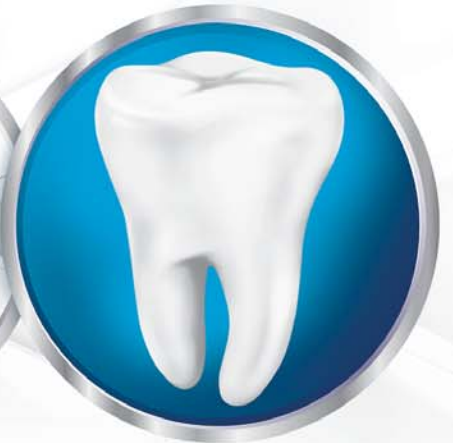Cause of sensitivity pain

Tiny holes in dentine

A hard layer

Repairs these holes

Helps protect from pain




No.1 DENTIST RECOMMENDED BRAND FOR SENSITIVE TEETH

*Forms a protective layer over the sensitive areas of the teeth. Brush twice a day for lasting sensitivity protection.

CHPAKCHSENO001917

Grab any opportunity, learn, and prove yourself: Dr Sameer Qureshi

Dr Sameer Qureshi graduated from Fatimah Jinnah Dental College (FJDC), Karachi, in 2001. Following his graduation, Dr Sameer went on to pursue his Masters in Prosthodontics from the University of Manchester. After returning from England, Dr Sameer returned to his alma mater, FJDC, as an educator. He has been associated with the institute ever since. Dr Sameer also runs his own private practice in DHA, Karachi. He also teaches various courses in Prosthodontics and Restorative Dentistry to sustain his passion for teaching.



By Dr Hira M. Khan

Dental Tribune Pakistan: Which higher education option would you recommend to young graduates after BDS: Masters from abroad, FCPS, or MDS?

Sameer Qureshi: No education is useless because you are always learning something new. FCPS, however, being a fellowship program, has a lot of weightage. It is a good option if you plan to stay in Pakistan. MDS is rising to prominence with each passing day; however, it is going to take some time to prove itself. Regardless, it is a good degree for both clinical and non-clinical fields.

As far as Masters from abroad is concerned, if you have the opportunity and means of going abroad, I would always suggest that you should. That way, the horizon opens up, and you get many opportunities to learn about new aspects of the field. It is good to go abroad and achieve something besides doing your basic degree from Pakistan.

DTP: Benefits and drawbacks of MSc from abroad and FCPS from Pakistan on a local and global scale?

SQ: Both are good education platforms, and if you can gather both that would be a huge plus. Having international exposure is always important for any human being. I always push my students to go abroad, if they can, to get some basic understanding of what is happening outside Pakistan.

Both options come with their own set of perks. No education option comes with an inherent disadvantage; it is up to the acquirer how they use the acquired knowledge. If there is bad luck or lack of hard work, things might not work out then, but education itself does not carry any disadvantage. Anything that you have learnt is going to prove beneficial if applied properly.

Regarding the fact that you plan on staying in the country and practicing

or/and teaching dentistry, I would say FCPS is the goal at the moment. MDS is also an excellent major degree that you could pursue. Then again, if you want to learn good clinical dentistry, I would say that you acquire basics from here and then go abroad to learn skills from the masters who have written the books.

DTP: What was the time of completion of your degree?

SQ: I did my Masters in Fixed and Removable Prosthodontics from the University of Manchester. It was a one-year degree. I got an excellent opportunity to learn from incredible teachers. Alhamdulillah, life has been good to me in prosthodontics so far.

DTP: What is the expected time of completion of your suggested degree?

SQ: I would say that any four-year degree would do the job. Whether it is Masters or FCPS, you should go for a four-year clinical program if you want to become a clinician. However,

“For higher studies in Dentistry, England is the easiest to get in.”

if non-clinical subjects have good opportunities, then any program with a three to four-year duration would do well for your learning and contribute to the credibility of your degree.

DTP: What would you recommend out of the two: join the workforce or pursue higher education after BDS?

SQ: I would suggest that one should start studying during their house job if there is a plan to do post-graduation immediately after. So you can complete your education in one go because once you start working it creates a lag between you and further education. Therefore, it is better to finish with post-graduation to maintain the flow of studying. It is easier to do it when you have peers

“MDS is becoming more prominent day by day; it is going to take some time to prove itself.”

along with you, which creates a 'college environment' that facilitates better learning.

So I would say, go with the flow. Complete your education, whether it is FCPS or MDS.

Along with education, you must also find time for clinical attachments/ observerships. It would prove to be very helpful in polishing your clinical knowledge. If you get a good job opportunity, and you are able to divide your time between your two commitments effectively, then that is great too. In any case, it is advisable to pursue higher education, which is easier to manage if you are not working alongside.

DTP: For those joining the workforce after BDS, which one is the better choice: private practice or getting a job at an institute or a clinic?

SQ: Opening a clinic is a very good idea but it is essential to have some prior experience, because managing a clinic is a completely different ballgame. It is about marketing, dealing with all kinds of people, etc. It is not only about seating your patient and starting to drill their teeth. You

“Go with the flow. Complete your education, whether it is FCPS or MDS.”

have to manage the clinic, manage your staff, and so you have to learn those basics. I opened my own clinic 5-6 years after my graduation. I got my basic training from my seniors, for which I took on observership with great dentists. If presented with opportunities, do take up clinical attachments and observerships. It helps

RAPID FIRE

1. Why dentistry and not medicine?

SQ: It was my father's wish. I wanted to be a pilot like him.

2. Why Masters and not FCPS?

SQ: I wanted to go abroad.

3. MSc, MDS, or Fellowship?

SQ: Whichever opportunity you get, take it, grab it, learn from it, and prove yourself.

4. Priority after graduation (BDS)?

SQ: Post-graduation. If not, then private practice and courses. Continuing education is essential.

5. Is prevention still better than cure?

SQ: Always was and always will be, in every aspect.

6. How important is sterilization?

SQ: It is as essential for the doctor as it is for the patient.

7. Can enamel structure really be restored with a toothpaste?

SQ: We have great modern fillings for that purpose.

8. Patient history, important or just a formality?

SQ: Extremely important. Cannot move forward without it.

a lot in setting up a private practice.

DTP: What are your recommended destinations and institutes for those wanting to pursue a foreign degree?

SQ: There are a lot of options to choose from. I would suggest researching thoroughly regarding the various programmes being offered, the standing of the university, and their faculty while going through the process of applying to foreign universities. England has a lot of good universities; I would name the University of Manchester because I had a great experience there. The city was beautiful as well. To name a few other options, there is Kings College, Eastman, Edinburgh, and Sheffield.

There are three different countries for you to deal with: UK, USA, and Australia. England is the easiest to get in. The US and Australia would be a difficult path to pursue.

DTP: Reflect on your experience of learning abroad?

SQ: Personally, I feel that while studying there, I was able to groom myself. It was a great experience, learning from some of the most prominent names in dentistry. I found it to be a morale-boosting experience. The learning environment there is fantastic. We as a nation are hardworking people when presented with a good opportunity in a foreign country; we are capable of achieving a lot.



HELP KEEP YOUR PATIENTS ON A JOURNEY TO HEALTHY GUMS

PARODONTAX® TOOTHPASTE IS CLINICALLY PROVEN TO REDUCE PLAQUE, BLEEDING GUMS AND INFLAMMATION

4X

greater plaque removal*¹

48%

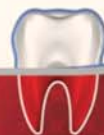greater reduction in bleeding gums*¹

Recommend parodontax® toothpaste to help patients maintain their optimal gum health between dental visits.

DAILY FLUORIDE TOOTHPASTE FOR HEALTHY GUMS & STRONG TEETH

parodontax®

EXTRA FRESH



gsk

Helps stop and prevent bleeding gums

GlaxoSmithKline Consumer Healthcare Pakistan Ltd.
35-Dockyard Road, West Wharf, Karachi - 74000

GSK is committed to the effective collection and management of human safety information relating to our products and we encourage healthcare professionals to report adverse events to us on +92 (21) 111-475-725 or pk_pharmasafety@gsk.com

* Compared to a regular toothpaste and professional clean and 24 weeks' twice-daily brushing.

Use of 3D technology in the diagnosis and treatment of endodontic disease

By Dr. Fabio Gorni

In recent years, the technology associated with endodontic therapy has undergone a veritable revolution. For years, intraoral radiographs were used as the basis for diagnosis and for planning root canal therapy, despite the fact that these images did not provide a faithful reproduction of the endodontic anatomy. This created a series of technical problems, which, although they could be partly overcome by the operator's personal experience, to some extent remained unresolved, especially in the field of diagnosis.

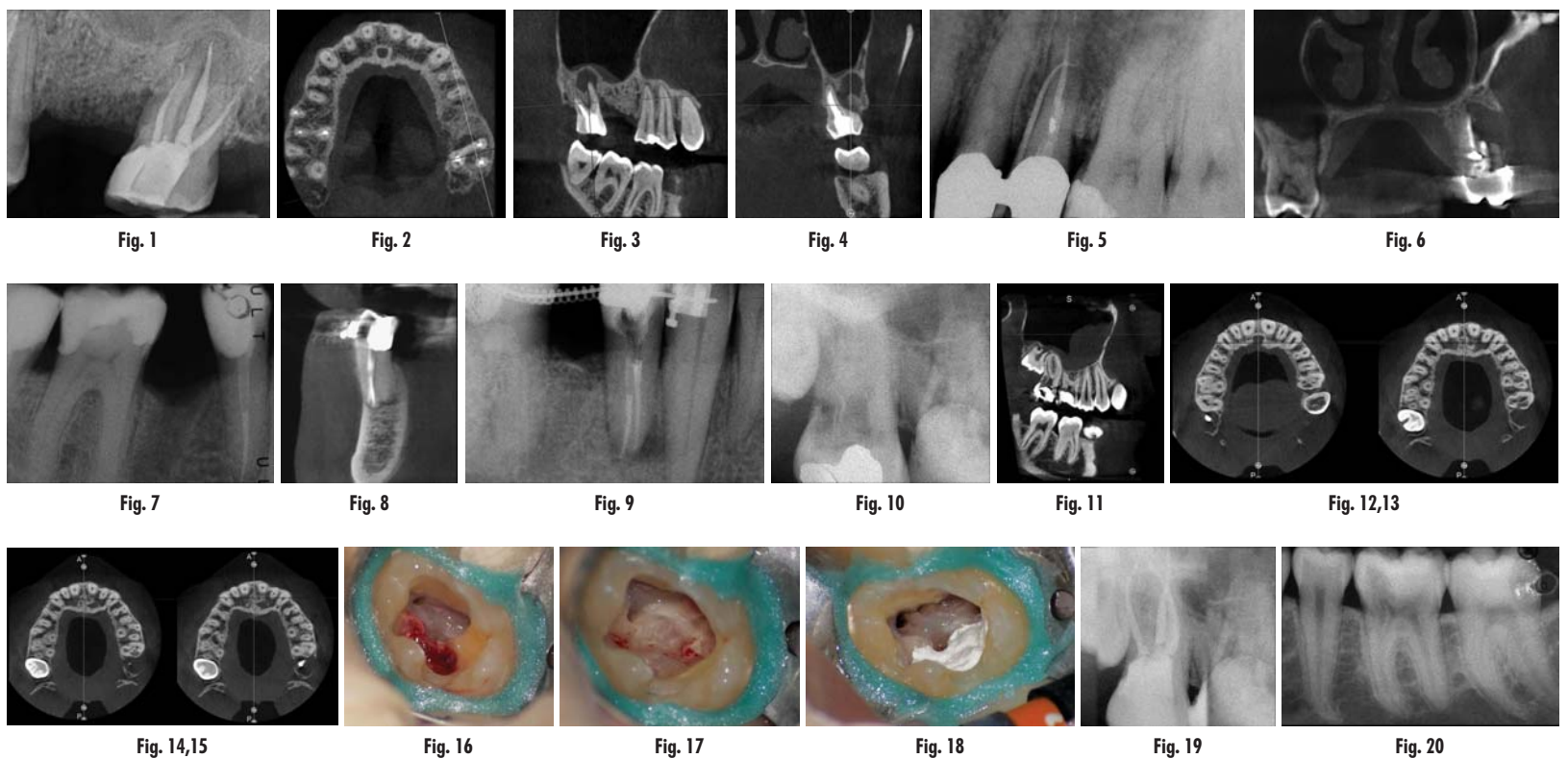
trium technology, with extremely satisfactory results. The imaging is very accurate and highly detailed, and above all, the user friendliness of the ACTEON Imaging Suite makes it possible to identify even slight differences between the different radiographic slices, differences that are of paramount importance for making a correct endodontic diagnosis and for the therapeutic decision-making process itself. Clinician experience alone is not sufficient for establishing the correct approach to be adopted in the case of endodontic disease, and very often clinical cases that were initially scheduled for

root of this molar to the furcation, while the axial slices allow us to conduct a precise analysis of the endodontic anatomy and, in particular, the shape of the mesial root, which in this case was fused with the palatine root. A full overview of the case can, therefore, guide the decision-making process and direct the treatment plan towards a specific type of treatment (Figs. 1–4).

In the maxillary premolar shown in Figures 5 and 6, the fistulogram revealed the presence of an apical lesion that extended coronally to approximately the middle third of the root. The clinical decision could,

diagnosis, thus, made it possible to perform selective intervention on the remaining pulp, leading to successful treatment of the untreated canal.

Undeniably, one of the most complex conditions to treat is external invasive root resorption, where the extent of the defect affects the treatment options. It therefore becomes sensible to perform a preoperative evaluation of the location and extent of the resorption, and the potential for recovery, thus, depends on correct 3D planning of the procedure, which can only be achieved after examination of the CBCT images. It is very important to



I personally started using cone beam computed tomography (CBCT) for endodontic purposes more than ten years ago. Although the machines that I used then were far from ideal for this specific purpose, the possibilities offered today by increasingly sophisticated technologies have greatly improved my diagnostic and interventional capabilities. In order to make an accurate diagnosis, an endodontist needs to perform a highly detailed assessment of the canal and pulpal anatomy, which requires high-definition examination techniques and software that enables the endodontist to rotate the tooth accurately and easily. This may seem obvious and trivial, but is not. Indeed, over the past ten years, I have had the opportunity to work with a large number of devices and dozens of software programmes, but only very few have proven to be suitable for endodontic purposes. For a few years now, I have been using ACTEON's

orthograde treatment, after CBCT assessment, turn into cases for endodontic surgery or vice versa. We can therefore state that the capability we have now of performing these studies in a quick and easy manner has drastically reduced the number of incorrect diagnoses and, consequently, the number of clinical errors.

The case with which I would like to start my clinical review is a perfect example of how difficult it is to establish the origin of the patient's symptoms on the basis of an intraoral radiograph alone. Not only does the 2D study fail to establish with certainty the presence of a lesion, but more importantly, it is impossible to establish the size, morphology and type of the lesion. An analysis of the 3D imaging, however, provides a clear picture of the clinical situation: the coronal and sagittal slices revealed the presence of a large lesion extending from the apex of the mesial

therefore, propend towards orthograde retreatment; however, CBCT gave us a very different view of the situation compared with the radiograph, as it indicated that a prior treatment had irreversibly damaged the tooth, which would therefore have to be extracted.

The situation was entirely different for the mandibular premolar shown in Figures 7 to 9, where, in the absence of any radiological signs of a lesion and despite the apparently correct endodontic approach adopted by another colleague, the patient complained of persistent pain which was both spontaneous and triggered by percussion of the tooth. In this case, the previous excellent root canal therapy would suggest an endodontic surgery approach, which could guarantee a higher success rate than retreatment. Given this diagnostic doubt, it was decided to perform a 3D study, which revealed an endodontic lesion caused by an untreated lingual canal. This correct

be able to view the slices of the tooth correctly in all three planes, focusing in particular on the axial slices, which will prove to be strategic from an endodontic diagnosis point of view.

Comparing the two teeth shown in Figures 10 to 22 demonstrates just how important it is to analyse all the slices of the CBCT study correctly. We can see that, in the maxillary molar, the lesion penetrates into the pulp chamber, starting from the root's distal surface, but remains within the coronal third of the tooth, without significantly affecting the integrity of the pulp chamber floor (Figs. 10–15). The clinical images illustrate the operative treatment phases, from resorption debridement through to repair using bioceramic cement (Figs. 16–19). The final radiographic images confirm the validity of the conservative and endodontic treatment of the tooth. The situation is completely different for the

Continued on page 14

Straumann Pro Arch concept with fully guided implant and abutment placement

By Dr Nikolay Makarov

In cases of severe posterior bone atrophy, Straumann Pro Arch is a solution that helps achieve fixed restoration for the patient. Straumann Guided Surgery and the coDiagnostiX planning software (Dental Wings) can produce predictable results in cases of complex bone anatomy or when implants are placed such to obtain planned multi-unit angulation. With CARES Visual (Straumann), we can obtain a precise framework fit on the original components, which is fundamental for the final restoration.

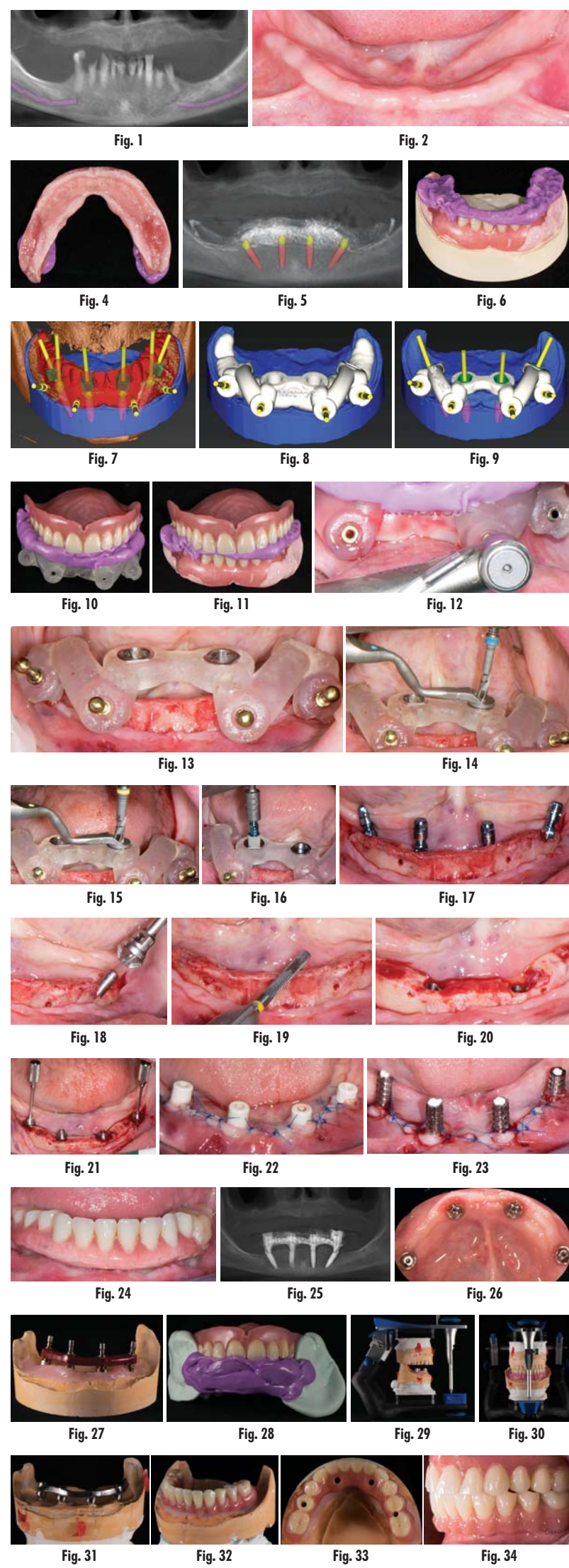
Initial situation

A 70-year-old female patient in good general health presented to a private practice with an edentulous maxilla and partially edentulous mandible seeking a fullmouth rehabilitation. Conditions in the maxilla allowed satisfactory retention of a new complete denture, which was accepted by the patient, while the mandible exhibited severe atrophy of the hard- and soft-tissue in the posterior region and hopeless teeth in the frontal area, as observed clinically and confirmed by a CT scan (Fig. 1).

Treatment planning

Bone quality in the mandible allowed placement of four implants in the anterior region, with both lateral implants tilted, and did not allow for any implants to be placed in the distal area. For these reasons, the Pro Arch concept was chosen as a treatment modality. As bone conditions in the mandible were very difficult in terms of correct implant placement, it was decided to place them with the help of a surgical guide.

The planning included several steps. First, the hopeless teeth in the mandible were to be extracted, followed by delivery of a complete immediate denture, as they did not offer any stable support for a surgical guide. Six weeks later, owing to the lack of keratinised tissue in the premolar regions, apical repositioning and a free gingival graft were performed (Fig. 2). After 1.5 months, the denture was relined with a mixture of barium sulphate and resin, transforming the denture into a radiographic stent (Fig. 3). Another CT scan was recorded with the stent in the mouth (Fig. 4). The stone cast of the stent was poured (Fig. 5), giving us the actual clinical picture of the mucosa, and both cast and stent were scanned to obtain their STL files. Using the coDiagnostiX planning software, the radiopaque saddle of the stent and the STL scan were matched, which also allowed the stent to be matched with the cast as positive and



negative, thus, giving us the soft-tissue volume. Implants were planned in a prosthetically driven manner at sites #34, 32, 42 and 44, with corresponding screw-retained abutments (Fig. 6).

Because of an open-flap procedure owing to the lack of keratinised tissue and the placement of long implants (all Straumann BLT Roxolid, SLA implants; 4.1 × 12.0 mm), it was decided to make two surgical guides: first, a mucosa-supported guide only for drilling the template fixation pins (Straumann; Fig. 7); and second, a pin-supported guide for fully guided implant placement (Fig. 8).

The software can be used to choose a screw-retained abutment in implant planning. Also, we can plan abutment placement with the engraving of implant rotation markers on the guide. This planning helps us stop at the right moment in terms of rotation at the very end of implant placement. We planned to convert the denture into an immediate temporary fixed restoration and deliver the final restoration three months after implant placement.

Surgical procedure

On the day of surgery, two impressions were taken: first with the guide for the pins for stable drilling (Fig. 9), then with the existing prosthesis (Fig. 10) for its correct conversion into an immediate restoration. The first mucosa-supported guide was used for drilling the sites for template fixation pins (Fig. 11). Next, the guide was removed, the flap was raised and the second guide was fixed with the pins at the corresponding sites (Fig. 12).

Implant beds were prepared (Figs. 13 & 14) and Straumann BLT implants placed with a torque setting of more than 35 Ncm, following the protocol to allow correct subsequent screw retained abutment placement (Figs. 15 & 16). Bone around the implants was prepared with bone profilers (Straumann) for the same reason (Fig. 17). The crest was flattened (Figs. 18 & 19), screw-retained abutments were screwed to 35 Ncm (Fig. 20) and covered with healing caps, and the wound was sutured (Fig. 21).

Prosthetic procedure

Provisional restoration

On the same day of the surgery, the existing denture was converted into an immediate temporary fixed restoration by adjusting it on temporary abutments directly in the mouth (Fig. 22), and an impression was taken as a double-check. The restoration was tightened to 15 Ncm (Fig. 23). Ten days later, the sutures were removed, the control CT scan was recorded (Fig. 24) and the results

Continued on Page 15